

Mitral Anterior Leaflet Perforation Due to Jet Flow in Aortic Valve Insufficiency

© Mehmet Işık, © Muhammet B Cavlak, © Serkan Yıldırım, © Yüksel Dereli

Necmettin Erbakan University Faculty of Medicine Hospital, Department of Cardiovascular Surgery, Konya, Turkey

Abstract

Mitral valve disease is one of the most common pathologies of heart valve diseases. Mitral regurgitation may develop due to pathologies in the valve apparatus (primary regurgitation) or due to pathologies related to the atrium and/or ventricle (secondary regurgitation). Treatment options include medical, transcatheter, and surgical approaches, depending on the course of the disease. In this study, we present a patient with perforation in the mitral anterior leaflet secondary to aortic valve regurgitation. Mid-aortic regurgitation (jet flow directed toward the mitral anterior) was observed on echocardiography. It was interesting that the perforation in the mitral anterior leaflet developed secondary to aortic valve regurgitation. Aortic valve replacement and mitral valve repair were performed. The successful surgery and images of the case are wanted to be shared.

Keywords: Mitral regurgitation; aortic regurgitation; mitral repair

Introduction

Mitral insufficiency is the most common heart valve disease in the United States and the second most common heart valve disease requiring surgical intervention in Europe⁽¹⁾. Its prevalence increases to approximately 9% in the population over 75 years of age⁽²⁾. Mitral regurgitation is classified as primary or secondary, depending on the etiology. In primary mitral insufficiency, valve defects

prevent coaptation. In secondary failure, although the valve is normal, there are problems in parts of the heart other than the valve (atrium and/or ventricle). Treatment options may include medical, transcatheter, and surgical approaches, depending on the course of the disease⁽³⁾.

Etiological distribution of patients requiring surgery; primary myxomatous, 61%; rheumatic, 22%; endocarditis, 5%; non-ischemic cardiomyopathies, 3%; and ischemia-induced, 1.3%(4).



Address for Correspondence: Mehmet Işık, Necmettin Erbakan University Faculty of Medicine Hospital, Department of Cardiovascular Surgery, Konya, Turkey

e-mail: drmisik@hotmail.com **ORCID:** orcid.org/0000-0002-2154-7473

Received: 08.12.2024 **Accepted:** 07.01.2025 **Epub:** 10.01.2025 **Publication Date:**

Cite this article as: Işık M, Cavlak MB, Yıldırım S, Dereli Y. Mitral anterior leaflet perforation due to jet flow in aortic valve insufficiency. J Updates Cardiovasc Med. [Epub Ahead of Print].

DOI: 10.32596/jucvm.galenos.2025.2024-40-121



Copyright © 2025 The Author. Published by Galenos Publishing House on behalf of Heart and Health Foundation of Turkey (HHFT). This is an open access article under the Creative Commons Attribution-NonCommercial-NoDerivatives 4.0 (CC BY-NC-ND) International License.

In this study, we present a patient who developed perforation in the mitral anterior valve due to aortic valve regurgitation. Eccentric mid-aortic insufficiency (jet flow toward the mitral anterior) was observed on echocardiography. It was interesting that the perforation in the mitral anterior leaflet developed secondary to aortic valve insufficiency. Aortic valve replacement and mitral valve repair were performed. We wanted to share images of successful surgery and cases.

Case Presentation

The patient was 67 years old and male. He had complaints of exertional dyspnea and orthopnea that had been present for 2 months. He had a history of chronic obstructive pulmonary disease, hypertension, and smoking. No history of coronary or vascular intervention. As a result of echocardiography, the ejection fraction was 60%, sinus valsalva was 3.8 cm, ascending aorta is 3.7 cm, aortic regurgitation is moderate and eccentric (jet flow is mitral anterior leaflet oriented), severe mitral regurgitation, left atrial dilatation (left atrium 4.9 cm), mitral Cleft and color transition were observed in the anterior leaflet, and pulmonary artery pressure was found to be 43 mmHg. In the preoperative examinations, blood samples, chest X-ray, and coronary angiography were evaluated as normal. Electrocardiogram was in sinus rhythm. The surgery decision was made by the Cardiology and Cardiovascular Surgery Council. Informed consent was obtained from the patient. Median sternotomy was performed under general anesthesia. The valve was accessed via right atriotomy and atrial septostomy with cardiopulmonary bypass. A large perforated area was observed in the mitral anterior leaflet (Figure 1). This area was first repaired with 5/0 polypropylene suture, and mitral annuloplasty was performed with a 32-mm 3D ring (Figure 2). The aortic valve was then reached via aortotomy. The valve was tricuspid. The aortic valve was too degenerative for repair. Therefore, the aortic valve was replaced with a mechanical valve number 27. There was no bacterial growth in the aortic valve tissue taken. We completed the surgery using the standard procedure.

The patient was extubated at 6 hours after surgery. We did not observe any pathology on control echocardiography and we discharged him on the 5th day after surgery.

Discussion

Mitral regurgitation can develop due to pathology in the valve apparatus, as well as pathologies related to the atrium (atrial fibrillation, atrial dilatation, etc.) and/or ventricle (cardiomyopathy, ischemia, etc.). The causes of valve pathology include rheumatic valve disease, degeneration, endocarditic and myxoma⁽¹⁾.

Aortic valve regurgitation jet stream; It can be quite heterogeneous, as it can develop depending on the valve structure, valve asymmetry, aortic root dilatation, and acquired abnormalities (endocarditic or degenerative)⁽⁵⁾. Mitral regurgitation due to aortic valve regurgitation jets has been reported in the literature⁽⁶⁾. In some cases of

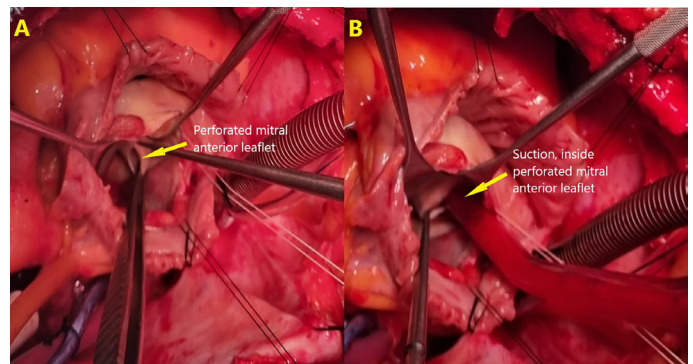


Figure 1. (A,B) Images of the perforated mitral anterior leaflet

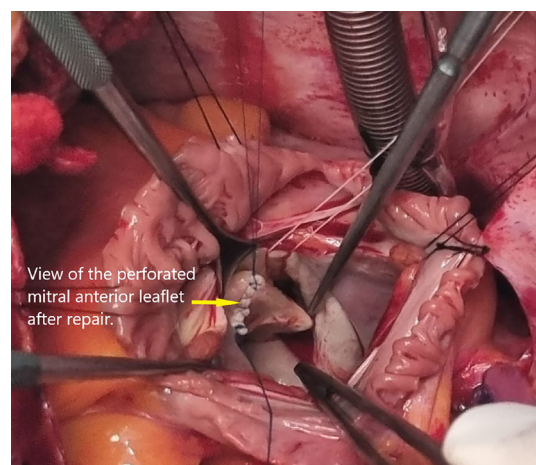


Figure 2. Post-repair view of the perforated mitral anterior leaflet

the bicuspid aortic valve, the regurgitation jet is directed toward the anterior mitral leaflet, thereby affecting valve patency⁽⁷⁾.

The patient had no previous history of coronary or vascular intervention. It was determined that he did not have febrile illness similar to infective endocarditic. Infection parameters were normal in the analysis performed. In echocardiography; The aortic valves were tricuspid. We found that moderate aortic jet flow was directed toward the anterior mitral valve leaflet. Aortic valve insufficiency is a characteristic of degenerative valve disease. As a result, we concluded that severe mitral regurgitation is a newly developing condition caused by aortic jet flow.

In non-ischemic mitral valve regurgitation, mitral valve repair is preferred over valve replacement. Lower cost and valve-related complications, including bleeding and thrombosis events, have been reported⁽⁸⁾. Similarly, significantly fewer complications and better quality of life have been reported in patients undergoing aortic valve repair compared with mechanical valve replacement⁽⁹⁾. In the present case, we repaired the valve primarily because there was only mitral valve anterior leaflet perforation, and the other valve apparatus was normal. Since the insufficiency of the aortic valve was degenerative, it could not be repaired, and mechanical valve replacement. Although 67 years old, he was vigorous. For this reason, we used a mechanical valve with better durability instead of a bioprosthetic valve.

Conclusion

As a result, it should be kept in mind that mitral valve perforation may occur in patients with newly developing mitral insufficiency who are followed up with aortic regurgitation.

Ethics

Informed Consent: Informed consent was obtained from the patient.

Footnotes

Authorship Contributions

Surgical and Medical Practices: Işık M, Cavlak MB, Yıldırım S, Dereli Y, Concept: Işık M, Yıldırım S, Dereli Y, Design: Işık M, Data Collection and/or Processing: Işık M, Cavlak MB, Analysis and/or Interpretation: Işık M, Literature Search: Işık M, Yıldırım S, Dereli Y, Writing: Işık M, Yıldırım S, Dereli Y.

Conflict of Interest: The author declare no conflicts of interest concerning the authorship or publication of this article.

Financial Disclosure: This research received no specific grants from any funding agency in the commercial or not-for-profit sectors.

References

1. Enriquez-Sarano M, Akins CW, Vahanian A. Mitral regurgitation. *Lancet*. 2009;373:1382-94.
2. Harky A, Botezatu B, Kakar S, et al. Mitral valve diseases: pathophysiology and interventions. *Prog Cardiovasc Dis*. 2021;67:98-104.
3. Vahanian A, Beyersdorf F, Praz F, et al. 2021 ESC/EACTS Guidelines for the management of valvular heart disease. *Eur Heart J*. 2022;43:561-632. doi: 10.1093/eurheartj/ehab395. Erratum in: *Eur Heart J*. 2022;43:2022.
4. Maher T, Vegh A, Uretsky S. Mitral regurgitation: advanced imaging parameters and changing treatment landscape. *Heart Fail Clin*. 2023;19:525-30.
5. Roberts WC, McCullough SP, Vasudevan A. Characteristics of adults having aortic valve replacement for pure aortic regurgitation involving a congenitally bicuspid aortic valve unaffected by infective endocarditis or aortic dissection. *Am J Cardiol*. 2018;122:2104-11.
6. De Brabandere K, Voigt JU, Rex S, et al. Aortic and mitral valve repair for anterior mitral leaflet perforation caused by severe aortic regurgitation. *J Vis Surg*. 2018;4:99.
7. Galea N, Pambianchi G, Cundari G, et al. Impaction of regurgitation jet on anterior mitral leaflet is associated with diastolic dysfunction in patients with bicuspid aortic valve and mild insufficiency: a cardiovascular magnetic resonance study. *Int J Cardiovasc Imaging*. 2022;38:211-21.
8. McNeely CA, Vassileva CM. Long-term outcomes of mitral valve repair versus replacement for degenerative disease: a systematic review. *Curr Cardiol Rev*. 2015;11:157-62.
9. Aicher D, Holz A, Feldner S, et al. Quality of life after aortic valve surgery: replacement versus reconstruction. *J Thorac Cardiovasc Surg*. 2011;142:19-24.