

Intracerebral Hemorrhage after Discharge from Carotid Endarterectomy: An Extraordinary Complication Despite Standard Anticoagulation

© Hüseyin Demirtaş, © Abdullah Özer, © Mehmet Burak Gülcan, © Hacı Delibaş, © Levent Otkar

Gazi University Faculty of Medicine, Department of Cardiovascular Surgery, Ankara, Turkey

Abstract

Carotid artery disease is the most important source of cerebrovascular diseases, causing a high rate of morbidity and mortality. While there are medical and interventional treatment options for carotid artery disease, carotid endarterectomy (CEA) is the gold standard treatment for severe carotid artery stenosis. Our study focuses on a rare complication encountered in a 74-year-old female patient who underwent carotid endarterectomy for carotid artery disease. Our patient, who had a smooth postoperative course, developed intracranial hemorrhage after discharge. This complication, occurring under standard antiplatelet therapy, is quite rare in the literature. Our aim is to contribute this rare complication to the literature with our case report.

Introduction

Intracerebral hemorrhage (ICH) is described as the clinical situation regarding bleeding in intracranial area including parenchyma and meningeal spaces⁽¹⁾.

In the USA, approximately 50.000 individuals are suffering from intracerebral hemorrhage annually⁽¹⁾. Only one of five can be healed functionally⁽¹⁾. Also, the 30-day mortality rate can project to 50%⁽¹⁾. Thus,



Address for Correspondence: Mehmet Burak Gülcan, Gazi University Faculty of Medicine, Department of Cardiovascular Surgery, Ankara, Turkey

e-mail: drmburakgulcan@gmail.com **ORCID:** orcid.org/0000-0003-4572-9359

Received: 09.02.2024 **Accepted:** 13.03.2024

Cite this article as: Demirtaş H, Özer A, Gülcan MB, Delibaş H, Otkar L. Intracerebral Hemorrhage after Discharge from Carotid Endarterectomy: An Extraordinary Complication Despite Standard Anticoagulation. EJCM 2024;12(1):25-28.

DOI: 10.32596/ejcm.galenos.2024.2024-4-58



©2024 The Author. Published by Galenos Publishing House on behalf of the Heart and Health Foundation of Turkey (HHFT). This is an open-access article under the Creative Commons Attribution-NonCommercial-NoDerivatives 4.0 (CC BY-NC-ND) International License.

intracerebral hemorrhage is related to poor outcomes. Risk factors may include male gender, aged population, Asian genetic background, alcohol consumption, high cholesterol levels, anticoagulation therapy, and drug use⁽¹⁾. Coma, headache, vomiting, nausea, seizures, focal and generalized neurological symptoms can be seen in victims⁽¹⁾. Computed tomography (CT), CT angiography, and magnetic resonance imaging (MRI) are common imaging techniques to diagnose⁽¹⁾. Hence, intracranial hemorrhage after carotid endarterectomy (CEA) is an extremely rare clinical picture that is related to hyperperfusion syndrome (HPS)⁽²⁾. It occurs less than 0,5% of all carotid endarterectomy cases⁽²⁾. The lack of the vascular autoregulatory mechanism in the affected hemisphere is blamed as a known pathophysiological event⁽²⁾. Seizures, headache, focal deficits may be seen as HPS related symptoms⁽²⁾. HPS is encountered more commonly, approximately 2,5% of all carotid endarterectomy cases⁽²⁾. ICH and HPS are related to high mortality and morbidity as a complication of the CEA⁽²⁾. Our aim is to declare an intracerebral hemorrhage after the CEA as a rare clinical entity. We believe that our study may contribute to the literature.

Case Presentation

A 74-year-old woman admitted to the cardiovascular surgery clinic for her complaint of left leg pain. That pain had been present for a year while walking 200 meters. The patient had a history of hypertension, diabetes mellitus, and hypothyroidism. There was no history of smoking or known cardiovascular disease, and any neurological disease. Physical examination revealed absent left femoral pulse and a murmur on the left carotid artery. Duplex ultrasonography showed monophasic flow in the left femoral and popliteal arteries. Bilateral carotid-vertebral artery duplex ultrasonography revealed a calcified plaque extending from the common carotid artery to the internal carotid artery on the right side, and a 70% stenosis and calcified plaque extending from the common carotid artery to the internal carotid artery on the left side. Angiography was performed for the lower extremities, carotid arteries,

and coronary arteries in the same session. Left internal carotid artery was more than 90% stenotic. There was no significant stenosis in the coronary arteries, but a 70% stenosis was observed in the left iliac artery.

Endarterectomy was planned for the stenosis in the left internal carotid artery. Incision was made on the medial border of the left sternocleidomastoid muscle. Plaque location was identified, and arteriotomy was performed. Shunt was also employed. The plaque was removed with the help of a plaque elevator. Standard closure was performed after the successful process. The patient was also monitored with cerebral oxygenation during the operation. Afterwards, the patient's intensive care unit follow up was uneventfully done. The patient was discharged on the 4th postoperative day with routine medication.

Nausea and vomiting happened the day after the discharge. After a few hours, confusion happened. The patient's family admitted to the closest emergency department. Cranial CT scan showed intracerebral hemorrhage (Figure 1). The patient was intubated and transferred to our hospital. Afterwards, she underwent emergency surgery under general anesthesia by the neurosurgery department for hematoma evacuation and decompression. After the craniotomy, it was observed that the brain tissue was edematous and pulsatile. Widespread subarachnoid hemorrhage foci were seen in the temporal and frontal lobes. Hematoma evacuation and decompression were performed. The patient was followed up in the intensive care unit post-op while intubated. After approximately 1 month of follow-up in the ICU with a GCS score of 3, the patient passed away.

Discussion

Carotid artery stenosis can be defined as greater than 50% stenosis of internal carotid artery (ICA) according to The North American Symptomatic Carotid Endarterectomy Trial-NASCET classification⁽³⁾. Doppler ultrasound (DUS) may be beneficial as a first step imaging technique, and also provide detailed information about a plaque^(3,4).

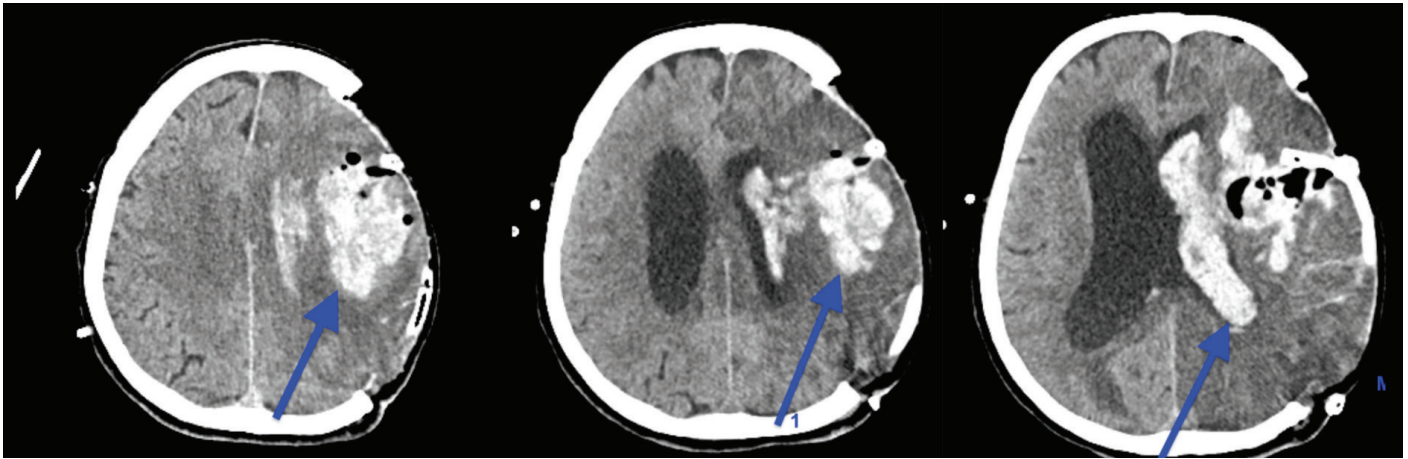


Figure 1. Arrows show hemorrhage areas on CT images in different sections
CT: Computed tomography

CT angiography (CTA) and MR angiography (MRA) also can be helpful to gain further information^(3,4). Digital subtraction angiography (DSA) is necessary when the plan of a surgery exists⁽³⁾. DSA is a gold standard technique for carotid artery imaging⁽⁴⁾. If there is significant narrowing, which is 60-99%, in carotid arteries in the asymptomatic patient whose life expectancy is greater than 5 years, CEA is recommended⁽⁴⁾.

CEA can be defined as the best treatment for symptomatic critical stenosis of the internal carotid artery in order to prevent stroke⁽⁵⁾. Hence, carotid artery stenting (CAS) has advantages to be a more noninvasive technique, lack of risks regarding wound⁽³⁾. However, CEA provides significant advantages rather than CAS in terms of 30 days of stroke and death rates⁽⁶⁾. Thus, CAS is considered as an alternative to CEA⁽⁷⁾. Hence, CAS could be beneficial when the patient is in high risk for surgery which situations like previous radical neck surgery, cervical irradiation history, re-stenosis after CEA, older than 80 years age, major cardiac disease, or chronic obstructive pulmonary disease⁽⁴⁾. Given parallel to improvements in endovascular treatments, ischemic stroke rates lowered, but HPS and ICH became the usual suspect of morbidity and mortality after CAS⁽⁷⁾. Both HPS and ICH are existing as the complication of the carotid artery stenting⁽²⁾.

Outcomes of both HPS and ICH regarding CAS are worse than outcomes regarding CEA⁽²⁾. In addition, more acute onset exists in CAS related ICH with a greater than 5% incidence⁽²⁾.

There is a case in the literature, similar to our study, in terms of the age of the patient and clinical situation after CEA⁽⁸⁾. However, there are some differences. In our case, ICH occurred after uneventful discharge of the patient under standard antiplatelet therapy. Our patient had leaved the hospital by walking. Thus, it is hard to be linked between ICH and the operation. Conversely, ICH has occurred just after the procedure in other case⁽⁸⁾. Despite, their patient's prognosis is better than ours⁽⁸⁾. It seems where the event was happening could have been a critical role in prognosis. In their patient, they have intervened as soon as they can in hospital and ICU with the entire team. It shows the importance of the time of the intervention.

Intracerebral hemorrhage may be encountered after carotid surgery and interventions. Thus, it should be considered when planning the procedure. Although encountering such a rare complication is not sympathetic to a practitioner, it is our scientific duty to declare this seldom complication in order to contribute to the literature.

Ethics

Informed Consent: Informed consent was obtained.

Authorship Contributions

Surgical and Medical Practices: Concept: Design: Data Collection and/or Processing: Analysis and/or Interpretation: Literature Search: Writing: All authors contributed equally to the article.

Conflict of Interest: The authors declare no conflicts of interest concerning the authorship or publication of this article.

Financial Disclosure: This research received no specific grants from any funding agency in the commercial or not-for-profit sectors

References

1. Caceres JA, Goldstein JN. Intracranial Hemorrhage. *Emerg Med Clin North Am* 2012;30:771-94.
2. Timaran CH, Veith FJ, Rosero EB, Modrall JG, Valentine RJ, Clagett GP. Intracranial Hemorrhage After Carotid Endarterectomy and Carotid Stenting In The United States in 2005. *J Vasc Surg* 2009;49:623-9.
3. Aboyans V, Ricco JB, Bartelink MLEL, et al. 2017 ESC Guidelines on the Diagnosis and Treatment of Peripheral Arterial Diseases, in collaboration with the European Society for Vascular Surgery (ESVS): Document covering atherosclerotic disease of extracranial carotid and vertebral, mesenteric, renal, upper and lower extremity arteries Endorsed by: the European Stroke Organization (ESO) The Task Force for the Diagnosis and Treatment of Peripheral Arterial Diseases of the European Society of Cardiology (ESC) and of the European Society for Vascular Surgery (ESVS). *Eur Heart J* 2018;39:763-816.
4. Naylor R, Rantner B, Ancetti S, et al. Editor's Choice - European Society for Vascular Surgery (ESVS) 2023 Clinical Practice Guidelines on the Management of Atherosclerotic Carotid and Vertebral Artery Disease. *Eur J Vasc Endovasc Surg* 2023;65:7-111.
5. Russell DA, Gough MJ. Intracerebral Haemorrhage Following Carotid Endarterectomy. *Eur J Vasc Endovasc Surg* 2004;28:115-23.
6. Saratzis A, Naylor R. 30 Day Outcomes After Carotid Interventions: An Updated Meta-analysis of Randomised Controlled Trials in Asymptomatic Patients. *Eur J Vasc Endovasc Surg* 2022;63:157-8.
7. Abou-Chebl A, Yadav JS, Reginelli JP, Bajzer C, Bhatt D, Krieger DW. Intracranial Hemorrhage and Hyperperfusion Syndrome Following Carotid Artery Stenting. *J Am Coll Cardiol* 2004;43:1596-601.
8. Ogasawara K, Inoue T, Kobayashi M, Endo H, Fukuda T, Ogawa A. Intracerebral hemorrhage after carotid endarterectomy associated with asymptomatic perioperative cerebral ischemia detected by cerebral perfusion imaging: Case report. *Surg Neurol* 2004;62:319-22.