

# Hybrid treatment of aortic bifurcation aneurysm

Funda Yıldırım<sup>1</sup>, Dilşad Amanvermez Şenarslan<sup>1</sup>, Adnan Taner Kurdal<sup>2</sup>,  
Barış Bayram<sup>1</sup>, Tülün Öztürk<sup>3</sup>, Mustafa Cerrahoğlu<sup>4</sup>, İhsan İşkesen<sup>4</sup>, Ömer Tetik<sup>4</sup>

<sup>1</sup>) Manisa Celal Bayar University Hafsa Sultan Hospital Cardiovascular Surgery Department, MD., Manisa, Turkey

<sup>2</sup>) Manisa Celal Bayar University Hafsa Sultan Hospital Cardiovascular Surgery Department, Assist.Prof., Manisa, Turkey

<sup>3</sup>) Manisa Celal Bayar University Hafsa Sultan Hospital Department of Anesthesiology and Reanimation, Prof.Dr., Manisa, Turkey

<sup>4</sup>) Manisa Celal Bayar University Hafsa Sultan Hospital Cardiovascular Surgery Department, Prof.Dr., Manisa, Turkey

## Abstract

The success of endovascular treatments mostly depends on anatomical suitability. Secure neck and iliac landing zones are required to avoid of endoleaks. Common iliac artery aneurysms frequently extend to the iliac bifurcation and complicates endovascular interventions. We report a hybrid operation of an abdominal bifurcation and extremely angulated iliac artery aneurysm that aneurysmatic segments involving both internal iliac arteries (IIA). We excluded the aneurysm by an uniiliac endovascular stent graft and contralateral IIA flow was supplied by retrograde filling from femoro-femoral bypass after ligation contralateral common iliac artery via retroperitoneal approach. It is important to consider alternative treatment modalities and in cases with extreme anatomic variations, to choose a hybrid endovascular approach may be the most feasible and less invasive.

**Keywords:** Endovascular treatments, hybrid operation, abdominal bifurcation, iliac artery aneurysm.

*Yıldırım F., Amanvermez Şenarslan D., Kurdal A. T., Bayram B., Öztürk T., Cerrahoğlu M., İşkesen İ., Tetik Ö Hybrid treatment of aortic bifurcation aneurysm EJCM 2017; 05 (3): 50-53. Doi: 10.15511/ejcm.17.00350.*

## Introduction

Infrarenal abdominal aortic aneurysm and iliac artery aneurysm are seen mostly together. The success of endovascular treatments mostly depends on anatomical suitability. Secure neck and iliac landing zones are required to avoid of endoleaks. Common iliac artery aneurysms (CIA) frequently extend to the iliac bifurcation and complicate the endovascular interventions. The preservation of circulation of at least one internal iliac artery (IIA) is highly recommended.

## Case

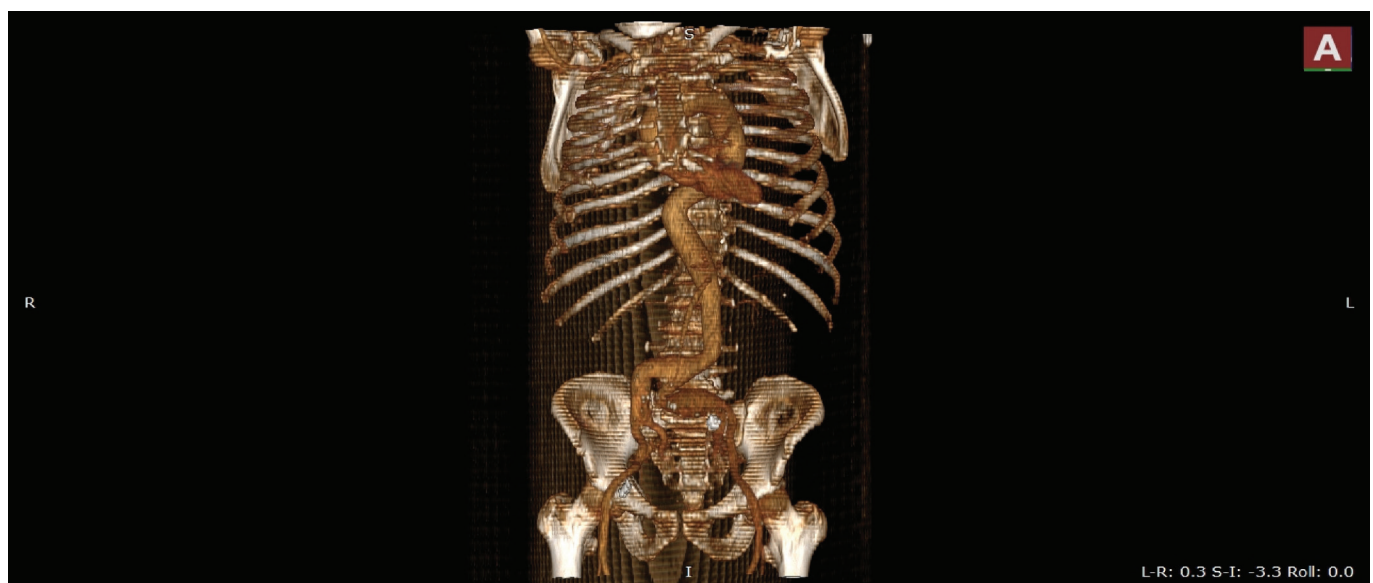
We report a hybrid operation of an abdominal bifurcation and extremely angulated iliac artery aneurysm that aneurysmatic segments involves both internal iliac arteries. A 71-year old man was diagnosed incidentally aortoiliac aneurysm by routine urologic examination and referred to our clinic (Figure 1). We planned hybrid approach. Both common femoral arteries were explored and snared. The aneurysm is excluded by a aorto-uniiliac endovascular stent graft system (Endurant II, Medtronic™) that extending to the right external iliac artery (EIA) and right IIA is closed with the extension graft. A femoro-femoral bypass is made with

8 mm ringed PTFE graft to supply left lower extremity circulation (Figure 2, 3). Then we explored the left common aneurysmatic iliac artery by retroperitoneal approach with lateral oblique abdominal incision. We ligated the CIA with nylon tape to prevent the enlargement of aneurysmal sac of the left CIA. The flow to the left IIA was supplied by retrograde filling from femoro-femoral bypass. Then we observed the decreased tension of the aneurysmal sac in left CIA also the left IIA pulse was palpated. No proximal, distal, or graft junction endoleaks occurred. The patient was discharged without trouble at postoperative fourth day.

## Discussion

EVAR has become the firstline choice in abdominal aortic aneurysm repair. But there are some limitations to its use; hostile neck anatomy, hostile iliac anatomy (HIA) and aneurysmal enlargement involving bilateral internal iliac artery. Approximately 30% of patients treated by EVAR have ectatic or aneurysmal common iliac arteries not suitable for distal sealing zones. Bilateral internal iliac artery occlusion during endovascular repair may lead significant morbidity, including gluteal claudication, erectile dysfunction, ischemia of the sigmoid colon and perineum and spinal cord injury.<sup>(1,2,3)</sup>

**Figure 1.** Computed tomography angiography 3 dimensional reconstruction view, aortic aneurysm just prior to aortic bifurcation and extending to common iliac artery. Aneurysmatic segment involves bilateral internal iliac artery and hostile iliac arteries.



In CIA aneurysms involving the IIA, there are some ways of preserving flow to IIA; Surgical revascularization of IIA via retroperitoneal or retroinguinal incision. An uncovered stent can extend the sealing zones, whilst maintaining complete preservation of pelvic circulation and offers support to the covered stent-graft.<sup>(4)</sup> Iliac side-branched graft (IBG) or sandwich technique can maintain pelvic perfusion. However, these adjunctive procedures increase the risk of endoleaks and they need to be applied by an experienced interventionist because of its technical difficulties.<sup>(5-8)</sup>

The presence of narrow iliac arteries (diameter <7 mm), hemodynamic iliac stenosis or obstruction, severe or extensive calcifications (>50%iliac circumferential calcification), angulations (>90 degree), previous aortailiac/femoral graft was defined as HIA.<sup>(5)</sup> HIA or previous surgical or endovascular graft greatly limits the endograft's maneuverability.<sup>(9)</sup>

This case have an aortic aneurysm just prior to aortic bifurcation and extending to CIA. The case is an

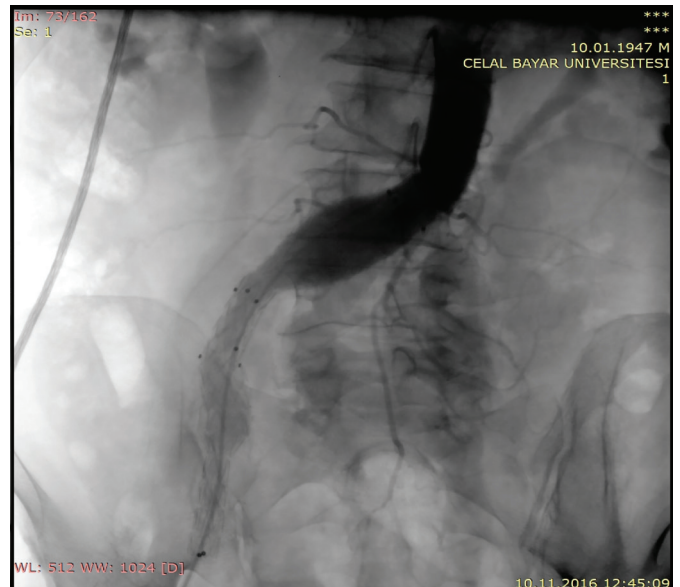
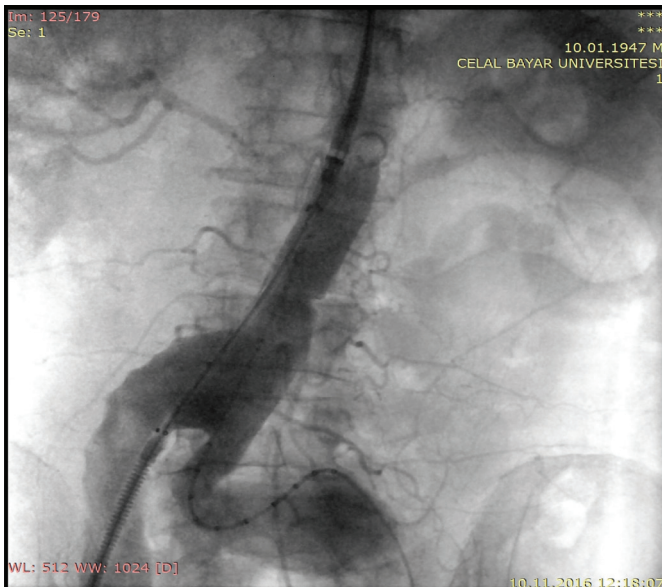
example to hostile iliac artery because of severe iliac angulation and also it is complicated by aneurysmatic segment involving bilateral IIA ostium. The aneurysm is treated in combined fasion: endovascular and conventional surgery. We used this approach for two reasons. First, to prevent recurrent king or stenosis of the left iliac endograft system due to extreme angulation to the right side. Secondly, to preserve the blood supply of at least one of the internal iliac artery.

We think that it is important to consider alternative treatment modalities and in cases with extreme anatomic variations, to choose a hybrid endovascular approach may be the most feasible and less invasive.

### Conclusion

Despite progress in endovascular therapy, large infrarenal to use combined thoracic and abdominal stent graft as an alternative treatment modality when the patient is not suitable for standard EVAR and open surgery.

**Figure 2, 3.** Insertion of uniiliac stent graft system.



## References

1. Faries PL, Morrissey N, Burks JA, Gravereaux E, Kerstein MD, Teodorescu VJ et al. Internal iliac artery revascularization as an adjunct to endovascular repair of aortoiliac aneurysms. *J Vasc Surg* 2001; 34(5): 892-9.
2. Cochenec F, Marzelle J, Allaire E, Desgranges P, Becquemin JP. Open vs endovascular repair of abdominal aortic aneurysm involving the iliac bifurcation. *J Vasc Surg* 2010; 51(6): 1360-6.
3. Bosanquet DC, Wilcox C, Whitehurst L, Cox A, Williams IM, Twine CP; British Society of Endovascular therapy (BSET). Systematic Review and Meta-analysis of the Effect of Internal Iliac Artery Exclusion for Patients Undergoing EVAR. *Eur J Vasc Endovasc Surg* 2017; 53(4): 534-548.
4. Silingardi R, Tasselli S, Gennai S, Saitta G, Coppi G. Endovascular preservation of pelvic circulation with external iliac-to-internal iliac artery "cross-stenting" in patients with aorto-iliac aneurysms: a case report and literature review. *J Cardiovasc Surg (Torino)* 2012; 53(5): 651-5.
5. Zeng Q, Huang L, Huang X, Peng M. Endovascular repair of abdominal aortic aneurysm with severely angulated neck and tortuous artery access: case report and literature review. *BMC Surg* 2015; 15: 20.
6. Noel-Lamy M, Jaskolka J, Lindsay TF, Oreopoulos GD, Tan KT. Internal Iliac Aneurysm Repair Outcomes Using a Modification of the Iliac Branch Graft. *Eur J Vasc Endovasc Surg* 2015; 50(4): 474-9.
7. Lim CS, Naji Y, Hussain ST, Pleban E, Wiszniewski A, Onida S et al. Modified Sandwich-graft Technique Employing Aorfix and Viabahn Stent-grafts to Preserve Hypogastric Flow in Cases of Complex Aortoiliac and Isolated Common Iliac Artery Aneurysms Including the Internal Iliac Artery Ostium. *Eur J Vasc Endovasc Surg* 2016; 51(3): 364-70.
8. Donas KP, Torsello G, Pitoulias GA, Austermann M, Papadimitriou DK. Surgical versus endovascular repair by iliac branch device of aneurysms involving the iliac bifurcation. *J Vasc Surg* 2011; 53(5): 1223-9.
9. Gallitto E, Gargiulo M, Faggioli G, Pini R, Mascoli C, Freyrie A et al. Impact of iliac artery anatomy on the outcome of fenestrated and branched endovascular aortic repair. *J Vasc Surg*. 2017; 6. pii: S0741-5214(17)31359-9. doi: 10.1016/j.jvs.2017.04.063. [Epub ahead of print] PubMed PMID: 28888759.

Received: 16/01/2017

Accepted: 22/07/2017

Published: 15/09/2017

### Disclosure and conflicts of interest:

The authors declare no conflict of interest.

### Corresponding author:

MD. Funda Yıldırım

**Mail:** fundanizamoglu@yahoo.com

*Yıldırım F., Amanvermez Şenarslan D., Kurdal A. T., Bayram B., Öztürk T., Cerrahoğlu M., İşkesen İ., Tetik Ö Hybrid treatment of aortic bifurcation aneurysm EJCM 2017; 05 (3): 50-53. Doi: 10.15511/ejcm.17.00350.*