

An useful complication of emergent pericardiocentesis procedure in cardiac tamponade: Case report

Çiğdem İleri¹, Zekeriya Doğan¹, Ahmet Altuğ Çiçin¹, Bülent Mutlu²

¹ Marmara University Faculty of Medicine, Department of Cardiology, Specialist Dr., Istanbul, Turkey

² Marmara University Faculty of Medicine, Department of Cardiology, Prof. Dr., Istanbul, Turkey

Abstract

We present a case of 19-years-old patient was admitted to emergency service with abdominal pain, nausea, dyspnea and loss of appetite for one week and had prodromal symptoms for ten days. He was hypotensive, tachycardic and dyspneic. CT scan indicated large amount of peritoneal, pericardial and bilateral pleural fluid. With the diagnosis of cardiac tamponade; emergent pericardiocentesis (PC) was implemented by apical approach and quick hemodynamic relief was observed. It was understood that rapid haemodynamic response was a result of complication characterized by increase in left pleural fluid and decrease in pericardial effusion.

Keywords: Useful complication, pericardial effusion, pericardiocentesis procedure, cardiac tamponade.

İleri Ç., Doğan Z., Çiçin A. A., Mutlu B. An useful complication of emergent pericardiocentesis procedure in cardiac tamponade: Case report. EJCM 2016; 04 (4): 93-96. Doi: 10.15511/ejcm.16.04093.

Case Report

A 19 years old man with a history of migraine and smoking, was admitted to emergency service with abdominal pain, nausea, dyspnea and loss of appetite for one week. The abdominal pain was worsening by standing and it was relieving by lying down. He had prodromal period symptoms for ten days. Chest x-ray revealed minimal cardiac silhouette enlargement. As computerized tomographic (CT) scan of abdomen and thorax revealed large amount of free peritoneal, 30 mm pericardial, 30 mm pleural effusion in left lung as well as 20 mm effusion in right lung, he was consulted to our department. Electrocardiogram showed sinus tachycardia. Transthoracic echocardiography (TTE) showed large circumferential pericardial effusion (PE) with right atrial (RA) and right ventricular (RV) diastolic collapse and >30% variation in mitral inflow pattern suggesting cardiac tamponade (Figure 1). He was hypotensive and tachycardic during examination; pulsus paradoxus was observed at the same time. It was concluded that the most convenient way for PC was apical approach. However collecting very small amount of pericardial

fluid (15 cc), his hemodynamic profile was rapidly improved. A CT scan of thorax was taken immediately and 15 mm residual pericardial effusion was implemented; but 20 mm effusion at right and 45 mm at left lung was identified. (Figure 2). Thoracal drainage tube was inserted left pleural cavity and 500 cc hemorrhagic fluid drainage was collected. Tube was removed 2 days after, and no residual or recurrent effusion existed in his control radiologic examination. Increase in acute phase reactants like, CRP:93(0-5mg/l) fibrinogen:744 (200-400mg/dl), ESR: 53mm/h and neutrophilic leucocytosis was established in blood tests. However pericardial effusion was exudative quality; aerob- anaerob blood, urine and fluid culture was negative, no acid fast bacilli was seen in fluid, ANA, Anti-CCP, Anti-DNA and ENA profile were also normal. Colchicum 2*5mg and brufen 3*600 mg without antibiotic regimen applied as the treatment strategy. 10 days after beginning of the treatment, only 10 mm pericardial effusion at posterior wall and 8 mm at RV neighbouring found in TTE (Figure 3). He was on treatment for two months without any symptoms; rheumatologic and genetic tests are still having been done.

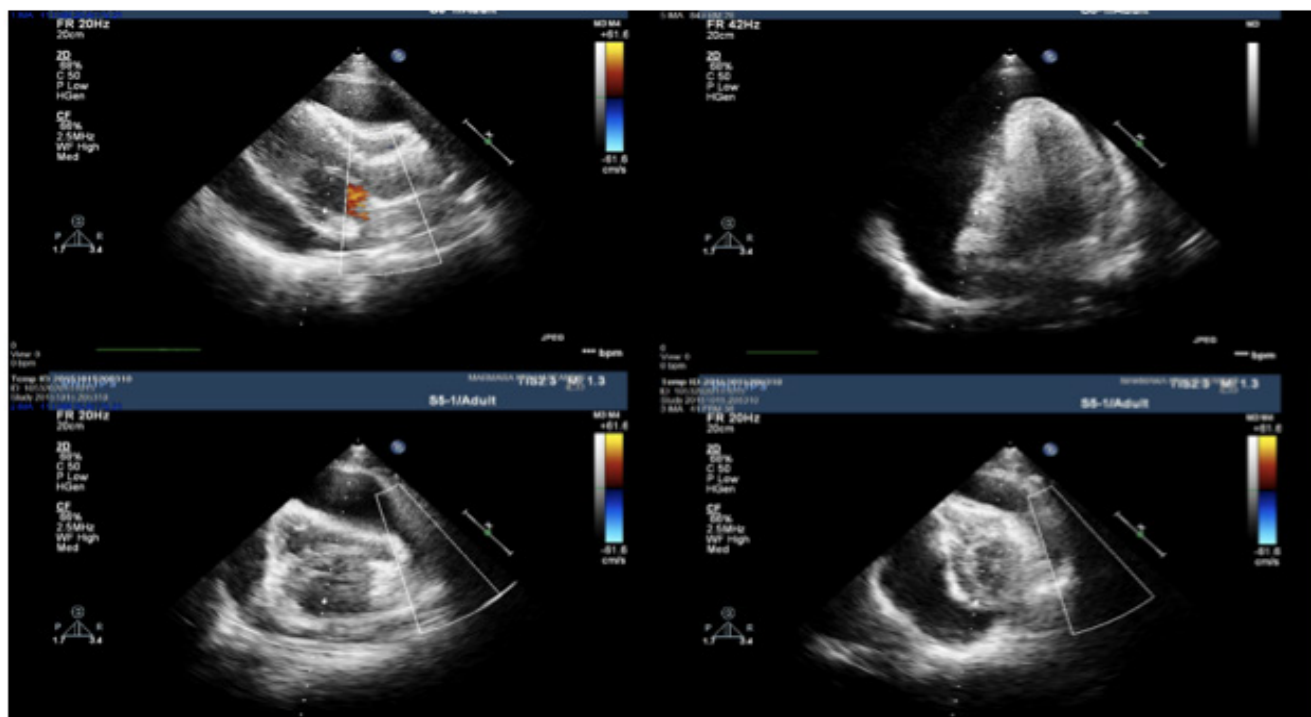


Figure-1: Echocardiographic images before procedure shows right ventricular collapse during diastole

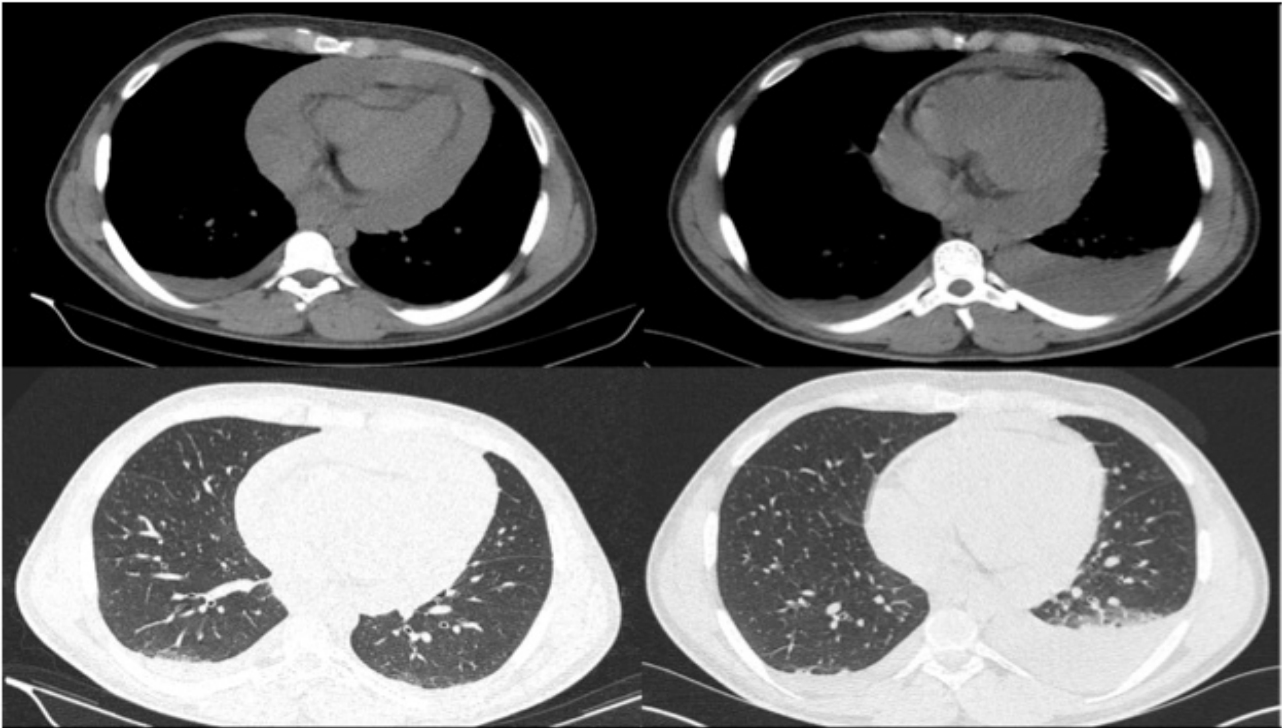


Figure-2: Left side CT images were taken before PC; in right side images after PC representing increase of left pleural effusion

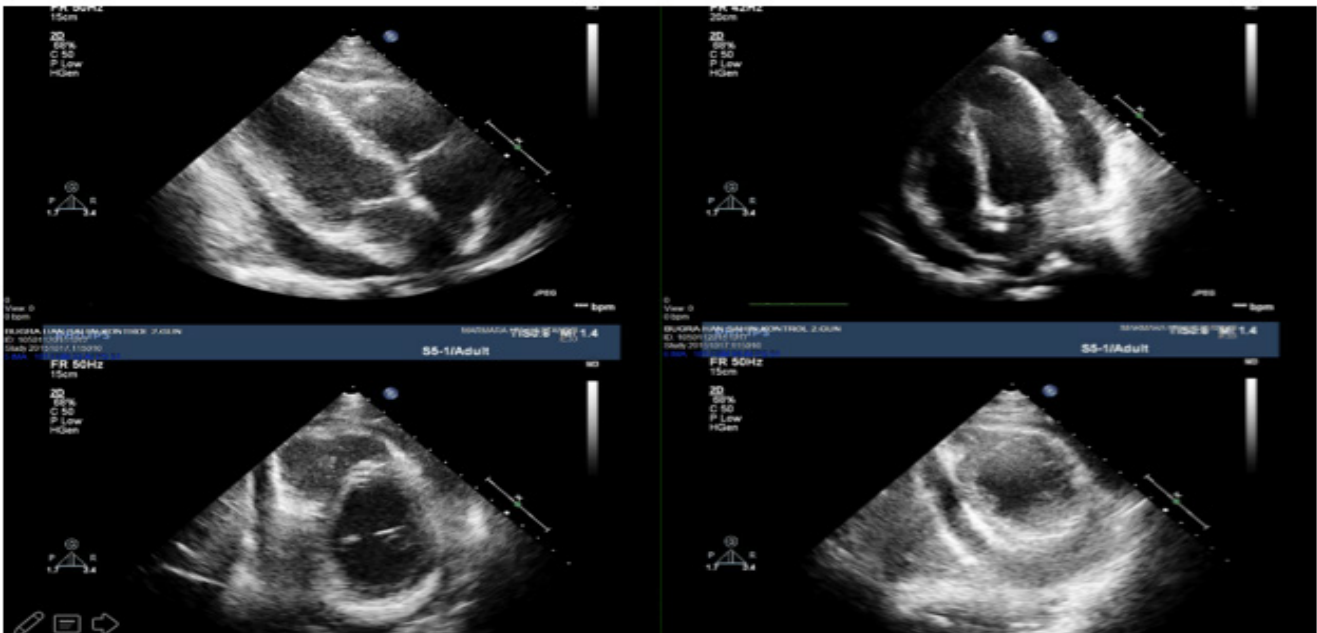


Figure-3: Decreasing amount of effusion and absence of right ventricular diastolic collapse were seen in echocardiographic images after PC

Discussion

Cardiac tamponade is a life-threatening condition and requires emergent treatment. A variety of percutaneous or surgical therapeutic methods have been applied. Pericardiosynthesis is a minimally invasive, easy to perform procedure and has relatively shorter in-hospital stay and lower complication rate than surgical operation. Apical, subxiphoid and other sides are area of interest in procedure. In our clinic, most of the PC are done by apical approach with lower complication rates. In this case, a complication happened during emergent

PC which is likely to occur. Despite symptomatic and haemodynamic relief of patient, immediate echocardiographic study and CT scan was taken due to continuing of clinical suspicion. Thoracal drainage tube inserted fastly as a result of increase in left pleural effusion.

We think that increase in the amount of pleural fluid is an acceptable result confronting with the life threatening feature of tamponade. Mutual result of tamponade, haemodynamic parameters, clinical background of patient as well as collaborative assesment of imaging techniques are contributing to the outcome.

Received: 11/04/2016

Accepted: 06/11/2016

Published: 20/12/2016

Disclosure and conflicts of interest:

Conflicts of interest were not reported.

Corresponding author:

Dr. Ahmet Altuğ Çiçin

Mail: acincin@yahoo.com