

Oral Presentation Session Surgical Alternatives for Atrial Fibrillation

Date: 27.03.2019 Time: 15:15 - 16:15 Hall: 4

ID: 233

Topic: **Cardiovascular Surgery » Surgical Treatment of AF**

Presentation Type: **Oral**

SURGICAL ABLATION OF ATRIAL FIBRILLATION BY A TOTALLY VIDEOTHORACOSCOPIC APPROACH- NEW PARADIGM?

Carolina Rodrigues, Rui Cerejo, Rui Rodrigues, José Fragata

Hospital de Santa Marta, Lisbon, Portugal

**Corresponding Author (rodriguescarolina@gmail.com)*

rodriguescarolina@gmail.com, ruiocerejo@gmail.com, ruirodrigues68@gmail.com, jigfragata@gmail.com

Abstract Text

Background

Maze surgery is a time-consuming invasive procedure, that requires extra-corporeal circulation. Catheter ablation presents highly variable rates of success. Surgical ablation of atrial fibrillation by a totally videothoracoscopic approach, using radiofrequency, is a recent alternative, that we performed for the first time at November of 2017.

Methods

We performed a descriptive analyses of the 13 patients that have been submitted to surgical ablation of atrial fibrillation and occlusion of the left appendage by a totally thoracoscopic approach. We describe the surgical technique and our results, including duration of surgery, hospital stay, complications and conversion to sinus rhythm immediately after surgery, at one month, 6 and 12 months of follow-up.

Results

Of the 13 patients, with ages between 39 and 75 years old, 46% (n=6) are male. The mean time since the diagnosis of atrial fibrillation was 5,75 years. Almost all (n=12) had been submitted to prior catheter ablation (mean of 2 attempts). The mean diameter and volume of left atrium was 42 mm and 70 ml (43 ml/m²). The mean duration of surgery was 2hours and 22 minutes. In only one patient we had to convert to a median sternotomy. The procedure was not possible to perform in one patient. Pacemaker implantation was needed in one patient. The mean hospital stay was 5 days. Mean time of follow-up is 8 months. All patients were maintained on anti-coagulation after the surgery. Patients under anti-arrhythmic drugs pre-operatively, were maintained on anti-arrhythmic after the surgery. At one month follow-up, 91% were in sinus rhythm. At 6 months follow-up, 90% were in sinus rhythm. At November 2018, 4 patients complete 1 year of follow-up. Of those, one has already been evaluated, maintaining sinus rhythm.

Conclusion

We are aware of the small dimensions of this population and short period of follow up. This is a minimally invasive safe approach, reproducible, with a reasonably fast learning curve. Most importantly, it represents a real benefit for those with multiple attempts of catheter ablation without success, and possibly a new paradigm in atrial fibrillation treatment.

ID: 377

Topic: **Cardiovascular Surgery » Surgical Treatment of AF**Presentation Type: **Oral**

TOTALLY THORACOSCOPIC LEFT ATRIAL POSTERIOR WALL ISOLATION IN PATIENTS WITH LONG STANDING PERSISTENT ATRIAL FIBRILLATION

Aleksandr Zotov, Sergei Vachev, **Daniil Borisov**, Aleksandr Troitskiy, Robert Khabazov

Federal Research Clinical Center for Specialized Types of Health Care and Medical Technologies, Moscow, Russia

*Corresponding Author (dan-cer@inbox.ru)

tired.romantic@gmail.com, daniel_burn@mail.ru, dan-cer@inbox.ru, dr.huyancer2@yandex.ru,
dr.huyancer3@yandex.ru

Abstract Text

Background

This single-centre study aimed to evaluate immediate and medium-time efficacy and safety of totally thoracoscopic left atrial posterior wall isolation and appendage resection in patients with long standing persistent atrial fibrillation.

Methods

56 patients with long standing persistent atrial fibrillation underwent totally thoracoscopic left atrial posterior wall isolation and appendage resection (April 2017 – November 2018). Some characteristics of those patients are shown in the Table.

Duration of atrial fibrillation, months (median [min; max])	25 [18; 58]
Left ventricle ejection fraction, Simpson, % (median [min; max])	53 [36; 64]
Drugs refractory tachycardia (> 90/min), Number of pts (N [%])	34 [60.7%]
Endocardial RFA of pulmonary veins in the past, Number of pts (N [%])	18 [32.1%]
Endocardial RFA of cava-tricuspid isthmus in the past, Number of pts (N [%])	10 [17.8%]

We used thoracoscopic ablation device with irrigated electrodes. Basic surgical technique was modified GALAXY procedure [Doty et al.]. At our institution we initially perform 10 lesions from each side with 3-5 mm adjustment between ablations. The device is then removed, cleaned and the same side repeated with a downward angulation of the device for 10 more lesions for a total of 20 lesions on each side. Left atrial appendage was resected with a linear cutting stapler.

Results

The procedure was successfully completed in all patients. The mean number of autonomic ganglia ablated was 6.3 (range, 2-9). There was no operative mortality, no myocardial infarction, and no stroke or transient ischemic attack. Two patients required sternotomy and another one survived left anterolateral thoracotomy due to bleeding. One patient required prolonged non-invasive ventilation for transient bilateral phrenic nerve palsy. Right phrenic nerve injury was documented in two patients.

Mean follow-up was 9 months (range, 2-18 months). At last follow-up, 55 patients (98.2%) were in sinus rhythm, as documented by 24-hour Holter monitoring. Anticoagulation therapy, beta-blockers and amiodarone were discontinued in 55 patients after routine examination (chest X-ray, 24-hour Holter monitoring) 3 months after the surgery. 7 days later routine examination was repeated in all patients in order to exclude cardiac rhythm disorders. One patient reverted to atrial fibrillation. Sotalol administration and electrical cardioversion were unsuccessful.

Conclusion

Frequent ablation device positioning change and increased number of applications during thoracoscopic surgery help to achieve complete left atrial posterior wall isolation and effectively fight re-entry waves, especially in patients with long standing persistent atrial fibrillation.

ID: 390**Topic: Cardiovascular Surgery » Surgical Treatment of AF****Presentation Type: Oral****MITRAL VALVE REPLACEMENT AND SIMULTANEOUS TREATMENT OF THE ATRIAL FIBRILLATION**

Amiran Revishvili¹, Vladislav Aminov², Mihail Svetkin³, **Aleksei Semagin³**, Oleg Lukin²

¹*A.V. Vishnevsky National Medical Research Center of Surgery, Moscow, Russia*

³*Federal Centre for Cardiovascular Surgery, Chelyabinsk, Russia*

**Corresponding Author (voland420@gmail.com)*

voland420@gmail.com, aminovvlad@mail.ru, voland420@gmail.com, voland420@gmail.com, voland420@gmail.com

Abstract Text

BACKGROUND: To evaluate the efficacy of concomitant the Cox-Maze IV procedure for the treatment of atrial fibrillation (AF) after mitral valve replacement.

METHODS: The study had included 118 patients: 29 males and 89 females. The inclusion criteria was mitral valve replacement and concomitant Cox-Maze IV procedure. The mean age was $56,7 \pm 9,6$ years. Most of them (71- 60,2%) had long-standing persistent AF; 28 (23,7%) - persistent AF; 19 (16,1%) - paroxysmal AF. The etiology of mitral valve disease were rheumatic in 95 (80,5%) cases; degenerative in 21 (17,8%); and endocarditis in 2 (1,6%). The Cox-maze IV procedure was performed in all cases.

RESULTS: The hospital mortality rate was 0,8% (1 patient). Ten patients (8,5%) required pacemaker implantation. The indications were sinus node dysfunction in 7 patients, bradycardia AF in 2 patients, av node dysfunction in 1. On discharge 78 patients (66,7%) had a sinus rhythm, 10 (8,5%) had atrial rhythm, a pacemaker rhythm was in 7 (6%), and AF was in 22 (18,8%).

Thus, the rate of freedom from AF was 78,6% (92 patients). The effectiveness of ablation for paroxysmal AF, persistent AF and longstanding persistent AF was 100%, 74,1% and 78,6%, respectively ($p=0,006$). To reveal other predictors of freedom from AF on discharge, each ECHO parameter was included in the simple logistic regression analysis. Statistically significant p-value was obtained for the preoperative right atrial size ($p=0,005$). Value for the index of left atrium (left atrial volume/body surface area) was close to statistically significant threshold ($p=0,052$).

During follow-up 100 patients were examined (85,5%). The mean follow-up time was $42,6 \pm 21,9$ (3 – 88) months. All patients were alive (survival 100%). The rate of freedom from stroke and AF was 97% and 79%, respectively.

CONCLUSIONS: The radiofrequency ablation is an effective method for treatment of AF in patients undergoing mitral valve replacement. The predictors of freedom from AF on discharge are a preoperative form of AF and a preoperative size of both atria.

ID: 500

Topic: **Cardiovascular Surgery » Surgical Treatment of AF**Presentation Type: **Oral****BILATERAL TOTALLY THORACOSCOPIC APPROACH FOR THE TREATMENT OF LONE PERSISTENT ATRIAL FIBRILLATION WITH LEFT ATRIAL APPENDAGE THROMBOSIS****Igor Vendramin, Andrea Lechiancole, Daniela Piani, Ugolino Livi***S.Maria della Misericordia University Hospital, Udine, Italy***Corresponding Author (igor.vendramin@asuiud.sanita.fvg.it)**igor.vendramin@asuiud.sanita.fvg.it, andrea.lechiancole@asuiud.sanita.fvg.it, danielapiani89@gmail.com, ugo.livi@asuiud.sanita.fvg***Abstract Text****BACKGROUND**

•Catheter ablation (CA) and minimally invasive surgical ablation (SA) have become accepted therapy for atrial fibrillation (AF). Over the last decade several studies were published showing an increasing evidence of success with limited complications rates.

•Nevertheless, the presence of a thrombus in the left atrial appendage (LAA) is considered an exclusion criteria for both approaches and for LAA occlusion.

•We describe a new mini-invasive procedure for a combined radiofrequency treatment of AF and exclusion of left appendage with partial thrombosis through a bilateral totally thoracoscopic approach.

METHODS

- Three patients underwent bilateral Totally Thoracoscopic Radiofrequency Ablation of AF and LAA exclusion.
- Partial LAA thrombosis was firstly secured by encircling the LAA base with a 3/0 prolene Ethibinder.
- Ablation was obtained by encircling the pulmonary veins origin ("Box Lesion") with Estech COBRA Fusion device, delivering both bipolar and monopolar energy to create transmural lesions.
- LAA exclusion was finally achieved by deploying the Atricure AtriClip PRO2.

RESULTS

Postoperative course was uneventful and the patient was discharged after 7 days. At 1 year follow-up the sinus rhythm was stable.

CONCLUSIONS

This procedure represents a new mini-invasive method to concurrently treat AF and exclude the LAA in those cases in which a partial thrombosis contraindicate a percutaneous treatment.

ID: 542

Topic: **Cardiovascular Surgery » Surgical Treatment of AF**Presentation Type: **Oral****THE USE OF ABLATION OF THE PULMONARY VEINS FOR THE PREVENTION OF ATRIAL FIBRILLATION AFTER CABG**

Amiran Revishvili, Vadim Popov, Egor Malysenko, Maksim Anishchenko

*A.V. Vishnevsky National Medical Research Center of Surgery, Moscow, Russia***Corresponding Author (max_ress@mail.ru)**max_ress@mail.ru, drpopov@mail.ru, max_ress@mail.ru, max_ress@mail.ru***Abstract Text****Background**

To evaluate in-hospital results in prospective RCT PULVAB (Prophylactic Pulmonary Veins Ablation).

Methods

The RCT PULVAB had been included 96 CAD patients. The study consists from three groups. In 1st group (n=34), only conventional CABG was performed. In 2nd group (n=29), CABG was combined with prophylactic pulmonary vein(PV) bipolar ablation. In 3rd group, CABG was combined with PV ablation and added with the administration of amiodarone just after procedure.

Results

Prophylactic pulmonary bipolar RF ablation did not lead to the increase of the operation main stages length. The mean time of operation is 251 ± 37.7 min in group 1; 250.4 ± 42.5 min in 2nd group and 244.2 ± 29 min in 3rd group, $p = 0.114$) and don't differ in the CPB time: 88.6 ± 19.2 min; 92 ± 18.4 and 84.8 ± 17.3 min ($p = 0.08$) respectively.

We don't have in-hospital mortality. Significant complications (bleeding, wound complications, stroke and perioperative myocardial infarction) are not observed.

Postoperative atrial fibrillation (POAF) identified in 11 (32.4%) cases in the group 1; in 6 (20.7%) cases in the 2nd group and in 2 (6.1%) cases in the 3rd group. There were no significant differences between 1st and 2nd groups ($p = 0.298$) and between 2nd and 3rd groups (0.086) also. The statistical significant differences revealed between 1st and 3rd groups ($p = 0.0065$), which indicates the effectiveness of prevention of POAF with PV ablation+amiodarone administration. Atrial fibrillation in 91% of patients had been occurred at 2-3 days of the postoperative period. Sinus rhythm at discharge from hospital recorded in 97.1% cases in 1st group; in 96.7% cases in 2nd group and in 97% cases in 3rd group ($p = 0.293$).

Conclusion

A positive trend established in reducing the frequency of POAF in patients undergoing preventive bipolar radiofrequency ablation of the pulmonary veins. Combination of bipolar RFA and amiodarone revealed significant positive results in the prevention of POAF.

Oral Presentation Session**Better Understanding and Treatment of Peripheral Venous Problems**

Date: 27.03.2019 Time: 16:15 - 17:15 Hall: 4

ID: 345

Topic: **Cardiovascular Surgery » Various Veins**Presentation Type: **Oral****MICROSURGICAL LYMPHATICOVENOUS ANASTOMOSIS FOR THE TREATMENT OF OBSTRUCTIVE LYMPHEDEMA: A CASE SERIES****Kanat Ozisik, Seyhan Babaroglu, Atike Tekeli Kunt, Serdar Gunaydin***University of Health Sciences Ankara Numune Education and Research Hospital, Ankara, Turkey***Corresponding Author (sozisik2002@yahoo.com)**sozisik2002@yahoo.com, babaroglus@yahoo.com, atikemd@gmail.com, serdarkvc@gmail.com***Abstract Text**

Background: Treatment of lymphedema is challenging therefore therapeutic approaches consist of both non-operative and operative methods. There are many classical surgical approaches in the treatment of obstructive lymphedema of the lower extremities. The application of microsurgical techniques to the drainage of lymph in to the venous system offers new possibilities in this field. Herein we aimed to report the results of our cases treated with microsurgical lymphaticovenous implantation.

Methods: From October 2009 to December 2017, 24 patients (14 females and 10 males) with lymphedema in lower limbs treated by microsurgical lymphaticovenous implantation. The diagnostic evaluation of the patients were made by

Lymphoscintigraphy as a test for selecting patients for derivative microsurgical operations. Doppler USG is performed in all patients to identify any venous system disorders possibly associated with lymphedema. The operations were carried out under local anesthesia. The skin incision was made and exploration of the saphenous vein was carried out first. After identification of the veins, the groin lymph nodes were detected later. The lymph node was decapsulated and the vein was occluded with silk sutures. Lymphaticovenous anastomosis was applied by using 8-0 polypropilen suture.

Results: Patients treated by lymphaticovenous anastomosis were followed from 2 months to 16 months, with an average followup 6 months. Subjective improvement was noted in 83% of patients. These patients felt more comfortable. Only one patient suffered from induration of the operated right lower extremity during the follow up period.

Conclusion: This easy and simple method could be used widely and could provide stable improvement of lymphedema. Surgical treatments still have an important role in the management of lymphedema

ID: 258

Topic: **Cardiovascular Surgery » Various Veins**Presentation Type: **Oral****VENOUS COMPRESSION SYNDROMES: CLINICOPATHOLOGIC AND THERAPEUTIC IMPLICATIONS****Yigit Akcali, Rukiye Derin Atabey, Aydin Tuncay, Halis Yılmaz, Cihat Atabaş***Erciyes University, Kayseri, Turkey***Corresponding Author (yigitakcali@gmail.com)**yigitakcali@gmail.com, rukiyeatabey@hotmail.com, atuncay@erciyes.edu.tr, halisy38@hotmail.com, h.c.atabas@gmail.com***Abstract Text**

OBJECTIVE. Venous compression syndromes (VCSs) are caused by compression of the veins in a limited anatomical area of the thoracic outlet, abdomen or extremities in otherwise healthy young patients and may lead to thrombosis, hematuria and chronic venous insufficiency. Surgery and endovenous procedures are performed in the treatment. We have presented a clinicopathological and therapeutic analysis of our patients with VCS.

METHODS. In the last decade, 110 patients (84 females, 26 males) with median age 33.8 years (range, 12-69) were reviewed (Table I). The VCS ratio among other vascular compression syndromes was high (71.0%). Doppler ultrasonography, MRA, CTA and DSA were used in the diagnosis (Figure 1). Hereditary thrombophilia (HT) was investigated when indicated. The patients were treated medically, surgically and endoluminally.

RESULTS. The ratio of HT in May-Thurner syndrome (MTS) was 34.7%. In nutcracker syndrome (NS), renal vein compression, retroaortic (posterior NS) (9.5%), circumaortic (4.7%), and in the remainder, the renal vein was compressed in varying degrees in the aorto-mesenteric angle (85.8%) (anterior NS). MTS and superior mesenteric artery syndrome were also present in patients with anterior NS (23.8% and 2.4%, respectively). Varicose veins of the vulvar and lower extremities due to pelvic venous insufficiency were observed respectively in 40% and 85% of the patients. The ratio of patients with Paget-Schrötter syndrome (PSS), mostly young male patients, among all DVT patients in the same period was 3.6% and among the other VCSs was 15.4%. One patient had McCleery's syndrome. The incidence of HT among patients with PSS was 22.2%. The ratio of documented single popliteal venous entrapment syndrome among other popliteal vascular compressions was 10%.

CONCLUSIONS. Venous compression syndromes occur due to external compression leading to venous hypertension or venous thrombosis. Long-term unfavorable results can be avoided if they are diagnosed early and treated appropriately.

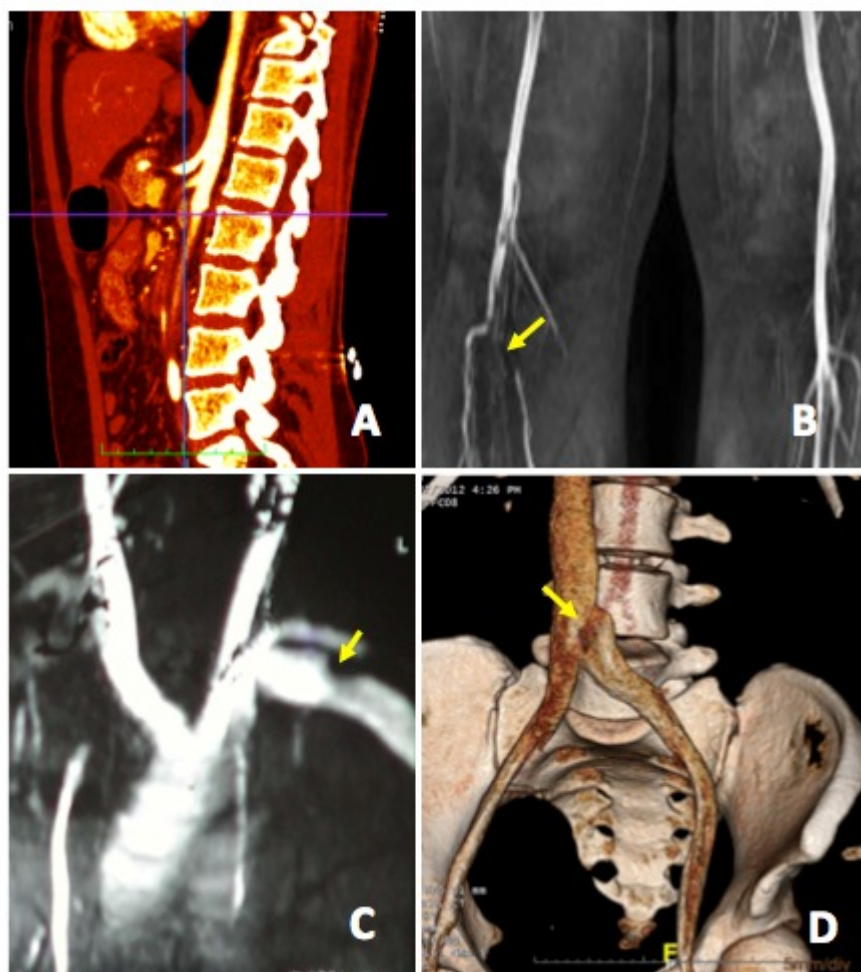


Figure 1. Diagnostic modalities in patients with venous compression syndrome. A CT angiography (3D MPR) shows the left renal vein, which is compressed in the aorto- mesenteric angle in a patient with nutcracker syndrome (A). A MR venography (MRV) showing stenosis and external compression in the right popliteal vein lumen due to popliteal vein entrapment (B). A MRV showing venous compression of the hypertrophic subclavian muscle (C). A CT angiography (3D VR) shows the pronounced compression on the left common iliac vein of the right common iliac artery in a patient with May- Thurner syndrome (D). Note that the arrows indicate venous compression sites (B, C, D).

Table I. Venous compression syndromes: Demographic data

Venous syndrome	Male		Female		Total (%)
	n (%)	Age * (year)	n (%)	Age * (year)	
May-Thurner syndrome	10 (20.4)	37 (13-63)	39 (79.6)	32 (14-60)	49 (44.6)
Nutcracker syndrome [†]	5 (11.9)	28 (14-44)	37 (88.1)	32 (12-54)	42 (38.2)
Paget-Schrötter syndrome ^{**}	11 (61.1)	25 (20-69)	6 (38.9)	38 (17-50)	17 (15.4)
McCleery syndrome	0	0	1	22	1 (0.9)
Popliteal vein entrapment syndrome	0	0	1	34	1 (0.9)
Total	26 (23.8)	33.6 (13-69)	84 (76.2)	34 (12-60)	110

*Median/mean, age (range); [†]The rate of adolescent with nutcracker syndrome was 23.8%; ^{**}Secondary subclavian-axillary vein thrombosis, which is usually secondary to central venous catheters, but can also be seen in patients with nephrotic syndrome, mediastinal tumor, malignant disease, local surgery or trauma and hypercoagulable, not included in this study.

ID: 509

Topic: Cardiovascular Surgery » Various Veins

Presentation Type: Oral

HEMODIALYSIS TUNNELED CATHETER NONINFECTIOUS COMPLICATIONS

Çağatay Bilen, Gökmen Akkaya

Ege University, Izmir, Turkey

**Corresponding Author (cagataybilen86@gmail.com)*

cagataybilen86@gmail.com, akkayagokmen@gmail.com

Abstract Text

Background

The aim of our study was to determine the noninflammatory complications after the insertion of a tunneled hemodialysis catheter due to chronic renal failure.

Methods

56 patients with hemodialysis catheter inserted in two separate centers in 2017 due to chronic renal failure were included in our study. hemogram levels, liver function tests and kidney function tests of all patients were determined before the procedure. After the procedure all the patients were evaluated with the posteroanterior chest radiogram. Venous doppler examination was performed on all patients at the 10th day after discharge.

Result

25 of the patients were female. tunneled hemodialysis catheter was inserted to 36 patients with the jugular vein access, to 16 patients with the subclavian access and to 4 patients with the femoral vein access. Vena cava superior thrombosis was detected in 2 patients at the jugular vein group and 2 patients at subclavian group. Due to thrombosis the catheter was removed and a new catheter was inserted with a new vascular approach. A catheter with the use of subclavian vein approach was directed to the jugular vein. The catheter was redirected to vena cava superior with radiological procedure.

Conclusion

Although tunneled hemodialysis catheter insertion is a simple procedure, it may cause some complications. Therefore, patients should be examined carefully after the procedure.

ID: 271

Topic: **Cardiovascular Surgery » Various Veins**Presentation Type: **Oral****YELLOW NAILS IN LYMPHEDEMA: THE VISIBLE PART OF THE ICEBERG****Rukiye Derin Atabey, Yigit Akcali***Erciyes University, Kayseri, Turkey***Corresponding Author (rukiyeatabey@hotmail.com)**rukiyeatabey@hotmail.com, yigitakcali@gmail.com***Abstract Text**

OBJECTIVE. Yellow nail syndrome (YNS), which is a very rare clinical entity, is usually diagnosed with a combination of yellow dystrophic nail, lymphedema (80%) and chronic recurrent respiratory diseases (36%). Although there are comments about dysfunctional hypoplastic lymphatics, the etiology is not known. Most cases occur sporadically, but few cases are associated with systemic diseases or may be hereditary. Because of the lack of definitive treatments for STS, the morbidity of the disease is high and its treatment is primarily supportive and palliative. We presented the diagnosis and treatment of STS patients among our lymphedema patients.

METHODS. The medical records of 639 lymphedema patients (female / male = 2.5 / 1) together with truncular lymphatic malformations in the last fifteen years, with a median age of 46 years (age range, 1 month-85 years) were examined.

RESULTS. There were two patients with STS who were 14 and 17 years of age. Among the patients with lymphedema, the rate of STS was 0.3%. The application period of the patients was 11 years (incidence, 1/11 years). In both patients, yellow dystrophic nails were bilaterally in both lower and upper extremities (Fig. 1A, B). The lower extremity lymphedema was documented with lymphoscintigraphy and MR lymphangiography in one patient in the right and the other in the left leg (Figure 1C). A CT scan demonstrated a retention cyst in her maxillary sinus, although one of them had no respiratory tract symptoms (Fig. 1D). Patients are followed-up with conservative treatment including vitamin E, antibiotic and compression stockings.

CONCLUSIONS. The emergence of each new YNS among our lymphedema patients was over a decade. According to our knowledge, in most of the patients in the literature whose number did not exceed 160, STS was reported in early middle age, however, our patients were in the childhood age group; and also one of them is the first young case of yellow nail syndrome associated with an asymptomatic sinus retention cyst. Although it is reasonable to recommend conservative treatment before pursuing more aggressive therapeutic modalities, extensive studies are needed to determine the true effectiveness of all treatment options.

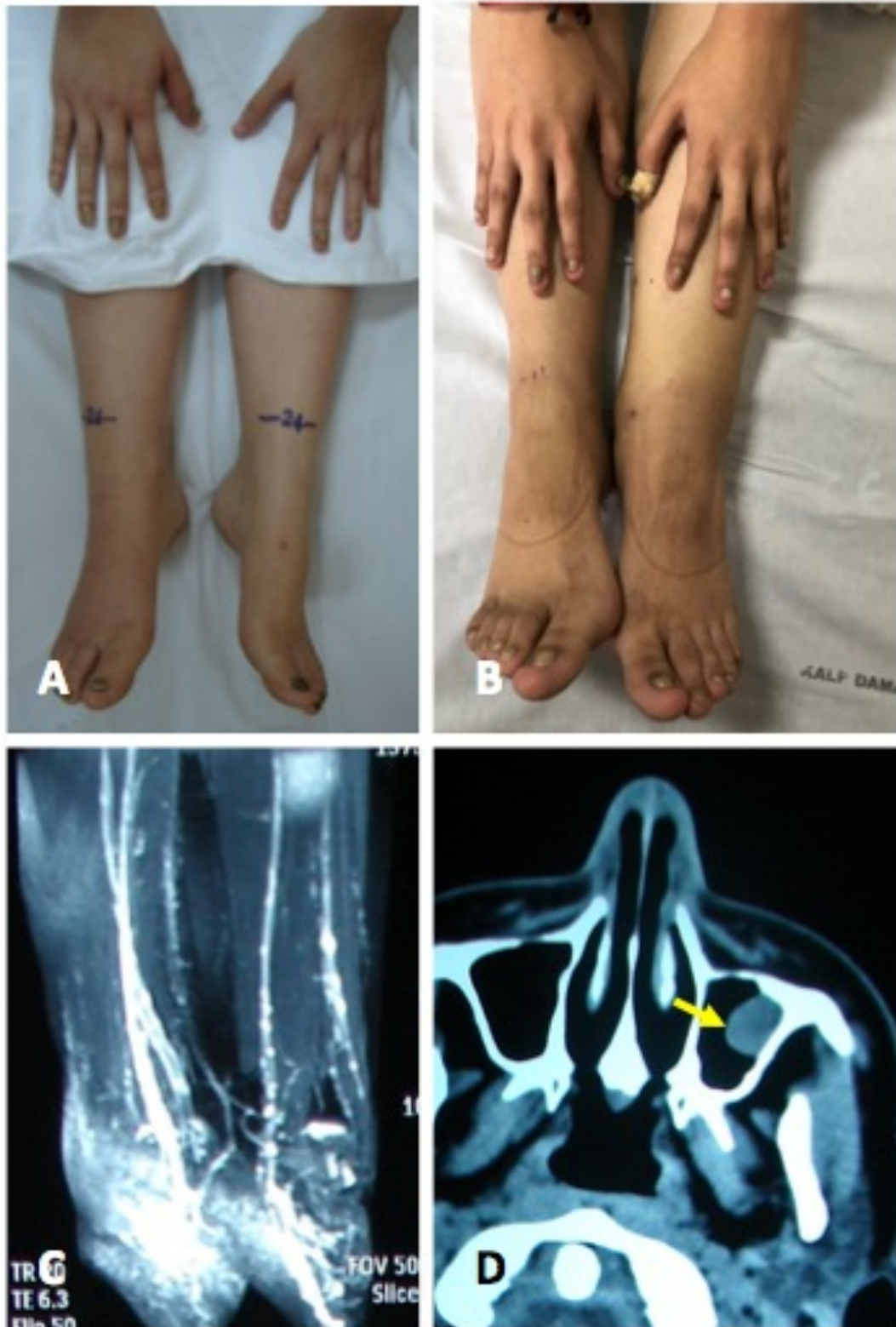

Figure 1. Note the non-onychomycotic yellow, dystrophic changes in both hands and toenails of girls aged 17 and 14 who presented with right (A) and left (B) lymphedema on the lower extremities. MR lymphangiography demonstrates lymphatic duct dilatations in the right lateral ankle (C). Computed tomography showed retention cyst in the maxillary sinus (arrow) despite the normal appearance of the pulmonary parenchymal areas (D).

ID: 546

Topic: **Cardiovascular Surgery » Various Veins**Presentation Type: **Oral****FROSTBITE, AND HYPOTHERMIA****Ali Kagan Coskun, Celalettin Günay***UHS, Gulhane Faculty of Medicine, Ankara, Turkey***Corresponding Author (kagancoskun@gmail.com)**kagancoskun@gmail.com, celalettin.gunay@sbu.edu.tr***Abstract Text**

The frostbite, and hypothermia are commonly occurs at training or field operations causing to loss of manpower related with cold-weather-injuries. The oldest case was found as a mummy with an age of 5000 at Chile mountains. Direct cold injury at cells, deformation at the structure of proteins and lipids with shift at electrocytes, extracellular ice crystal formation with intracellular dehydration at indirect cell injury, microvascular stasis, formation of embolus, ischemia with reperfusion injury could be seen at pathophysiology of frostbite. Windy, cold temperatures, wetness and weather forecasting can be indicative of changing weather conditions and be prepared for this type of air. The management of frostbite and hypothermia are the important points. The management varies from ensure warm, dry clothes and move to a protected environment with proper education, preparation, are the critical points for the protection up to the hospital event. As a medical view, formation of a team including vascular, general surgery, orthopaedic, plastic surgeon or interventional radiologist are the critical point for limb-saving interventions and in some cases this team is inevitable for life-saving procedures. Whether a medical specialist may have the skill and knowledge to manage potentially limb-saving intervention but available treatment options could be sometimes overlooked not to be faced more.

Oral Presentation Session
Innovative Approaches for Venous Problems

Date: 27.03.2019 Time: 17:15 - 18:15 Hall: 4

ID: 397

Topic: Cardiovascular Surgery » Various Veins

Presentation Type: Oral

TREATMENT FOR A VENOUS ANEURYSM: A SALVAGE TECHNIQUE OF AVF WITH AN EARLY CANNULATION PROSTHETIC GRAFT

Naim Boran Tumer¹, Atike Tekeli Kunt¹, Orhan Eren Gunertem¹, Seyhan Babaroglu², Ali Baran Budak¹, Onur Karahasanoglu¹, Serdar Gunaydin¹, Kanat Ozisik¹

¹*University of Health Sciences Ankara Numune Education and Research Hospital, Ankara, Turkey*

²*29 Mayıs Devlet Hastanesi, Ankara, Turkey*

**Corresponding Author (naimborantumer@hotmail.com)*

naimborantumer@hotmail.com, atikemd@gmail.com, egunertem@yahoo.com, babaroglus@yahoo.com, drbaranbudak@gmail.com, onurkarahasanoglu@gmail.com, serdarkvc@gmail.com, sozisik2002@gmail.com

Abstract Text

Objectives: A Venous aneurysm (VA) is one of the complications of arteriovenous fistulas (AVF) and may lead to rupture and potentially fatal bleeding. VA formation in AVF is mostly seen in the upper arm. **Methods:** Between January 2018 and December 2018, a total of 12 VA patients underwent surgery to end-to-end anastomosis using a vascular graft. **Results:** Eight of the patients (66%) were males, and the mean age was 43.1 years (range 25-69 years). All of the fistulas were in the upper arm; two were basilic transpositions, and 10 were brachiocephalic AVF. Mean VA diameter was 4,7 cm (range 3-7 cm). All patients cannulated successfully within 24-48 hours from the newly placed AV access. **Conclusions:** The procedure we described in this series is a successful and effective method for the treatment of VA in AVF. Postoperatively, most of the patients discharged early, and the VA site could be used for HD in 24-48 hours.

Key Words: Early cannulation, Vascular Graft, Arteriovenous fistula, Venous aneurysm

ID: 505

Topic: **Cardiovascular Surgery » Various Veins**Presentation Type: **Oral****A COMPARISON OF N-BUTYL CYANOACRILATE AND
RADIOFREQUENCY ABLATION IN THE TREATMENT OF VARICOSE
VEINS: 3-YEAR FOLLOW-UP RESULTS****Erdinç Eroğlu, Mehmet Acipayam, Alptekin Yasım***Kahramanmaraş Sutcu Imam University, Kahramanmaraş, Turkey***Corresponding Author (erdinc046@hotmail.com)**erdinc046@hotmail.com, mehmetacipayam@gmail.com, alpyasim@hotmail.com***Abstract Text**

BACKGROUND: To compare 3-year results for Nbutyl cyanoacrylate (NBCA), radiofrequency ablation (RFA) in the treatment of varicose veins.

METHODS: 456 patients with saphenous vein insufficiency between November, 2014, and June, 2015, were divided into three groups and underwent endovenous ablation. NBCA was applied to the 180 patients in Group 1, RFA to the 160 patients in Group 2. Patients were followed-up for 3 years. The primary endpoint was the rate of occlusion of the saphenous veins, and secondary endpoints were patients' quality of life, peri- and post procedural pain, complications observed and time to return to work.

RESULTS: Occlusion rates in two groups were similar immediately after the procedure and at 1 year, 2 years and 3 years. However, periprocedural pain was significantly lower in the NBCA group. In terms of complications, there was no variation between the groups regarding deep vein thrombosis, bleeding and phlebitis. However, ecchymosis was significantly higher in the RFA than in the Group 1. While no significant variation was determined between the groups in terms of postoperative analgesic consumption, patients' times to return to work differed, the shortest being in the NBCA group. Pre-procedural venous clinical severity scores (VCSS) values were the same in two groups but began falling in the groups after the procedures. However, the greatest decrease was in the NBCA group.

CONCLUSIONS: While there was no difference in terms of occlusion at 3-year follow-up in groups treated with NBCA, RFA and NBCA is superior in terms of patient comfort

ID: 458

Topic: **Cardiovascular Surgery » Various Veins**Presentation Type: **Oral****DOES THE ULTRASOUND GUIDED SYRINGE-FREE METHOD REDUCE THE PROCEDURE TIME DURING SAPHENOUS VEIN CATHETERIZATION?****Erdinç Eroğlu**, Gozen Oksuz, Mehmet Acipayam*Kahramanmaraş Sutcu Imam University, Kahramanmaraş, Turkey***Corresponding Author (erdinc046@hotmail.com)**erdinc046@hotmail.com, gozencoskun@gmail.com, mehmetacipayam@gmail.com***Abstract Text**

Background: Vein catheterization under the guidance of ultrasound is a significant part of the varicose vein treatment methods for VNUS closure, endovenous laser, foam sclerotherapy, and glue ablation. The catheterization by ultrasound allows rapid improvement, better cosmetic results, and higher success rates.

Material Method: This prospective and randomized study is started following the receipt of approval from Sütçü İmam Üniversitesi Ethical Committee and the patients' informed consents. 75 patients (ASA I-III, between 18-60 ages) who received catheterization because of endovenous laser, foam sclerotherapy and glue ablation are included in the study. The patients are separated into two groups following the sealed tender technique. The group who got a catheter placed on saphenous vein by using a syringe on the long axis following an ultrasound guidance, is named Group C (n=398) and the group who got a catheter placed on the saphenous vein following an ultrasound guidance but without using a syringe on the long axis, is named Group SF (n=37). All saphenous catheter placement procedures are realized by the same cardiovascular surgery experienced in ultrasound-guided procedures, and all the procedures are realized by a single person. In conclusion, an ultrasound-guided syringe-free approach can also decrease the duration of saphenous vein catheterization and allows the operator to perform the whole procedure with ultrasound guidance without interruptions. This method can be used as an advantageous and practical method for experienced operators. In conclusion, an ultrasound-guided syringe-free approach can also decrease the duration of saphenous vein catheterization and allows the operator to perform the whole procedure with ultrasound guidance without interruptions. This method can be used as an advantageous and practical method for experienced operators.

Results: When the demographical qualities of the patients are compared, the results are found to be similar in each group. No vein intervention time difference is observed in each group. In the syringe-free method, the catheterization time is determined to be significantly shorter. In the syringe-free method, it is determined that the successful catheterization number is higher at first try, but the difference is not determined to be significant. In each group, no complication is determined during the procedure (for example arterial puncture, hematoma) or after the procedure in relation to the central venous catheter (for example faulty catheter placement, catheter breaking).

Conclusion: An ultrasound-guided syringe-free approach can also decrease the duration of saphenous vein catheterization and allows the operator to perform the whole procedure with ultrasound guidance without interruptions. This method can be used as an advantageous and practical method for experienced operators.

ID: 103

Topic: **Cardiovascular Surgery » Various Veins**Presentation Type: **Oral****THE ROLE OF SCLEROTHERAPY IN THE TREATMENT OF
TELENGIECTASIAS AND RETICULAR VEINS****Emine Şeyma Denli Yalvaç***Medeniyet University, Istanbul, Turkey***Corresponding Author (drseymadenli@yahoo.com)**drseymadenli@yahoo.com***Abstract Text**

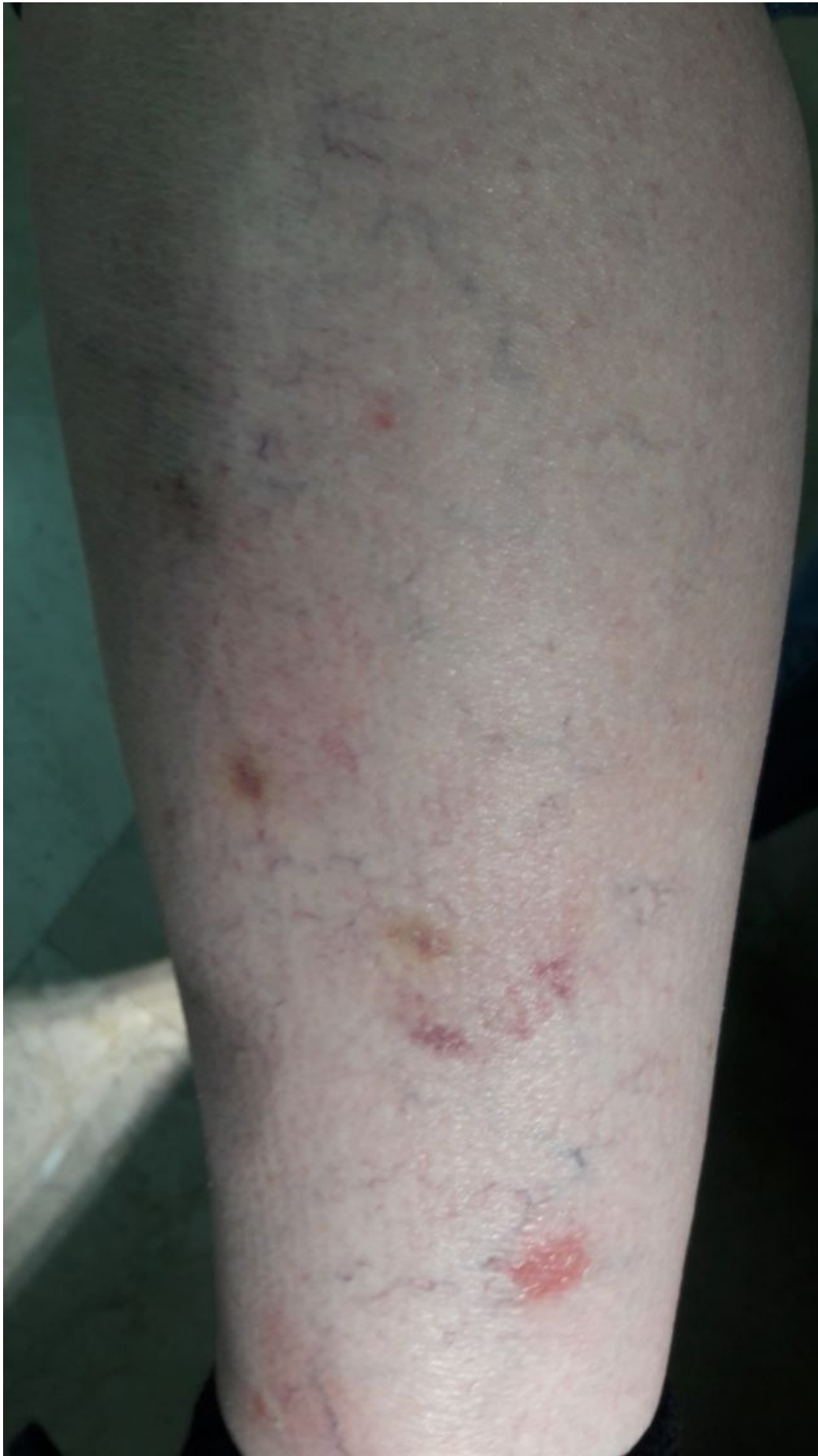ABSTRACT Venous insufficiency may be because of increased pressure and insufficiency of valvula or smooth muscle degeneration at vein wall. If it is not treated for a long time, many complications can develop altering from cosmetic changes to ulceration. Venous disorders may appear in many forms from simple cosmetic disorder as telangiectasia, painful varicose veins to skin ulcerations caused by serious venous insufficiency. The aim of the study is to define sclerotherapy efficiency and complications in small size diametered (≤ 3 mm) varicose veins.

Materials and Methods: 213 patients (210 female, 3 male) suffering from varices who were thereated by sclerotherapy between december 2015 and december 2018 were involved in our study. Sclerotherapy is applied to the varicose veins in size of 0.1-1 mm (telangiectasies) and 1-3 mm (reticular veins). Polidokanol (0,5%) were administered to all patients as a sclerozing agent. Compression therapy applied by elastic bandages for 48 hours after the procedure.

Results: In sixteen patients (7.51%) mild brown discoloration and blush next to the injected vein were observed as complications. We did not encountered any deep venous thrombosis, tromboflebitis, ulcer or anafaktoid reaction. The patient satisfaction was seen in 197 patients (92.48%).

Conclusion: We concluded that sclerotherapy is an easy method, inexpensive, with low complication rate and does not necessitates hospitalization. Especially good reasults in patients applying for cosmetic reasons make it a favourable method. In addition, sclerotherapy is effective in relieving leg pain and discomfort.

Key words: Telangiectasia, Reticular Veins, Sclerotherapy.



ID: 242

Topic: **Cardiovascular Surgery » Various Veins**Presentation Type: **Oral**

COMPARISON OF LONG TERM DOPPLER ULTRASONOGRAPHY RESULTS OF ENDOVENOUS LASER ABLATION AND RADIOFREQUENCY ABLATION PATIENTS

Hakan Bahadır*BETATOM GÖRÜNTÜLEME MERKEZİ, İSTANBUL, Turkey***Corresponding Author (aycankavala@gmail.com)**aycankavala@gmail.com***Abstract Text**

Comparison of Long Term Doppler Ultrasonography Results of Endovenous Laser Ablation and Radiofrequency Ablation Patients

ABSTRACT**Introduction-Objective:**

The development of minimally invasive procedures in varicose vein surgery significantly reduced the time to return to normal life after standard surgical technique and increased patient comfort. Nowadays, two main thermal endovenous treatment methods are applied: endovenous laser ablation (EVLA) and radiofrequency ablation (RFA). Many of the randomized clinical trials have shown that EVLA and RFA are as effective as surgery, and that postoperative patient return to normal life is shorter than standard surgery. Our aim in this study; To compare the long-term (2-year) venous doppler results of 1470 nm wavelength EVLA and RFA.

Method:

The study included 75 patients with endovenous laser ablation between August 2014 and October 2016, and 73 patients with radiofrequency and venous ablation between August 2014 and October 2016. 31 patients female (%41.3) 44 patients male (%58.7) who underwent EVLA, 29 patients female (%39.7) 44 patients male (%60.3) who underwent RFA. The mean age of patients treated with EVLA was 50 ± 15 years, The mean age of RF patients was 49 ± 12 years. RFA and EVLA group were compared with the results of Doppler ultrasonography after 2 years. All of the patients included in the study with Doppler controls were only great saphenous vein (GSV) deficiency and endvenous ablation was applied to GSV

Results:

Two years later, compared to Doppler USG results, EVLA (Group 1) revealed complete closure in GSV in 57 patients (76%), while partial recanalization was detected in 8 patients (10.6%), and full patency was detected in 10 patients (13.4%). While complete closure was detected in 63 patients (86.3%) who underwent radiofrequency, in 8 patients (10.9%) partial recanalization and in 2 patients (2.8%) complete patency was detected.

Conclusion:

When we compare the results of EVLA (1st group) and RF (2nd group) methods, it is noteworthy that the closure rate of great saphenous vein is higher in patients with RF. In addition, we think that high joule heat transfer in EVLA method increases the microtraumas minorcomplaints. According to these results and 2-year long-term doppler USG results, the closure rate of RF ablation is better than EVLA.

Oral Presentation Session**Surgical Solutions for Peripheral Venous Diseases**

Date: 27.03.2019 Time: 11:45 - 12:45 Hall: 5

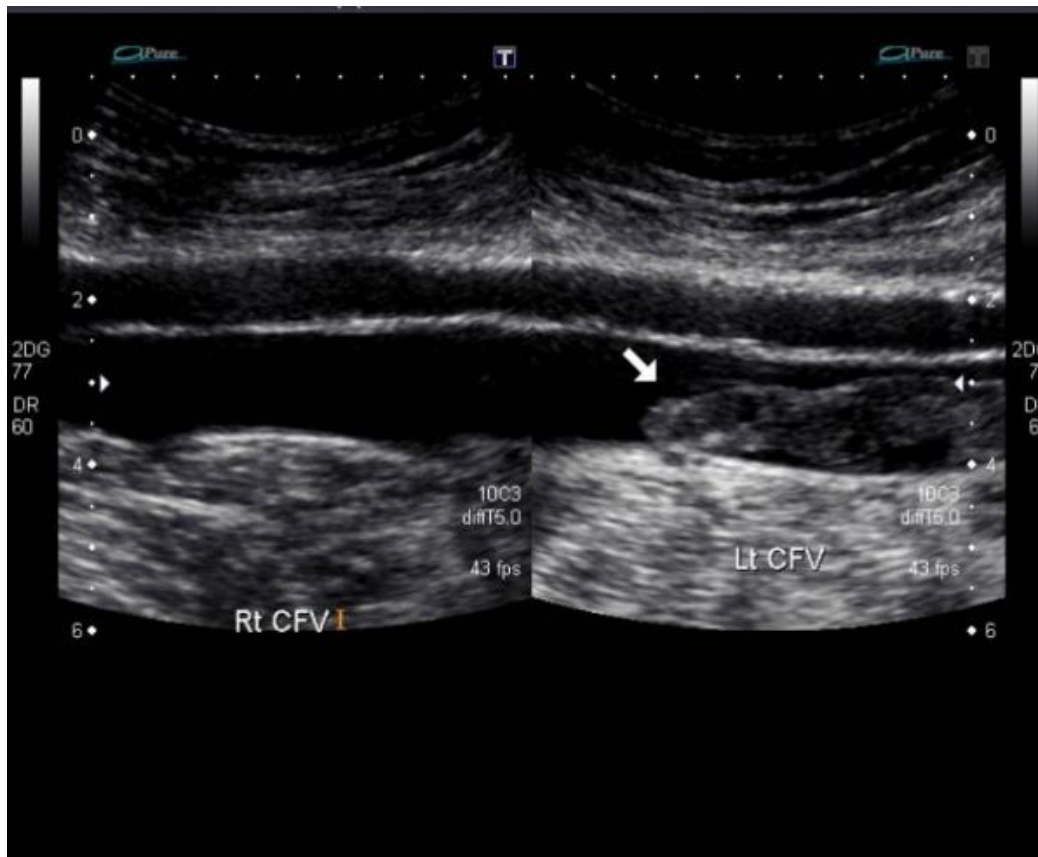
ID: 537

Topic: **Cardiovascular Surgery » Various Veins**Presentation Type: **Oral****EFFECTIVENESS OF RIVAROXABAN AFTER CATHETER-DIRECTED THROMBOLYSIS IN ACUTE DEEP VENOUS THROMBOSIS****Mustafa Bilge Erdoğan¹, Özerdem Özçalışkan²**¹*Bahcesehir University School of Medicine, Istanbul, Turkey*²*Medical Park Tarsus Hospital, Mersin, Turkey***Corresponding Author (mubier@gmail.com)**mubier@gmail.com, ozerdemo@yahoo.com***Abstract Text****BACKGROUND:**

Deep venous thrombosis (DVT) occurs in approximately one in 1000 adults every year, and has an annual mortality of 14.6%. In particular, iliofemoral DVT can lead to recurrent thrombosis and post-thrombotic syndrome, a painful condition which can lead to chronic venous insufficiency, oedema, and ulceration. Early thrombus removal techniques have been advocated in patients with an iliofemoral DVT in order to improve vein patency, prevent valvular dysfunction, and reduce future complications, such as post-thrombotic syndrome and venous ulceration. One such technique is catheter-directed thrombolysis. Our aim was to summarize our results using this method.

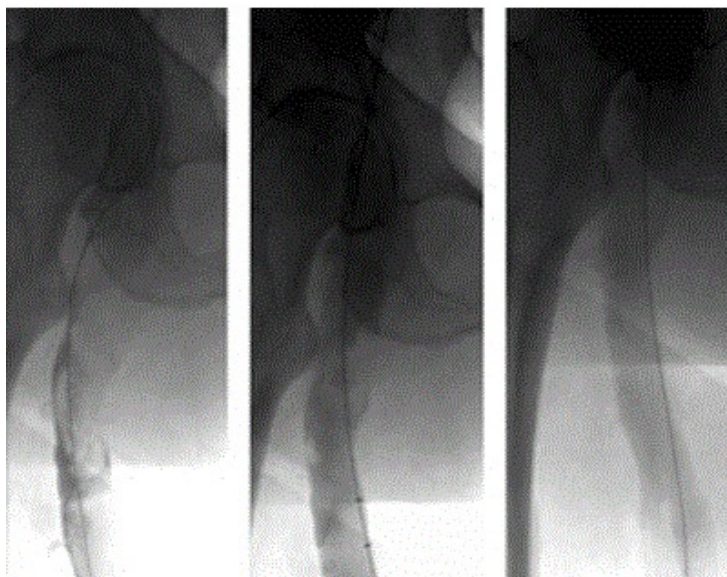
METHODS:

A retrospective analysis was conducted in 192 patients (116 women, 76 men, age range 16-84 years, mean 64 years) who had acute iliofemoral thrombosis (≤ 10 days) and were treated by catheter-directed thrombolysis between June 2014 and August 2017. All patients presented with acute DVT with a median duration of 4.1 days and were treated with catheter-directed thrombolysis (tPA: initial dose of 5-20 mg during intervention followed by 20-30 mg in 5 hours). Temporary filters were implanted in all patients and taken back 24 hours later. Rivaroxaban was initiated (2x15 mg 1st month, 1x20 mg until 6th month.) in postoperative 1st day. A Duplex ultrasound was used to perform follow-up examinations at 1 month, 6 months, 1 year, and 2 years after the operation.



RESULTS:

Three patients had pulmonary emboli before catheter-directed thrombolysis as assessed by the computed tomography angiography. Overall, the 1-month, 6-month, 1-year, 2-year, primary patency rates were 96.7%, 95.1%, 91.8%, 90.2%, respectively. The reductions of thigh and calf circumferences were 66.7% (6.19 ± 2.67 vs. 1.98 ± 1.43 cm) and 61.6% (4.36 ± 2.10 vs. 1.46 ± 1.10 cm), respectively. Reocclusion occurred in 4 patients within 1-17 months. Nine patients experienced minor bleeding. There was no major bleeding in any patients. Five patients died from nonvascular causes during follow-up. The incidence rate of postthrombotic syndrome was 9.8% (19/192).



CONCLUSIONS:

Treatment with catheter-directed thrombolysis for acute DVT achieves good patency and vein function after 2 years of follow-up in our study. Using Rivaroxaban in follow-up period is more safe and comfortable than warfarin for these patients. However, further evidence is required to establish longer term benefits.

ID: 529

Topic: **Cardiovascular Surgery » Various Veins**Presentation Type: **Oral****A NOVEL MODIFIED TECHNIQUE WITH A COMBINATION OF PERCUTANEOUS EMBOLIZATION WITH N-BUTYL CYANOACRYLATE AND HIGH LIGATION OF SAPHENOUS VEIN: A PRELIMINARY REPORT****Erhan Renan Uçaroğlu¹, Ufuk Turan Kürşat Korkmaz², Ahmet Yüksel², Yusuf Velioglu², Osman Ünal², Kemalettin Erdem²**¹*Abant İzzet Baysal University Faculty of Medicine, Bolu, Turkey*²*Abant İzzet Baysal University Faculty of Medicine, Bolu, Turkey***Corresponding Author (erhanrenanu@gmail.com)**erhanrenanu@gmail.com, dr.utkk@hotmail.com, ahmetyuksel1982@mynet.com, yusufvelioglu@gmail.com, dr.osmanunal@gmail.com, kemalettincvs@yahoo.com***Abstract Text**

Background: Nowadays, there are various therapeutic modalities for the treatment of chronic venous insufficiency (CVI). Surgical treatment methods like saphenous vein (SV) stripping and high ligation have remained leading therapeutic options for long years, and is still being remained as a considerable option. On the other hand, endovenous treatment methods (both thermal and non-thermal modalities) have gained increasing popularity in the treatment of CVI worldwide due to their less invasive nature. Among these endovenous methods, percutaneous embolization of SV with n-butyl cyanoacrylate (NBCA) that is relatively new, non-thermal and non-tumescent, has recently become one of the most preferred and safest methods since it has great early and mid-term outcomes, but long-term outcomes have not been widely studied; thus, there still exist some concerns about its long-term recurrence risk. We have developed a novel modified technique with a combination of percutaneous embolization with NBCA and high ligation of SV. The aim of this study was to present a preliminary report of this aforementioned modified technique for the treatment of CVI.

Methods: Between October 2018-December 2018, 15 patients were treated with a novel modified hybrid technique involving Venablock embolization system (Invamed RD, Ankara, Turkey) and surgical high ligation of great SV. Preprocedural, intraoperative, postoperative, and early-term follow-up data of patients were recorded and retrospectively analyzed. All these hybrid procedures were performed under local anaesthesia in the operating room. Firstly, through an approximately 2-3 cm groin incision, high ligation of great SV involving ligations of all lateral branches of SV at the saphenofemoral junction level was performed. Then, through a percutaneous puncture of great SV at medial knee level with ultrasound-guidance, NBCA embolization of great SV was performed. All patients were uneventfully discharged 2-3 hours after the procedure, and re-evaluated by physical examination and duplex ultrasound in control visit 10-14 days after the procedure.

Results: Mean age of patients was 41.8±8.4 years (range: 28-53), and 8 (53.3%) of them were male. According to CEAP classification, the majority of patients (12/15) were in C3 class preoperatively. Technical success rate of the procedure was 100%. Mean procedure time was 48±11.3 minutes (range: 25-65). No serious adverse event related to procedure was occurred. Mean Venous Clinical Severity Score was significantly improved from 8.8±1.3 at preprocedural period to 2.8±0.7 at control visit. Complete occlusion of great SV was present in all patients.

Conclusion: We believe that this novel modified hybrid technique is effective and safer in the treatment of CVI.

ID: 70

Topic: **Cardiovascular Surgery » Various Veins**Presentation Type: **Oral****INVESTIGATION OF ALBUMIN LEVELS IN VENOUS THROMBOSIS****Murat Karabiga**, Tenzile Karabiga*Alanya Eğitim Araştırma Hastanesi, Alanya/Antalya, Turkey***Corresponding Author (muratkarabiga@hotmail.com)**muratkarabiga@hotmail.com, tenzileilikan@gmail.com***Abstract Text**

Objective: Mortality is related with thrombosis burden in deep venous thrombosis (DVT). Therefore, determining of thrombosis burden at important DVT patients. The relation between albumin levels and thrombosis burden was investigated in this study.

Method: Venous involvement of 30 DVT patients were detected with doppler ultrasonography. Routine blood tests were investigated in these patients and relation with venous involvement detected.

Findings: Mean age was detected as 44.3±11.7 years and 46% of the patients were male. Blood parameters (neutrophil, lymphocyte, MPV, WBC, platelet count, D-Dimer, fibrinogen) were found as similar between groups ($p>0.05$). However, serum albumin levels (3.11±0.58) were lower in iliac DVT group when compared with popliteal DVT (3.77±0.43) group ($p<0.05$). Furthermore, albumin levels were found as highly sensitive and mildly specific for prediction of severe DVT.

Conclusion: Lower albumin levels were seems to be highly related with widespread DVT. These findings should be supported with large cohorts.

ID: 163

Topic: **Cardiovascular Surgery » Various Veins**Presentation Type: **Oral****COMPARISON OXIDATIVE STATUS QUO OF FAMILIAL DEEP VENOUS THROMBOSIS WITH HEALTHY POPULATION****Fevzi Sarper Türker¹**, Ayşe Doğan²*¹Elazığ Fethi Sekin Town Hospital, Elazığ, Turkey**²Bitlis Eren University, Bitlis, Turkey***Corresponding Author (sarperturker@gmail.com)**sarperturker@gmail.com, aysedogan2003@yahoo.com*

Abstract Text

Objective: The aim of our study was to investigate the oxidative damage and some antioxidant parameters in a family found to have familial deep vein thrombosis, and to determine their differences with normal individuals.

Methods: Our study included 4 family members (1 father and 3 daughters) and 100 healthy volunteers. The father is 78 years old and was diagnosed with deep vein thrombosis involving the common femoral vein of the right leg and its distal and apixaban treatment was initiated. The first daughter is 58 years old and was diagnosed with deep vein thrombosis at the right femoral vein and its distal after the first and only delivery 27 years ago, and has been still receiving acetyl salicylic acid treatment. The second daughter is 46 years old and was diagnosed with deep vein thrombosis after the first and only delivery 9 years ago, and has been still receiving warfarin therapy. The third daughter is 40 years old, single and has not given any birth. Her physical examination and venous doppler USG results are normal. The genetic tests of the father and the second daughter showed homozygous factor V Leiden mutation. Malondialdehyde (MDA), a product of lipid peroxidation, reduced glutathione (GSH), glutathione peroxidase (GPx), catalase (CAT) and superoxide dismutase (SOD) antioxidant parameters, which are the markers of oxidative damage, were studied on blood samples taken. The Mann Whitney-U test was used for the comparisons between DVT patients and healthy subjects.

Results: There was a statistically significant increase in the GPx, CAT and SOD antioxidant enzyme activities of the patients than that of healthy subjects ($P < 0.05$) (Table 1), whereas, there was an increase in the MDA levels of the patient group than that of healthy individuals ($P = 0.05$); however, the P value was not considered to be significant since it was equal to 0.05 (Table 1).

Conclusion: In various studies, oxidative stress has been found to be effective in venous thrombosis. In our study, increased GPx, CAT and SOD antioxidant enzyme activities in the patients suppressed the increase in MDA, a marker of oxidative damage, which tended to increase in the patients and would almost gain statistical significance. In further studies, there is a need to determine the diagnostic and prognostic values of oxidative stress in DVT disease. We are of the opinion that these parameters to be studied in the clinic will be more rapid and more economic in diagnosing DVT disease.

Table 1. Comparison of DVT patients father and three daughters with healthy population about oxidative damage and antioxidant parameters.

Mean±Std. Deviation

Parameters	N	P	
MDA nmol/ml	102	1.20±0.45	P>0.05 P=0.05
GSH μmol/ml	101	0.92±0.26	P>0.05 P=0.201
GPx U/gr Hb	99	6.81±5.84	P<0.05 P=0.03
CAT U/g Hb	98	214.66±56.32	P<0.05 P=0.03
SOD U/g Hb	102	32.97±5.49	P<0.05 P=0.04

ID: 510

Topic: **Cardiovascular Surgery » Various Veins**Presentation Type: **Oral****MOST COMMON DRUGS AND DRUG INTERACTIONS IN THE MODERN
TREATMENT OF VARICOSE VEINS****Inci Selin Dogan¹, Emre Dogan²**¹*Karadeniz Technical Uni., Trabzon, Turkey*²*Health Sciences University Ahi Evren Thoracic and Cardiovascular Surgery Education Research
Hospital, Trabzon, Turkey***Corresponding Author (selinci@gmail.com)**selinci@gmail.com, dremredogan@gmail.com***Abstract Text**

OBJECTIVE: Chronic venous diseases are defined with different pathologies and symptoms such as pain, edema, and skin changes at the lower extremity venous system (1). Basic approaches in treatment; binding of veins by surgical procedure, cannulation of veins (surgery), use of compression socks and application of drugs that cause hardening in tissues (1-3). In medical treatment, venoactive drugs are used. Patients may have several diseases at the same time. This raises the risks of interaction with the drug-drug/nutrient/clinical situation. These drugs are classified as venotonic drugs (benzopyrones, saponins, other plant extracts, and synthetic drugs) and horse chestnut extract (2-6). Ideal venoactive drugs should be analgesic, anti-edema effect and should increase venous tone, reduce inflammatory reactions (6). **METHODS:** The most common diseases existing with venous disease are hypertension, hyperlipidemia and diabetes. ACE inhibitors, statins and antidiabetic drugs are commonly used in these diseases. The aim of this study was to investigate the most commonly used drugs "calcium dobesilate, diosmin-hesperidine, oxerutin, aescin" in the treatment of varicose veins and the drug interactions of them (2-6).

CONCLUSIONS: Drug interactions affect treatment, depending on the consequences. The efficacy of the drug may be decreased, increased, or side effects may occur. So this is an important problem for all clinicians. **Keywords:** Chronic Venous Diseases, Venoactive Drugs, Drug interactions.

References:

1. Cronenwett, J.L., Johnston, K.W. Rutherford's Vascular Surgery. 7th Edition. 2010.
2. Akgün Hülya vd., Farmasötik Kimya 2, Hacettepe Üniversitesi Yayınları, Ankara 2016, 869.
3. Wittens, C., Davies, AH, Baekgaard, N., Broholm, R, Cavezzi, A, Chastanet S. et al. Editor's choice-Management of Chronic Venous Disease: Clinical Practice guidelines of the European Society for vascular Surgery (ESVS). Eur. J.Vasc.Endovasc.Surg 2015; 49: 678-737.
4. Albert-Adrien Ramelet, Venoactive Drugs, <https://clinicalgate.com/venoactive-drugs/#t0010>, erişim: 21.11.2018
5. Akçalı, Y., Venoaktif ilaçlar güncel endikasyonlar, <https://www.slideshare.net/uvcd/venoaktif-ilacilar-guncel-endikasyonlar>, erişim: 21.07.2017.
6. Katrancıoğlu, A. Kronik venöz yetmezlik ve venöz ülserlerde medikal tedavi, http://www.anadoluissagligi.com/img/file_1504.pdf, erişim: 21.07.2017.

ID: 440

Topic: **Cardiovascular Surgery » Various Veins**Presentation Type: **Oral****THE EVALUATION OF CHRONIC VENOUS DISEASE IN HEALTH WORKERS BY THE CIVIQ-20 QUESTIONNAIRE****Rukiye Derin Atabey, Yigit Akçalı***Erciyes University, Kayseri, Turkey***Corresponding Author (rukiyeatabey@hotmail.com)**rukiyeatabey@hotmail.com, yigitakcali@gmail.com***Abstract Text**

OBJECTIVE. Chronic venous disease(CVD) with primary or secondary causes is a common, serious but often unimportant clinical process of failure.The Chronic Venous Insufficiency Quality of Life Questionnaire (CIVIQ-20) was evaluated to draw attention to this insignificant clinical process and assess quality of life in patients with CVD.The questionnaire was used to analyze the CVD and determine the related factors.

METHODS. The median age of the Erciyes University Medical Faculty hospital with symptoms of CVD was 32 (29-37); A questionnaire was applied to 207 subjects (medical secretary = 69, nurse = 69, doctor = 69) consisting of 86 men and 121 women.1 individuals with CVD symptoms were interviewed face to face with employees. In the G-power 3.1.9.2 program, effect was taken as 0.25, with a 90% confidence rate, 69 people from each group were employed.

RESULTS. When the relationship between age and Global Index Score (GIS) was evaluated in the study group, there was a negative correlation between age and GIS score ($p = 0.033$ $r = - 194$), whereas there was no statistically significant correlation between men and women ($p = 0,364$, $r = 0,99$). While there was no difference between the scores of the secretaries and nurses in the comparison of the occupational groups according to CIVIQ-20 scores, it was found that the doctors had a significantly lower venous insufficiency score compared to these two occupations ($p = 0.001$).

CONCLUSIONS. Health workers are at risk for CVD due to both stressful work environment and intensive work pace.In particular, doctors have a higher risk of CVD than other occupational groups.Therefore, according to the results obtained, the working conditions of health workers should be regulated.More clinical studies are needed for Turkish patients use of the CIVIQ-20 questionnaire, which is widely used abroad.

Oral Presentation Session**Revisiting Concepts in Hypertension Management**

Date: 27.03.2019 Time: 13:00 - 14:00 Hall: 5

ID: 138**Topic: Cardiology » Hypertension and Antihypertensive Therapy****Presentation Type: Oral****THE EFFECT OF BLOOD PRESSURE VARIABILITY ON HYPERTENSIVE PATIENTS' PROGNOSIS****Abdulhalim Kinsara¹**, Mohammed Tashkandi², Marwan Balubaid², Waleed Khayyat², Ziad Taher²¹*King Saud bin Abdulaziz University for Health Sciences, COM-J. King Abdul Aziz Medical City-WR King Faisal Cardiac Centre , Jeddah, Saudi Arabia*²*King Saud bin Abdulaziz University for Health Sciences, COM-J., Jeddah, Saudi Arabia***Corresponding Author (akinsara@yahoo.com)**akinsara@yahoo.com, moyata.1416@gmail.com, korabica96@gmail.com, waleed-khyyat@hotmail.com, ziadaot@gmail.com***Abstract Text**

Objective: To compare the effects of high blood pressure variability (BPV) during ambulatory blood pressure monitoring (ABPM) and visit-to-visit measurements on the development of complications in hypertensive patients.

Method: A retrospective cohort study was conducted at a general public hospital. All adult patients (>18 years old) with at least one recorded ABPM report, and at least three recorded BP measurements were included. Excluded patients were those who had less than 3 years follow-up

Results: There were a total of 305 cases with recorded 24 ABPM. 152 were included. Overall, 21.7% developed one or more complications. The mean age was 53.5 ±14.3, 54.6% were male. Comorbidities included; DM 53.9%, dyslipidemia 39.5%, obesity 16.4%, and smoking 8.6%. Mean follow-up was 6.6 ±2.3 years. Generally, 28.3% had a history of a complication before the diagnosis, including: stroke 2%, ACS 8.6%, ischemic heart disease 20.4%, HF 2.6%, and renal failure 1.3%. SD of total systolic measurements was significantly correlated with IHD (RR, 1.9; 95% CI, 2.225-1.575; P-value < 0.04).

Conclusion: The fluctuation of BP measured by ABPM is linked with developing HTN complications more than the fluctuation of BP measured in visit-to-visit.

ID: 152

Topic: **Cardiology » Hypertension and Antihypertensive Therapy**Presentation Type: **Oral****CAN OCULAR OPTICAL COHERENCE TOMOGRAPHY FINDINGS BE AS A PREDICTOR FOR END ORGAN DAMAGE IN SYSTEMIC HYPERTENSION?****Batur Gönenç Kanar***Marmara University, İstanbul, Turkey***Corresponding Author (baturkanar@hotmail.com)**baturkanar@hotmail.com***Abstract Text**

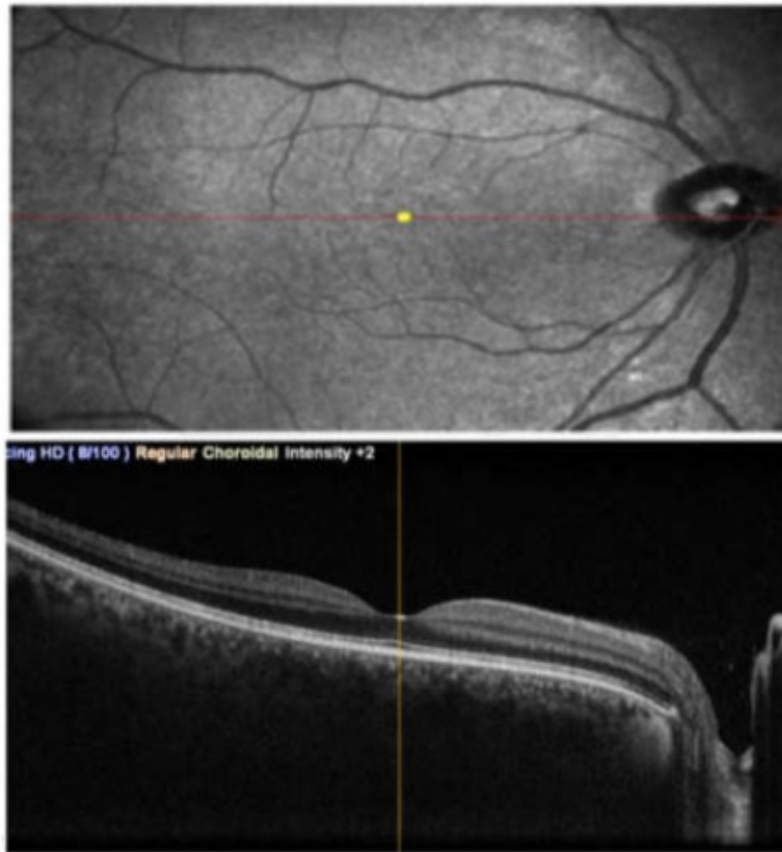
Purpose: We aimed to evaluate subfoveal choroidal thickness (SFCT) and retinal layers thicknesses with spectral domain optical coherence tomography (SD-OCT) and to show the effect of end organ damage (EOD) on spectral domain- optical coherence tomography (OCT) measurements in patient with systemic hypertension (SHT).

Material and Methods: A total of 282 patients with SHT which have any stages of hypertensive retinopathy (HTRP), and 97 healthy controls were included. HTRP classification was made by using Keith Wagener Berker classification system. Patients were also subjected standard transthoracic echocardiography (STTE) and 24 hour urine analyzes. Patients were divided into 3 groups according to presence of HTRP, left ventricular hypertrophy (LVH) and/or microalbuminuria (MA). Group 1 comprised of 97 patients without EOD (HTRP, LVH or MA), group 2 comprised of 94 patients with HTRP without LVH or MA and group 3 comprised 91 patients with HTRP and LVH or MA. SFCT, inner plexiform-ganglion cell complex (IPGCC), retinal nerve fiber layer (RNFL) and central macular thickness (CMT) were compared between the control and SHT patients groups.

Results: Complete data was collected for 280 patients with documented SHT and 100 healthy controls. The mean age was $64,9 \pm 11,6$ years for patients with SHT and $68,1 \pm 11,3$ years for healthy controls. ($P=0,25$). There was significant difference in SD-OCT parameters between patients and controls ($P<0,001$). However, there were no statistical differences between control and group 1. But in group 2 and 3, IP GCC, RNFL values were significantly lower than group 1 and controls. Also CMT and SFCT were significantly lower in group 2 and group 3.

Conclusion: We indicated that additional EOD increased SD-OCT parameters in patients with SHT. Therefore, HTRP evaluating with funduscopy is not enough to follow-up complicated SHT patients.

Key words: choroidal thickness, inner plexiform-ganglion cell complex thickness spectral domain optic coherence tomography, systemic hypertension



Control group	Group 1	Group 2	Group 3	p^{α}	p^{β}	
Inner plexiform-ganglion cell complex (μm)	85.3 \pm 6.4	83.7 \pm 5.8	79.2 \pm 5.2	68.2 \pm 10,0	<0.001	<0.001 ^{a,b,c}
Retinal nerve fiber layer (μm)	100.2 \pm 8.1	98.6 \pm 7.2	88.4 \pm 6.4	77.3 \pm 8.4	<0.001	<0.001 ^{a,b,c}
Central macular thickness (μm)	254.5 \pm 16.2	250.2 \pm 14.6	245.0 \pm 21.30	230.7 \pm 19.7	<0.001	<0.001 ^{b,c}
Subfoveal choroidal thickness (μm)	293.3 \pm 22.2	290.8 \pm 17.9	287.6 \pm 16.7	273.3 \pm 18.1	<0.001	<0.001 ^{b,c}

P^{α} : values derived from statistical comparison between hypertensive patients and healthy controls.

P^{β} : values derived from statistical comparison between 3 groups. Posthoc analysis are shown with a, b and c;

^a: the statistical difference was originated from Group 1 and Group 2

^b: the statistical difference was originated from Group 1 and Group 3

^c: the statistical difference was originated from Group 2 and Group 3

ID: 366

Topic: **Cardiology » Hypertension and Antihypertensive Therapy**Presentation Type: **Oral****IMPACT OF CARDIAC REHABILITATION ON QUALITY OF LIFE IN PATIENTS WITH HYPERTENSION**Engin Ersin Simsek¹, **Ahmet Anil Sahin**², Batur Kanar², Murat Sunbul², Huseyin Cetin¹, Ilker Yagci², Beste Ozben², Kursat Tigen²¹*University of Health Sciences, Kartal Dr. Lutfi Kirdar Training and Research Hospital, Istanbul, Turkey*²*Marmara University, Istanbul, Turkey***Corresponding Author (aanilsahin@hotmail.com)**aanilsahin@hotmail.com, aanilsahin@hotmail.com, aanilsahin@hotmail.com, aanilsahin@hotmail.com, aanilsahin@hotmail.com, aanilsahin@hotmail.com, aanilsahin@hotmail.com, aanilsahin@hotmail.com***Abstract Text**

Objective: Sedentary lifestyle decreases exercise capacity and cardiac functions and increases morbidity and mortality in hypertensive patients. The aim of this study is to explore the effect of cardiac rehabilitation on blood pressure control and quality of life (QoL) in patients with hypertension.

Methods: Thirty consecutive hypertensive patients (21 female, mean age 55.9 ± 8.1 years) were included into the study. All patients were enrolled in the 30 sessions of phase 3 cardiac rehabilitation program for 10 weeks. The daily blood pressure profiles of the patients were assessed by ambulatory blood pressure (BP) monitoring before and after cardiac rehabilitation. QoL assessment was done using The World Health Organization Quality of Life-BREF (WHOQOL-BREF) questionnaire before and after the rehabilitation.

Results: The ambulatory blood pressure measurements and QoL scores of the patients before and after cardiac rehabilitation program are listed in Table 1. Ten weeks of cardiac rehabilitation program improved significantly all daily systolic and diastolic, day-time systolic and diastolic, night-time systolic and diastolic blood pressures together with significant decreases in daily, day-time and night-time blood pressure loads (Table 1). Similarly, cardiac rehabilitation improved significantly general health, physical health and psychological health status (Table 1).

Conclusion: Cardiac rehabilitation not only significantly improves blood pressure control but also increases the quality of life in hypertensive patients suggesting that cardiac rehabilitation should be recommended in the management of hypertensive patients.

Table 1. The ambulatory blood pressure measurements and QoL scores of the patients before and after cardiac rehabilitation program

	Before Rehabilitation	After Rehabilitation	P
Daily Systolic Pressure (mmHg)	130.3 ± 10.6	125.6 ± 8.9	0.006
Daily Diastolic Pressure (mmHg)	82.0 ± 7.7	78.3 ± 7.1	<0.001
Day-time Systolic Pressure (mmHg)	131.9 ± 11.8	127.6 ± 9.1	0.024
Day-time Diastolic Pressure (mmHg)	83.7 ± 8.2	80.2 ± 6.9	0.002
Night-time Systolic Pressure (mmHg)	126.3 ± 11.9	120.6 ± 10.1	0.005
Night-time Diastolic Pressure (mmHg)	76.7 ± 8.2	73.3 ± 8.2	0.003
Daily Systolic Blood Pressure Load (%)	33.7 ± 23.2	26.1 ± 20.8	<0.001
Daily Diastolic Blood Pressure Load (%)	32.6 ± 21.5	24.9 ± 18.4	<0.001
Day-time Systolic Blood Pressure Load (%)	31.6 ± 24.9	23.9 ± 19.8	<0.001
Day-time Diastolic Blood Pressure Load (%)	31.5 ± 21.9	24.6 ± 18.1	<0.001
Night-time Systolic Blood Pressure Load (%)	47.0 ± 33.6	33.1 ± 30.5	0.004
Night-time Diastolic Blood Pressure Load (%)	38.1 ± 26.7	28.2 ± 24.7	<0.001
General Health (scores)	47.5 ± 16.9	59.6 ± 14.9	<0.001
Physical Health (scores)	48.2 ± 16.8	58.7 ± 13.4	<0.001
Psychological Health (scores)	55.8 ± 14.5	60.1 ± 12.6	<0.001

ID: 437

Topic: **Cardiology » Hypertension and Antihypertensive Therapy**Presentation Type: **Oral****THE RELATIONSHIP BETWEEN NEUTROPHIL TO LYMPHOCYTE RATIO AND PULSE WAVE VELOCITY WITH PRESENCE OF HYPERTENSION AND DIPPING STATUS**Bulent Altunkeser¹, Muhammet Salih Ates², Abdullah Tuncez², **Muhammed Ulvi Yalcin²***¹Selcuk Universty, Konya, Turkey***Corresponding Author (bbaltunkeser@hotmail.com)**bbaltunkeser@hotmail.com, m.salih.ates@gmail.com, drtuncz@gmail.com, ulviyalcin@gmail.com***Abstract Text**

Background: Previous studies has proved that neutrophil/lymphocyte ratio (NLR) to be a useful indicator cardiovascular risk as a inflamatuar marker. Pulse wave velocity (PWV) is a cursor for early atherosclerotic process. It is unknown whether PWV differs in presence of hypertension. Also little research has been performed on the relationship between NLR and PWV in dipper status of hypertension. The purpose of this article was to investigate their relationship.

Methods: A total of 108 patients with hypertension and 131 persons without hypertension were included. The non-dipping status and arterial distensibility were assessed using a Mobil-O-Graph Arteriograph, an automatic oscillometric device. Pulse wave velocity and NLR was eveluated in study population and compared with patients with hypertension and normotensive controls. Also PWV and NLR compared according to dipper status in hypertensive group.

Results: Baseline characteristics were similar between hypertension and normotensive group. PWV were higher in hypertensive group than noromotensive control (7.86 ± 1.72 vs 6.96 ± 1.65 m/s, $p < 0.001$). Also NLR (0.66 ± 0.16 va 0.59 ± 0.10) and PWV (0.816 ± 183 vs. 7.32 ± 149) were increased in nondipper than dipper hypertensive patients.

Conclusion: We found in our study that increased NLR and PWV which are indicators of increased inflammation and atherosclerotic process, are significantly higher in the non-dipper HT patients in comparison to the dipper HT patients and control group.

ID: 563

Topic: **Cardiology » Cardiac Imaging - Echocardiography**Presentation Type: **Oral****ASSESSMENT OF CARDIAC SYNCHRONY AND SEGMENTAL SYSTOLIC AND DIASTOLIC FUNCTIONS BY TISSUE DOPPLER IMAGING IN PATIENTS WITH AORTIC VALVE SCLEROSIS****Selçuk Özkan***Instinye University, İstanbul, Turkey***Corresponding Author (drselcukozkan@gmail.com)**drselcukozkan@gmail.com***Abstract Text**

Objective: Aortic valve sclerosis (AVS) may be associated with increased cardiovascular risk and mortality. In this study, we aimed to evaluate the systolic and diastolic functions of the left ventricle and the status of cardiac synchronization in patients with AVS but no clinical evidence of systolic and diastolic dysfunction by using tissue Doppler imaging (TDI).

Method: Thirty people with AVS and 30 age and sex matched healthy volunteers were enrolled. Global cardiac function was assessed by the measurement of left ventricular ejection fraction, mitral e and a velocities and mitral E/e' ratio. Segmental myocardial systolic (Sm), early diastolic (Em) and late diastolic (Am) peak velocities were measured at one right (lateral) and 5 different left ventricular myocardial segments by using Tissue Doppler Imaging (TDI). Precontraction time (Q-Sm), defined as the time interval between the beginning of the QRS complex on the surface ECG and the beginning of the systolic wave (Sm) on TDI was used to evaluate cardiac synchrony. Intraventricular systolic synchrony was assessed by the difference between Q-Sm intervals acquired at different left ventricular segments. Interventricular activation delay was defined as the difference between the right ventricular lateral wall Q-Sm and the Q-Sm at the latest activated left ventricular myocardial segment

Results: The peak Sm velocity at the lateral left ventricular wall was significantly lower in patients with AVS as compared to controls (7.22±1.47 cm/sec vs 8.13±1.63 cm/sec, p=0.028). The peak early diastolic velocities (Em) at the septum (7.67±42.29 cm/sec vs 8.88±2.01 cm/sec), left ventricular lateral (8.78±1.77 cm/sec vs 9.85±2.34 cm/sec) and posterior walls (8.58±2.47 cm/sec vs 11.29±3.27 cm/sec) were significantly lower in the patient group (p=0.036, p=0.043, p=0.001, respectively). Inter and intraventricular delay were significantly lower in patients with AVS as compared to controls (23.13±17.61 vs 6.43±5.96 msec p<0.001 and 26.8±16.82 msec vs 9.56±4.7 msec: p<0.010 respectively). **Conclusion:** In patients with AVS and normal global cardiac functions TDI may disclose segmental systolic and diastolic dysfunction and impaired cardiac synchrony as compared to controls. The clinical significance of these findings need to be validated by further research.

ID: 571

Topic: Cardiology » Hypertension and Antihypertensive Therapy

Presentation Type: Oral

**INCREASED MASKED HYPERTENSION RATE IN PATIENTS WITH
IMPAIRED GLUCOSE TOLERANCE**

Naim Ata

T.C.Ministry of Health 29 Mayıs Government Hospital , Ankara, Turkey

**Corresponding Author (atanaim@gmail.com)*

atanaim@gmail.com

Abstract Text

Objectives: Masked hypertension is related to a high risk for cardiovascular diseases. The oral glucose tolerance test (OGTT) is used both in clinical practice and research to assess glucose tolerance. The purpose of this study was to assess the relationship between masked hypertension and impaired glucose tolerance (IGT).

Methods: The study group consisted of 67 consecutive outpatient subjects without overt hypertension and diabetes mellitus. After a complete medical history and laboratory examination, patients' height, weight, waist circumference heart rate, and office blood pressure were recorded. All Subjects underwent OGTT and ambulatory blood pressure. Masked hypertension is defined as normal office blood pressure measurement and high ambulatory blood pressure level.

Results: There were 32 patients with IGT and 25 patients with Masked Hypertension. Masked hypertension rate was significantly higher in patients with IGT (19 subjects (59.4%)) than without IGT (6 subjects (17.1%), $P < 0.001$).

Conclusion: This study demonstrated that masked hypertension prevalence was increased in patient with IGT. It can be suggested that predefining IGT might be helpful in early detection of masked hypertension.

ID: 575

Topic: **Cardiology » Chronic Stable Angina Pectoris**Presentation Type: **Oral****BLOOD GROUP A PREDICTS SLOW CORONARY FLOW IN PATIENTS UNDERGOING ELECTIVE CORONARY ANGIOGRAPHY****Birsen Doganay¹, Yucel Balbay²**¹*Numune Education and Research Hospital, Ankara, Turkey*²*Turkiye Yuksek Ihtisas Training and Research Hospital, Ankara, Turkey***Corresponding Author (birsengulkan@yandex.com)**birsengulkan@yandex.com, yucelbalbay1@gmail.com***Abstract Text**

Background: Coronary slow flow (CSF) is an angiographic phenomenon characterized by slow progression of contrast in the coronary arteries in the absence of coronary artery obstruction. As it is not considered as benign finding and there is still no convincing pathophysiologic explanation, further research is needed. In the present study, we aimed to evaluate the relationship between ABO blood groups and coronary flow characteristics.

Methods: The clinical, laboratory and angiographic data of 230 patients with SCF were collected retrospectively from our institutional databases. A total of 250 age- and gender-matched subjects with normal coronary flow (NCF) were used as a control group. Coronary flow was assessed by using the thrombolysis in myocardial infarction frame count (TFC). Coronary flow characteristics were evaluated according to ABO blood groups.

Results: A total of 230 patients with SCF (125 males, mean age: 54.6±9.1 years) and 250 subjects with NCF (134 males, mean age: 53.7±10.1 years) were included. In SCF group, cigarette smoking (33.5% vs 23.2%; p=0.012), platelet count (257.2±73.3 x10³/mm³ vs. 240.5±63.7 x10³/mm³, p=0.011) and mean MPV (9.2±1.4 fL vs. 8.8±1.2 fL, p=0.001) were higher than subjects with NCF. Having blood group A was more common in SCF group than subjects with NCF (53.5% vs 41.2%; p=0.039). In the regression analysis, blood group A (OR=1.94; p=0.003), cigarette smoking (OR=1.57; p=0.033), platelet count (OR=1.03; p=0.008) and MPV (OR=1.27; p=0.002) were found to be as independent predictors of SCF.

Conclusion: Blood group A is more common in SCF group and independently predicts SCF. Further studies are needed to evaluate the underlying mechanisms, but the relationship between blood groups and SCF seems multifactorial.

ID: 75

Topic: **Cardiology » Metabolic Syndrome**

Presentation Type: **Oral**

METABOLIC SYNDROME IN HYPERTENSIVE WOMEN

Maryam Mouadili

Centre Hospitalier Universitaire Mohammed VI, Marrakech, Morocco

**Corresponding Author (maryam.mouadili@gmail.com)*

maryam.mouadili@gmail.com

Abstract Text

Background: The metabolic syndrome (MetS) is recognized as a cluster of cardiovascular risk factors. Appropriate treatment can reduce cardiovascular morbidity and mortality. However, cardiologists may not routinely diagnosis the MetS.

Aim: To identify the prevalence of MetS among hypertensive women and to study the characteristics of this population.

Methods: We studied 248 hypertensive women, of median age 61(range: 18 - 86) years. Ten percent of them only were diagnosed as MetS. A health questionnaire was completed for all participants, including personal history of hypertension, diabetes mellitus (DM), smoking habits and medication. The waist circumference and blood pressure were measured as well as plasma glucose and the complete lipid profile.

Results: one hundred twenty two patients (49.19%) met the criteria for MetS. We divided our patients in three groups according their age (<40, 40-65and >65 years). There was no statistical significant difference in the prevalence of MetS in these 3 groups (50.7%, 43.6% and 53% respectively).

Concerning MetS related factors; increased waist circumference was by far the most common one (86.88%). There was no significant difference in the prevalence of MetS between women with controlled or uncontrolled HTA.

One hundred eight out of 248 females (43.54%) were diabetics, and the majority of them 92 (85.18%) met the criteria for MetS.

Conclusions: Our results suggest that the prevalence of MetS is dramatically increased among hypertensive women and this prevalence is not influenced by age. Interventions should be planned to increase the awareness of cardiologists to diagnose and treat the MetS

ID: 180

Topic: **Cardiology » Hypertension and Antihypertensive Therapy**Presentation Type: **Oral****HYPERTENSIVE PATIENTS: EVALUATION OF A THERAPEUTIC EDUCATION PROGRAM.****Maryam Mouadili¹, Cyriaque Mbauchy², Mariame Chakir²**¹*Centre Hospitalier Universitaire Mohammed VI, Marrakech, Morocco*²*Centre Hospitalier Universitaire Mohammed VI Marrakech, marrakech, Morocco***Corresponding Author (maryam.mouadili@gmail.com)**maryam.mouadili@gmail.com, cyrmbauchy@hotmail.com, mariamechakir@hotmail.com***Abstract Text**

Objective: Evaluation of a therapeutic education program for hypertensive patients over a 6-month period with personalized objectives.

Patients and methods: A prospective single-center study conducted in 106 patients, the study was conducted as follows:

- 1- Initial collection of epidemiological, clinical and paraclinical data from patients in normal consultation,
- 2- Each patient received a therapeutic education session -personalized- with education in the use of the "hypertension follow-up notebooks" developed by the work team.
- 3- The monitoring of the effectiveness of the education program was carried out over three evaluation consultations over the 6 months of survey.

Results: 106 patients participated in the study: mean age 47 ± 10 years; 62.26% of them male (66 patients). Essential hypertension in 95.28% of patients, grade II to III, uncontrolled in approximately 70% of them. With an average evolution period of: 9.5 ± 7.5 years. At 6 months, a significant decrease of SAP (from 154 ± 3 to 143 ± 3 mmHg, p less than 0.01) and DAP (from 95 ± 2 to 87 ± 2 mmHg, p less than 0.01) was notified. 50.7% versus 33.8% of patients have SAP and DAP in the therapeutic objectives. The monitoring of dietary and physical activity objectives is correlated with the decrease in BP ($p < 0.05$). Significant increase in self-monitoring with therapeutic decision-making ($p < 0.01$). Significant decrease in hypertension-related distress and feelings of failure ($p < 0.01$). Success rate among patients who chose the objective "reduce salt": 53%, "reduce fat": 50%, "walk several times/week (30 min)": 88%, "exercise at least once/week": 22%. 67% have at least one physical activity objective in place. No significant decrease in weight (-0.6 ± 4.1 kg) but 39% lost at least

2

kg.

Conclusion: A therapeutic education program with personalized objectives can give significant results at 6 months in terms of BP figures, dietetics and physical activity, self-monitoring of hypertension while reducing feelings of distress.



ID: 565

Topic: Cardiology » Percutaneous Coronary Interventions

Presentation Type: Oral

CLINICAL EFFECT OF NON-DIPPER AND DIPPER HYPERTENSION WITH ACUTE CORONARY SYNDROME PATIENTS

Deniz Elcik, Murat Cetin, Mehmet Tugrul Inanc

I Erciyes University Medicine Faculty, Department of Cardiology, Kayseri, Turkey, Kayseri, Turkey

**Corresponding Author (denizelcik@hotmail.com)*

denizelcik@hotmail.com, dr.mrtctn@hotmail.com, mtinanc@msn.com

Abstract Text

Abstract

Objectives: Cardiovascular parameters and coronary tonus change during the day with circadian rhythm. Because blood pressure does not show %10-20 decrease during sleep, target organ damage risk of non-dipper hypertension is related with left ventricle hypertrophy, MI, and stroke. In this study, we analyzed the effect of non-dipper hypertension on prevalence of coronary artery disease, time of symptom onset, and in-hospital MACE in patients with acute coronary syndrome.

Material and method: We included 107 patients who were diagnosed as acute coronary syndrome and had angina pectoris lasting 12 hours at most and no history of coronary artery disease in this study. Patients were monitored for 24-hour ambulatory blood pressure. Patients were stratified as non-dipper and dipper according to decrease of blood pressure during night. We compared both groups for prevalence of coronary artery disease, time of symptom onset, and in-hospital MACE.

Result: We included 52 patients in non-dipper group and 55 patients in dipper group in this study. When we compared both groups for Syntax and Gensini scores statistical significance was determined between the groups ($p=0.006$). In terms of symptom onset hours, 32 patients admitted with night angina pectoris in non-dipper group (%62) while 19 patients admitted with night angina pectoris in dipper group (%35) ($p=0.007$). In terms of in-hospital MACE ratios, we identified MACE in 6 patients in non-dipper group and 3 patients in dipper group ($p=0.223$). **Conclusion:** In our study, one can conclude that non-dipper hypertension increases number of lesions, MI cases at night, and MACE ratios in coronary artery disease by causing endothelium dysfunction and stimulating thrombocyte activation.

Keywords: Acute coronary syndrome, dipper and non-dipper hypertension

Oral Presentation Session**New Insights into Hypertension Management: Circadian Rhythm and Situational Variations**

Date: 27.03.2019 Time: 14:00 - 15:00 Hall: 5

ID: 36

Topic: **Cardiology » Preventive Cardiology**Presentation Type: **Oral****THE RELATIONSHIP BETWEEN DIURNAL BLOOD PRESSURE ABNORMALITIES AND TARGET ORGAN DAMAGE IN NORMOTENSIVE SUBJECTS. WHICH IS MORE IMPORTANT? INCREASED BLOOD PRESSURE LEVELS OR CIRCADIAN BLOOD PRESSURE ABNORMALITIES****Ziya Apaydın***Haseki Eğitim ve araştırma hastanesi, İstanbul, Turkey***Corresponding Author (ziyaapaydin@hotmail.com)**ziyaapaydin@hotmail.com***Abstract Text**

Abstract

Background and aim: Circadian blood pressure (CBP) abnormalities are well-known risk factors for many diseases such as cardiovascular, cerebrovascular, and chronic kidney disease. The object of this study was to evaluate the relationship between abnormalities in CBP rhythm and target organ damage (TOD) in normotensive non-dipper (non-DP) subjects.

Methods: The 24-hour ambulatory BP monitoring (ABPM) and echocardiography were performed and urinary albumin excretion (UAE) was measured in 127 dipper (DP) (41 males, 85 females) and 337 (89 males, 248 females) normotensive non-DP subjects.

Results: When we compared DP and non-DP subjects; Pulse wave velocity (PWV) ($7,12 \pm 1,72$ vs $7,57 \pm 1,87$ m/s, $p=0,02$), the percentile of corrected PWV (cPWV) (according to age) ($7,1$ vs $20,2$, $P=0,001$) and the percentile of corrected augmentation index (cAIx(%)) (according to age) ($23,5$ vs $33,9$, $p=0,03$), left ventricle mass index (LVMI) ($78,00 \pm 23,27$ vs $95,59 \pm 18,29$ g/m², $p=0,01$), relative wall thickness (RWT) ($0,36 \pm 0,13$ vs $0,46 \pm 0,09$, $p=0,01$), percentile of proteinuria ($8,6$ vs $29,2$ %, $p=0,00$) were higher in non-DP group. As a result of the correlation analyses, the PWV, LVMI, RWT were negatively correlated with the rate of systolic fall in nighttime (%) ($-0,15$, $p=0,01$ vs $-0,23$, $p=0,02$ vs $-0,27$, $p=0,00$). It was observed that both cPWV and UAE were affected by non-DP status (NDS) independently of other variables, in multivariate analysis (Odd ratio 95% CI. P Value c PWV $3,74.1,44-9,68. 0,00$; UAE $7,39. 1,78-28,4. 0,02$).

Conclusions: Our results suggested that normotensive persons with CBP abnormalities had TOD. Even subclinical atherosclerosis may have begun in these subjects. Therefore, the provision of diurnal blood pressure rhythm may reduce the incidence of future adverse events in normotensive subjects.

ID: 244

Topic: **Cardiology » Hypertension and Antihypertensive Therapy**Presentation Type: **Oral****NON-DIPPING PATTERN IN NORMOTENSIVE SUBJECTS IS RELATED TO INCREASED PULSE WAVE VELOCITY****Muhammed Yalcin***Selcuk University, Konya, Turkey***Corresponding Author (ulviyalcin@gmail.com)**ulviyalcin@gmail.com***Abstract Text**

Background: Non-dipper status, characterized by decreased nocturnal decline in blood pressure (BP), is associated with an increase in cardiovascular events. Pulse wave velocity (PWV) has been accepted as a easy way of measurement of arterial stiffness. PWV is a well-recognized predictor of an adverse cardiovascular outcome with higher predictive value than classical cardiovascular risk factors. However, to our knowledge, a possible relationship between PWV and normotensive non-dipper patients has not yet been clearly investigated. In this study, we investigated the association between PWV as the surrogate of arterial stiffness and non-dipper pattern in normotensive patients.

Methods: Subjects were included to the study according to ambulatory BP measurements (mean BP < 130/80 mmHg). 149 subjects, were enrolled retrospective manner. The non-dipping status and arterial distensibility were assessed using a Mobil-O-Graph Arteriograph, an automatic oscillometric device. Subjects with the history of any cardiovascular disease or hypertension were excluded from the study.

Results: 90 subjects had non-dipper pattern and 59 subjects had dipper pattern in the study. Baseline characteristics were not significantly different between the two groups, except the PWV (non-dipper vs dipper; 7.41 ± 1.82 vs 6.60 ± 1.34 m/s, $p=0.005$).

Conclusion: Non-dipper status has been recognized in several studies as a condition with increased risk for target organ damage in hypertensive and normotensive subjects. Our study instead has clearly demonstrated a significant relationship between PWV and the non-dipper status.

ID: 111

Topic: **Cardiology » Hypertension and Antihypertensive Therapy**Presentation Type: **Oral****MORNING BLOOD PRESSURE SURGE AND DIASTOLIC DYSFUNCTION
IN PATIENTS WITH MASKED HYPERTENSION**

Samet Yilmaz, Gökay Nar

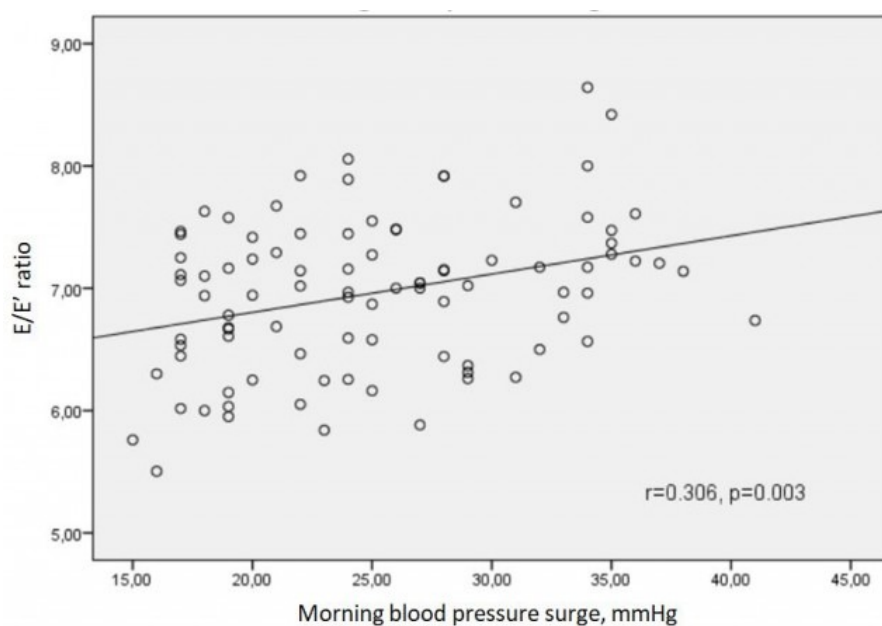
*Pamukkale University Faculty of Medicine, Denizli, Turkey***Corresponding Author (sametyilmazmd@gmail.com)**sametyilmazmd@gmail.com, gokay_nar@yahoo.com***Abstract Text**

Objectives Morning blood pressure surge (MBPS) is defined as an increase of blood pressure in the morning hours and it has been reported as a risk factor for cardiovascular events. In this study, we evaluated the association between MBPS levels and diastolic function parameters in patients with masked hypertension (MH).

Methods A total of 92 patients with diagnosis of MH were enrolled in the study. Patients were divided into three groups according to their MBPS levels. Cardiac structures, left atrial volume and ejection fraction were determined by transthoracic echocardiography. A 2-dimensional Doppler echocardiogram was performed to evaluate diastolic function parameters including transmitral E-wave and A-wave velocity, mitral annular E' and A' velocity, E wave deceleration time and isovolumic relaxation time.

Results Mean MBPS value of the total study population was 25.1 ± 6.4 mmHg. When going from the lower MBPS group to the highest MBPS group; E velocity [0.75 (0.74-0.77) vs. 0.71 (0.69-0.73) vs. 0.68 (0.66-0.69) m/sn, respectively] E/A ratio [1.44 (1.40-1.48) vs. 1.35 (1.32-1.39) vs. 1.26 (1.23-1.29), respectively] and E' velocity [0.114 (0.111-0.117) vs. 0.102 (0.100-0.105) vs. 0.093 (0.089-0.096) m/sn, respectively] were significantly decreased. E/E' ratio [7.3 (6.9-7.7) vs. 6.6 (6.4-7.9), $p=0.002$] and left atrial volume index [27.24 (25.5-28.9) vs. 21.90 (21.0-22.7) ml/m², $p<0.001$] were significantly higher in the highest MBPS tertile than the lowest tertile. There was a positive correlation between E/E' ratio and MBPS values ($r=0.306$, $p=0.003$).

Conclusions Increased MBPS levels was found to be related with deterioration of diastolic function parameters in patients with MH.



ID: 200

Topic: **Cardiology » Acute Coronary Syndromes**Presentation Type: **Oral**

VALUE OF MONOCYTE TO HDL-CHOLESTEROL LEVELS IN PREDICTING THE LONG TERM PROGNOSIS OF PATIENTS WITH ST-ELEVATION MYOCARDIAL INFARCTION

Abdullah Tunçez*Selçuk University Faculty of Medicine , Konya, Turkey***Corresponding Author (drtuncez@yahoo.com)**drtuncez@yahoo.com*

Abstract Text

BACKGROUND

ST elevation myocardial infarction (STEMI) is a cardiovascular emergency which is still a significant majority in acute coronary syndromes and is associated with high mortality and morbidity. In recent years the relationship between the levels of hematologic marker levels (neutrophil to lymphocyte ratio-NLR, platelet to lymphocyte ratio-PLR and monocyte to HDL-cholesterol ratio-MHR) and short/long term major adverse cardiac events (MACE) in patients with STEMI. In this research we investigate the association between admission MHR levels and long-term prognosis of patients with STEMI.

METHODS

We analyzed 216 STEMI patients retrospectively. Patients were divided into three groups according to admission MHR levels. In-hospital, 6-months and 30-months mortality rates of patients were recorded. GRACE (Global Registry of Acute Coronary Events) scores of patients on admission were calculated. We investigated the relationship between admission MHR levels and in-hospital, 1-month and 30-months mortality rates. We also evaluated the relationship between admission MHR levels and GRACE scores of patients. Association between admission NLR and PLR levels and long-term prognosis of STEMI patients were also evaluated. $p < 0.05$ was considered as statistically significant for all tests.

RESULTS

MHR values was $10,8 \pm 3,0$ for group 1, $19,7 \pm 2,4$ for group 2 and $36,7 \pm 13,1$ for group 3 ($p < 0,001$). There was no significant differences in three groups for the in-hospital, short and long term all-cause and cardiovascular mortality rates. ($p=0,167$ for total mortality and $p=0,421$ for cardiovascular mortality). MHR levels were negatively correlated with GRACE scores ($r:-0,143$ for 6 months GRACE score, $r:0,137$ for 12 months GRACE score and $r:0,118$ for 36 months GRACE score, pearson correlation analyze). Multivariate logistic regression analyze shows that, only advanced age was independently associated with long term mortality (OR:1,172, $p < 0,001$) and NLR, PLR and MHR has no statistically significant effects.

CONCLUSION

Admission MHR levels were ineffective to predict short and long-term prognosis of STEMI patients.

Oral Presentation Session**Multimodality Imaging in the Management of Cardiovascular Medicine**

Date: 27.03.2019 Time: 15:15 - 16:45 Hall: 5

ID: 60

Topic: Cardiology » Cardiac Imaging - Echocardiography**Presentation Type: Oral****ASSESSMENT OF INFLAMMATORY MARKERS AND EPICARDIAL ADIPOSE TISSUE THICKNESS IN WOMEN WITH POLYCYSTIC OVARY SYNDROME****Gamze Aslan¹, Çağdaş Aslan²***¹Koç University Hospital , Istanbul, Turkey**²Istanbul IVF and Women's Health Center, istanbul, Turkey***Corresponding Author (gamzeaslan@e-mail.com.tr)**gamzeaslan@e-mail.com.tr, cag_as@hotmail.com***Abstract Text**

Objective: Polycystic ovary syndrome (PCOS), one of the most common reproductive system disorders in women, is a clinical condition in which chronic inflammatory parameters increase. In this study, we aimed to evaluate the epicardial adipose tissue (EAT) thickness, inflammatory and immune parameters and their relationships with each other by comparing PCOS patients and healthy controls.

Methods: Complement 3 (C3), complement 4 (C4), hsCRP, GGT, fibrinogen, and hormonal parameters were measured in serum. EAT was measured with transthoracic echocardiography and abdominal subcutaneous adipose tissue thickness was measured with ultrasonography. **Results:** 32 patients with PCOS (mean age: 24 ± 6 years) and 27 healthy controls (mean age: 26 ± 3 years) were included in the study. EAT (p = 0.000), subcutaneous thickness (p = 0.000), C3 (p = 0.023), C4 (p = 0.039), hsCRP (p = 0.026), GGT (p = 0.012) and fibrinogen (p = 0.035) were significantly increased in the PCOS group compared to the control group. There were positive correlations between EAT thickness and BMI (r = 0.84, p = 0.000), abdominal subcutaneous adipose tissue thickness (r = 0.82, p = 0.000), HOMA-IR as a insulin resistance indicator (r = 0.62, p = 0.000), hsCRP (r = 0.58, p = 0.000), C3 (r = 0.52, p = 0.000), C4 (r = 0.44, p = 0.000), fibrinogen (r = 0.50, p = 0.000). In logistic regression analysis, EAT was found to have a significant relationship with PCOS (p = 0.000). According to linear regression analysis; C4 (p = 0.039), HOMA-IR (p = 0.000) and hsCRP (p = 0.006) were found to have a significant relationship with EAT.

Conclusions: Increased EAT which was found the significantly associated with PCOS, was showed significant relation with insulin resistance, C4, hsCRP in this study. Clinically, the evaluation of the levels of inflammatory and immune parameters together with the measurement of EAT thickness in PCOS patients may be helpful in determining the cardiovascular risk. Of course; prospective randomized controlled trials are needed to show this relationship more clearly in the future.

Keywords: Polycystic ovary syndrome, epicardial adipose tissue, complement factor, inflammation

ID: 431

Topic: Cardiology » Cardiac Imaging - Cardiac CT

Presentation Type: Oral

ASSOCIATION OF PLATELET-LYMPHOCYTE RATIO WITH THE PRESENCE, SEVERITY, EXTENT AND SUBTYPES OF CORONARY ATHEROSCLEROTIC PLAQUES DETECTED BY CORONARY COMPUTED TOMOGRAPHY ANGIOGRAPHY

Cüneyt Toprak

Umraniye Education and Research Hospital, , Istanbul, Turkey

**Corresponding Author (cuneytoprak@hotmail.com)*

cuneytoprak@hotmail.com

Abstract Text

Objective: We evaluated whether the platelet-lymphocyte ratio (PLR) was associated with the presence, severity, and extent of coronary atherosclerotic plaques detected by computed tomography angiography (CTA).

Methods: Three hundred six subjects (54.9 % men) who underwent dual-source 64-slice CTA for the assessment of coronary artery disease (CAD) were studied. Coronary arteries were evaluated on 16 segment basis and critical coronary plaque was described as luminal narrowing >50 %, whereas plaque morphology was assessed on per segment basis.

Results: The atherosclerotic lesions were detected in 195/306 (63.7 %) subjects by CTA. Logistic regression showed apart from age, diabetes mellitus, smoking, high-density lipoprotein cholesterol, low-density lipoprotein cholesterol, and white blood cell, PLR was an independently risk factor of the coronary atherosclerosis (121 ± 42 vs. 130 ± 46 , $p = 0.028$). Area under the receivers operating characteristic curve of PLR was 0.61 (95% confidence interval [CI] 0.54-0.67; $< .002$) for predicting a presence of coronary atherosclerotic plaques. Also PLR level was higher in patients with critical stenosis compared to non-critical stenosis ($p < 0.05$), and the extent of coronary atherosclerosis was increased with higher PLR levels.

Conclusions: Our study demonstrated that a higher PLR may be a useful additional measure to assess cardiovascular risk in clinical practice. Further prospective clinical studies are needed to clarify the exact physiopathologic and prognostic role of PLR in CAD.

ID: 197

Topic: Cardiology » Cardiac Imaging - Cardiac CT

Presentation Type: Oral

CORONARY ARTERY CALCIUM SCORE IS ASSOCIATED WITH RED BLOOD CELL DISTRIBUTION WIDTH AND MEAN PLATELET VOLUMECihan Altın¹, Mustafa Yılmaz², Esin Gezmiş¹, Haldun Müderrisoğlu³¹Baskent University, İzmir, Turkey²Baskent University, Adana, Turkey³Baskent University, Ankara, Turkey

*Corresponding Author (drcihanaltin@hotmail.com)

drcihanaltin@hotmail.com, yilmazmustafa2001@yahoo.com, khnumhetep@gmail.com, ihaldunum@gmail.com

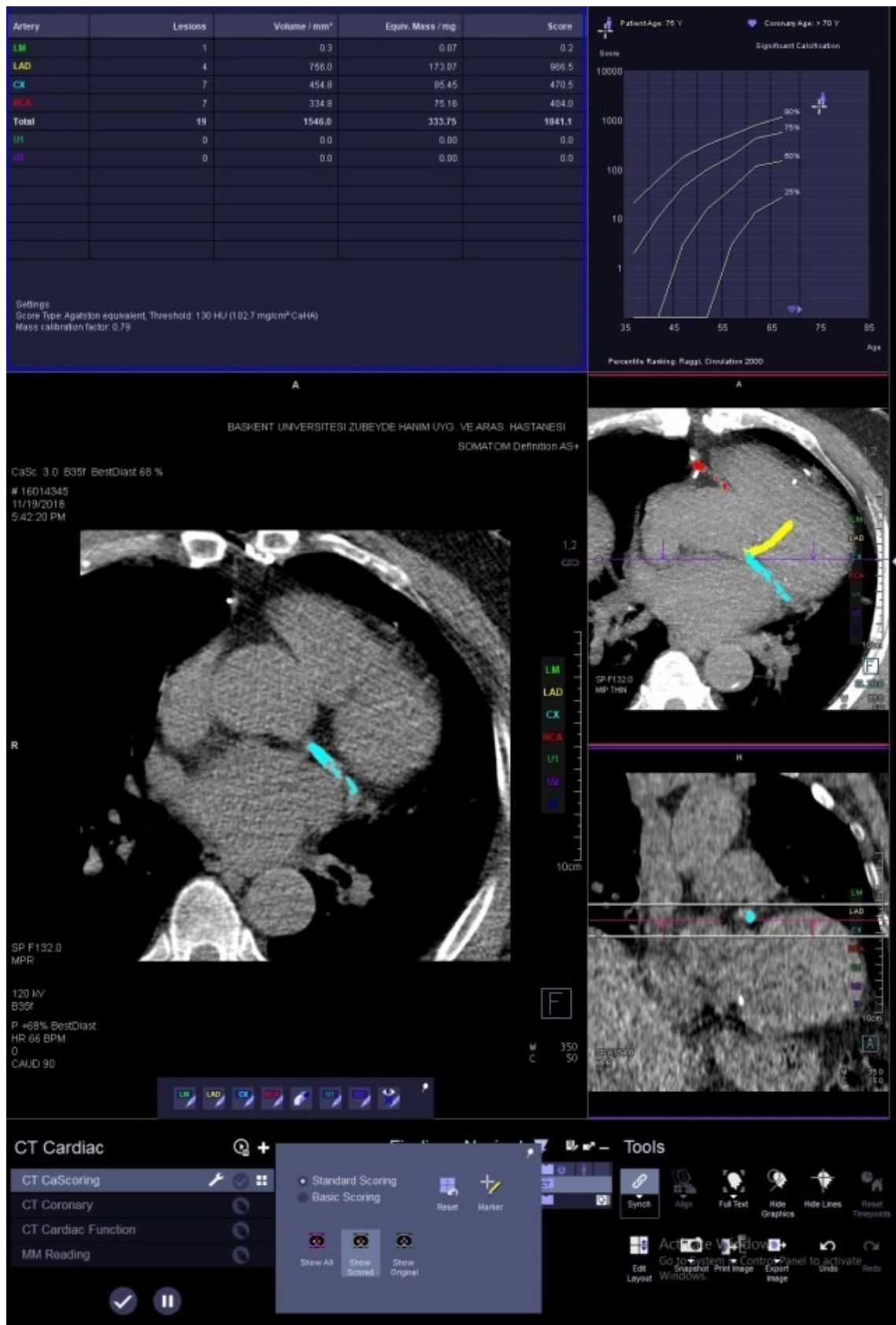
Abstract Text

Objective: In this paper, it is aimed to investigate red blood cell distribution width (RDW), mean platelet volume (MPV) and coronary artery calcium scores (CACs) in patients with and without coronary artery disease (CAD) detected by coronary computed tomography angiography (CCTA).

Methods: Clinical records of 172 patients who underwent CCTA due to the presence of angina-like symptoms were retrospectively investigated. Coronary calcium was quantified by using Agatston score (Figure). Clinical characteristics, risk factors for CAD, CACS and biochemical parameters including RDW and MPV were recorded.

Results: Mean MPV (7.95 ±1.57 fL vs. 7.12±1.26 fL, p<0.001) and RDW (15.36±1.15% vs 14.37±2.01%; p<0.001) levels were significantly higher in patients with CAD (n=85) than in those with normal coronary arteries (n=87). CACS is positively correlated with age (r=0.339, p < 0.001), fasting glucose (r=0.223, p=0.003), C-reactive protein (r=0.294, p<0.001), RDW (r=0.157, p=0.04) and MPV (r=0.221, p=0.004). On multivariate logistic regression analysis, CACS [odds ratio (OR): 1.005; 95% confidence interval (CI): 1.002-1.008; p=0.001] and MPV [OR: 1.410; 95% CI: 1.069-1.860; p=0.015] were shown to be one of the independent predictors for CAD detected by CCTA.

Conclusions: RDW and MPV were increased in patients with CAD detected by CCTA. These parameters were positively correlated with CACS which is a well-known indicator for CAD. Because several factors may affect these parameters further prospective studies are needed to confirm our results.



ID: 453

Topic: **Cardiology » Cardiac imaging - Nuclear Imaging**Presentation Type: **Oral****AN ASSESMENT OF ISCHEMIA AND INFARCTION RATES IN PATIENTS WITH ABNORMAL SUMMED STRESS SCORE****Gökmen Akkaya¹, Emine Acar²**¹*Ege University, İzmir, Turkey*²*Dokuz Eylul University Faculty of Medicine, İzmir, Turkey***Corresponding Author (akkayagokmen@gmail.com)**akkayagokmen@gmail.com, emineacar87@hotmail.com***Abstract Text****Objective:**

The purpose of this study is to determine the rate of infarct and ischemia in patients with abnormal summed stress score (SSS). Another aim is to evaluate how this ratio changes in terms of gender and presence of coronary artery disease (CAD).

Method:

Myocardial perfusion scintigraphy (MPS) images of overall 93 patients with SSS > 4 between March 2018 and December 2018 were retrospectively reviewed in the study. Stress and rest MPS images of all patients were analyzed by using seventeen segment model and five point scale via Cedars-Sinai myocardial imaging software (Table 1). SSS, summed rest score (SRS), summed difference score (SDS), stress total perfusion defect (TPD) percentage, rest TPD values were calculated automatically. Mann-Whitney U test was used for statistical analysis.

Result:

Images of 93 (50 female, 43 male) patients with a mean age of 61 ± 11 years were evaluated. Thirty patients were diagnosed with CAD, furthermore 15 patients had stent implantation and 11 had CABG. The mean values were calculated as SSS: 11.2 ± 6 , SRS: 6.6 ± 6 , SDS: 4.7 ± 3 , stress TPD: $13 \pm 8\%$, rest TPD: $7 \pm 8\%$. These values were SSS: 13.7 ± 12 , SRS: 9.2 ± 7 , SDS: 4.7 ± 8 , stress TPD: 16.9 ± 11 , rest TPD: 10.4 ± 11 in patients with CAD while SSS: 9.9 ± 5 , SRS: 5.4 ± 4 , SDS: 4.6 ± 3 , stress TPD: 11.6 ± 6 , rest TPD: 5 ± 6 in non-CAD group. The percentage of SRS, stress TPD and rest TPD results were significantly higher in patients with CAD (p: 0.006, p: 0.021, p: 0.020, p: 0.020, respectively). Although, SDS was higher in patients without CAD, this difference was not statistically significant (p: 0.759). Moreover, there was no difference observed in comparisons between genders. On the other hand, when the patients who were initially treated with stent and CABG compared; SDS was higher in stent group (p: 0.041), however there was no significant difference in SSS, SRS and percentages of stress and rest TPD values.

Conclusion:

Stress defects were observed in 13% and rest defect 7% of patients with abnormal SSS. The defects were associated with infarction with a rate of 54% and 46% with ischemia. The patients with CAD demonstrated more infarction zones. While the more ischemia zone was observed in patients with stent when compared to CABG group, infarct rate was similar.

ID: 37

Topic: **Cardiology » Cardiac imaging - Nuclear Imaging**Presentation Type: **Oral****COMPARISON OF AUTOMATED QUANTIFICATION OF NUCLEAR
CARDIOLOGY WITH SEMIQUANTITATIVE VISUAL ANALYSIS AND
CONVENTIONAL CORONARY ANGIOGRAPHY IN PATIENTS WITH
STABLE ANGINA USING IQ-SPECT MPI IN A SINGLE CENTER**Murat Cap¹, **Cem Dogan**², Emrah Erdogan³, Nihal Ozdemir⁴¹*Gazi Yaşargil Educational and Research Hospital, Diyarbakır, Turkey*²*Kartal Kosuyolu Educational and Research Hospital, İstanbul, Turkey*³*Agri State Hospital, Agri, Turkey*⁴*Kartal Kosuyolu Educational and Research Hospital, İstanbul, Turkey***Corresponding Author (murat00418@hotmail.com)**murat00418@hotmail.com, cemcardio@hotmail.com, dremraherdogan49@gmail.com,
ozdemirnihal@hotmail.com***Abstract Text**

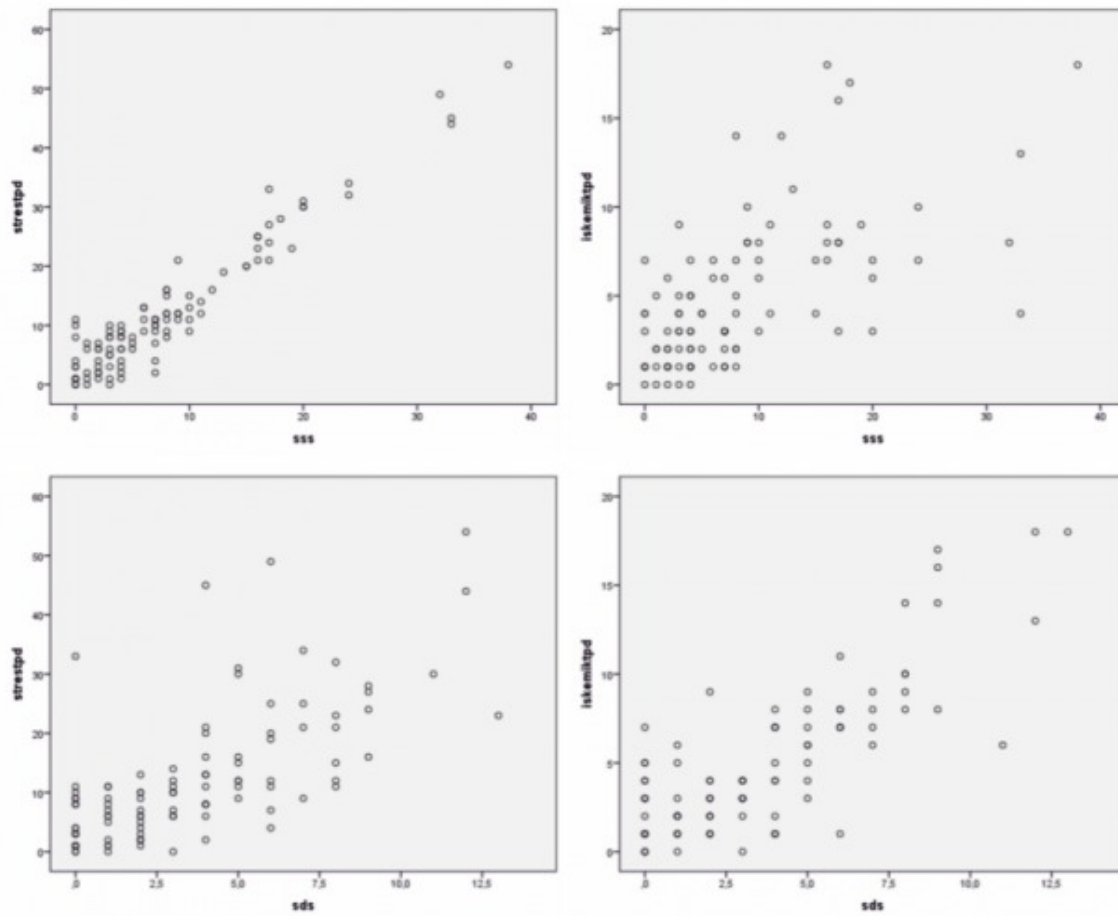
BACKGROUND: Semiquantitative visual analysis is commonly used for the detection of coronary artery disease (CAD) in nuclear cardiology. The aim of our study is to assess coronary artery disease with automated quantitative total perfusion deficit (TPD), and to detect validity of the automated quantitative and semiquantitative visual analysis by comparing with conventional coronary angiography.

METHODS: Patients with suspected CAD underwent a two-day 99mTc-sestamibi stress/rest testing with IQ-SPECT myocardial perfusion single photon emission computed tomography (SPECT) and conventional coronary angiography according to SPECT results. The summed stress scores (SSS), summed rest scores (SRS) and summed difference scores (SDS) (semiquantitative visual analysis results) were assessed on a five-point scale in a standard 17-segment model, and TPD (stress, rest and ischemic TPD) was quantified by automated software. A stenosis was considered significant if the narrowing of the arterial diameter detected by coronary angiography was $\geq 70\%$.

RESULTS: Eighty four patients (Group 1) had significant coronary lesions (who underwent revascularization) and 81 (Group 2) had nonsignificant lesions. The mean values were 10.3 ± 8.3 vs 5.2 ± 6.1 (mean \pm sd) for SSS, 4.8 ± 3.5 vs 2.1 ± 2.4 for SDS, 15.1 ± 11.7 vs 8.8 ± 8.2 for sTPD, 8.9 ± 8.7 vs 5.5 ± 7.2 for rTPD, and 6.2 ± 4.9 vs 3.5 ± 2.5 for iTPD ($p < 0.05$ for all) in Group 1 and Group 2, respectively. To detect ischemia, the optimal cut-off points were 5.5 (Se 72%, Sp 67%) for SSS, 2.5 (Se 70%, Sp 65%) for SDS, 8.5 (Se 75%, Sp 60%) for stress TPD and 4.5 (Se 56%, Sp 73%) for ischemic TPD. There were significant correlations between quantitative and semiquantitative variables (stress TPD-SSS $r: 0.954$, stress TPD-SDS $r: 0.746$, ischemic TPD-SSS $r: 0.654$, ischemic TPD-SDS $r: 0.759$; $p < 0.05$ for all).

CONCLUSION: Both quantitative and visual semiquantitative parameters of IQ-SPECT system can be used to detect myocardial ischemia compared to conventional angiography. Quantitative analysis appears to be a useful and valid method as summed scores to detect significant coronary artery disease.

Figure 2 : Correlations between quantitative and semiquantitative parameters.
SSS: Summed Stress Score, **SDS**: Summed Difference Score,
sTPD: Stress Total Perfusion Deficiency, **iTPD**: Ischemic Total Perfusion Deficiency



ID: 154

Topic: **Cardiology » Cardiac Imaging - Echocardiography**Presentation Type: **Oral**

EVALUATION OF THE PREDICTIVE CAPABILITES OF LEFT VENTRICULAR WALL MOTION PATTERN AND OTHER STRAIN CHARACTERISTICS IN LEFT VENTRICULAR NONCOMPACTION PATIENTS' FIRST DEGREE RELATIVES FOR EARLY DIAGNOSIS OF CARDIOMYOPATHY

Onur Akhan¹, Emre Demir², Filiz Özerkan Çakan³, Sanem Nalbantgil⁴

¹Bilecik State Hospital, Bilecik, Turkey

³Ege University Faculty of Medicine, Izmir, Turkey

**Corresponding Author (akhanonur@gmail.com)*

akhanonur@gmail.com, emre.demir.ege@gmail.com, fozerkan@yahoo.com, sanem.nalbantgil@ege.edu.tr

Abstract Text

BACKGROUND AND AIM:None of the diagnostic indices present in noncompaction cardiomyopathy involve left ventricular dysfunction. Left ventricular function and hemodynamics can be normal in these patients. For demonstrating regional deformation Tissue Doppler imaging studies, two and three dimensional 'speckle-tracking' and 'strain' echocardiography studies are available. The aim of this study is to evaluate 'Left ventricular noncompaction' patients and first degree relatives of these patients with respect to ventricular motion pattern and other strain characteristics, and demonstrate the predictive capabilities of these features for early diagnosis of cardiomyopathy.

METHODS:This cross-sectional, case-control study included 32 noncompaction cardiomyopathy patients, 30 first-degree relatives and 31 healthy volunteers. All patients were evaluated for baseline echocardiography, strain measurements, and ventricular wall motion pattern. Student t test, chi square test and ce fisher tests were used for statistical analysis. In all analyzes, $p < 0.05$ was considered significant.

RESULTS:There was no difference between the case and control groups in terms of age, weight and body surface area. There was a statistically significant decrease in EF, FS, E / E', GLS, GLSr, GCS, GCSr, GRS and GRSr values from the control group to the patient relatives and the patient group, respectively(patient relatives and control EF $p = 0,023$, for all other groups $p < 0.01$). There was a significant correlation between EF and strain values in all groups ($p < 0.001$). When the rotation values were examined, the decrease was observed from the control group to the patient relatives and the patient group, respectively, but significant difference was observed between the patient and the other groups and not between the patient relatives and control groups. In the case group, 'Rigid Body Rotation(RBR)' movement pattern was observed in 17 patients and the present pattern was observed in 9 patients in the patient relatives group. EF, GLS, GLSr and basal rotation values were significantly lower and GRS and GRSr values were higher in the group with RBR after comparison of patients with and without RBR pattern.

CONCLUSIONS:It may be considered that the evaluation of the strain characteristics of all three study groups, observations of significant differences and findings in terms of RBR motion pattern contribute to reveal the genotype - phenotype relation of disease and to suggest that these features are predictive of early diagnosis of cardiomyopathy.

ID: 84

Topic: **Cardiology » Cardiac Imaging - Echocardiography**Presentation Type: **Oral****ECHOCARDIOGRAPHY AS A PREDICTING METHOD IN DIAGNOSIS AND OUTCOMES OF KOSOVAR CHILDREN WITH HYPERTROPHIC CARDIOMYOPATHY****Ramush Bejqi¹**, Arlinda Maloku¹, Aferdita Mustafa¹, Hana Bejqi², Rinor Bejqi¹¹*Pediatric Clinic, University Clinical Center of Kosovo, Prishtina, Republic of Kosovo, Prishtina, Kosovo*²*Main Center of Family Medicine, Prishtina, Republic of Kosovo, Prishtina, Kosovo***Corresponding Author (rbejqi@hotmail.com)**rbejqi@hotmail.com, lindamaloku@yahoo.com, ditam22@hotmail.com, hebjiqi@live.com, rinorbejqi@gmail.com***Abstract Text**

Background Hypertrophic cardiomyopathy (HCM) is a condition in which a portion of the heart becomes thickened without an obvious cause, which results in the less able to pump blood effectively. Symptoms vary from none to feeling tired, leg swelling, and shortness of breath or chest pain to fainting, heart failure, an irregular heartbeat, and sudden cardiac death. Identification of the manifestations, assessment and follow up of children with of hypertrophic cardiomyopathy (HCM) by transthoracic echocardiography may be important for clinical management and our understanding of the pathogenesis.

Method Retrospectively we analyzed medical records of all children diagnosed with HCM in Kosovo, during the period 2005 – 2017, clinical profile and outcomes.

Results Here we present a comprehensive analysis of 43 patients seen in Kosovo, of whom 23 were male, aged between 4 months and 9 years at first presentation, (median of 2 years and 3 months). Cardiac failure, seen in almost half of them, was the most frequent presenting feature. In admission, on the chest x-ray, the cardiothoracic ratio was increased, to a mean of 72 % in 5 infants and to 65 % in 37 older children. Measured by transthoracic echocardiography, in 28 patients hypertrophy of left ventricle was asymmetric while 15 had concentric hypertrophy. Left ventricular ejection fraction was depressed in the 21 patients. Patients in cardiac failure received various combinations of diuretics, B-blockers, ACE inhibitors and aspirin. Death occurred in 8 patients, in 4 of them shortly after admission, 3 left Kosovo and continued examination abroad, and the remaining 32 were followed- up for a mean 42 months, with a range from 5 to 115 months. Surgical intervention was not performed to none of them, despite of clinical and echocardiographic indications. Recovery was noted in 14 patients but still requiring anti-failure medications. Slightly over two-fifths died. Of those with asymmetric form, 45 % died, in half of those presenting in infancy, and 89 % of those who presented at admission with signs of cardiac failure.

Key words: hypertrophic cardiomyopathy, left ventricular hypertrophy, heart failure, myectomy, transthoracic echocardiography

ID: 98

Topic: Cardiology » Cardiac Imaging - Echocardiography

Presentation Type: Oral

CARDIAC SYNDROME X IS RELATED WITH IMPAIRED AORTIC ELASTICITY AND INCREASED EPICARDIAL FAT THICKNESS.Onur Akgün, **Vahit Demir**, Yaşar Turan, Huseyin Ede*Bozok University, Faculty of medicine, Yozgat, Turkey***Corresponding Author (dr.vdemir@hotmail.com)**onur_akgun@hotmail.com, dr.vdemir@hotmail.com, yasar044@yahoo.com, huseyinede@gmail.com***Abstract Text**

Objective: Epicardial fat tissue (EFT) is located over the myocardium and is enclosed by visceral pericardium. Previous studies have shown an association between EFT and arterial stiffness in most cardiovascular diseases. EFT and arterial stiffness have been considered as an independent predictors of cardiovascular morbidity in cardiovascular disease. The aim of this study was to investigate the EFT and aortic stiffness in patients with cardiac syndrome X (CSX).

Patients and methods: This study was designed in cross-section. The study population included 85 patients (mean age 54±6 years; 32 men) with typical anginal symptoms and a positive exercise stress test or ischemia in myocardial perfusion scintigraphy and normal coronary arteries detected angiographically, and 85 otherwise healthy subjects (mean age 53±8 years; 38 men) with atypical chest pain and a negative stress test. EFT, systolic and diastolic diameters were measured by M-mode echocardiography, and elastic indices (aortic stiffness index and distensibility) were calculated. Pulse pressure was obtained by a sphygmomanometer. The results were compared with those of a control group consisting of age- and sex-matched otherwise healthy subjects

Results: Age, gender, and body mass index were similar between the groups. Aortic systolic and diastolic diameters were significantly higher in the CSX group. Aortic stiffness index was higher in CSX patients compared to healthy individuals (2.44±0.33 and 3.75±0.53, p<0.001). Also, aortic distensibility was lower in CSX patients than those with control groups (2.98±1.24 and 5.31±2.82, p<0.001). EFT was significantly higher in the CSX group than in the control group (0.59±0.28 and 0.46±0.38 respectively, p<0.001) (Table 1). Patients had significantly higher C-reactive protein and white blood cell levels than the control group (p values are <0.001 and p<0.001 respectively).

Conclusion: Aortic stiffness and EFT are increased in patients with CSX. Using a noninvasive and readily available tool such as transthoracic echocardiography, arterial stiffness and EFT can easily be assessed, so the knowledge about the cardiovascular burden of the subjects can be obtained and early precautions may be considered in the treatment and follow-up. Additionally these findings suggest that increased EFT and impaired elastic properties of aorta may have a role in pathophysiology of CSX.

Table 1. Echocardiography data data of the Control and Cardiac syndrome X Groups

Control Groups (n=85)	Cardiac syndrome X Groups (n=85)	p*	
Aort systolic diameter (cm)	3,0±0,4	3,2±0,4	<0,001
Aortic diastolic diameter (cm)	2,6±0,3	3,1±0,3	<0,001
Left ventricular ejection fraction (%)	63±2	62±2	0,168
Epicardial fatty tissue	0.46±0.38	0.59±0.28	<0,001
Aortic dispensability	5,31±2,82	2,98±1,24	<0,001
Aortic strain indeksi	2,44±0,33	3,75±0,53	<0,001

Oral Presentation Session**New Echocardiographic Indices in Atrial Imaging**

Date: 27.03.2019 Time: 16:45 - 18:15 Hall: 5

ID: 556**Topic: Cardiology » Cardiac Imaging - Cardiac CT****Presentation Type: Oral****COMPARISON OF TRANSESOPHAGEAL ECHOCARDIOGRAPHY TO COMPUTED TOMOGRAPHY IN EVALUATION OF LEFT ATRIAL APPENDAGE THROMBUS BEFORE ATRIAL FIBRILLATION ABLATION****Begum Yetis Sayin, Sercan Okutucu, Hakan Aksoy, Ebru Ercan Akgul, Ali Oto***Memorial Ankara Hospital, Ankara, Turkey***Corresponding Author (begumyts@yahoo.com)**begumyts@yahoo.com, sercanokutucu@yahoo.com, haksoy63@yahoo.com, akgul37ebru@hotmail.com, alioto@tksv.org***Abstract Text**

Catheter ablation of arrhythmogenic origins has been applied to patients who have atrial fibrillation refractory to antiarrhythmic medication. A dilated left atrium (LA) and reduced blood flow in LA and left atrial appendage (LAA) on echocardiogram are independent risk factors for thromboembolism. Also presence of spontaneous echo contrast (SEC) or "smoke" on transesophageal echocardiography (TEE) has been related to hemodynamic and hemostatic abnormalities with an increased risk of stroke and thromboembolism. Evaluation of thrombus in LA and LAA with TEE or computed tomography(CT) before atrial fibrillation ablation is mandatory to reduce embolic events before and after the procedure. Also the goal of pre-procedural imaging is to obtain a detailed anatomical description of the pulmonary veins and to define prognostic factors for recurrence. Guidelines have uniformly recommended TEE to accomplish these goals. Although TEE is the gold standard for detecting LA thrombus, there has been increasing interest in the use of cardiac computed tomography angiography (CCTA) especially used before AF ablation to define pulmonary venous anatomy which has 3-dimensional imaging ability. Some previous studies have supported CCTA to have high sensitivity and negative predictive value for detecting thrombus in LAA. We aimed to determine the accuracy of CCTA in detecting and excluding LAA thrombus in comparison with TEE.

Methods

We retrospectively reviewed 30 patients with paroxysmal and persistent AF who had atrial fibrillation ablation procedure with electroanatomic mapping system with CARTO/Ensite, cryoablation or radiofrequency ablation. Cardiovascular images of two/three dimensional TEE and CCTA performed immediately before pulmonary vein ablation procedure. Exclusion criteria were overweight of 220 kg, renal insufficiency (glomerular filtration rate<30 ml/min) and documented history of anaphylaxis to iodinated contrast agent for CCTA. TEE studies were evaluated by a reader blinded to results of CCTA images. CCTA images were analyzed by one experienced reader blinded to all echocardiographic information.

Results

In our study of 30 patients, the mean age was 62.1 years (19 men and 11 women). TEE was used as reference standard method for determining the sensitivity and specificity of CT for the detection thrombi and circulatory stasis in LAA. Cryoablation was applied in 40% of patients, also in 33 % of them had ablation by using electroanatomic mapping with CARTO/Ensite system and 27 % of patients had radiofrequency ablation procedure with conventional methods. CCTA images used to merge with images in electroanatomic mapping system. In 3 patients LAA closure applied at the end of ablation. 28 patients had no thrombus or SEC on both TEE and CT. In one patient there was thrombus both in CT and TEE, also in follow-up after 6 months thrombus disappeared. Also SEC was seen on TEE in one patients but LAA was clear on CT images. Using TEE as the reference standard, positive predictive value(PPV), negative predictive value(NPV) and accuracy of the CCTA imaging for the detection of thrombus were calculated (PPV was 100%, NPV was 96.5%, accuracy was 96.67%).

Conclusion

Multi detector CT angiography effectively and simply meets nearly all images that are mandatory for ablation. Both imaging modalities have some unique capabilities to use in specific situations. We conclude that CCTA is a reasonable alternative to TEE when the primary aim is to exclude left atrial and left atrial appendage thrombus and in patients in whom the risks associated with TEE outweigh the benefits. Also both of them should be discussed according to shared decision making. CCTA imaging seems to have more advantages than TEE not only for imaging of LAA but also to evaluate pulmonary vein anatomy before or during ablation and determine factors in prognosis.

Key words: Atrial fibrillation ablation, thrombus, left atrial appendage

ID: 141

Topic: Cardiology » Cardiac Imaging - Echocardiography

Presentation Type: Oral

IS THERE ANY LINK BETWEEN VITAMIN D AND LEFT ATRIAL DIAMETER IN CHILDREN?

Sule Gokce¹, Zeynep Cerit², Levent Cerit²

¹Ege University, İzmir, Turkey

²Near East University, Nicosia, Turkish Republic of Northern Cyprus

sule.gokce@yahoo.com, drceritzeyno@gmail.com, drcerit@hotmail.com

Abstract Text

OBJECTIVE

Vitamin D (vitD) deficiency has been found associated with rickets/osteomalacia, autoimmune diseases, cardiovascular system diseases, and infectious diseases. Growing evidence demonstrated that vitD has a key role in the renin-angiotensin-aldosterone system. Although there is a strong association between left atrial diameter and serum vitD level in adults, there is scarce data in children. Therefore, we aimed to assess the association between serum vitD level and left atrial diameter in children.

METHODS

We performed a prospective study with 97 children in routine control without any complaint. All patients were evaluated for the echocardiographic evaluation in the outpatients clinic, and the children were divided into two groups as vitamin D deficiency group (vitamin D < 20 ng/ml) and control group (vitamin D ≥ 20 ng/ml). Demographic data, echocardiographic parameters, and serum vitD level were analysed. A p-value of < 0.05 was considered significant.

RESULTS

The study population included 97 children, and the prevalence of vitD deficiency was found 46.3%. Although left atrial diameter was increased in children with vitD deficiency, there was no significant difference between the two groups with regard to left atrial diameters. Left atrial diameter was significantly associated with BMI z-score ($r=0.301$), age ($r=0.307$) ($P<0.001$), interventricular septum ($r=0.209$), weight ($r=0.184$), vitD ($r=0.127$). On multivariate analysis, BMI z-score was significantly associated with left atrial diameter. BMI z-score is independently associated with left atrial diameter.

CONCLUSIONS

Although left atrial diameter was increased in patients with vitD deficiency, serum vitamin D level was not found an independently associated with the left atrial diameter.

ID: 524

Topic: Cardiology » Cardiac Imaging - Echocardiography

Presentation Type: Oral

**THE RIGHT ATRIAL AND VENTRICULAR FUNCTIONS ASSESSED BY
SPECKLE TRACKING ECHOCARDIOGRAPHY IN PATIENTS WITH
ACUTE PULMONARY EMBOLISM****Beste Ozben**, Nurten Sayar, Tuba Bayram, Özge Can Bostan, Emel Eryüksel, Emre Gürel, Altuğ Çiçin, Anıl Şahin, Murat Sünbül, Kürşat Tigen*Marmara University School of Medicine, Istanbul, Turkey***Corresponding Author (besteozen@yahoo.com)**besteozen@yahoo.com, sayarnurten@gmail.com, dr.tubik@gmail.com, ozge.can20@hotmail.com, emeleryuksel@yahoo.com, emregurelctf@yahoo.com, acincin@yahoo.com, aanilsahin@hotmail.com, drsunbul@yahoo.com.tr, mktigen@yahoo.com***Abstract Text**

Background: Right ventricular functions are impaired due to acute right ventricular pressure overload in patients with massive and submassive acute pulmonary embolism. Right ventricular size and functions are presumed to be normal in patients with nonmassive pulmonary embolism. The aim of this study was to assess right atrial and ventricular functions in patients with nonmassive acute pulmonary embolism.

Methods: Seventy-one patients with confirmed acute pulmonary embolism and 50 normal subjects were consecutively included. The right atrial, right and left ventricular functions were evaluated by both conventional and speckle-tracking echocardiography.

Results: Thirty-four patients had submassive pulmonary embolism while 37 patients had nonmassive pulmonary embolism. The echocardiographic parameters of the pulmonary embolism patients and controls are listed in Table 1. Submassive pulmonary embolism patients had significantly larger right ventricle and higher systolic pulmonary artery pressure while they had significantly lower right ventricular fractional area change and tricuspid annular plane systolic excursion compared to nonmassive pulmonary embolism patients and controls. While there were not any significant differences in conventional echocardiographic parameters between nonmassive pulmonary embolism patients and controls, right ventricular global longitudinal strain assessed by “speckle tracking” echocardiography was significantly lower in nonmassive pulmonary embolism patients. Right atrial phasic functions were impaired in submassive pulmonary embolism patients compared to nonmassive pulmonary embolism patients and controls.

Conclusions: Acute pulmonary embolism impaires right atrial and ventricular functions. Even in nonmassive patients, “speckle tracking” echocardiography revealed that right atrial and ventricular functions were impaired although the conventional echocardiographic parameters were similar to those of controls.

	Patients with submassive pulmonary embolism (n= 34)	Patients with nonmassive pulmonary embolism (n= 37)	Controls (n= 50)	p
Age (years)	69.0 ± 11.3 ^{ab}	54.8 ± 13.4	36.0 ± 10.0	<0.001
Male sex (n-%)	18 (52.9%)	13 (35.1%)	29 (58.0%)	0.097
Right atrial reservoir function (%)	22.4 ± 7.9 ^{ab}	30.8 ± 14.0	35.3 ± 10.3	<0.001
Right atrial conduit function (%)	11.3 ± 5.4 ^{ab}	16.0 ± 9.8	16.7 ± 5.8	0.004
Right ventricle (mm)	38.2 ± 7.3 ^{ab}	32.6 ± 4.6	31.9 ± 4.7	<0.001
Right ventricular fractional area change (%)	33.5 ± 8.8 ^{ab}	45.5 ± 8.1	42.4 ± 7.2	<0.001
Tricuspid annular S velocity (cm/s)	13.1 ± 4.3	13.0 ± 2.0	14.3 ± 1.8	0.056
Tricuspid annular plane systolic excursion (TAPSE) (mm)	18.0 ± 4.7 ^{ab}	20.9 ± 4.0	22.8 ± 4.1	<0.001
Systolic pulmonary arterial pressure (mmHg)	39.8 ± 18.8 ^{ab}	24.7 ± 11.1	18.8 ± 7.0	<0.001
Right ventricular global longitudinal strain (%)	16.6 ± 3.9 ^a	17.9 ± 2.5 ^a	20.7 ± 3.1	<0.001
Left ventricular ejection fraction (%)	50.7 ± 5.6 ^a	53.3 ± 7.3	55.0 ± 5.0	0.008
Left ventricular global longitudinal strain (%)	16.9 ± 2.9 ^a	18.0 ± 2.0 ^a	20.3 ± 2.2	<0.001

Posthoc analysis; ^a significant compared to controls; ^b significant compared to nonmassive pulmonary embolism patients

ID: 512

Topic: Cardiology » Cardiac Imaging - Echocardiography

Presentation Type: Oral

RIGHT ATRIAL VOLUME AND PHASIC FUNCTIONS IN HEALTHY SMOKERS

Beste Ozben, Nurten Sayar, Tuba Bayram, Özge Can Bostan, Emel Eryüksel, Murat Sünbül, Altuğ Çinçin, Anıl Şahin, Emre Gürel, Kürşat Tigen

Marmara University School of Medicine, Istanbul, Turkey

*Corresponding Author (besteozen@yahoo.com)

besteozen@yahoo.com, sayarnurten@gmail.com, dr.tubik@gmail.com, ozge.can20@hotmail.com, emeleryuksel@yahoo.com, drsunbul@yahoo.com.tr, acincin@yahoo.com, aanilsahin@hotmail.com, emregurelctf@yahoo.com, mktigen@yahoo.com

Abstract Text

Background: Smoking is a risk factor for cardiovascular diseases. It may contribute to the development of atrial fibrosis via nicotine. The aim of this study was to evaluate the right atrial volume and phasic functions in apparently healthy smokers.

Methods: Eighty healthy smokers and 70 healthy nonsmokers were consecutively included in the study. None of the subjects had additional cardiovascular risk factor other than smoking. The right atrial and ventricular functions were assessed by speckle tracking echocardiography.

Results: The echocardiographic parameters of the smokers and nonsmokers are listed in Table 1. The smokers had significantly larger right atrial volumes. The right atrial reservoir and conduit strain were significantly lower in healthy smokers compared to those of nonsmokers. Similarly, smokers had significantly lower right ventricular global longitudinal strain compared to nonsmokers.

Conclusions: Smoking impairs right atrial and ventricular functions even in apparently healthy young people with no other additional cardiovascular risk factors. Speckle tracking echocardiography is useful in detecting subclinical right atrial and ventricular dysfunction in healthy smokers.

	Smokers (n= 80)	Nonsmokers (n= 70)	P
Age (years)	35.5 ± 8.4	33.9 ± 9.5	0.273
Male sex (n-%)	56 (70%)	44 (62.9%)	0.355
Right atrial volume max (mL)	37.6 ± 15.8	30.8 ± 10.8	0.002
Right atrial volume min (mL)	16.1 ± 7.6	12.8 ± 5.0	0.002
Right atrial volume pre-A (mL)	23.9 ± 10.6	18.9 ± 6.6	0.001
Right atrial total stroke volume (mL)	21.5 ± 10.8	17.9 ± 7.9	0.021
Right atrial total emptying fraction (%)	56.1 ± 12.3	57.5 ± 11.7	0.488
Right atrial passive stroke volume (mL)	13.7 ± 7.5	11.8 ± 5.7	0.082
Right atrial passive emptying fraction (%)	35.9 ± 10.8	37.6 ± 9.9	0.310
Right atrial active stroke volume (mL)	7.8 ± 4.2	6.1 ± 2.9	0.005
Right atrial active emptying fraction (%)	32.4 ± 11.2	32.7 ± 11.0	0.882
Right atrial expansion index	151 ± 94	155 ± 80	0.752
Right atrial reservoir function (%)	33.0 ± 10.6	37.6 ± 11.2	0.011
Right atrial conduit function (%)	15.2 ± 5.6	18.0 ± 6.3	0.004
Right ventricular global longitudinal strain (%)	- 18.4 ± 2.1	- 21.8 ± 2.2	<0.001

ID: 504

Topic: Cardiology » Cardiac Imaging - Echocardiography

Presentation Type: Oral

LEFT ATRIAL VOLUME AND PHASIC FUNCTIONS IN HEALTHY SMOKERS

Beste Ozben¹, Nurten Sayar¹, Tuba Bayram¹, Özge Can Bostan¹, Emel Eryuksel¹, Anıl Şahin¹, Altuğ Çinçin¹, Murat Sünbül², Emre Gürel¹, Kürşat Tigen¹

¹Marmara University School of Medicine, Istanbul, Turkey

*Corresponding Author (besteozen@yahoo.com)

besteozen@yahoo.com, sayarnurten@gmail.com, dr.tubik@gmail.com, ozge.can20@hotmail.com, emeleryuksel@yahoo.com, aanilsahin@hotmail.com, acincin@yahoo.com, drsunbul@yahoo.com.tr, emregurelctf@yahoo.com, mktigen@yahoo.com

Abstract Text

Background: Smoking is a major risk factor for cardiovascular diseases. It is associated with activation of the autonomic nervous system, oxidative stress, inflammation and endothelial dysfunction and may result in significant alteration in the diastolic functions of both ventricles. The aim of this study was to evaluate the left atrial volume and phasic functions in apparently healthy smokers.

Methods: Eighty healthy smokers and 70 healthy nonsmokers were consecutively included in the study. None of the subjects had additional cardiovascular risk factor other than smoking. The left atrial and ventricular functions were assessed by speckle tracking echocardiography.

Results: The echocardiographic parameters of the smokers and nonsmokers are listed in Table 1. The left atrial reservoir and conduit strain were significantly lower in healthy smokers compared to those of nonsmokers. Similarly, left ventricular global longitudinal strain was lower in smokers although the left ventricular ejection fraction was similar.

Conclusions: Smoking impairs left atrial and ventricular functions even in apparently healthy young people with no other additional cardiovascular risk factors. Speckle tracking echocardiography is useful in detecting subclinical left atrial and ventricular dysfunction in healthy smokers.

	Smokers (n= 80)	Nonsmokers (n= 70)	P
Age (years)	35.5 ± 8.4	33.9 ± 9.5	0.273
Male sex (n-%)	56 (70%)	44 (62.9%)	0.355
Left atrial volume max (mL)	33.5 ± 12.8	34.3 ± 12.3	0.719
Left atrial volume min (mL)	12.2 ± 5.7	12.3 ± 5.8	0.905
Left atrial volume pre-A (mL)	19.2 ± 7.6	19.9 ± 7.9	0.605
Left atrial reservoir function (%)	35.9 ± 11.1	40.2 ± 11.2	0.022
Left atrial conduit function (%)	16.7 ± 6.8	19.4 ± 6.8	0.016
Left ventricular ejection fraction (%)	54.8 ± 5.0	54.6 ± 4.3	0.869
Left ventricular global longitudinal strain (%)	- 19.0 ± 2.0	- 21.2 ± 1.9	<0.001

ID: 137

Topic: **Cardiology » Cardiac Imaging - Echocardiography**

Presentation Type: **Oral**

THE EFFECT OF NONINVASIVE VENTILATION ON LEFT AND RIGHT MYOCARDIAL FUNCTION IN PATIENTS WITH OBSTRUCTIVE SLEEP APNEA SYNDROME: A SPECKLE TRACKING ECHOCARDIOGRAPHIC BASED STUDY

Batur Gonenc Kanar

Marmara University, Istanbul, Turkey

**Corresponding Author (baturkanar@hotmail.com)*

baturkanar@hotmail.com

Abstract Text

Background and aim: In patients with obstructive sleep apnea syndrome (OSAS), repetitive hypoxia due to sleep-induced apnea adversely affects the interaction between myocardial oxygen demand and supply, resulting in the development of subclinical cardiac dysfunction. The purpose of the study was to analyze the different involvement of left ventricle (LV) and right ventricle (RV) functions in patients with OSAS treated with noninvasive ventilation (NIV)

Methods: Conventional 2D echocardiography (2DE) and speckle tracking echocardiography (STE) were performed in 64 patients with OSAS undergoing NIV (M/F 48/16; mean age 66.5±10.3 years). LV and RV global longitudinal strain (GLS) was calculated by averaging local strain along the entire right and left ventricle, before and after 6 months of nocturnal NIV therapy. Right ventricle (RV) peak longitudinal systolic strain dyssynchrony (PLSSD) index, which presented right intraventricular synchronicity, was derived from the standard deviation of the times from QRS beginning to PLSS of the six segments.

Results: There was no statistically significant difference between before and after NIV therapy in 2DE measurements, except estimated SPAP (38±4.6 vs. 26±3.8). After NIV therapy RV GLS, LV GLS, and RV PLSSD index significantly decreased (Table 1).

Conclusion: STE is a useful tool for assessing left and right heart myocardial deformation in patients with OSAS and for monitoring the effect of NIV.

NIV: non-invasive ventilation; OSAS: obstructive sleep apnea syndrome.

OSAS patients before NIV	OSAS patients after NIV	p value	
Left ventricle ejection fraction (%)	64.4±6.7	62.7±5.9	0.48
Right ventricle fractional area change (%)	42.5±5.6	43.2±5.7	0.27
Mitral E/A	7.5±3.4	6.8±3.2	0.39
Pulmonary artery systolic pressure (mmHg)	38.2±5.6	26.7±4.3	0.01
Right ventricle end-diastolic diameter (mm)	45.3±15.6	43.7±12.9	0.14
Tricuspid annular plane systolic excursion (mm)	18.2±3.4	19.3±3.4	0.25
Right ventricle S' (cm/s)	11.2±2.4	12.3±2.5	0.12
Left ventricle global longitudinal strain (-%)	19.6±4.3	20.8±4.9	0.02
Right ventricle global longitudinal strain (-%)	17.8±3.7	20.3±4.5	<0.001
Right ventricle peak longitudinal systolic strain dyssynchrony index	68.4±4.7	24.6±2.5	<0.001

ID: 287

Topic: **Cardiology » Cardiac Imaging - Echocardiography**Presentation Type: **Oral****HIGHER ULTRAFILTRATION RATE IS ASSOCIATED WITH RIGHT VENTRICULAR MECHANICAL DISPERSION****Serkan Ünlü***Ataturk Chest Diseases and Chest Surgery Education and Research Hospital, Ankara, Turkey***Corresponding Author (unlu.serkan@gmail.com)**unlu.serkan@gmail.com***Abstract Text**

Objective: Patients undergoing hemodialysis (HD) therapy have high cardiovascular mortality rate. Ultrafiltration rate is one of the major determinants of adverse outcomes. Current data shows a strong relation between adverse cardiovascular outcomes and high ultrafiltration rates especially higher than 13ml/kg/h. Previous studies have focused on the impact of HD on peak strain values and however, the potential influence of HD on the temporal characteristics of deformation has not been reported yet. Thus, we aimed to evaluate the impact of high ultrafiltration rate on right ventricular (RV) mechanical dyssynchrony.

Methods: Echocardiographic images focused on RV and left ventricle (LV) were obtained from 60 patients (49.2±17.3y, 22 f) before and after HD. Patients were divided into two groups according to ultrafiltration rate. Changes in echocardiographic parameters with HD were examined. 2D speckle tracking strain analysis was used to assess deformation. Mechanical dispersion was measured as the standard deviation of time to peak longitudinal strain of 6 segments for RV and 18 segments for LV.

Results: The average ultrafiltrated volume and ultrafiltration rate were 3000.12±1007.9 ml and 11.4±2.9ml/kg/h, respectively. Global longitudinal strain (GLS) of RV and LV decreased after HD in both groups. A significant difference was observed in RV mechanical dispersion with HD for patients in the high ultrafiltration group. A mild statistically insignificant increase in LV mechanical dispersion was also observed after HD.

Conclusion: High ultrafiltration rates have a substantial impact on LV and RV GLS and RV dyssynchrony. Ultrafiltration rates and volumes should be kept as low as possible to achieve hemodynamic stability and tolerability.

ID: 149

Topic: **Cardiology » Preventive Cardiology**Presentation Type: **Oral****SIMPLE ECHOCARDIOGRAPHIC PARAMETER RELATED TO AGING:
DESCENDING AORTIC CONTINUOUS WAVE DOPPLER SYSTOLIC PEAK
GRADIENT****Onur Argan***Balikesir University Medical Faculty, Balikesir, Turkey***Corresponding Author (onur_argan@yahoo.com)**onur_argan@yahoo.com***Abstract Text**

Objective: Aging is the largest risk factor for cardiac diseases and the frequency of these diseases grows significantly with increasing age. Useful and basic parameters related to cardiovascular aging may help us to understand cardiac pathophysiology and prevention of cardiac disorders.

Aortic continuous wave (CW) doppler is an indispensable parameter in aortic coarctation patients. However, this parameter can be used in other areas and there is not enough article about this. The aim of this study is to investigate a possible relationship between descending aortic CW doppler systolic peak gradient and age related illnesses.

Methods: The study group was composed of 372 people. Aortic coarctation patients and participants under 18 years old were excluded from the study. CW doppler measurements from suprasternal window at supine position were recorded with the cursor parallel to main flow of direction in descending aorta. Descending aortic CW systolic peak gradient was obtained from all participants, and correlations were evaluated between participant characteristics, echocardiographic, biochemical parameters and age.

Results: When descending aortic CW doppler systolic peak gradient was analyzed, there were negative correlations with age ($r = -0.499$, $p < 0.001$); creatinine ($r = -0.217$, $p < 0.001$); urea ($r = -0.289$, $p < 0.001$); HbA1c ($r = -0.252$, $p < 0.001$); left ventricle end diastolic diameter ($r = -0.188$, $p < 0.001$); left ventricle end systolic diameter ($r = -0.200$, $p < 0.001$); interventricular septum diameter ($r = -0.259$, $p < 0.001$); posterior wall diameter ($r = -0.248$, $p < 0.001$); left atrium ($r = -0.272$, $p < 0.001$); pulmonary artery pressure ($r = -0.217$, $p < 0.001$); e/e' ratio ($r = -0.185$, $p < 0.001$) and positive correlations with estimated glomerular filtration rate (Cockcroft-Gault mL/dk) ($r = 0.395$, $p < 0.001$), ejection fraction ($r = 0.266$, $p < 0.001$). In Mann Whitney U test, descending aortic CW doppler systolic peak gradient was significantly lower in hypertension ($p < 0.001$); coronary artery disease ($p < 0.001$); atrial fibrillation ($p < 0.001$); and systolic heart failure patients ($p < 0.001$) when compared to those without these diseases. In stepwise linear regression analysis, significant independent correlates of descending aortic CW doppler systolic peak gradient was only age ($p < 0.001$).

Conclusion: Aortic CW doppler is usually used for evaluation of aortic coarctation, but this parameter is also independently related to aging and it might be useful for evaluation of age-related cardiovascular diseases. Decreasing descending aortic CW doppler systolic peak gradient measurements can be easily feasible in clinical practice and it might be useful for risk scoring.

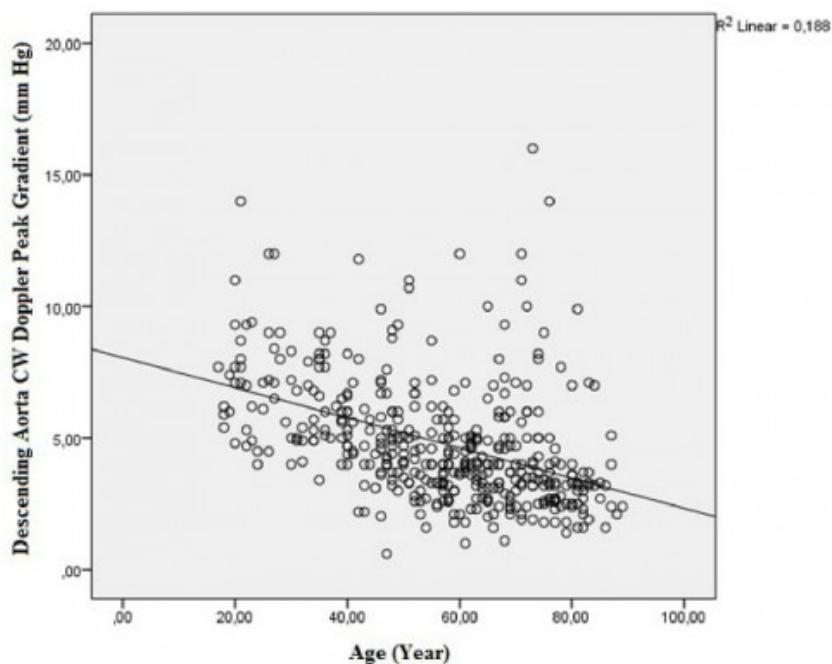


Figure 1: Relationship between descandan aortic CW doppler peak gradient and age.

Biochemical parameters correlated CW doppler descandan aortic peak gradient

Age (year)	Spearman Correlation	-0.499
	Sig. (2-tailed)	<0.001
eGFR (Cockcroft-Gault mL/dk)	Spearman Correlation	0,395
	Sig. (2-tailed)	<0.001
Urea (mg/dl)	Spearman Correlation	-0.289
	Sig. (2-tailed)	<0.001
Creatinine (mg/dl)	Spearman Correlation	-0,217
	Sig. (2-tailed)	<0.001
Hba1c (mmol/mol)	Spearman Correlation	-0.252
	Sig. (2-tailed)	<0.001

Echocardiographic parameters correlated with descandan aortic CW doppler peak gradient

EF (%)	Spearman Correlation	0,266
	Sig. (2-tailed)	<0.001
LVEDD (mm)	Spearman Correlation	-0,188
	Sig. (2-tailed)	<0.001
LVESD (mm)	Spearman Correlation	-0,200
	Sig. (2-tailed)	<0.001
IVSd (mm)	Spearman Correlation	-0,259
	Sig. (2-tailed)	<0.001
PWd (mm)	Spearman Correlation	0,248
	Sig. (2-tailed)	<0.001
LAd (mm)	Spearman Correlation	-0,272
	Sig. (2-tailed)	<0.001
PAB (mm Hg)	Spearman Correlation	-0,217
	Sig. (2-tailed)	<0.001
E/e'	Spearman Correlation	-0,185
	Sig. (2-tailed)	<0.001
e' (cm/sn)	Spearman Correlation	0,402
	Sig. (2-tailed)	<0.001

ID: 280

Topic: Cardiology » Cardiac Imaging - Cardiac CT

Presentation Type: Oral

LEFT ATRIAL APPENDAGE THROMBUS EXCLUSION BY CARDIAC COMPUTED TOMOGRAPHY IN PATIENTS UNDERGOING ABLATION OF ATRIAL FIBRILLATION: SINGLE CENTER EXPERIENCEMustafa Karaca, Fatma Kayaaltı Esin, **Aykan Çelik**, Tuncay Kırış*İzmir Atatürk Training and Research Hospital, İzmir, Turkey***Corresponding Author (mustafakaraca99@hotmail.com)**mustafakaraca99@hotmail.com, dr.fatmakesin@gmail.com, draykancelik@windowslive.com, drtkiris@hotmail.com***Abstract Text**

Introduction: Atrial fibrillation (AF) is one of the most common cardiovascular disorders which is associated with significant morbidity, including cardio-embolic stroke and heart failure. Catheter ablation of AF is indicated for most patients with symptomatic paroxysmal and persistent arrhythmia. Presence of thrombus should be excluded before catheter ablation to prevent embolization. The optimal strategy for ruling out thrombus in the left atrial (LA) LA appendage (LAA) before catheter ablation is unclear. Transesophageal echocardiogram (TEE) is considered the gold standard modality to exclude LA/LAA thrombi in patients with AF. Computed tomography angiography (CTA) is commonly used to evaluate pulmonary vein anatomy before left atrial ablation for AF. It has been shown that there is growing evidence suggesting that CTA could be a noninvasive alternative to TEE for the exclusion of LAA thrombus in patients who are already having a CTA to evaluate pulmonary vein anatomy before ablation. We aimed to evaluate the diagnostic accuracy of cardiac computed tomography assessing LA/LAA thrombi in comparison with TEE in these patients.

Methods: 60 patients with AF underwent both 128-section cardiac CT angiography and TEE were enrolled in this study. Demographics, and clinical risk factors, were analysed. The patients were divided into two groups; patients with thrombus or without thrombus.

Results: 60 patients with AF were included in this study. In ten patients, thrombus was seen (16.6%). The rate of CHA2DS2-VASC score > 2 was more common in patients with thrombus compared with those without thrombus (60% vs 18%, $p = 0.005$). The concordance between LAA thrombus detection with 128-section cardiac CT angiography and that with TEE was high: Fifty patients had no thrombus at either CT or TEE; 9 patients had a thrombus at both CT and TEE; and one patient had a thrombus at TEE but not at CT (overall $K = 0.937$)

Conclusions: 128-section cardiac CT angiography is a noninvasive sensitive modality to exclude LA/ LAA thrombi in patients with AF.

Table 1. Baseline characteristics of the study population.

Variable	No Thrombus	Thrombus (+)	P-value
Age (years)	54.3 ± 11	57.3 ± 8	0.435
Female n (%)	24 (48)	7 (70)	0.034
Hypertension n (%)	23 (46)	6 (60)	0.065
Diabetes mellitus n (%)	10 (20)	4 (40)	0.003
Stroke history n (%)	0 (0)	0 (0)	
History of heart failure n (%)	2 (4)	1 (10)	0.427
Vascular disease n (%)	0 (0)	4 (40)	0.001
LVEF (%)	60 ± 3	58 ± 6	0.213
CHADSVASC score > 2	9 (18)	6 (60)	0.005

Abbreviations: LVEF; left ventricular ejection fraction.

Table 2. Concordance between CT and TEE in predicting thrombus in left atrial appendage.

CT finding	TEE finding	TEE finding
CT finding	Thrombus	No thrombus
Thrombus	9	0
No thrombus	1	0

Oral Presentation Session

New Solutions in Vascular Surgery

Date: 27.03.2019 Time: 11:45 - 12:45 Hall: 6

ID: 62

Topic: Cardiovascular Surgery » Peripheral Artery Disease and Treatment

Presentation Type: **Oral**

LONG-TERM OUTCOMES AFTER PERCUTANEOUS LOWER EXTREMITY ARTERIAL INTERVENTIONS WITH ATHERECTOMY VS. BALLOON ANGIOPLASTY

Orhan Rodoplu¹, Mihriban Demir²

¹Private Yalova Hospital, YALOVA, Turkey

²Ordu Government Hospital, ORDU, Turkey

**Corresponding Author (orhanrodoplu@yahoo.com.tr)*

orhanrodoplu@yahoo.com.tr, mihribandemir33@hotmail.com

Abstract Text

Objective: The impact of endovascular revascularization of the lower extremity arteries with atherectomy (AT) compared with percutaneous transluminal angioplasty (PTA) is still unclear. Therefore, the aim of the study was to compare long-term outcomes after percutaneous PTA and AT in patients requiring endovascular revascularization.

Methods: The study included 425 patients with symptomatic peripheral arterial disease between May 2014 and May 2016. This was done by multicentre, retrospective records of obstructive and symptomatic PAD patients undergoing endovascular revascularization.

PTA was performed in 215 patients and 204 patients underwent Aterectomy with the Jetstream PV Aterectomy System (Pathway Medical Technologies, Redmond, WA, USA).

There was no significant difference between the baseline characteristics except for the prevalence of increased CAD, dialysis and Critical Leg Ischemia (CBI) in the PTA group.

Results:

Post-procedure stenting requirement was more frequent in the reference group (PTA, 6.1% and AT, 0%; $P = 0.004$). There was no difference in the HLR between the groups at the 6- and 12-month follow-up (PTA, 8.3% vs AT, 5.3%; $P = 0.47$; PTA, 16.7% vs AT, 13.7%; $P = 0.73$). , respectively).

In the 24-month follow-up, the difference in target lesion revascularization (HLR) was in favor of AT (PTA, 29.0% and AT, 16.7%; $P = 0.05$).

No difference was observed in amputation rates (PTA, 0.7% vs AT, 1.5%; $P = 0.62$).

In the Kaplan-Meier analysis, there was no significant difference between groups in terms of TLR, amputation or death.

The present study reports a direct observational comparison of PTA with a single type of AT device. Although there are some differences in the initial characteristics of the patient in favor of the EC group, the PTA group has a lower requirement for stenting after the procedural procedure.

PTA group required more stenting due to current limiting dissection In the long-term follow-up, there was no difference in the amputation rate, but the EC group had a significantly lower HLR in the 24-month follow-up.

In our study, the number of patients with diabetes is quite high.

End-stage renal disease, Critical Leg Ischemia and chronic total occlusion were more frequent in the PTA group, thus increasing the risk level for complications.

However, the complication rate was low in both groups.

All patients in this record were also pharmacologically treated to reduce the risk of major cardiovascular side effects. Cilostazol was added to the treatment and dual antiplatelet therapy (DAPT) of almost all present patients was composed of clopidogrel (75 mg) and once daily, on acetylsalicylic acid (81 mg).

DAPT was prescribed because it significantly increased the risk of acute or subacute thrombosis, as it could be exposed to blood flow after intima-media AT (33).

Conclusions: In summary, when we evaluate the results of long-term EC, this study is multifactorial compared to PTA alone.

In addition to the aforementioned studies, as shown by this study, plate modification and removal with AT provides a more predictable and stable result with less post-procedure stenting requirement rates.

In addition, post-TAT vascular damage may be lower compared to PTA, resulting in increased vascular response and neointimal hyperplasia, thus turning into a lower HLR at follow-up.

Patients with lower extremity PAD were associated with a lower long-term risk of stenting and a lower HLR ratio compared to PTA.

Nevertheless, this should be confirmed in randomized controlled trials.

ID: 288

Topic: **Cardiovascular Surgery » Peripheral Artery Disease and Treatment**Presentation Type: **Oral****BRANHAM'S SIGN: BEYOND A BRADYCARDIA****Rukiye Derin Atabey, Yigit Akcali***Erciyes University, Kayseri, Turkey***Corresponding Author (rukiyeatabey@hotmail.com)**rukiyeatabey@hotmail.com, yigitakcali@gmail.com***Abstract Text**

OBJECTIVE. Branham's sign, an acute bradycardia in response to manual compression of an arteriovenous fistula (AVF), is well known among cardiovascular surgeons (some label this finding as the "Nicoladoni sign" or "Nicoladoni-Israel-Branham sign"). Branham's bradycardic reaction has been considered as a standard test that may provide important clinical information on the hemodynamic significance of an AVF. The hemodynamic changes induced by Branham's test, temporary AVF occlusion, may be important predictors of the favorable cardiac effects of a surgical AVF closure. We analyzed the point-of-care results of Branham's sign.

METHODS. In the last decade, 21 patients with traumatic arteriovenous fistula (TAVF), five of whom were women, with median age of 39 years (range, 10 months to 70 years) were evaluated. The rate of TAVFs among vascular injuries was 16.5%. Congenital arteriovenous malformations were not included in the study. Branham's test and point-of-care duplex ultrasonography were also added to the clinical assessment of the patients except for computed tomography or digital subtraction angiography, which provides a more definitive diagnosis of the AVF (Video 1, Figure 1). The bradycardia produced by digital closure of a proximal artery into the AVF was considered as positive Branham's sign (Video 2).

RESULTS. Most of the injuries were located on the right side and the lower extremity (respectively, 66.6% and 90.4 %). The rate of fistulous aneurysm was 14.3% (figure 1). Four patients had documented pulmonary hypertension (19.0%). All patients except one were treated surgically (Figure 1). Branham's sign was positive in 52.4% of the patients who could be tested. The mean heart rate, which was 74.7 bpm (range, 60 to 90 bpm), decreased to mean 48 bpm (range, 42 to 64 bpm) after the test.

CONCLUSIONS. Branham's sign may be not positive in acute AVFs where clinical picture is not always characteristic. Moreover, failure of a patient to exhibit Branham's sign may suggest an impairment of cardiac baroreflex control.

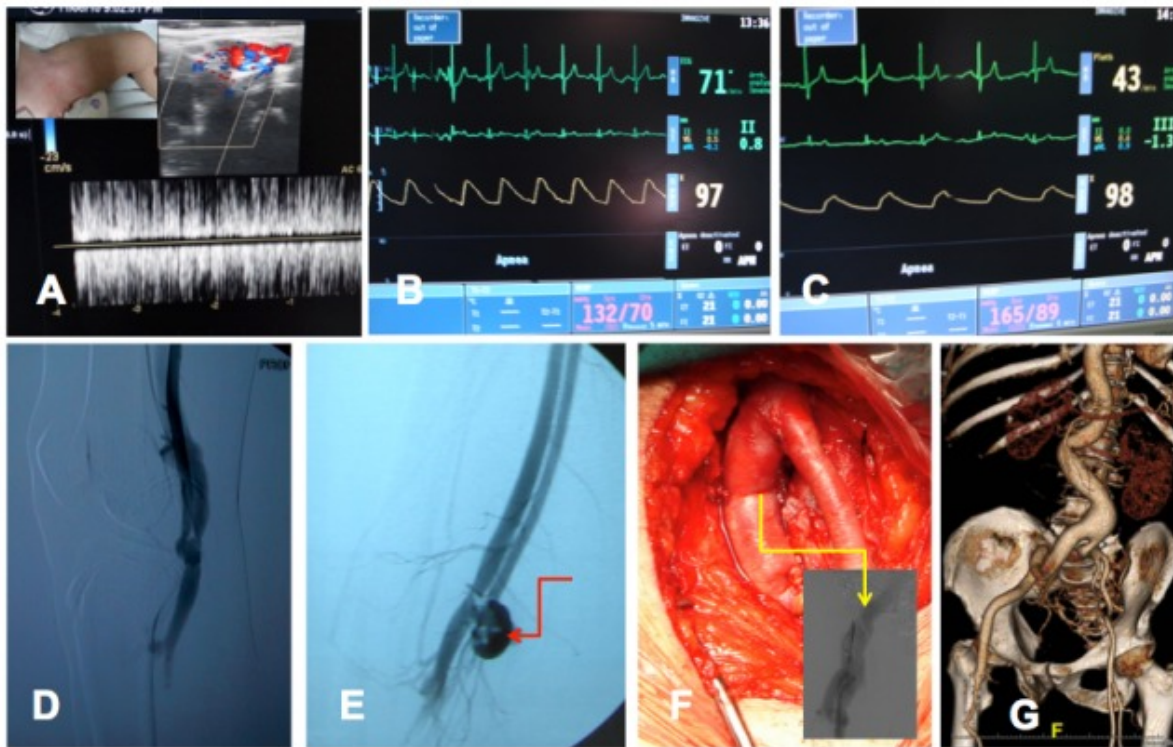


Figure 1. A point-of-care duplex ultrasound spectral exam performed in a 10-month-old child shows high-velocity, low-impedance flow (A); monitored Branham's sign in a 42-year-old male patient with femoral arteriovenous fistula (AVF) (B, C). Note the decrease in heart rate and increase in blood pressure following closure of the AVF (C); An angiography showing a pre-fistulous tortuosity and post-fistulous thinning of arteries in a 39-year-old patient with popliteal arteriovenous fistula (D); A DSA demonstrating a fistulous aneurysm (arrow)(E); The surgical field of a 44-year-old patient with femoral arteriovenous fistula (F), and his angiography which shows dilatation of arteries (small picture). Note apparent dilatation of femoral arteries as compared with contralateral femoral arteries in the same patient (G).

ID: 135

Topic: **Cardiovascular Surgery » Peripheral Arterial Disease**Presentation Type: **Oral****COMPARISON THE IMPACT OF ASETYLSALICYLIC ASID AND CLOPIDOGREL ON ARTERIOVENOUS FISTULA EARLY PRIMARY PATENCY AT PATIENTS WITH END STAGE RENAL DISEASE****Mehmet Şenel Bademci***Istanbul Medeniyet University, Istanbul, Turkey***Corresponding Author (mbademci@gmail.com)**mbademci@gmail.com***Abstract Text****Comparison the Impact of Asetylsalicylic Asid and Clopidogrel on Arteriovenous Fistula Early Primary Patency at Patients With End Stage Renal Disease**

Objective: This retrospective study was aimed to investigate the effects of asetylsalicylic asid and clopidogrel on arteriovenous fistula early primary patency at patients with end stage renal disease.

Methods: Patients with end stage renal disease who underwent distal radiocephalic arteriovenous operation and had perioperative medication of asetylsalicylic asid or clopidogrel due to coronary artery disease or peripheral artery disease were included in the study. 64 patients had been constructed distal radiocephalic arteriovenous fistula between January 2018 and October 2018 by only one vascular surgeon. All patients had preoperative arterial and venous duplex ultrasound mapping which were performed by the same vascular surgeon. Physical examination and control duplex ultrasound evaluation were performed in the post-procedural 1st week and month. One month primary patency and adwers events were examined and compared between two groups.

Results: The mean age of the patients was 55 (40-70) and 36 (56.2%) of them were male. One month primary patency rates were 67.6% (n=23) versus 66.6% (n=20) at asetylsalicylic asid and clopidogrel groups, respectively. In asetylsalicylic asid group the hematoma were observed in 2 (5.8%) patients and in clopidogrel group was detected in 5 (16.6%) patients. No other serious early complications were observed. Two groups had similar one month primary patency rate but hematoma complication was significantly higher in the clopidogrel group.

Conclusions: Perioperative asetylsalicylic asid or clopidogrel medication has no impact on one month patency rate of distal radiocephalic arteriovenous fistula in patients with end stage renal disease but asetylsalicylic asid has a low incidence of postoperative adverse events.

ID: 544

Topic: **Cardiovascular Surgery » Peripheral Arterial Disease**Presentation Type: **Oral****ARTERIOVENOUS FISTULAS IPSILATERAL TO INTERNAL JUGULAR CATHETERS FOR HEMODIALYSIS HAVE DECREASED PATENCY RATES**Berkan Ozpak¹, Yeliz Yılmaz², Aykut Şahin³¹*Çorlu State Hospital, Tekirdag, Turkey*²*Izmir Katip Celebi University, İzmir, United States*³*Osmangazi University, Eskişehir, United States***Corresponding Author (berkanozpak18@gmail.com)**berkanozpak18@gmail.com, dryelizyilmaz@yahoo.com, draykutsahin@gmail.com***Abstract Text**

Purpose: This study aimed to evaluate the effects of hemodialysis catheters on the survival of subsequent arteriovenous fistulas, according to the relative localization to the catheters.

Methods: A total of 201 patients who initiated dialysis therapy using a hemodialysis catheter were eligible for this retrospective study. Arteriovenous fistulas were created on the nondominant upper extremity after the placement of hemodialysis catheters. The catheters were removed after four consecutive successful dialyses via arteriovenous fistulas. The effective factors on arteriovenous fistula failure were determined in and the prognostic factors for survival were modeled by regression analysis.

Results: The relative placement of catheters as ipsi- or contralateral was found to significantly affect the survival of the AVFs. The overall survival was significantly longer in the contralateral arteriovenous fistula group (778.7±28.8 vs. 247.3±26.1 days; p<0.001). The independent predictors of AVF survival were found to be relative side of AVF and hemodialysis catheter, age, and the presence of hypertension in multivariate analyses.

Conclusion: This study showed that ipsilateral localization of the catheters and arteriovenous fistulas negatively affect the cumulative arteriovenous fistula survival. Therefore, to improve vascular access survival, side of catheters or arteriovenous fistulas should always be considered.

ID: 5

Topic: **Cardiology » Interventions for Peripheral Arterial Diseases**

Presentation Type: **Oral**

**A RESEARCH FOR PREDICTIVE VALUE OF HEMOGRAM PARAMETERS
AT LATE TERM ARTERIOVENOUS FISTULA THROMBOSIS
FORMATION**

Gökmen Akkaya, Çağatay Bilen

Ege University, Izmir, Turkey

**Corresponding Author (akkayagokmen@gmail.com)*

akkayagokmen@gmail.com, cagataybilen86@gmail.com

Abstract Text

Objective: This study aims to assess the relation between late term arteriovenous fistula thrombosis and alteration in hemogram parameters before thrombosis occurrence in hemodialyses patients with end-stage renal failure.

Methods: Data of three hemodialyses centers in our city was evaluated retrospectively. The results of hemogram values before thrombosis formation at first and third month in 14 re-operated patients between March - September 2017, owing to late term fistula thrombosis occurrence, who previously had a successful fistula access, were compared to 73 patients still having hemodialysis therapy via fistula access.

Results: When hemogram results of groups were examined statistically significant increments were measured all in neutrophile lymphocyte ratio (NLR), red blood cell distribution width (RDW), mean platelet volume (MPV), platelet distribution width (PDW) parameters in fistula thrombosis occurred patients compared to control group and their previous results before thrombosis formation. Therewithal, there was no significant relation found among thrombosis formation and other parameters in hemogram.

Conclusion: Herein, it's determined that a profound examination of hemogram has a predictive value for late term fistula thrombosis in hemodialyses patients.

ID: 332

Topic: **Cardiovascular Surgery » Peripheral Artery Disease and Treatment**Presentation Type: **Oral****TREATMENT OF LYMPHATIC MALFORMATIONS: HOW, TO WHOM, AND WHEN SHOULD BE MADE?**

Yigit Akcali, Rukiye Atabey, Aydin Tuncay

*Erciyes University, Kayseri, Turkey***Corresponding Author (yigitakcali@gmail.com)**yigitakcali@gmail.com, rukiyeatabey@hotmail.com, atuncay@erciyes.edu.tr***Abstract Text**

OBJECTIVE. Lymphatic malformations (LMs), result from abnormal development of the lymphatic channels, are one of the most common forms of congenital vascular malformations (CVMs) when you should include both truncular (T-LMs) and extratruncular (ET-LMs) lesions according to the new Hamburg classification (Table I). Both are consequences of a developmental arrest at the different stages of embryonal life as a result of defective genes. The aim of this study was to evaluate the current treatment results of LMs.

Table I. Lymphatic malformations according to Hamburg Classification (1988)

Truncular form (T-LM)*: Primary lymphedema (LE)		
Clinical		Pathological
	*Age of onset (year)	Aplasia or Obstruction
LE congenita	(* <1)	Familial (Milroy disease) and nonfamilial
LE praecox	(* 1-35)	Familial (Meige disease) and nonfamilial
LE tarda	(* >35)	Dilatation
		Hypoplasia or aplasia
		Hyperplasia
		Localized (aneurysm)
		Diffuse (ectasia)
Extratruncular form (ET-LM)**		
Microcystic	("Lymphangioma")	<2 mL (< 1 cm in diameter)
Macrocytic	("Cystic higroma")	≥2 mL (> 1 cm in diameter)
Combined		
		Diffuse, infiltrating
		Limited, localized

*Outcome of the lack of proper development of new axial/truncal lymphatic vessel, due to the developmental arrest during "the latter stage" of lymphangiogenesis. Aplasia, hypoplasia, hyperplasia, obstruction, or dilatation of lymphatic vessels and/or lymph nodes: congenital and/or primary lymphedema (*praecox* or *tarda*); ** 'Premature' embryonic tissue which is supposed to be involute but remained through the rest of life, due to the developmental arrest in "earlier stage" of lymphangiogenesis: cystic/cavernous lymphangioma.

METHODS. A retrospective review of the clinical data of 186 patients (female/male=96/90) with a median age of 9 years (range, 2 days to 80 years) who had been treated with the diagnosis of LM in the last decade was performed. Ultrasound, lymphoscintigraphy, and MRI were frequently used diagnostic tests. The patients with ET-LM were treated with sclerotherapy and/or surgical excision. Combinations of complex decongestive physiotherapy (CDP) and/or compressotherapy were used to treat all the T-LM patients (Figure 1). The results of LM management were evaluated twice a year.

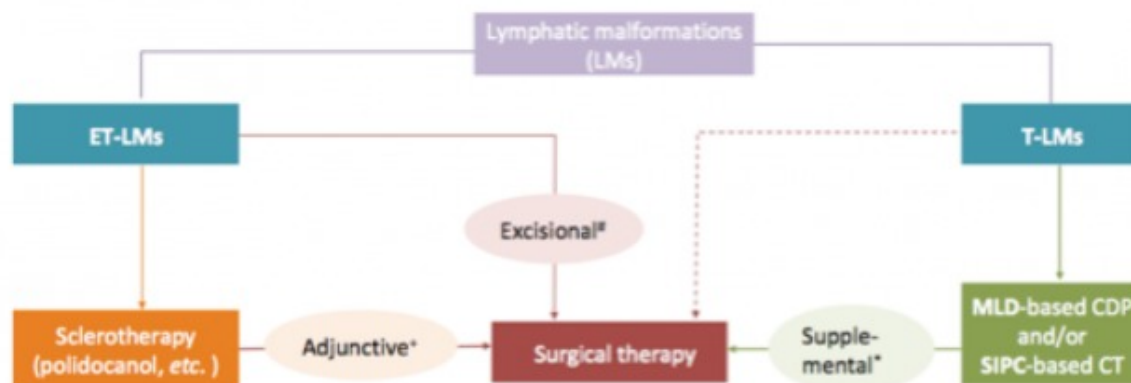


Figure 1. Therapeutic algorithm for lymphatic malformations. *Although the traditional role of surgical (excisional) treatment as independent therapy has been limited, it remained pivotal in our patients with macrocystic with septa and microcystic ET-LM, and HLM. †The surgical therapy, incorporated to the multidisciplinary approach provides significant improvement of the results mostly with pre- & post-operative adjunctive sclerotherapy. *Surgical therapy is performed as supplemental therapy to the non- to poor- response LM of CDP and/or CT. LM, lymphatic malformation; T, truncular; ET, extratruncular; HLM, hemolymphatic malformation; MLD, manual lymphatic drainage; CDP, complex decongestive physiotherapy; SIPC, sequential intermittent pneumatic compression; CT, compressotherapy.

RESULTS. Among total 1312 patients with CVM, 186 were confirmed to have LMs, either as the T-LM (n=114, 64.2%) or the ET-LM (n=72, 35.8%) (Table II). Eleven patients had both truncal and ET forms (Figure 2). Another 38 (20.3%) LMs were diagnosed with hemolymphatic malformations (HLM) (Figure 3). The T-LMs were located to the extremities, mostly to the lower extremity (86.8%), and they included lymphatic aplasia and/or obstruction (76.3%). Most of the ET-LMs were the cystic type (91.6%). The ET-LMs were most frequent in the extremities and axillary-cervicofacial region (75.6%). ET-LMs were treated with sclerotherapy (~37%) and/or surgical excision (30.1%)(Figure 4). The ET-LMs in patients undergoing surgery located to extremity (72.7%), trunk (22.7%), axillary fossa (13.6%), buttocks (4.5%), and retroperitoneum (4.5%)(Video 1). Transcutaneous radiofrequency ablation (TRFA) was performed in three patients. A patient with HLM was followed by aspiration and compression. The clinical response of the T-LMs at the extremity to CDP was good (Figure 5).

Table II. The location of the lesions (n=186 patient, female=96, male=90): median age, 9 years (range, 2 days to 80 years).

	Cervico-facial	Axillary	Extremity [†]	Truncal ^{**}	Visceral	Gluteal	Genital [‡]	Total
LM [†]	29 (13.8%)	9(4.3%)	145 (68.7%)	10(4.7%)	4 (1.9%)	7 (3.3%)	7 (3.3%)	211 (100%)
Male	17 (58.6%)	5 (55.6%)	65 (44.8%)	8 (80%)	2(50%)	3 (42.8%)	7(100%)	107(50.7%)
Female	12 (41.4%)	4 (44.4%)	80(55.2%)	2 (20%)	2(50%)	4 (57.2%)	0	104(49.3%)

[†] It included 72 extratruncular (ET-LM) and 114 truncular form (T-LM), 38 (20.3%) of them were hemolymphatic malformation, combined form of LM (HLM) with VM. †Most of them were in lower limb (80.7%); One of them was quadrilateral (0.9%); One of the *upper extremities* (n=19) was bilateral (4.3%); Thirteen of the *lower extremities* (n=90) were bilateral (~15%); **the axillary fossa (n=3) and upper extremity (n=3) was concomitantly involved in five of them; ‡ all of the genital LMs involved the scrotum and, all except one had a primary lymphedema of lower extremity, bilateral in three. LM, lymphatic malformation; VM, venous malformation.

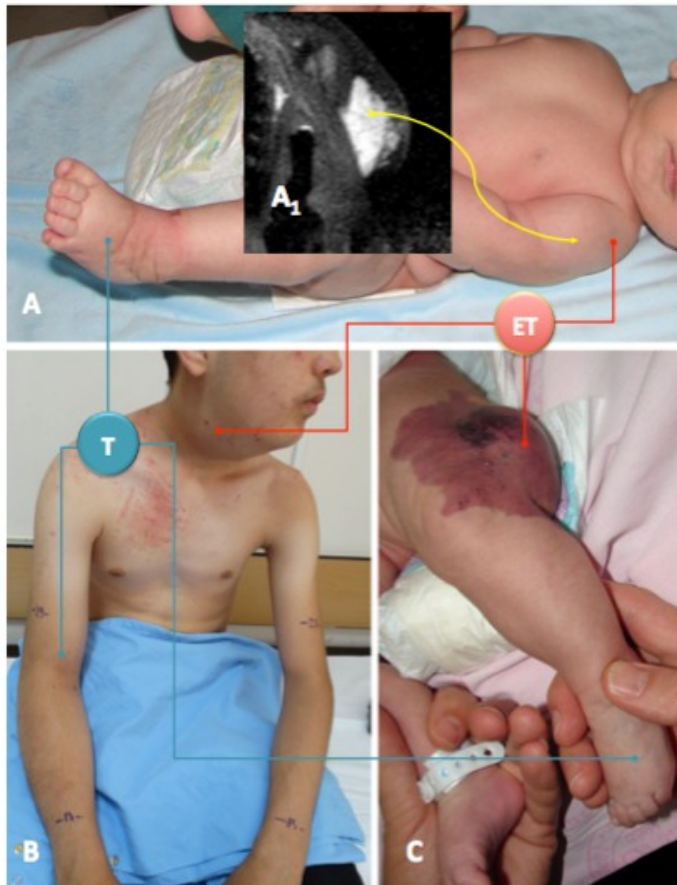


Figure 2. The samples of patients with combined T-LM and ET-LM, which may coexist affecting each other lymphodynamically: the left leg and the arm (A), the right arm and the neck (B), and the left leg and the thigh (C). The small picture shows a MR sequence showing humeral cystic LM (A₁). T, truncular; ET, extratruncular; LM, lymphatic malformation.

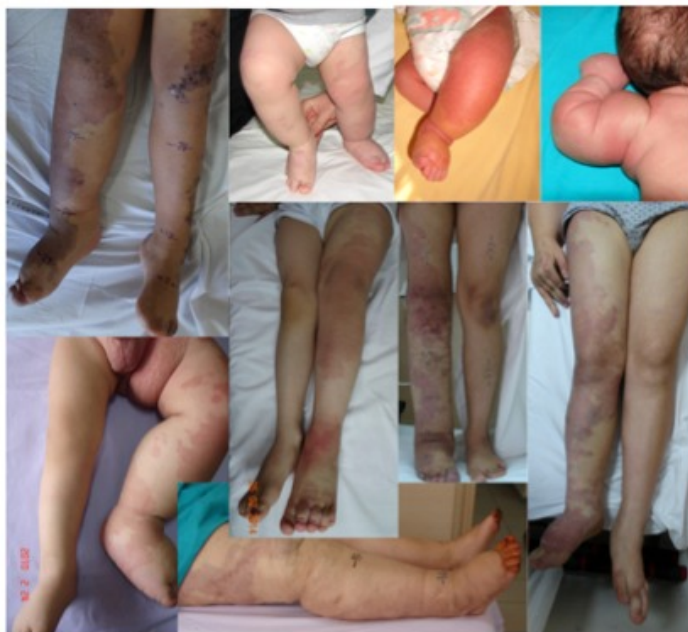

Figure 3. Lymphatic malformations may exist alone as independent (predominant) vascular defect or combined with other congenital vascular malformations such as capillary malformation, venous malformation and/or arteriovenous malformation knowing as hemolympathic malformations (HLMs). Figure shows some samples of these patients with HLM.

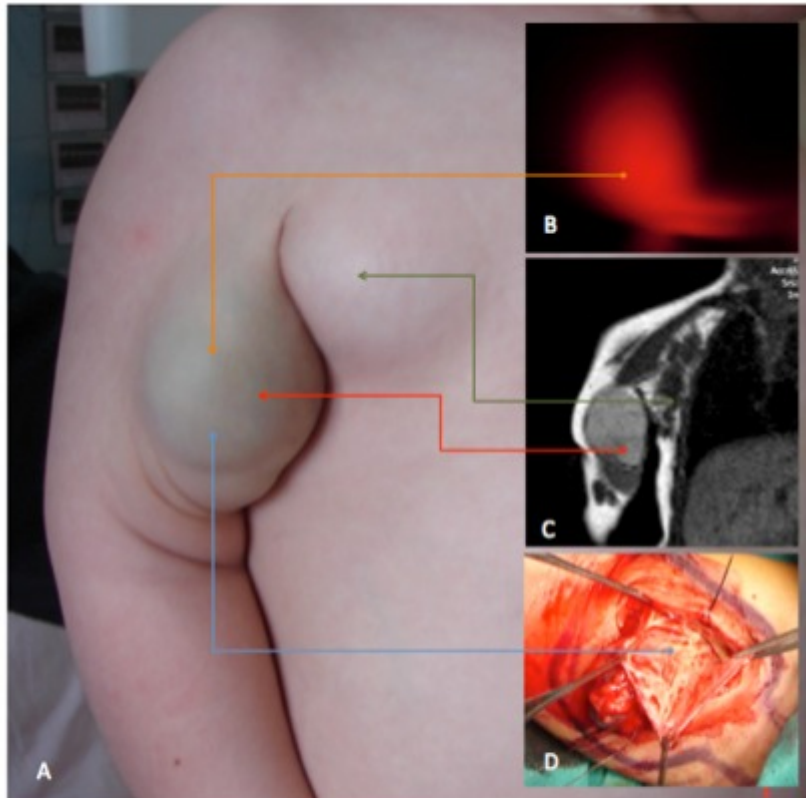


Figure 4A. Lymphatic malformation (LM) in a 3-year-old infant with a swollen mass in the arm and axilla (A). Images of a translucency (B), a MR sequence (C) and an interior appearance of the macrocystic LM in surgical field (D) are related to the same patient. Note the fluid-fluid level in the cyst, may be seen if complicated by hemorrhage (red elbow arrow).

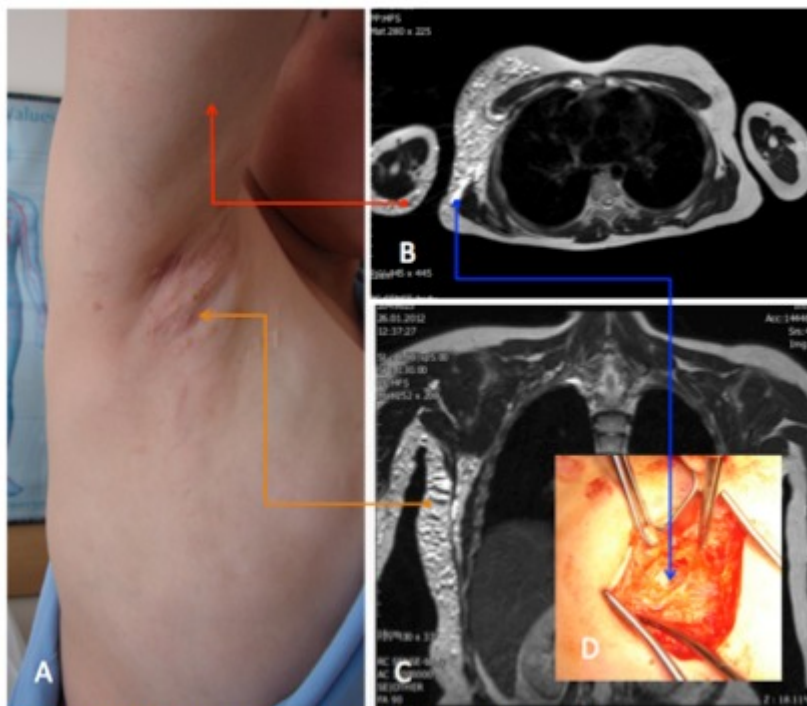


Figure 4B. A 14-year-old adolescent with diffuse axillary, truncal, extremity lymphatic malformation (A). The appearance of LM in MR sequences (B, C) and surgical field (D).

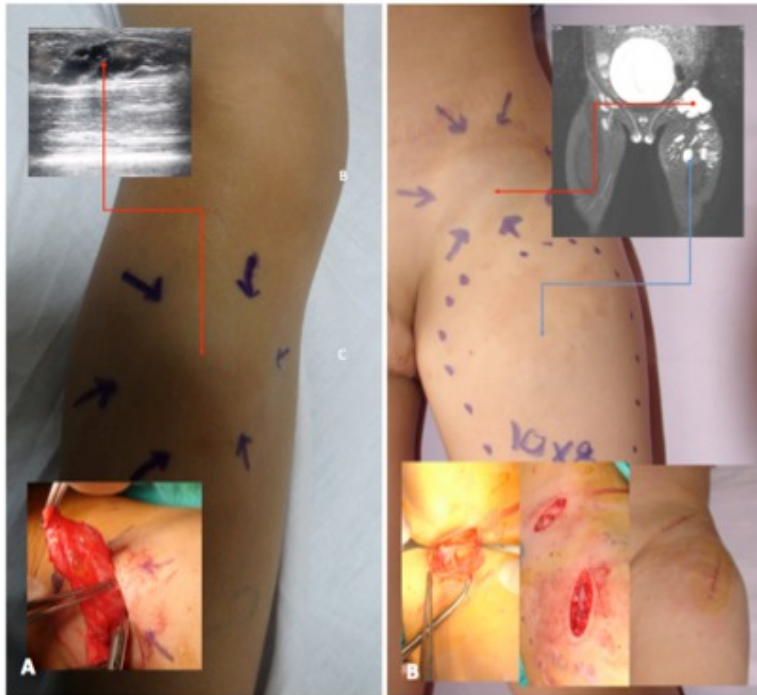


Figure 4C. Two different samples to the operative management of extremital ET-LMs presenting as diffuse (blue elbow arrow) and limited lesions (A, B). Note to smaller skin incisions as compared with the lesion for cosmetic reasons.

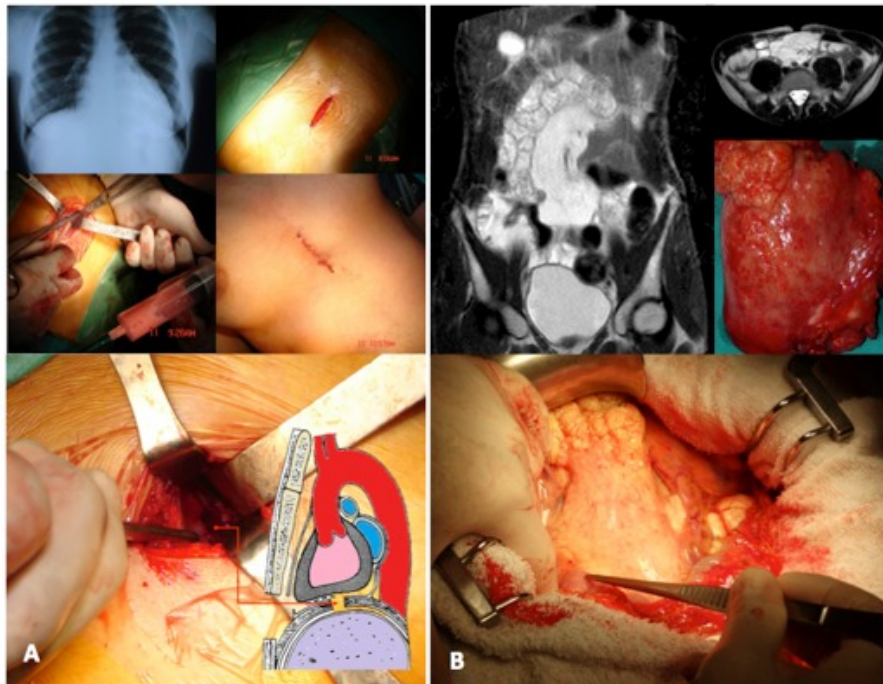


Figure 4D. Two different patient samples to the operative management of visceral ET-LMs presenting as chylopericardium and abdominal pain. The first was a 20-year-old female patient with hemolympathic malformation. A pericardio-peritoneal window was made through a cosmetic subxyphoid incision as a permanent solution in this patient, which had recurrent pericardial chylous effusion despite repeated pericardiocentesis (A). The second patient was a 22-year-old male with atypical postprandial abdominal pain, nausea, vomiting, and weight loss. MRI showed large, multicystic lesion in paraaortic area. The approach by midline laparotomy allowed total LM mass resection without any bowel resection except appendectomy (B).

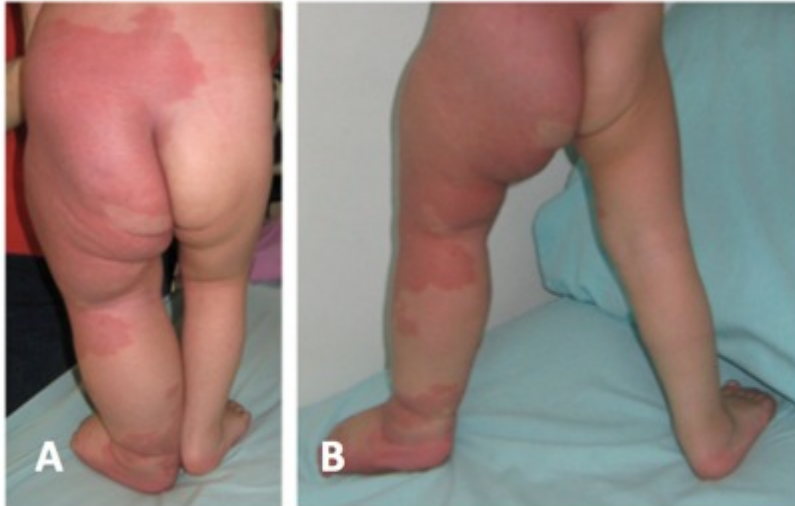


Figure 5. Clinical presentation of a patient with T-LM as a component of the KTS: Pre-CDP (A) and early post-CDP (B). Note the capillary malformation presenting as port-wine stain, which is another component of the KTS. T-LM, truncular lymphatic malformation; KTS, Klippel-Trénaunay syndrome; CDP, complex decongestive physiotherapy.

CONCLUSION. The multimodal management of LMs will continue to develop as new knowledge about the molecular biology and genetics of these complicated lesions is discovered, along with data obtained from clinical practice. For optimum results, a patient-centered multidisciplinary medical and surgical team approach should guide modality and timing of treatment, which includes surgery, sclerotherapy with various scleroagents, TRFA, CDP, drug therapies such as sirolimus, and observation. The main objective of all these treatments should be to improve and optimize LM patients' quality of life.

ID: 85

Topic: Cardiovascular Surgery » Peripheral Artery Disease and Treatment

Presentation Type: Oral

PYODERMA GANGRENOSUM TRIGGERED BY ACUTE ISCHEMIA OF LOWER EXTREMITY

Mehmet Kalender

Kocaeli Derince Training and Research Hospital, Kocaeli, Turkey

**Corresponding Author (ka97084@yahoo.com)*

ka97084@yahoo.com

Abstract Text

Introduction

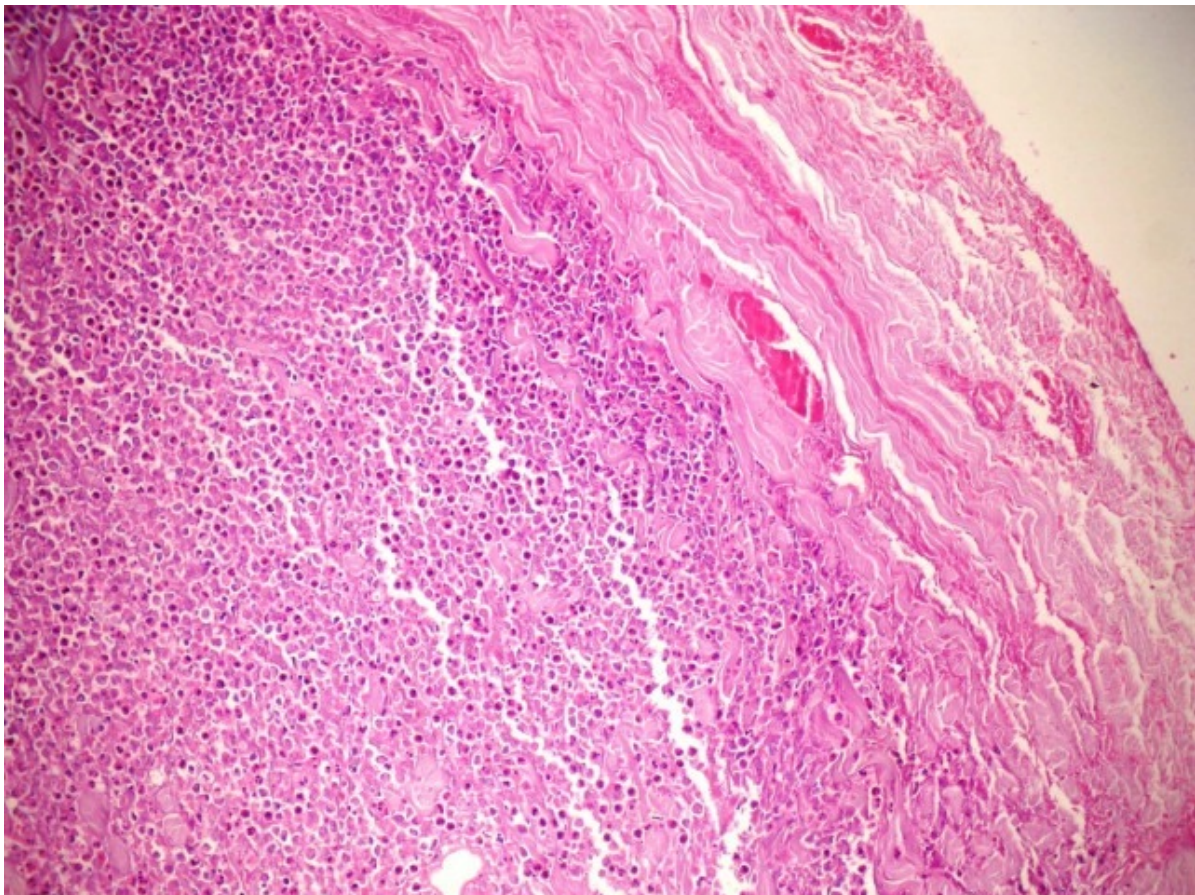
Pyoderma gangrenosum is a very rare condition with an estimated incidence of 3 to 10 cases per million people per year of uncertain etiology. The diagnosis is made by excluding other causes of similar-appearing cutaneous ulcerations, including infection, malignancy, vasculitis, collagen vascular diseases, diabetes, and trauma. We report a case with pyoderma gangrenosum triggered by acute ischemia of lower extremity without a prior history.

Case

77 years old female patient admitted to emergency department with necrosis on left lower extremity anterior surface. Medical history revealed pain as the main complaint started 20 days ago; necrosis was observed 2 weeks ago. Digital subtraction angiography of lower extremity arterial tree revealed total occlusion of the left common femoral artery. Left femoral artery thrombectomy under local anesthesia performed to the patient and full flow was achieved. Postoperative 1st-morning massive hemorrhage occurred from the necrotic site. Under emergency conditions necrotic area was debrided, biopsies were taken. Pathology report of necrotic region debridement specimen revealed pyoderma gangrenosum. The patient was discharged on the 10th day and was treated with prednisone 48 mg daily for 30 days. Pyoderma gangrenosum represents a diagnostic challenge which requires many specialists to be involved.

Conclusion

During management of ischemic peripheral artery disease patients with resistant skin findings, pyoderma gangrenosum should be in differential diagnosis list.



Oral Presentation Session**Complications and Challenges in Coronary Bypass Grafting**

Date: 27.03.2019 Time: 13:00 - 14:30 Hall: 6

ID: 348

Topic: **Cardiovascular Surgery » Coronary Bypass Surgery**Presentation Type: **Oral****PREOPERATIVE URINARY PH IS ASSOCIATED WITH ACUTE KIDNEY INJURY AFTER CARDIAC SURGERY IN NON-DIABETIC PATIENTS****Naim Boran Tumer¹**, Atike Tekeli Kunt¹, Serdar Gunaydin¹, Kanat Ozisik¹, Orhan Eren Gunertem¹, Ali Baran Budak¹, Onur Karahasanoglu¹, Seyhan Babaroglu²¹*University of Health Sciences Ankara Numune Education and Research Hospital, Ankara, Turkey*²*29 Mayıs Devlet Hastanesi, Ankara, Turkey***Corresponding Author (naimborantumer@hotmail.com)**naimborantumer@hotmail.com, atikemd@gmail.com, serdarkvc@gmail.com, sozisik2002@yahoo.com, egunertem@yahoo.com, drbaranbudak@gmail.com, onurkarahasaoglu@gmail.com, babaroglus@yahoo.com***Abstract Text**

BACKGROUND: Acute kidney injury is a common complication of cardiac surgery that increases morbidity and mortality. The aim of the present study is to analyze the association of preoperative urinary pH with acute kidney injury after isolated coronary artery bypass graft surgery (CABG).

METHODS: We retrospectively reviewed the prospectively collected data of 270 adult non-diabetic patients who underwent isolated CABG surgery with normal renal function. The perioperative data of the patients included demographic data, laboratory findings, morbidity and mortality. The patient population was divided into four groups: group I: patients with preoperative urinary pH=5, group II: pH=5.5, group III: pH=6-6.5 and group IV: pH ≥ 7.0.

RESULTS: There were 108 patients (40%) in group I, 44 patients (16.3%) in group II, 78 patients (28.9%) in group III and 40 patients (14.8%) in group IV. Postoperative acute kidney injury (AKI) occurred in 39 patients (36.1%) in group I, 4 patients (9.1%) in group II and in 2 patients (2,5%) in group III. None of the patients developed AKI in group IV. Renal replacement therapy was required in 8 patients (2.9%) (6 patients from group I; 2 patients from group II; P = .016). 30-day mortality occurred in 5 patients (1.9%) (5 patients from group I; none from other groups; P = .017). All of these patients required renal replacement therapy. Logistic regression analysis revealing the presence of lower pH levels preoperatively was shown to be associated with increased incidence of postoperative AKI (OR: 0.193; 95% CI: 0.103-0.361; P = .000).

CONCLUSION: Low preoperative urinary pH (≤5.5) results in severe acute kidney injury and increase the rate of morbidity and mortality after isolated CABG surgery.

ID: 346

Topic: **Cardiovascular Surgery » Coronary Bypass Surgery**Presentation Type: **Oral****THE EFFECT OF DESMOPRESSIN ON BLOOD PRODUCT USE AND POSTOPERATIVE BLEEDING AFTER EMERGENT CARDIAC SURGERY****Naim Boran Tumer¹, Atike Tekeli Kunt¹, Serdar Gunaydin¹, Kanat Ozisik¹, Orhan Eren Gunertem¹, Ali Baran Budak¹, Seyhan Babaroglu², Onur Karahasanoglu¹***¹University of Health Sciences Ankara Numune Education and Research Hospital, Ankara, Turkey**²29 Mayıs Devlet Hastanesi, Ankara, Turkey***Corresponding Author (naimborantumer@hotmail.com)**naimborantumer@hotmail.com, atikemd@gmail.com, serdarkvc@gmail.com, sozisik2002@yahoo.com, egunertem@yahoo.com, drbaranbudak@gmail.com, babaroglus@yahoo.com, onurkarahasanoglu@gmail.com***Abstract Text**

BACKGROUND: Bleeding is a major problem in cardiac surgery and this results in a high risk of allogeneic blood transfusion that is associated with increased morbidity and mortality. In recent years studies in the literature reported that desmopressin (1-deamino-8-D-arginine vasopressin, DDAVP) reduces the blood loss after surgical interventions. The aim of the present study is to analyze the effect of desmopressin on blood product use and postoperative bleeding in patients that were pretreated with P2Y12 inhibitors by cardiologists and undergone emergent coronary artery bypass grafting (CABG) surgery.

METHODS: We retrospectively reviewed the prospectively collected data of 62 adult patients who underwent emergent isolated CABG surgery and pretreated with P2Y12 inhibitors by cardiologists. The perioperative data of the patients included demographic data, laboratory findings, the amount of blood loss from chest tubes, the amount of blood product use, need of re-thoracotomy, morbidity and mortality. The patient population was divided into two groups: group I: patients that received tranexamic acid and DDAVP perioperatively (n= 26) and group II: patients that received only tranexamic acid perioperatively (n=36).

RESULTS: The two groups of patients had similar characteristics at baseline. There was a statistically significant difference between group I and II regarding postoperative blood loss from the chest tubes, re-thoracotomy, red blood cell and thrombocyte transfusions (p<0.05). No statistically significant differences were observed between the two groups in terms of fresh frozen plasma transfusion, inotropic support and mortality.

CONCLUSION: We suggest that desmopressin in addition to tranexamic acid reduces bleeding and the amount of blood product use in patients undergoing emergent isolated CABG surgery.

ID: 330

Topic: **Cardiovascular Surgery » Coronary Bypass Surgery**Presentation Type: **Oral****DOES BODY MASS INDEX HAVE AN EFFECT ON AMOUNT OF TRANSFUSION AND BLOOD LOSS IN PATIENTS UNDERWENT CORONARY ARTERY BYPASS GRAFTING SURGERY**

Gökhan Erol ¹, Ufuk Mungan², Renda Cırcı³, **Erdem Çetin** ⁴, Emre Boysan ⁵, Furkan Burak Akyol ⁶, Tuna Demirkıran ⁶, Işıl Taşöz ⁶, Kıvanç Atılğan ⁷, Ertan Demirdaş⁶

¹*Gulhane Training And Research Hospital, Ankara, Turkey*

²*Akay Hospital, Ankara, Turkey*

³*Liv Hospital, Ankara, Turkey*

⁴*Karabük Training and Research Hospital, Karabuk, Turkey*

⁵*Liv Hospital, Ankara, Turkey*

⁶*Gulhane Training And Research Hospital, Ankara, Turkey*

⁷*University of TOBB Medine Faculty, Ankara, Turkey*

**Corresponding Author (drgokhanerol@gmail.com)*

drgokhanerol@gmail.com, drumungan@gmail.com, rendacirci@gmail.com, erdem1978@gmail.com, emreboysan@gmail.com, akyolburak19@gmail.com, drtunademirkiran@gmail.com, dr.isiltasoz@gmail.com, kivancatilgan@gmail.com, dr.ertandemirdas@gmail.com

Abstract Text**Introduction**

The amounts of transfusion and blood loss are important indicators of the results of coronary artery bypass grafting (CABG) surgery. Bleeding after open heart surgery is still an important issue. Massive bleeding requiring transfusion is found to be independently associated with serious perioperative events like sepsis, acute respiratory distress syndrome and renal failure. In this study we've aimed to evaluate the effects of body mass index (BMI) on the amount of transfusion and blood loss in patients who underwent CABG surgery.

Methods:

This study included 1673 patients whom underwent primary CABG surgery at Cardiovascular Surgery Clinics of Akay Hospital between December 2012 - September 2014. The patients were classified according to BMI values: Group 1 (BMI<24kg/m², low and normal weighted group, n=547), Group 2 (24≤BMI<28 kg/m², overweighted group, n= 820) and Group 3 (BMI≥28 kg/m², obese group, n=306). After this classification, the amounts of blood loss and transfusion in postoperative 24 hours were analysed.

Results:

Postoperative chest tube drainage was 13.6±7.92 ml/kg, 10.42±4.87 ml/kg, 8.43±3.6 ml/kg and amount of postoperative transfusion was 2.12±8.34 ml/kg, 1.07±3.63 ml/kg, 0.89±2.07 ml/kg in groups 1, 2 and 3 respectively. Postoperative chest tube drainage was significantly

higher in low and normal weighted patients when compared to obese group (13.6±7.92 ml/kg vs 8.43±3.6 ml/kg, p=0.007). The amount of transfusion was also higher in low and normal weighted patients when compared to obese group (2.12±8.34 ml/kg vs 1.07±3.63 ml/kg, p=0.004). Reoperation rates were higher in low-normal weighted and overweighted patients when compared to obese patients (1.09%, 0.73% and 0.32% respectively).

Conclusion:

In conclusion, we've founded a significant relationship between low amounts of postoperative blood loss or transfusion after CABG surgery and high BMI in this study. Our study shows that preoperative BMI must be taken into consideration for preoperative bleeding estimation and transfusion planning.

ID: 328

Topic: **Cardiovascular Surgery » Coronary Bypass Surgery**

Presentation Type: **Oral**

OFF-PUMP CORONARY ARTERY BYPASS SURGERY REDUCES INSIDENCE OF ATRIAL FIBRILLATION

Gökhan Erol¹, Erdem Çetin², Furkan Burak Akyol¹, Ufuk Mungan³, Renda Cırcı⁴, Emre Boysan⁴, Tuna Demirkıran⁵, Işıl Taşöz¹, Ertan Demirdaş¹

¹*Gulhane Training and Research Hospital, Ankara, Turkey*

²*Karabük Training and Research Hospital, Karabük, Turkey*

³*Akay Hospital, Ankara, Turkey*

⁴*Liv Hospital, Ankara, Turkey*

⁵*Gulhane Training and Research Hospital, Ankara, Turkey*

**Corresponding Author (drgokhanerol@gmail.com)*

drgokhanerol@gmail.com, erdem1978@gmail.com, akyolburak19@gmail.com, drumungan@gmail.com, rendacirci@gmail.com, emreboysan@gmail.com, drtunademirkiran@gmail.com, dr.isiltasoz@gmail.com, dr.ertandemirdas@gmail.com

Abstract Text

Introduction:

Postoperative atrial fibrillation (POAF) is the most common type of arrhythmia after coronary artery bypass grafting (CABG) surgery. The incidence of AF after CABG surgery is about 35%. Despite the etiology of POAF remains unexplained, numerous risk factors have been proposed by many studies. Among these factors discharge of inflammatory mediators and oxidative stress due to cardiopulmonary bypass (CPB) are the most accused ones. We have planned this retrospective study to evaluate the patients whom underwent CABG with CPB (on-pump) and with beating heart (off-pump) for POAF.

Methods:

This study included 1282 patients whom underwent CABG surgery at Cardiovascular Surgery Clinics of Akay Hospital and Medkar Hospital between the years of 2014 - 2015. CABG surgery was performed on 612 of the patients with on-pump technique and on 670 of the patients off-pump technique. 457 (35.6%) of the patients was women and 825 (64.4%) was men. The patients with normal sinus rhythm but have a history of atrial fibrillation, the patients whom had emergency CABG surgery or the ones whom had additional procedures along with CABG surgery were excluded. Off-pump CABG technique was usually preferred in patients who have high risk or contraindication for CPB or aortic cross-clamping, atheromatous plaques and severe calcification in ascendant aorta, aortic disease which has risks of embolization or

rupture or dissection, impaired renal functions or chronic renal failure, history of transient ischemic attack or cerebrovascular event, advanced age, respiratory issues, systemic disease or comorbidity that increases surgical risk. On-pump CABG technique was preferred in patients who have poor target vessel quality, intramyocardial target vessel, diffuse lesions in target vessel, calcific lesions in target vessel, target vessels that are thought to require endarterectomy, hemodynamic instability, severely impaired left ventricular functions and history of recent MI. In all cases, CABG surgery was performed with median sternotomy.

Results:

276 (21.5 %) of the 1282 patients who had CABG surgery suffered POAF. POAF has occurred in 63 (10.3%) of the 612 patients whom underwent off-pump CABG surgery and 213 (31.7%) of the 670 patients whom underwent on-pump CABG surgery and this difference was statistically significant ($p=0.012$).

Conclusions:

In conclusion, this study suggests that off-pump CABG surgery, which is a less invasive technique, may reduce the incidence of POAF in patients whom underwent surgical revascularization.

ID: 204

Topic: Cardiovascular Surgery » Coronary Bypass Surgery

Presentation Type: Oral

EVALUATION OF COMPOSITE ARTERIAL REVASCULARIZATION IN ELDERLY PATIENTS UNDERGOING CORONARY ARTERY BYPASS GRAFTING

Emin Gurbanov, Seymur Musayev, Ulvi Mirzoyev, Musa Qayibov, Hikmat Nagiyev, Reshad Mahmudov

Central Hospital for Oilworkers, Baku, Azerbaijan

**Corresponding Author (emin405@hotmail.com)*

*emin405@hotmail.com, emin405@hotmail.com, emin405@hotmail.com, emin405@hotmail.com,
emin405@hotmail.com, emin405@hotmail.com*

Abstract Text

Background

With the increasing age of the patients undergoing coronary surgery the surgical approach in this high-risk subset of patients need to be investigated. We evaluated the short- and mid-term outcomes of composite arterial revascularization in elderly patients undergoing coronary artery bypass grafting.

Methods

We enrolled 160 patients age > 70 years undergoing isolated CABG from 2014 to 2017. The primary outcomes were all-cause mortality, stroke, angina recurrence, and acute myocardial infarction. The radial artery (RA) was anastomosed end-to-side to the in situ LITA in a Y/T-graft fashion, or the RA was divided into 2 segments and then anastomosed end-to-side on the LITA in a double Y-graft fashion. In some cases the diagonal branch was bypassed with LITA in a sequential pattern with LAD. Diltiazem oral therapy (≥ 120 mg/day) was continued for at least 6 months. Follow-up visits were performed at 1, 6, 12 and 24 months. RITA and saphenous vein was also used on a need base.

Results

In-hospital mortality was 1.9%; 30-day mortality was 2.5%. Aortic cross clamping time was 28 ± 7 minutes, whereas the cardiopulmonary bypass time was 45 ± 8 minutes. 3 patients (1.9%) experienced neurologic complications, of which 1 died within 30 days after the surgery. OPCAB were performed in 34.4% of cases (55 patients). The IABP was used in 1 patient initiated in ICU. At the mean follow-up of 18 months the incidence of angina recurrence was 2%. Whenever possible the aorta no touch technique was used, which comprised 68.8%. No patient had myocardial infarction within follow up period.

Conclusions

Performing CABG using composite arterial grafts in elderly patients is safe with acceptable rate of cerebrovascular complications. Surgical skills in performing surgical revascularization through off-pump method is essential which offers a significant reduction in risk of death, stroke, mortality or morbidity, and hospital stay as compared to on-pump coronary artery bypass. The aortic no-touch technique might be a chief option in this subset of patients who have severe atherosclerotic ascending aorta which is impossible to clamp.

ID: 202

Topic: Cardiovascular Surgery » Coronary Bypass Surgery

Presentation Type: Oral

COMPARING POSTOPERATIVE OUTCOMES OF FEMALE OCTOGENARIANS WHO UNDERWENT ISOLATED CORONARY ARTERY BYPASS SURGERY

Serkan Burç Deşer, Mustafa Kemal Demirag

Ondokuz Mayıs University, Samsun, Turkey

**Corresponding Author (sbd983@yahoo.com)*

sbd983@yahoo.com, mkd@yahoo.com

Abstract Text

Introduction

Female gender was considered to add 1.5-2 fold additional burden during and after coronary artery bypass surgery by some authors while some authors advocated vice versa. Accompanying diabetes mellitus, hypertension, late onset of coronary artery disease, advanced age, and lower coronary artery diameters were considered to increase the postoperative mortality and morbidity in females. In this study, we aimed to investigate the postoperative early outcomes of female octogenarians who underwent isolated coronary artery bypass surgery.

Materials and Methods

From February 2011 to October 2018 a total of 28 patients (14 males, 14 females; mean age 83,25±9,88 years; range 80 to 93 years) who underwent isolated coronary artery bypass grafting surgery were included in this study.

Results

No significant difference was found between genders respect to age (p=0,956), EF% (p=0,632), number of vessels (p=0,690), DM (p=0,445), HT (p=0,684), PAD (p=0,541), COPD (p=0,622), smoking (p=0,065), chronic renal failure (p>0,05), hyperlipidemia (p=0,45), LITA use (p=0,541), post op. AF (p=0,541), IABP (p=0,309), post op. low cardiac output (p=0,142), post op. MI (p>0,05), post op. bleeding (p>0,05), post op. stroke (p=0,309), post op. pneumonia (p=0,541), post op. mediastinitis (p=0,309), post op. renal failure (p=0,541), post op. ICU stay (p=0,373) and overall in hospital stay (p=0,425).

Conclusions

In this study, we found that no significant difference was found between genders and, female gender did not add extra early postoperative outcomes burden in octogenarians who underwent isolated coronary artery bypass grafting surgery.

ID: 304

Topic: **Cardiovascular Surgery » Coronary Bypass Surgery**Presentation Type: **Oral****DIAGNOSIS OF ACUTE MYOCARDIAL INFARCTION AFTER CORONARY ARTERY BYPASS GRAFT (CABG) SURGERY: A SYSTEMATIC REVIEW****Ahmed Elkaramany***National Heart Institute, CAIRO, Egypt***Corresponding Author (aelkaramany@gmail.com)***Abstract Text**

Introduction: Myocardial infarction after coronary artery bypass grafting is a serious complication and one of the most common causes of perioperative morbidity and mortality. Multiple mechanisms have been proposed to explain myocardial injury after CABG. Diagnosis will be established according to creatine kinase (CK) values more than five times the 99th percentile of the normal reference range during the first 72 hours following CABG, (or Troponin or CKMB more than ten time increase) when associated with the appearance of new pathological Q-waves or new left bundle-branch block (LBBB), or angiographically documented new graft or native coronary artery occlusion, or imaging evidence of new loss of viable myocardium, should be considered as diagnostic of a CABG related MI.

Objectives: to identify the methods of diagnosis of post coronary artery bypass graft (CABG) acute myocardial infarction.

Data sources: MEDLLINE (PubMed), EMBASE, Google Scholar and the Cochrane Library and all materials available in the internet till 2017.

Study selection: this search presented 23 eligible studies which studied the diagnostic methods for acute myocardial infarction after coronary artery bypass graft (CABG) surgery.

Data extraction: if the studies did not fulfill the inclusion criteria, they were excluded. The methodological quality of included studies was assessed using an adjusted QUADAS-tool.

Data synthesis: comparisons was made by structured review with the results tabulated.

CONCLUSION: Troponin I and T can both be used to indicate myocardial damage, with the level correlating well with the level of injury. However until issues such as a 'gold standard' for peri-operative MI are addressed, one single cut-off point cannot be recommended for either test.

Key words: (coronary artery bypass/OR CABG/ OR cardiac surgical procedures/ OR coronary bypass OR cardiac surgery) AND (troponin OR Troponin T/OR Troponin I OR TnI OR TnT) AND (Myocardial Infarction/OR MI/ OR myocardial damage OR myocardial injury) AND (postoperative OR perioperative) AND (diagnosis OR diagnostic methods).

References:

Danese E and Montagnana M. An historical approach to the diagnostic biomarkers of acute coronary syndrome. *Ann Transl Med* 2016 ;4(10):194.

Dianne VB, Bas van Zaane, Marc PB, et al. Implementation of the Third Universal Definition of Myocardial Infarction after Coronary Artery Bypass Grafting: A Survey Study in Western Europe. *J Am Heart Assoc.* 2015; 114: 1100-1161.

Pretto P, Gerez FM, Andressa B, et al. Perioperative myocardial infarction in patients undergoing myocardial revascularization. *Rev Bras Circ Cardiovasc.* 2015; 30: 1678 -1686.

ID: 218

Topic: **Cardiovascular Surgery » Perfusion Course**Presentation Type: **Oral****RARE AND DANGEROUS COMPLICATION OF CARDIOPULMONARY
BYPASS: VASOPLEGIC SYNDROME****Mehmet Kalender, Mustafa Bertan Ismail***Kocaeli Derince Training and Research Hospital, Kocaeli, Turkey***Corresponding Author (ka97084@yahoo.com)**ka97084@yahoo.com, bertan.ismail@gmail.com***Abstract Text**

Introduction

Vasoplegic Syndrome first described in 90s and increasingly recognized as an important clinical circumstance in perioperative period. Incidence reported in between 0.4-42% (mean 8.8-10%). Mortality rate reported as 25%. Mortality increases in patients with delayed diagnosis and/or refractor to treatment in first 36-48 hours. Vasoplegic Syndrome is characterized by tachycardia, normal or high cardiac output, decrease in systemic vascular resistance, hypotension resistant to volume replacement or inotropic treatment. In summary vasoplegic syndrome is vasodilator mechanism activation due to multifactorial causes thus causing resistant hypotension. The aim of this presentation is to review Vasoplegic Syndrome and alert to this under-recognized yet very challenging clinical condition.

Case:

51 age male with stable angina pectoris complaint had CABGx4 with CPB(full revascularization). Patient had 173 cm height and 108 kg weight. Preoperative laboratory tests were in normal range. Preoperative echocardiography revealed normal left ventricular ejection fraction. During CPB patient had 2500 cc cardioplegi (1000, 500, 500, 500). During CPB no blood product was transfused. Total perfusion time was 127+42 minutes and Total cross clamp time was 64 minutes. Patient was weaned off CPB with IABP and inotropic support. During postoperative ICU care patient had weaned of mechanic ventilator support at 8th hour. On postoperative 1th day IABP weaned off. And postoperative 5th day patient had no inotropic support requirement. Patient was discharged on postoperative 11th day and was doing good on 1st month follow up. During ICU follow up we have discovered patient had used ACE inhibitors since 2013.

Discussion

The potential risk factors include blood transfusion, cardiopulmonary bypass, organ transplantation, trauma and sepsis, and use of specific medications such as angiotensin-converting enzyme inhibitors, Angiotensin-II antagonist, calcium channel antagonists, heparin, amiodarone, aprotinin, and protamine.

Patients with high BMI, female patients, and additional preoperative arginin vasopressin deficiency increase the risk of perioperative vasoplegia syndrome.

In this particular case patient had confronted with cardiopulmonary bypass, mild hypothermia and protamine. Other than that patient's BMI was high (BMI=36.5) Also patient had angiotension-converting enzyme inhibitors since 2013.

Current management strategies include intravenous administration of volume and catecholamines, vasopressin, methylene blue and high dose hydroxocobalamin.

In our case; volume administration and inotropic support had enough effect. And patient had full recovery. Vasoplegia Syndrome is still associated with significantly increased perioperative morbidity and mortality.

ID: 41

Topic: **Cardiovascular Surgery » Risk Management in Cardiovascular Diseases**Presentation Type: **Oral****TREATMENT OF CANDIDA STERNAL INFECTION FOLLOWING
CARDIAC SURGERY**Ali Ahmet Arıkan¹, Oğuz Omay², Emre Horuz³, Gökhan Yağlı⁴, Hakan Ağır⁵¹*Derince Eğitim Araştırma Hastanesi, Kocaeli, Turkey*²*Kocaeli University Medical Faculty, Department of Cardiovascular Surgery, Kocaeli, Turkey*³*Department of Infectious Diseases and Clinical Microbiology, Zonguldak Hospital for Obstetrics and Pediatric Diseases, Zonguldak, Zonguldak, Turkey*⁴*Kocaeli University Medical Faculty, Department of Cardiovascular Surgery, Kocaeli, Turkey, Kocaeli, Turkey*⁵*Department of Plastic and Reconstructive Surgery, Altunizade Acibadem Hospital, _Istanbul, Turkey, İstanbul, Turkey***Corresponding Author (dr_aarikan@hotmail.com)**dr_aarikan@hotmail.com, oguzomay@gmail.com, dremrehoruz@gmail.com, drgkhnygl@gmail.com, agirhakan@yahoo.com***Abstract Text****ABSTRACT**

Background: Candida sternal wound infections (SWIs) following cardiac surgery are rare but are associated with a high mortality rate. Guidelines on this topic either propose no suggestions for management or offer recommendations based on a small number of reports.

Methods: This paper presents a case of a Candida SWI and its successful treatment with debridement using a burr, negative pressure vacuum therapy (NPVT) and dermal grafting. To investigate different methods of treating Candida SWIs following cardiac surgery, a review was completed using the MEDLINE database. Reports without English abstracts and without defined outcomes of therapy for individual patients were excluded.

Results: Seventy-seven cases of Candida SWIs following cardiac surgery were identified in 20 articles published since 1999, including our case. Treatment strategies are identified: omentum flap; muscle flap; debridement and secondary wound healing with or without NPVT; debridement and primary closure; incision and drainage; only medical therapy. Patients documented in the articles were classified based on the following outcomes: cured (Group 1, n=41 patients [including the present case]), relapse infection (Group 2, n=25 patients) and death (n=11 patients). The various methods used to treat patients were analysed.

Conclusions: Delayed closure reoperation with surgical debridement and NPVT have favourable outcomes. In the presence of widespread osteomyelitis, the use of omental flaps is advocated. Treatment with muscle flaps has a high rate of relapse. Debridement and secondary healing or conservative management with antifungals alone can be considered in the treatment of relapsing infection.

This report is published in Journal of Infectious Diseases with the DOI: <https://doi.org/10.1080/23744235.2018.1518583>

Oral Presentation Session**Surgery for Coronary Artery Disease: Current Practice of Experts**

Date: 27.03.2019 Time: 14:30 - 16:00 Hall: 6

ID: 158**Topic: Cardiovascular Surgery » Coronary Bypass Surgery****Presentation Type: Oral****ON-PUMP VERSUS OFF-PUMP CORONARY ARTERY BYPASS
GRAFTING: COMPARISON OF TRANSIT TIME FLOW METER
MEASUREMENT RESULTS****Eren Anđ, Atif Yolgösteren, Mustafa Tok***Uludag University, Bursa, Turkey***Corresponding Author (atif@uludag.edu.tr)**atif@uludag.edu.tr, dreren@hekim.net, mustafatok@uludag.edu.tr***Abstract Text**

Objective : The success of the safe anastomosis with the heart-lung machine, intaken interest to take place for performing operations on the beating heart. Complete revascularisation on the beating heart could be performed to all patient groups with the help of local stabilizers. The aim of this study is to investigate the initial morbidity and mortality rates , the patency rates of the grafts in the operations performed completely on the beating heart or on cardiopulmonary bypass.

Methods: In our study, the high mean flow, low pulsatility index, such as high diastolic filling, good quality of anastomosis and graft patency, showing the values of group1 them although they had more group2 than those with only mean flow rates of LIMA difference was statistically significant.

Results: The average height of the flow factors of multifactorial cardiac arrest only in group1, global myocardial ischemia and acidosis secondary to coronary vasodilatation, thanks to a good quality of anastomosis and graft patency between the groups, more specifically the quality of anastomosis, and blood pressure, vascular resistance affected by the pulsatility index and the diastolic filling patterns values of the parameters, such as no significant difference in the height of the flow in group1 suggests that this group due to coronary vasodilation.

Conclusion : Transit Time Flow Meter measurement method is a useful method in objective evaluation of perioperative graft flow. Technical errors can be evaluated and corrected while the patient is on the operation table and the sternum is open. The sensitivity of Transit Time Flow Meter measurement device in identification of less severe stenosis forms should be determined with the help of larger studies with angiographic correlation.

When unfavourable Transit Time Flow Meter measurement results are obtained, first the length and tightness of the graft, presence of air in the graft, bending and spasm should come into mind and those pathologies should be corrected if present, and if not, the anastomosis should then be revised.

ID: 89

Topic: **Cardiovascular Surgery » Coronary Bypass Surgery**Presentation Type: **Oral****PATIENTS WITH CORONARY BYPASS SURGERY ON LEFT VENTRICULAR AND HEMODYNAMIC PARAMETERS OF PERICARDIOTOMY EFFECTS****Mehmet Kizilay***Dr.Siyami Ersek Training and Education Centre, ISTANBUL, Turkey***Corresponding Author (kzlay@yahoo.com)**kzlay@yahoo.com***Abstract Text****Objective**

The increase in myocardial tension and ventricular filling leads to an increase in myocardial protein synthesis rate. It is thought that pericardium is a factor that limits myocardial growth biologically and pericardiotomy may be a factor stimulating myocardial growth.

Material Metods

This study was performed by selecting 32 patients with LVEF% 50 and over who underwent open pericardiotomy as part of the elective CABG. Twelve women and 20 men were male and the mean age was 59 ± 11 years. Five patients had single vessel disease, 10 patients had two-vessel disease, and 23 patients had three-vessel disease. Patients with unstable angina, underwent emergency coronary surgery, who had previously undergone myocardial infarction, patients with additional cardiac pathologies in addition to coronary artery disease, and those with systemic disease such as kidney or liver disease were not included in the study. The operation was terminated by leaving the pericardium open. For this purpose, 32 patients who underwent coronary artery bypass surgery in our clinic were investigated preoperatively on day 1, 6th weeks and 6 months postoperatively, EF, LVESV, LVESVI, LVEDV, LVEDVI, LV muscle mass index and left ventricular circumferential wall stress were measured echocardiographically. Blood pressure was also measured by noninvasive method simultaneously with echocardiography. Revascularization was performed according to the characteristics of the patients.

Results

Echocardiographically, the left ventricular end-diastolic volume index was significantly increased at 6th weeks and at 25% ($p < 0.05$) at 6 months compared to preoperative values. Also, left ventricular muscle mass index showed statistically significant changes at the 6th week 18% ($p < 0.05$) at the 6th week compared to the preoperative values. However, there was no statistically significant change in the systolic volume left ventricular circumferential wall stress values ($p > 0.05$).

Ejection fraction (EF) values measured by two-dimensional echocardiography and left ventriculographic evaluations were $63 \pm 7\%$ on average. At the 6th postoperative week, EF was found to be $65\% \pm 9$, and at the 6th month, EF was found to be $68\% \pm 10$. Although the data obtained in the sixth week increased slightly compared to the preoperative values, this increase was not statistically significant ($p > 0.05$). The values obtained at the 6th month showed a statistically significant increase compared to the preoperative and 6th week values. Table-1

Total number of patients (n=32)	Preoperative	Postoperative	
		6th. week	6. month
LVESV (ml)	36 ±11	39±15	38±13
LVESVI (ml/m ²)	20±6	22±5	21±4
LVEDV (ml)	99±21	120±25*	125±23*
LVEDVI (ml/m ²)	55±8	67±10*	70±12*
LVEF (%)	63±7	65±9	68±10*
δ_c (kdyn/cm ²)	175±22	188±18	190±20
LVKK (g)	205±56	236±62*	242±58*
LVKKI (g/m ²)	115±25	132±21*	135±23*
SYSTOLIC PRESSURE (mmHg)	130±18	132±25	141±24
DIASTOLIC PRESSURE (mmHg)	75±10	76±10	77±12

LVESV = Left ventricular end-systolic volume, LVESVI = Left ventricular end-systolic volume index, LVEDV = Left ventricular end-diastolic volume; LVEF = Left ventricular ejection fraction, δ_c = systolic wall stress, LV = left ventricle, LVKK = left ventricular muscle mass, LVKKI = left ventricular muscle mass index, (*) = p <0.05

Conclusion

In conclusion, pericardiotomy was performed in patients undergoing coronary artery bypass graft surgery; it leads to better left ventricular filling, leading to an increase in left ventricular end-diastolic volume and left ventricular muscle mass.

ID: 116

Topic: **Cardiovascular Surgery » Risk Management in Cardiovascular Diseases**Presentation Type: **Oral****CORONARY REVASCULARIZATION IN PATIENTS WITH CHRONIC KIDNEY DISEASE, EARLY AND LATE RESULTS.****Mohamed Ismail¹, Ahmed Jamjoom²**¹*Mansoura University, Mansoura, Egypt*²*King Faisal Specialist Hospital, Jeddah, Saudi Arabia***Corresponding Author (mfismail2299@yahoo.com)**mfismail2299@yahoo.com, jamjoom_ahmed@hotmail.com***Abstract Text**

Background: Chronic kidney disease (CKD) is a strong predictor of mortality after percutaneous coronary intervention (PCI) or coronary artery bypass grafting (CABG). In this study we compare outcomes in patients with chronic kidney disease undergoing PCI and CABG.

Methods: We retrospectively reviewed 205 consecutive patients with CKD (glomerular filtration rate <60 ml/min) who underwent either CABG or PCI for multivessel CAD at our institute from Jan, 2014 to December, 2016.

Results: Our patients were divided into 2 groups. Group (A) included 131 patients who underwent PCI, and 74 had CABG as group (B). Females were 32 (24.4%) in group A, and were 22 (29.7%) in group B (p = .23). Age was 63.71±11.04 in group A and 62.29±9.67 in group B (p=.35). Patients on hemodialysis in group A were 26 (19.8%) and 40 (54.05%) in group B (p<.0001). Ejection fraction was 36.04±11.14 in group A and 32.14±14.21 in group B (p = .09). Diabetics was 100 (76.3%) in group A and 54 (72.9%) in group B (p <.19). History of cerebrovascular accident was 20.6% in group A compared to 12.2 % in group B (p <.02). Post intervention results regarding needing for permanent hemodialysis; was 6 patients in group A (4.6%) and 8 patients (10.8%) in group B (p <.01). In hospital mortality was 3 patients (2.3%) in group A and 2 patients (2.7%) in group B (p = .43). Late mortality was 16 patients (12.2%) in group A and 4 patients (5.4%) group B (p <.05). Repeat revascularization was 20 patients (15.3%) in group A and 5 patients (6.8%) in group B (p<.001).

Conclusion: Coronary artery bypass grafting is associated with higher incidence of need for permanent hemodialysis compared to percutaneous intervention in patients with chronic renal dysfunction. Late mortality and need for repeat revascularisation is significantly higher with percutaneous intervention.

ID: 518

Topic: **Cardiovascular Surgery » Coronary Bypass Surgery**Presentation Type: **Oral****MID-TERM EFFECTS OF CONVENTIONAL ULTRAFILTRATION ON
CARDIOPULMONARY FUNCTIONS****Gülen Sezer Alptekin Erkul, Sinan Erkul***Dumlupınar University Kütahya Evliya Çelebi Training and Research Hospital, Kütahya, Turkey***Corresponding Author (gsezeralptekin@hotmail.com)**gsezeralptekin@hotmail.com, drsinanerkul@hotmail.com***Abstract Text**

Objective: Inflammatory reactions, tissue edema, pulmonary dysfunction and poor cardiac performance may be observed frequently in pediatric cases but also in adult patients when weaning from cardiopulmonary bypass (CPB) and are some of the major causes of morbidity and mortality. According to some studies conventional ultrafiltration during CPB reduces the inotropic drug requirement and recovers cardiac functions particularly in adult patients. Our aim is to evaluate the mid-term effects of conventional ultrafiltration on cardiopulmonary functions of adult patients.

Methods: 971 patients who underwent CBP procedure in our department between February 2013 and December 2018 were studied retrospectively. Of 108 patients who were applied conventional ultrafiltration, 60 patients could be followed up after discharge. According to our routine clinical practice hyperkalemia (>5.5 mEq/dl) resistant to diuretic agents and hypervolemia (venous reservoir volume ≥ 1200 ml and Hct $\leq 25\%$) during the weaning process from CPB were assessed as indications for ultrafiltration. Ultrafiltration was performed with 1-3ml/kg/min filtrate volume in approximately 20-30 minutes after declamping of the aorta (Fx CorDiax, Aeff:1,6 m2, Germany).

Results: Of 60 patients, 16(26,7%) were female and 44(73,3%) were male and the mean age was $63,8\pm 8,1(45-81)$. Isolated coronary artery bypass surgery was performed in 43 patients (71,7%) whereas mitral or aortic valve surgery, ascending aortic surgery, ventricle repair or concomitant surgery were performed in 17 patients (28,3%). Inotropic agent requirement were determined in 25 patients whereas intraaortic balloon pump (IABP) support was applied in 8 patients. Mean follow-up duration was $19,9\pm 11,9$ months (2-76). At follow-up mean ejection fraction was $52,7\pm 11,15\%(20-65)$. The mean pulmonary artery pressure was lower than 25 mmHg in 46 patients and it was $44,4\pm 10,9$ mmHg (29-65) in 14 patients. The mean cardiothoracic index was $0,53 \pm 0,07(0,41-0,75)$. According to the New York Heart Association (NYHA) functional classification, 54 patients were in NYHA class 1-2 and 6 patients in NYHA class 3. None of the patients were in NYHA class 4.

Conclusions: We suppose that conventional ultrafiltration reduced the inotropic agent and IABP requirement in our patients though a considerable population of them implicated high surgical risk. The functional capacity of the patients was good and the mean early and mid-term cardiac functions were in normal ranges. We believe that conventional ultrafiltration is efficacious for a safety weaning from CPB and contributes to the preservation of the cardiopulmonary status for such patients in advanced period.

ID: 93

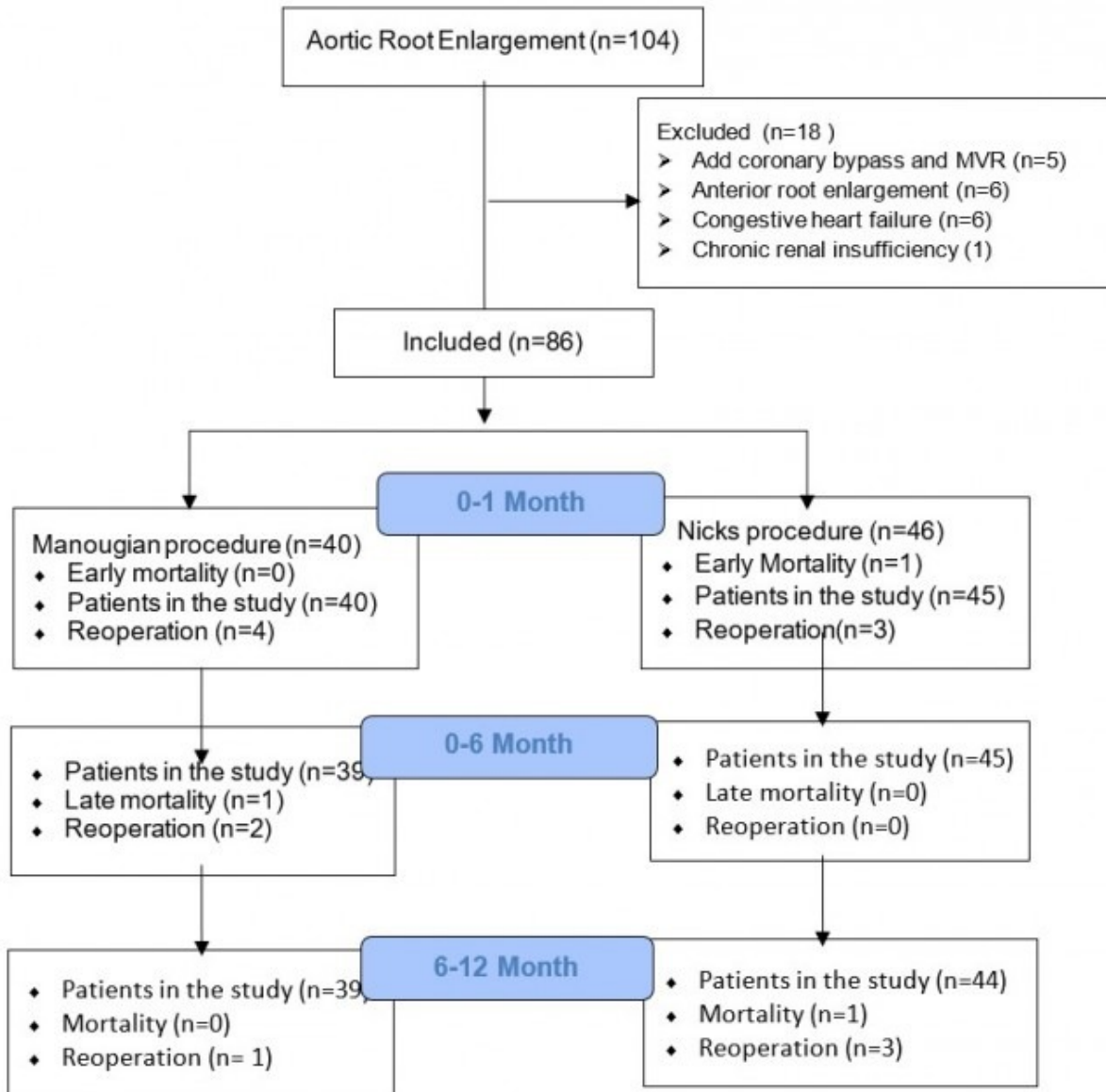
Topic: **Cardiovascular Surgery » Coronary Bypass Surgery**Presentation Type: **Oral****CORONARY INVOLVEMENT IN BEHÇET'S DISEASE: WHAT ARE ITS RISKS AND PROGNOSIS? (RARE CASES)**Ünsal Vural¹, Mehmet Kızılay², Ahmet Arif Ağlar²*¹Dr. Siyami Ersek Thoracic and Cardiovascular Surgery Center, Istanbul, Turkey***Corresponding Author (unsalvural@gmail.com)**unsalvural@gmail.com, opdrmkz@gmail.com, a.a.aglar@gmail.com***Abstract Text**

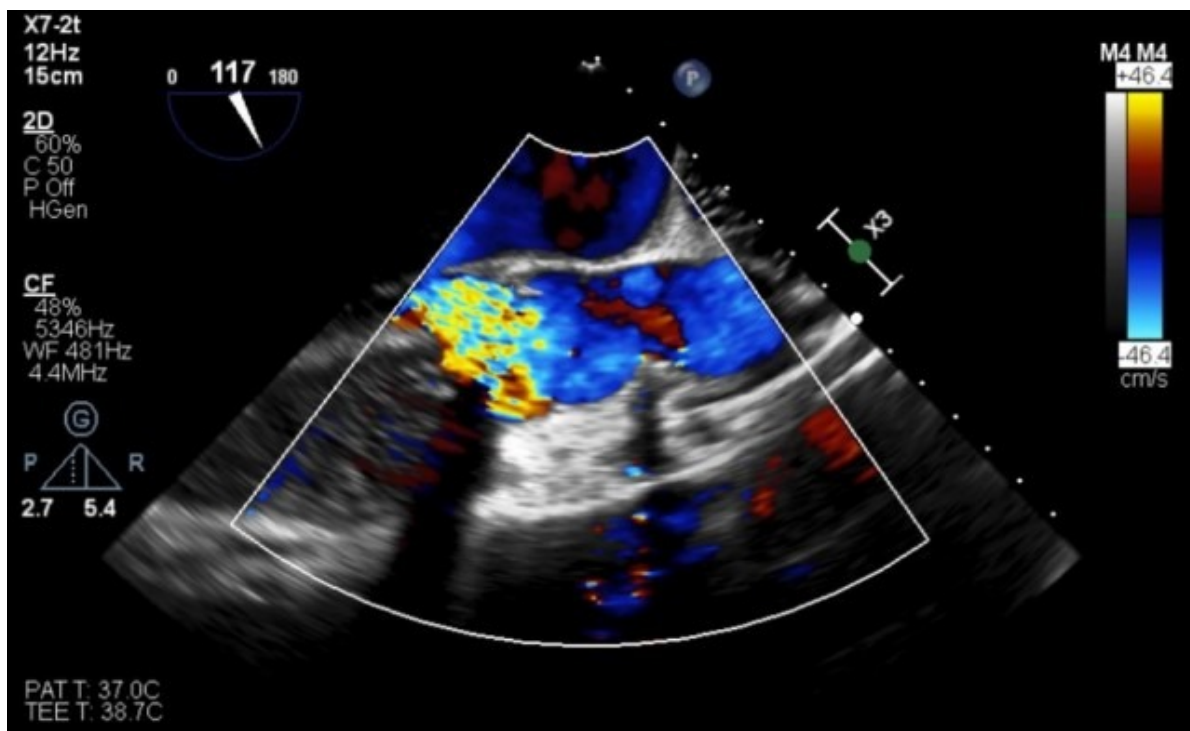
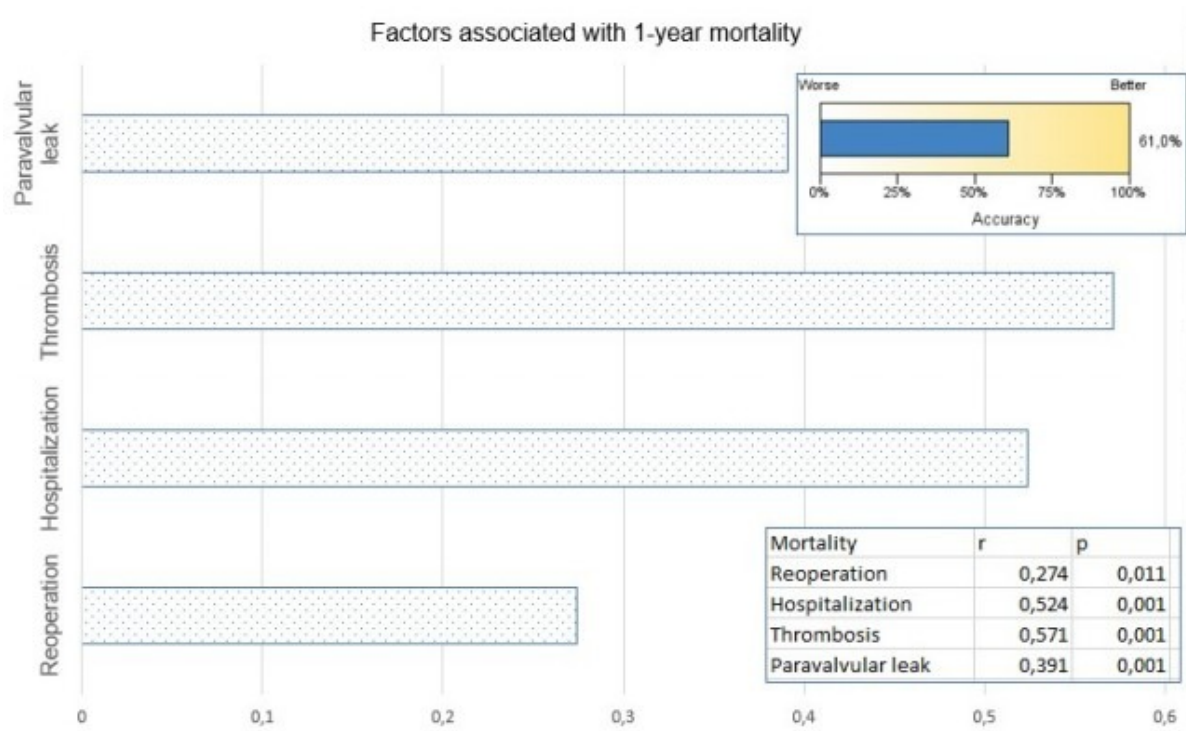
Objective: We evaluated the patients with Behçet's Disease who had undergone coronary artery bypass grafting in terms of preoperative risks, postoperative complications and the effect of disease on mortality.

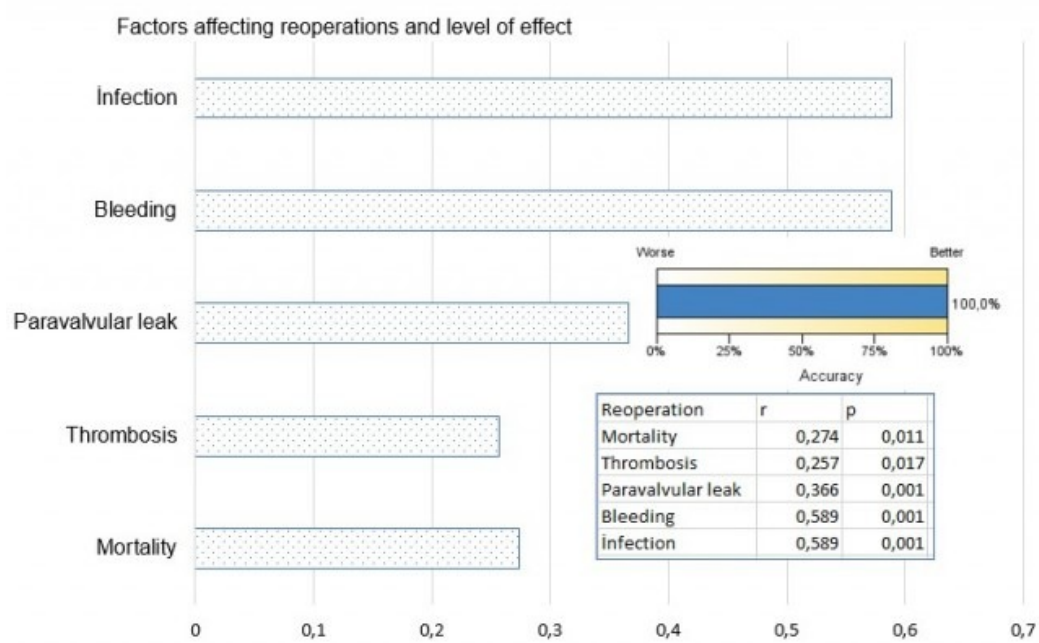
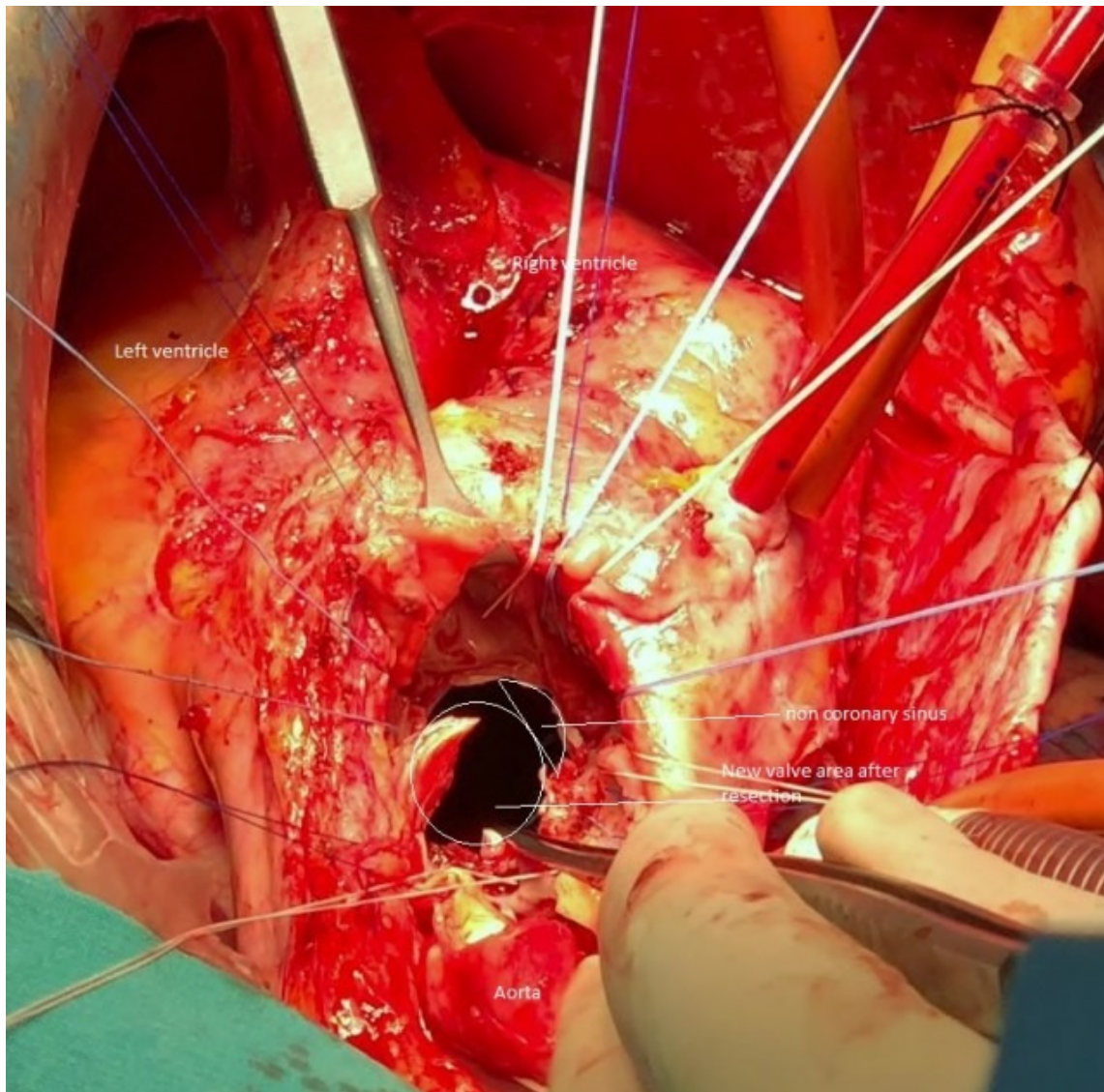
Material and Method: Thirteen patients with the Behçet's Disease who had undergone coronary artery bypass grafting in our center between 2003 and 2015 were analyzed. We evaluated the clinical and laboratory findings, complications and mortality rates of our patients in the light of the literature.

Results: The mean age was 38,5 (30-55; 3 out of 13 were women). The mean time from onset of Behçet's Disease to coronary artery disease was 4,7 (3-11) years. 54% of the patients were asymptomatic, 31% had angina pectoris, 8% had acute coronary syndrome and 8% had arrhythmia. In the coronary arteries, 31% of patients had distal type obstruction, 31% had aneurysm and pseudoaneurysm, 15% had proximal segment thrombus, 31% had chronic type stenosis and occlusions. Early mortality (15%) was due to acute MI while the late mortality (15%) was due to cerebral or GIS hemorrhage. Reoperation was due to bleeding in one case on the first postoperative day and due to acute pulmonary embolism in another case in the third postoperative year.

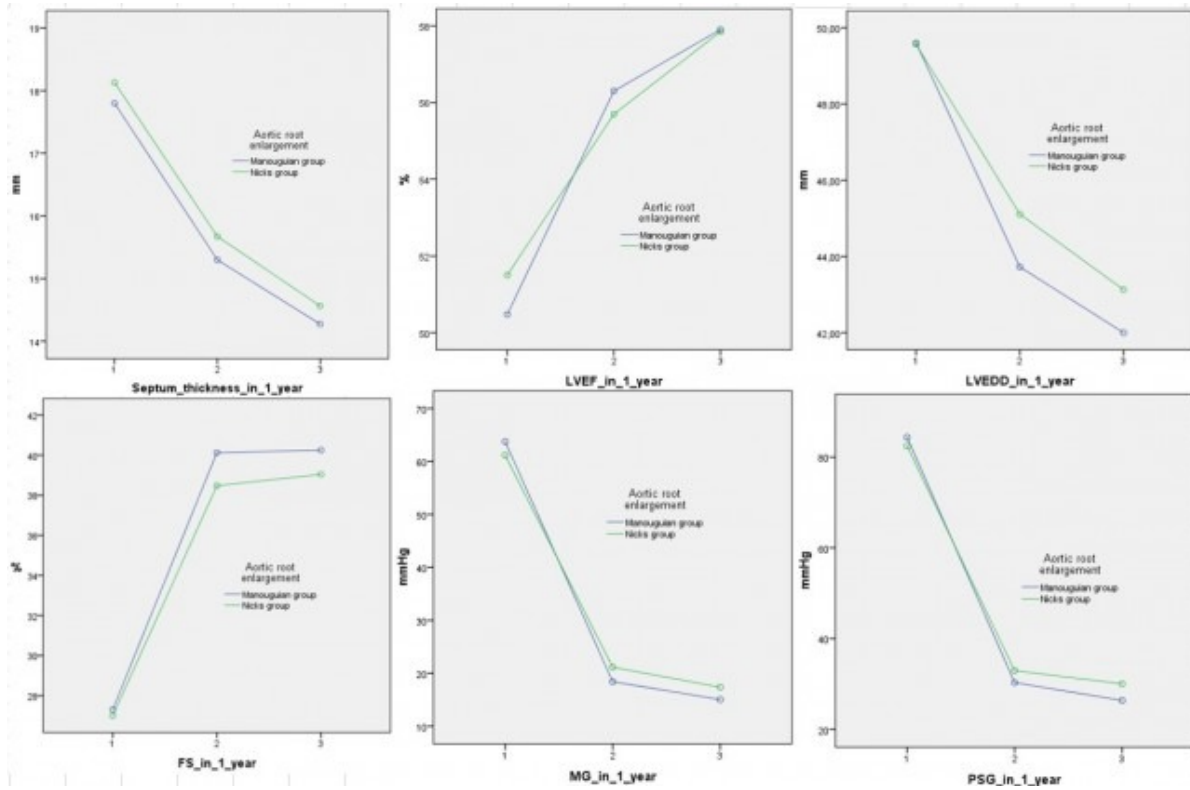
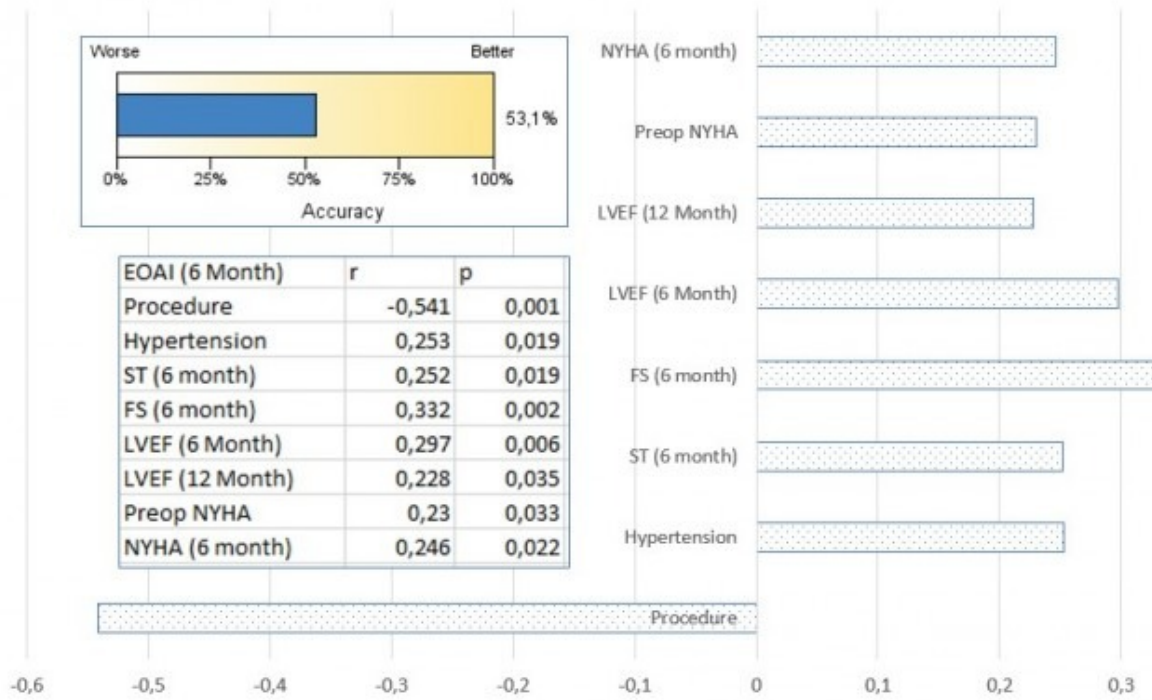
Conclusion: Coronary lesions were mostly in the form of aneurysms, and occlusions resulting from distal embolization in younger cases, whereas in older patients it was seen as intimal fibrosis and atherosclerosis secondary to vasculitis. Since the operative risk is high in the active phase, it is appropriate to prefer less invasive revascularization methods.







EOAI predictors at 6th Month



ID: 347

Topic: **Cardiovascular Surgery » Coronary Bypass Surgery**Presentation Type: **Oral****PREOPERATIVE SUBCLINICAL HYPOTHYROIDISM IS ASSOCIATED WITH POOR OUTCOMES AFTER ISOLATED CORONARY ARTERY BYPASS GRAFTING****Naim Boran Tumer***University of Health Sciences Ankara Numune Education and Research Hospital, Ankara, Turkey***Corresponding Author (naimborantumer@hotmail.com)**naimborantumer@hotmail.com***Abstract Text**

BACKGROUND: It is reported that subclinical hypothyroidism is associated with atherosclerosis and death due to cardiovascular diseases. The aim of the present study is to analyze the association of preoperative subclinical hypothyroidism with postoperative outcomes after isolated coronary artery bypass graft surgery (CABG).

METHODS: We retrospectively reviewed the prospectively collected data of 378 adult patients who underwent isolated CABG surgery. The perioperative data of the patients included demographic data, laboratory findings, morbidity and mortality. The patient population was divided into two groups: group I: euthyroid patients (n= 286) and group II: patients with subclinical hypothyroidism (SCH, n=50). Eight patients with overt hypothyroidism, 6 patients with overt hyperthyroidism and 28 patients with subclinical hyperthyroidism were excluded from the study.

RESULTS: There were 286 euthyroid patients (75.6%), and 36 patients with SCH (9.5%). The mean age, sex distribution, and BMI in euthyroid and SCH patients were similar. On regression analysis, preoperative SCH did show a significant effect on postoperative glycemic control, prolonged inotropic support, arrhythmias, respiratory failure, ICU and hospital length of stay in this cohort.

CONCLUSION: We suggest that preoperative evaluation of thyroid function may be helpful for predicting long-term outcomes after isolated CABG surgery.

ID: 272

Topic: **Cardiovascular Surgery » Coronary Bypass Surgery**Presentation Type: **Oral****OUR CLINICAL AND SURGICAL EXPERIENCE IN THE INTRACARDIAC
MASSES****Azman Ateş, Ferhat Borulu, Ümit Arslan, Eyüp Serhat Çalık***Atatürk University Faculty Of Medicine, Erzurum, Turkey***Corresponding Author (azmanates@atauni.edu.tr)**azmanates@atauni.edu.tr, fborulu@gmail.com, kvcumit@gmail.com, eyupserhatcalik@hotmail.com***ABSTRACT****Objectives**

The intracardiac masses are characterized by stenosis, embolic events, and conduction disturbances. They are very rare pathologies. Generally surgical excision offers a very good prognosis. The aim of this study is to present the cardiac masses and treatment methods in our clinic.

Method

In our clinic, 39 patients with intracardiac mass who were operated in our clinic between July 2003 and November 2015 were examined retrospectively.

Results

Of the patients, 26 (66.6%) were male and 13 (33.4%) were female. The most common clinical finding was dyspnea and rhythm disorder. The patients were between 21 and 79 years old and had a mean of 49 years. First diagnosis was made by echocardiography in all patients. 14 of the patients had mitral valve pathology accompanying cardiac mass. In these patients, mitral valve replacement was performed in 7 patients and tricuspid de Vega anuloplasty was performed. Coronary artery disease was detected in 4 patients and simultaneous coronary artery bypass surgery was performed. Left atrial thrombus was present in 18 patients (48.7%), atrial myxoma was present in 11 patients (28.2%), cardiac hydatid cysts were found in 4 (11.4%) patients, right atrial thrombus was present in 3 patients (7.6%). (2,8%) biatrial thrombus and 1 myxoma from right ventricle to pulmonary artery were present. In all patients, mass lesions were excised. Four patients with thrombus diagnosis were given thrombolytic therapy. They were treated without any surgical intervention. Although there was no intraoperative mortality, four patients died in the early postoperative period.

Conclusions

Although intracardiac masses are rare, obstructive symptoms are very important in terms of thromboembolic events and arrhythmias. Myxomas are quite common. If the excision of the cardiac masses is fully excised after the early diagnosis, the results are quite satisfactory.

ID: 528

Topic: **Cardiovascular Surgery » Coronary Bypass Surgery**Presentation Type: **Oral****CORONARY ARTERY BYPASS SURGERY IN A PATIENT WITH HEMOPHILIA C (FACTOR XI DEFICIENCY)****Hüseyin Sicim, Gökhan Arslan, Hakan Kartal, Celalettin Günay, Bilgehane Savaş Oz***Gulhane Training and Research Hospital, Ankara, Turkey***Corresponding Author (huseyinsicim@yahoo.com.tr)**huseyinsicim@yahoo.com.tr, drgokhanarslan@gmail.com, hakhankartal@gmail.com, celalettin.gunay@sbu.edu.tr, bilgehansavas.oz@sbu.edu.tr***Abstract Text**

INTRODUCTION:Factor XI (FXI) deficiency is a rare hereditary coagulation disorder with a prevalence of 1/1 million in the general population. Unlike other factor deficiencies, spontaneous bleeding in individuals with FXI deficiency is not expected; even in severely affected individuals, excessive bleeding may not be seen after a trauma. In this case, the management of hemophilia C (Factor XI deficiency), which is a very rare bleeding disorder planned for coronary artery bypass graft surgery, and the patient with prolonged partial thromboplastin time is presented.

CASE REPORT:A 68-year-old male patient was admitted to the hospital with chest pain. She had a history of hypertension, diabetes mellitus, cholelithiasis, and hemophilia c disease. The patient was diagnosed with NSTMI. Coronary artery bypass surgery was recommended. His laboratory test results were; white blood cell: $8.2 \times 10^3 / \mu\text{L}$, hemoglobin: 9.5 g / dL, hematocrit: 27.7%, platelet: $220 \times 10^3 / \mu\text{L}$, aPTT: 108 sec., international normalized ratio 1.08. A total of 4 unit TDP infusions were performed 12 hours before the operation. Control aPTT value was determined as 34.5 sec. The patient was heparinized for cardiopulmonary bypass. After the central cannulation, the patient had LIMA-LAD and saphenous vein graft from the aorta to the obtional diagonal bypasses. Protamine infusion was performed for neutralization. After that, 10cc / kg fresh frozen plasma infusion was continued. An intravenous tranexamic acid infusion was started at a dose of 10 mg / kg. The patient had aPTT value of 41 sec on the postoperative 1st day. The patient was given 2 units of TDP infusion. The mediastinum and thorax drains were removed due to the lack of significant drainage of the patient. Sinus rhythm was achieved in the patient who was started on amiodarone infusion due to atrial fibrillation attack on postoperative 3rd day. The patient was discharged on the 8th postoperative day without any complications.

DISCUSSION AND CONCLUSION:Factor FXI replacement therapy is indicated for the treatment of surgical prophylaxis or symptomatic bleeding due to the risk of bleeding. It is recommended to perform tranexamic acid infusion with TDP for bleeding control. Hemophilia C is a disease that can cause serious bleeding disorders and the case with coronary artery bypass surgery requiring high dose heparinization is not detected in the literature. We believe that the major surgical intervention to be performed in this patient group with a tendency to bleeding can be safely performed in the case of perioperative planning.

ID: 86

Topic: **Cardiovascular Surgery » Coronary Bypass Surgery**Presentation Type: **Oral****OFF-PUMP GRAFTING DOES NOT REDUCE POSTOPERATIVE
PULMONARY DYSFUNCTION****Farouk Almohammad, Mohammad Bashar Izzat***Damascus University Cardiac Surgery Hospital, Damascus, Syria***Corresponding Author (dr.farok85@hotmail.com)**dr.farok85@hotmail.com, mbizzat@gmail.com***Abstract Text****Background**

Pulmonary dysfunction is a recognized postoperative complication that may be linked to use of cardiopulmonary bypass. The off-pump technique of coronary artery bypass grafting aims to avoid some of the complications that may be related to cardiopulmonary bypass. In this study, we compared the influence of on-pump or off-pump coronary artery bypass on pulmonary gas exchange following routine surgery.

Methods

Fifty patients (mean age 60.4±8.4 years) with no preexisting lung disease and good left ventricular function undergoing primary coronary artery bypass grafting were prospectively randomized to undergo surgery with or without cardiopulmonary bypass. Alveolar/arterial oxygen pressure gradients were calculated prior to induction of anesthesia while patients were breathing room-air, and were repeated postoperatively during mechanical ventilation and after extubation while inspiring 3 specific fractions of oxygen.

Results

Baseline preoperative arterial blood gases and alveolar/arterial oxygen pressure gradients were similar in both groups. At both postoperative stages, the partial pressure of arterial oxygen and alveolar/arterial oxygen pressure gradients increased with increasing fraction of inspired oxygen, but there were no statistically significant differences between patients who underwent surgery with or without cardiopulmonary bypass, either during ventilation or after extubation.

Conclusions

Off-pump surgery is not associated with superior pulmonary gas exchange in the early postoperative period following routine coronary artery bypass grafting in patients with good left ventricular function and no preexisting lung disease.

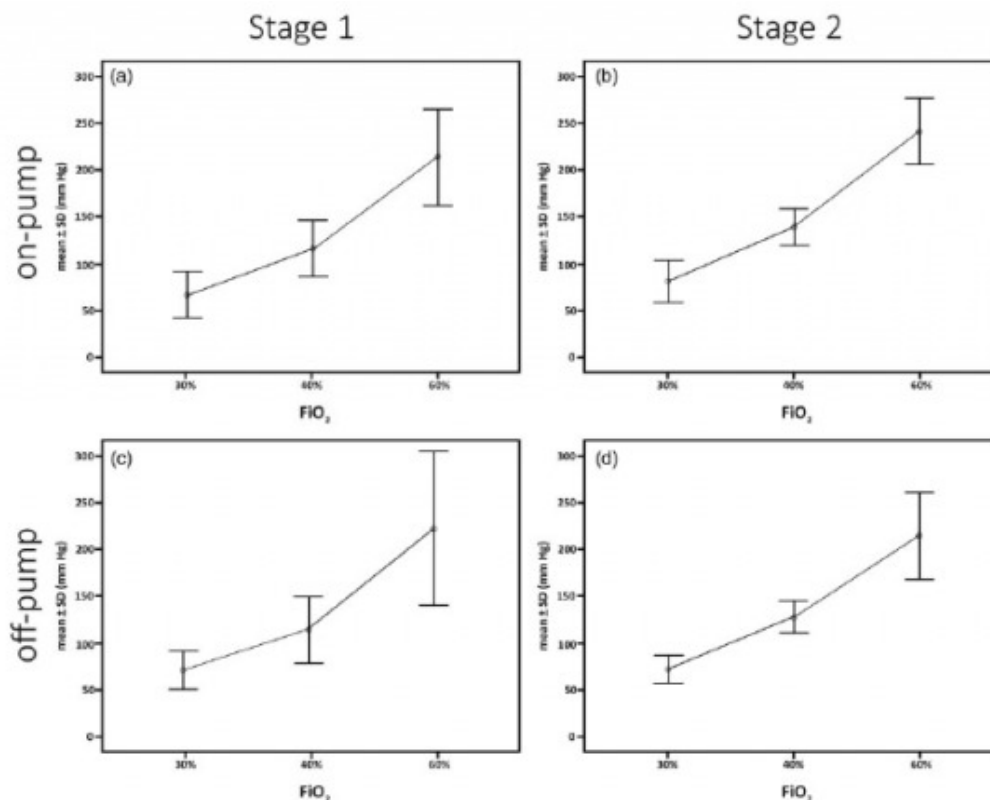


Figure 1. Postoperative alveolar/arterial oxygen pressure gradients in (a, b) the on-pump and (c, d) off-pump groups; a and c show results in stage 1, and b and d show results in stage 2. FiO₂: fraction of inspired oxygen.

Table 2. Arterial blood gas analyses and alveolar/arterial oxygen pressure gradients.

Pressure (mm Hg)	Group A (on-pump)			Group B (off-pump)		
	Preop	Postop		Preop	Postop	
		Stage 1*	Stage 2 [†]		Stage 1*	Stage 2 [†]
PaO₂						
Air [‡]	79.2 ± 15.9			82.6 ± 10.0		
30%		105.8 ± 22.6	89.6 ± 16.0		104.5 ± 19.7	97.9 ± 17.0
40%		126.3 ± 32.2	104.3 ± 21.0		138.2 ± 34.6	115.3 ± 26.7
60%		173.6 ± 48.4	140.0 ± 48.8		182.9 ± 78.6	164.3 ± 40.4
PaCO₂						
Air	38.2 ± 3.9			37.3 ± 3.0		
30%		36.3 ± 5.7	38.5 ± 4.8		36.5 ± 3.8	38.0 ± 4.2
40%		37.1 ± 6.9	38.8 ± 5.0		35.4 ± 5.8	39.1 ± 4.5
60%		37.3 ± 5.4	38.6 ± 5.0		36.6 ± 5.7	40.8 ± 4.4
P(A-a)O₂						
Air [‡]	22.6 ± 13.5			20.4 ± 10.9		
30%		62.7 ± 21.5	72.0 ± 20.2		63.7 ± 19.5	68.4 ± 17.8
40%		112.4 ± 29.9	132.3 ± 22.1		102.7 ± 33.9	120.9 ± 24.0
60%		207.5 ± 47.1	237.1 ± 49.9		199.1 ± 77.3	212.4 ± 41.3

*Stage 1 is 2–4 h postoperatively with the patient on artificial ventilation. [†]Stage 2 is 1 h after extubation with the patient breathing spontaneously. [‡]Air is the preoperative sampling period with the patient breathing room air. P(A-a)O₂: alveolar/arterial oxygen pressure gradient; PaCO₂: partial pressure of arterial carbon dioxide; PaO₂: partial pressure of arterial oxygen; Preop: preoperative; Postop: postoperative.

Oral Presentation Session Strategies and Outcomes in Coronary Surgery

Date: 27.03.2019 Time: 16:15 - 17:45 Hall: 6

ID: 230

Topic: **Cardiovascular Surgery » Coronary Bypass Surgery**

Presentation Type: **Oral**

USE OF NATIVE Y-SAPHENOUS VEIN GRAFT IN MULTI-VESSEL CORONARY BYPASS SURGERY

Sinan Göçer¹, Mehmet Karaçalılar²

¹Bahçeşehir Üniversitesi Medicalpark Göztepe Hastanesi, İstanbul, Turkey

²Batman Bölge Devlet Hastanesi, Batman, Turkey

**Corresponding Author (drsinangocer@gmail.com)*

drsinangocer@gmail.com, m.karacalilar@gmail.com

Abstract Text

Objectives: Although the popularity of arterial grafts has increased, saphenous vein grafts are the most commonly used grafts in coronary bypass surgery. Left internal mammarian artery (LIMA) is the gold standard for left anterior descending (LAD) artery, while saphenous vein or arterial grafts are preferred for other coronary arteries. Saphenous vein is used in different configurations in multi-vessel bypass surgery. The advantages of usage of native Y-saphenous grafts were evaluated with this study.

Methods: The study consist of 32 patients with coronary artery disease who underwent 3 or more distal anastomoses between January 2014 and January 2018. Grafts are prepared by protecting Y configuration for the patients whom their anatomy fit to Saphenous Y-graft. All cases were performed under cardiopulmonary bypass. The distal anastomoses of the Y-graft were performed on the diagonal arteries, diagonal and obtuse marginal arteries or two obtuse marginal arteries. All proximal anastomoses were performed on the ascending aorta. Patients were evaluated according to short- and mid-term survival, newly developed cardiac events, reoperation needs, operation and cardiopulmonary bypass perfusion times

Results: In this study, there are no early postoperative cardiac events, reoperation or death. Coronary angiography performed in 3 patients due to angina in the second and third years. Results findings revealed that all anastomoses of y-saphenous grafts were open for these patients. No mortality was observed in the patients who were followed remotely. It is observed that 10-15 minutes shorter time for duration of operation and the duration of cardiopulmonary bypass due to reduction in the number of proximal anastomoses.

Discussion: Nativ Y-saphen technique has some advantageous: (1) less maneuvering of the aorta, (2) shortening of the operation and perfusion time, and (3) shorter incision of the saphenous leg. We believe that the use of native y-saphenous graft technique can be used safely with multi-vessel bypass operations planned for saphenous vein use. However long-term follow-up is required to make such claim.

ID: 249

Topic: **Cardiovascular Surgery » Coronary Bypass Surgery**Presentation Type: **Oral****HARVESTING MINIMALLY INVASIVE SAPHENOUS VEIN GRAFT WITH MAYO STRIPPER IN CORONARY BYPASS SURGERY****Sinan Göçer¹**, Tufan Şener¹, Betül Tuba Arslan¹, Ahmet Hakan Gerçekoğlu², Mustafa Güler²¹*Bahçeşehir Üniversitesi Göztepe Medicalpark Hastanesi, İstanbul, Turkey*²*Bahçeşehir Üniversitesi Göztepe Medicalpark Hastanesi, İstanbul, Turkey***Corresponding Author (drsinangocer@gmail.com)**drsinangocer@gmail.com, tufan.sener@medicalpark.com, betul.arslan@medicalpark.com, hakan.gercekoglu@medicalpark.com, drmguler@gmail.com***Abstract Text**

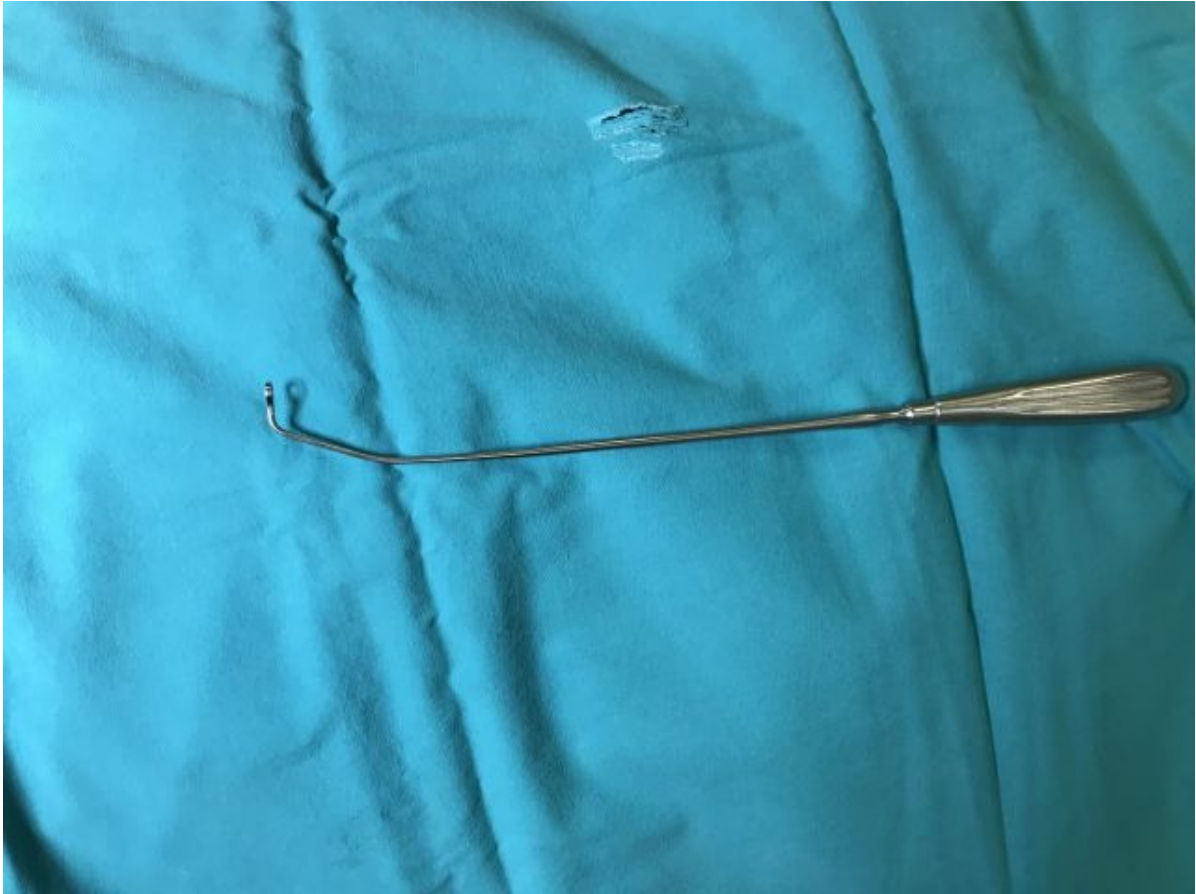Objective: The saphenous vein graft (SVG) is still indispensable for coronary bypass surgery (CABG). In this study, minimally invasive SVG harvesting technique was evaluated by using Mayo stripper as an alternative to endoscopic and conventional techniques.

Methods: Between January 2015 and December 2018, 313 patients who underwent CABG using 1 or more saphenous vein grafts were included in the study. In all cases, stripper was used to prepare SVG. Approximately 2 cm incision was made from the proximal of the medial malleol and the saphenous vein was found and ligated. The number 0 silk binding and the saphen attached to the distal end of the graft were passed through the stripper's ring. The stripper was moved proximally, and mini-incisions of approximately 1-2 cm in length were made at the resistance points. The lateral branches were tied and the graft was extended according to the number of grafts needed. Incisions were closed with single matrix sutures. After the procedure, the leg was wrapped with elastic bandage. The patients were dressed with anti-embolic sock on the first postoperative day.

Results: The duration of hospital stay, bleeding, reoperation requirement, wound healing, infection, pain, physical restriction and emotional status were evaluated. One patient had wound infection. 6 patients underwent exploration due to bleeding. Mayo stripper and saphenous extraction techniques were found to be better compared to the conventional technique. Although there is no clinically significant difference in terms of endoscopic technique known to have a high cost, it is quite advantageous in financial terms.

Conclusion: The technique should be performed by experienced people in CABG patients who are expected to use saphenous vein grafts. The harvesting of SVG with mayo stripper was thought to be an available method with economical, fast and acceptable results.

Picture: 1 Mayo Vein Stripper



ID: 255

Topic: Cardiovascular Surgery » Microcircuits in Cardiopulmonary Bypass

Presentation Type: Oral

**ASSOCIATION BETWEEN PEAK LACTATE LEVEL AND
POSTOPERATIVE OUTCOME DURING ADULT CARDIOPULMONARY
BYPASS SURGERY**

Ahmet Dolapoglu

Balikesir University Medical School, Balikesir, Turkey

**Corresponding Author (ahmetdolapoglu@yahoo.com)*

ahmetdolapoglu@yahoo.com

Abstract Text

OBJECTIVE: To assess the effect of the peak lactate levels during cardiopulmonary bypass on postoperative outcome in adult patients undergoing cardiac surgeries.

METHODS: An eighty one adult patients with coronary artery disease or valvular heart disease underwent elective cardiac surgery with using cardiopulmonary bypass were included into the study. All patients charts were reviewed retrospectively. Intra-operative peak lactate level, patient's clinical characteristics, surgical details and postoperative outcomes were recorded.

RESULTS : A total of 81 patients including 56 men, with a mean age of 63.1 ± 8.97 years, were enrolled. Patients were divided into two group according to peak lactate level of 2 mmol/L. Patients with peak lactate level ≥ 2 mmol/L (n=39 patients) had significantly higher preoperative body mass index ($p=0.0077$) and diuretic usage ($p=0.0012$) than patients with peak lactate < 2 mmol/L (n=41 patients). Cardiopulmonary bypass and cross clamp times were significantly longer in lactate ≥ 2 mmol/L group (<0.0001 for both). While there was no significantly difference in postoperative early mortality between groups, requirement of inotropi ($p=0.0097$) was significantly higher in patients with peak lactate level ≥ 2 mmol/L. Additionally, elevated peak lactate level was associated with longer postoperative hospital stay ($p = 0.036$).

CONCLUSIONS: Higher intra-operative peak lactate level was associated with increase requirement of postoperative inotropic support and longer length of hospital stay in adult patients undergoing cardiopulmonary bypass.

ID: 214

Topic: **Cardiovascular Surgery » Coronary Bypass Surgery**Presentation Type: **Oral**

THE EFFECT OF GENDER ON POSTOPERATIVE BLEEDING AFTER CORONARY BYPASS SURGERY IN DIABETIC PATIENTS UNDER CLOPIDOGREL THERAPY: EVALUATION OF 279 PATIENTS

Erdem Çetin¹, Levent Altınay²

¹Karabük University Medicine Faculty, Karabük, Turkey

²Bulent Ecevit University Medicine Faculty, zonguldak, Turkey

*Corresponding Author (erdem1978@gmail.com)

erdem1978@gmail.com, laltinay@gmail.com

Abstract Text

Background. Clopidogrel is a potent antiplatelet drug used in coronary artery disease for anti-aggregation before and after any coronary intervention including open heart surgery. Diabetic patients have more risk of cardiovascular mortality and morbidity after coronary bypass surgery than non-diabetic patients. We aimed to evaluate the effect of gender on postoperative bleeding in diabetic patients under clopidogrel therapy.

Methods. Two hundred and seventy-nine diabetic patients who were undergone coronary artery bypass grafting (CABG) operations between April 2014 and August 2016 included in this retrospective study. Patients were divided into groups according to gender and each of these groups divided into groups in regard to preoperative clopidogrel medication. According to this grouping method: Group 1a included female clopidogrel users and Group 1b included females with no anti-platelet drugs, Group 2a included male clopidogrel users and Group 2b included males with no antiplatelet drugs. All of the operations were done with beating heart technique. Clopidogrel or any other antiplatelet medications were ceased 7 days before the operation if the patients were under and low molecular weight heparin was administered once a day until the operation. Clopidogrel was administered in all of the patients on the first postoperative day regardless of their preoperative medications. Postoperative chest tube drainage amounts were recorded.

Results. Seventy-two (25,8%) patients were female and 207 (74,2%) patients were male. The mean age was $62,65 \pm 8,92$ years. The mean preoperative ejection fraction was $49,79 \pm 9,71\%$. Group 1a included 14 (19,4%), Group 2b included 58 (80,6%), Group 2a included 41 (19,8%) and Group 2b included 166 (80,2%) patients. The drainage amounts of the groups were as follows: in Group 1a $824,43 \pm 171,77$ ml; in Group 1b $709,48 \pm 195,44$ ml; in Group 2a $723,17 \pm 159,72$ ml; in Group 2b $674,10 \pm 146,34$ ml. The drainage amount of Group 1a was

significantly higher when compared to the drainage amount of Group 2a but there was no significant difference of drainage amounts of Group 1b and Group 2b ($p=0,043$ and $p=0,228$ respectively). Also there was a significant difference of the drainage amounts of Group 1a and 1b but no significant difference of groups 2a and 2b in regard to drainage amount ($p=0,037$ and $0,142$ respectively).

Conclusion. Clopidogrel effects the postoperative bleeding amount more in female diabetic patients than male diabetic patients.

Keywords: Coronary bypass surgery, postoperative bleeding, clopidogrel, diabetes, gender

ID: 206

Topic: Cardiovascular Surgery » Coronary Bypass Surgery

Presentation Type: Oral

NEW GENERATION ANTIAGGREGANT TREATMENT FOR PATIENTS RECEIVING CORONARY BY-PASS SURGERY

Kamuran Erkok

VM Medicalpark Bursa Hospital, Bursa, Turkey

**Corresponding Author (kamuranerkoc@hotmail.com)*

kamuranerkoc@hotmail.com

Abstract Text

Objective: The aim of this study is to investigate the effects of new generation antiaggregant (NGA) therapy on drainage, blood use and mortality after coronary bypass operation.

Methods: A total of 945 patients who applied coronary by-pass procedure in our institution between dates November 2012 and November 2018 were included in this study. Among these, 145 patients (Group 1) continued to receive new generation antiaggregant treatment, 413 patients (Group 2) stopped receiving this treatment in an average time of 47 hours (24-96 hours) before surgery, the remaining 387 patients (Group 3) however have not received any treatments in this manner. Acetylsalicylic acid (100-300gr) treatment was not stopped before operation. Patients whom these medications stopped while receiving NGA were administered with low molecular weight heparin. Most frequently used NGA's were determined as Clopidogrel (82%), Ticagrelor (12%), GPIIa-IIIa inhibitors (6%) respectively. Patients in Group 1 consisted of emergency priority in operation indication. In Group 1, the number of patients who had invasive procedures within the last 12 hours was 56 (38.6%), while the remaining were operated without any interventions after angiography. In Group 2, the number of patients who previously received an angiographic interventions was determined to be 386 (98%). In Group 3, the number of patients who had coronary angiography was 36 (9.3%) while the remaining received angiography for the first time. The mean number of grafts in patients operated while receiving NGA, after stopping treatment and not received NGA treatment were determined as 4.1 (1-6), 4.0 (1-5) and 4.1 (1-6) respectively.

Results: Drainage in Group 1, Group 2 and Group 3 was estimated to be 550 ± 180 cc, 400 ± 150 cc, and 400 ± 120 cc respectively with no statistically significant differences determined between each group ($p>0.05$). 2 patients (1.3%) in Group 1, 6 patients (1.4%) in Group 2 and 5 patients (1.3%) in Group 3 were taken back to the operation due to early period tamponade. Blood transfusion rates were estimated as 2.8 units (1-5) in Group 1, 2.3 units (1-4) in Group 2 and 2.2 units (1-4) in Group 3 ($p>0.05$). Erythrocyte suspensions were used as blood transfusions for all patients. Mortality rates between Groups 1, 2 and 3 were 3 patients (2%), 5 patients (1.2%) and 4 patients (1.0%) respectively with no statistical significance ($p>0.05$).

Conclusion: In patients operated with, without or after stopping new generation antiaggregant treatment had no significant differences in means of drainage, blood transfusion, and mortality rates.

ID: 205

Topic: **Cardiovascular Surgery » Coronary Bypass Surgery**Presentation Type: **Oral****SURGICAL OUTCOMES OF ISOLATED CABG IN PATIENTS WITH MODERATE ISCHEMIC MITRAL REGURGITATION**Seymur Musayev¹, Matin Hadizade², Vusal Mammadov¹, Calala Qarayeva¹, Reshad Mahmudov¹¹Central Hospital for Oilworkers, Baku, Azerbaijan²Central Hospital for Oilworkers, Baku, Azerbaijan

*Corresponding Author (emin405@hotmail.com)

emin405@hotmail.com, emin405@hotmail.com, emin405@hotmail.com, emin405@hotmail.com,
emin405@hotmail.com**Abstract Text**

BACKGROUND: We retrospectively evaluated early and late outcomes of patients undergoing isolated CABG with moderate ischemic mitral regurgitation.

METHODS: 25 patients (63.4±/-9.5 years) with moderate ischemic MR underwent isolated CABG between December 2012 and September 2015. 4 patients had Diabetes Mellitus type II, 8 patients had arterial hypertension, 2 patients had chronic renal insufficiency and 2 patients had previous cerebrovascular event. Patients were also grouped according to their ejection fraction (EF), thus 6 patients had 20-30%, 7 patients had 31-40%, 7 patients had 41-50% and 5 patients had > 50%. 3 patients had high SPAP > 40 mmHg.

RESULTS: Except 1 patient, all the patients survived to discharge. Mean aortic cross clamping time was 35 ± 7 minutes; mean cardiopulmonary bypass time was 49 ± 8 minutes. 12 patients had mild inotrope support while weaning off CPB. IABP was implanted in 1 patient whose CPB time was 220 minutes, whose weaning off CPB was possible with high inotrope support. Intensive care unit stay was 39 ± 10 hours in 17 patients and 72 ± 38 hours in 6 patients and 2 patients exceeded 5 days. 1 patient had dialysis due to acute renal failure, which recovered after 4 days. 21 patient underwent echocardiographic and stress-test checkup in 1 and 3 year after the surgery. There was increase in left ventricle dimension and increase in NYHA function compared to preoperative data (p<0.001).

CONCLUSIONS: Isolated CABG can be performed with acceptable results in patients with moderate ischemic mitral insufficiency. However, in order to improve cardiac remodeling and patient's quality of life we advocate performing mitral valve repair concomitant with CABG preferable in well experienced center.

ID: 439

Topic: **Cardiology » Coronary Artery Disease - CABG Surgery**Presentation Type: **Oral****THE USE OF DEL NIDO CARDIOPLEGIA FOR MYOCARDIAL PROTECTION IN ISOLATED CORONARY ARTERY BYPASS SURGERY**Mustafa Çağdaş Çayır¹, Ahmet Yüksel²¹*Pamukkale University Faculty of Medicine, Denizli, Turkey*²*Abant İzzet Baysal University Faculty of Medicine, Bolu, Turkey***Corresponding Author (dr.mcc@hotmail.com)**dr.mcc@hotmail.com, ahmetyuksel1982@mynet.com***Abstract Text**

BACKGROUND: Del Nido (DN) cardioplegia solution has been widely used in pediatric open-heart surgery for years; however, its application in adult open-heart surgery has not gained sufficient popularity yet. We investigated the safety and efficiency of DN cardioplegia solution as compared with the traditional crystalloid cardioplegia solution which named as “St. Thomas’ Hospital (STH) cardioplegia solution” in adult patients undergoing coronary artery bypass grafting (CABG).

METHODS: A retrospective comparative analysis of 200 consecutive patients undergoing isolated on-pump CABG operation between April 2016 and September 2017 was performed. Patients were divided into two groups as DN group (n=100) and STH group (n=100). Groups were compared with each other regarding perioperative clinical outcomes, and the safety and efficiency of DN cardioplegia solution in CABG surgery were evaluated.

RESULTS: In DN group, mean aortic cross-clamp, cardiopulmonary bypass and total operation times were significantly shorter than STH group. After the release of aortic cross-clamp, intraoperative defibrillation requirement was significantly lesser in the DN group. There were no significant differences in terms of the levels of perioperative cardiac biomarkers including creatine kinase-myocardial band (CK-MB) and troponin I, major postoperative adverse events and in-hospital mortality between the groups.

CONCLUSIONS: This study revealed that the use of DN cardioplegia solution in adult patients undergoing isolated CABG provides significantly shorter aortic cross-clamp, cardiopulmonary bypass and total operation times as compared with the traditional cardioplegia. DN cardioplegia solution could be used as a safe and efficient alternative to the traditional cardioplegia solutions in CABG surgery.

ID: 520

Topic: **Cardiology » Coronary Artery Disease - CABG Surgery**Presentation Type: **Oral****CORONARY ENDARTERECTOMY IN AORTA CORONARY BYPASS GREFT OPERATIONS**Mustafa Dağlı¹, **Ilker Mercan**²*¹University of Health Sciences Konya Education and Research Hospital, Konya, Turkey***Corresponding Author (drmustafaaaa@gmail.com)**drmustafaaaa@gmail.com, drmustafaaaa@gmail.com***ABSTRACT****OBJECTIVE,**

Coronary endarterectomy is one of the earliest forms of treatment for occlusive coronary artery disease. Though the long term patency of endarterectomised vessels are inferior, several authors have demonstrated satisfactory long term patency. This procedure is a useful tool in the surgeons armamentarium.

METHODS,

Coronary endarterectomy can safely be performed on aorta coronary bypass graft operations. But previously, anticipated endarterectomy had been considered a contraindication to beating heart aorta coronary bypass graft operations. Thirteen patients underwent 16 coronary endarterectomies. Six to the LAD, 6 to the RCA, 2 to the CX-OM, one to the diagonal and RCA-PDA. Two patients underwent coronary endarterectomy during beating heart aorta coronary bypass graft operation (LAD-RCA). The patients age range was between 38-81 years. 61,5 % of the patients had diabetes mellitus. All of patient had hypertension. Average Euroscore is 8,9.

RESULTS,

Four patients died in the immediate post operative period. Three patients suffered a perioperative myocardial infarctions who coronary artery diameters below 0.5 mm. Two patients had renal dysfunction which recovered with conservative management. Follow up rates from 3-8 months.

CONCLUSIONS

Coronary endarterectomy can be safely carried and can be extended to patients with severe occlusive coronary artery disease.

ID: 412

Topic: Cardiology » Coronary Artery Disease - CABG Surgery

Presentation Type: Oral

CAN FRAGMENTED QRS PREDICT POSTOPERATIVE ATRIAL FIBRILLATION IN PATIENTS AFTER CORONARY ARTERY BYPASS GRAFTING?

Seçkin Dereli

Ordu State Hospital, Ordu, Turkey

*Corresponding Author (drseckindereli@gmail.com)

drseckindereli@gmail.com

Abstract Text

Background: Postoperative atrial fibrillation (POAF) is the most common cardiac rhythm after coronary artery bypass grafting (CABG). Arrhythmia causes prolonged hospitalization and may affect both short- and long-term prognosis. A simplified non-invasive ECG marker Fragmented QRS (fQRS) has recently been noted as a diagnostic and prognostic marker in various cardiovascular pathologies. In this study we aimed to investigate the association between fQRS and POAF

Methods: The study was performed on 492 patients who underwent CABG in Ordu State Hospital between 2016–2019 years. AF was diagnosed using standard clinical criteria and fQRS was defined as presence of at least 1 of the following findings in 12-lead routine ECG: presence of an additional R wave (R'), notching of R or S wave, or >1 R' fragmentation in 2 contiguous leads. Data on co-existing diseases, as well as data collected at the time of surgery and in the post-operative period, were evaluated.

Results: Emergency CABG was performed on 12% of patients, whereas 85% of patients underwent CABG with the use of extracorporeal circulation. Based on the incidence of POAF, the post-CABG patients were classified into a POAF(+) group that comprised 103 (21%) patients, and a POAF(-) group involving 389 (79%) patients. The first occurrence of arrhythmia during the first three days after surgery was observed in 75% of patients. The average age of POAF(+) and POAF(-) patients was 68.7 ± 8.8 years and 63.5 ± 8.9 years, respectively ($p < 0.0001$). The respective incidence rates of co-existing diseases in patients with POAF and those without POAF were as follows: arterial hypertension, 80.1% vs. 75.8% ($p = 0.29$); heart failure, 18.7% vs. 21.1% ($p = 0.56$); type 2 diabetes, 24.1% vs. 26.2% ($p = 0.64$). The association of different variables with POAF was calculated using univariate and multivariate analysis. Age [OR: 1.320 (1.023-1.703 95% CI), $p=0.032$] and fQRS [OR: 3.029 (1.013-9.055 95% CI), $p=0.047$] were observed to be independent predictors of POAF.

Conclusions: In this study, age and fQRS level were independent predictors of AF after CABG surgery. Patients with fQRS on ECG were at higher risk of AF after CABG surgery.

Table 5. Univariate and multivariate logistic regression analyses of predictors of atrial fibrillation after CABG

	Univariate analysis		Multivariate analysis		
	OR (95% CI)	P	OR	95% CI	P
AGE	1.126 (0.975-1.301)	0.002	1.320	1.023-1.703	0.032
Male sex	1.064 (1.012-1.119)	0.010			
BMI	1.242 (1.080-1.427)	0.001			
GFR	1.005 (0.989-1.021)	0.400			
DM	0.111 (0.026-0.479)	0.001			
HT	0.155 (0.032-0.745)	0.011			
Gensini score	5.833 (1.904-17.868)	0.001			
LA diameter	2.196 (1.382-3.491)	0.001			
Cardiopulmonary bypass time	1.002 (0.964-1.041)	0.934			
Cross clamp time	0.924 (0.796-1.072)	0.298			
fQRS	3.614(1.972-6.622)	0.001	3.029	1.013-9.055	0.047

OR: Odds ratio; CI: Confidence Interval; P: p value; BMI: Body mass index; GFR: Glomerular filtration rate; DM: Diabetes; HT: Hypertension; LA: left atrium; fQRS: fragmented QRS

Oral Presentation**New ECG Parameters in Clinical Practice**

Date: 28.03.2019 Time: 08:00 - 09:00 Hall: 5

ID: 160**Topic: Cardiology » Electrocardiography and Non Invasive Electrocardiology****Presentation Type: Oral****NEW ARRHYTHMIA PARAMETERS IN PATIENTS WITH CHRONIC OBSTRUCTIVE PULMONARY DISEASE****Songül Usalp¹, Ümit Yüksek¹, Onur Akpınar¹, Emine Altuntaş², Levent Cerit¹, Hamza Duygu¹***¹Near East University, Nicosia, Cyprus**²Büyükcçekmece devlet hastanesi, Istanbul, Turkey***Corresponding Author (dr.songulusalp@hotmail.com)**dr.songulusalp@hotmail.com, uyuksekk@yahoo.com, onurakpinar@yahoo.com, emine_altuntas@hotmail.com, drcerit@hotmail.com, hamzakard@yahoo.com***Abstract Text**

BACKGROUND: The incidence of arrhythmia is increased in patients with chronic obstructive pulmonary disease (COPD). P wave dispersion (PwD) is important in determining the risk of AF development. QT dispersion (QTd) and QTc dispersion predict increased risk of malignant cardiac arrhythmias and sudden cardiac death (SCD). Our aim was to compare PwD, corrected P wave dispersion (cPwD), QT, QTc duration and QTc dispersion (QTcD) of patients with stable COPD with the normal population.

METHODS: We recruited fifty-seven patients to the study, who were followed in our Chest Diseases Clinic with COPD. The stability of COPD was determined with respiratory function testing (RFT). Forty age and sex matched normal controls were evaluated with physical examination, RFT. Electrocardiograms with 50 mm/sec speed and 1 mV amplitude were taken from all participants. P wave length was measured in all derivations from at least 2 beats. The shortest and longest P wave lengths were used to calculate PwD. The QTd was defined as the difference between the maximum (QT max) and minimum QT (QT min) intervals of the 12 leads. The difference between the corrected QTmax (cQT max) and corrected QTmin (cQT min) was defined as corrected QTd (QTcD).

RESULTS: Totally, 97 participants were enrolled in the present study. There was no significant difference between the control and study groups for sex, current smoking status, body mass index (BMI), arterial hypertension and diabetes mellitus prevalence, serum glucose and creatinine levels (p=0.124, p=0.135, p=0.195, p=0.096, p=0.072, p=0.519, p=0.160 respectively). The mean age of patients in the COPD group was higher than in the control group (p<0.001). In COPD group serum haemoglobin and haematocrit levels were also higher than in the control group (p=0.002, p=0.003 respectively). PwD and cPwD were found to be prolonged in COPD patients when compared to controls (p = 0.001). The QTd, QTc, QTcD intervals were all longer in COPD patients compared to healthy controls (p=0.009, p=0.001, p = 0.012, respectively). QT interval showed no significant difference in COPD patients and matched controls (p = 0.701). Ascending aorta diameters were similar between the two groups (p=0.407). But, left atrial size, right atrial size, Spap and TAPSE values were higher in COPD patients when compared with the control group (p=0.033, p=0.026, p<0.000, p<0.000 respectively). **CONCLUSION:** COPD population has altered cardiac repolarisation and increased dispersion of repolarisation, which may be related to hypoxia. Altered cardiac repolarisation may expose these patients to an increased risk of supraventricular and ventricular arrhythmias.

ID: 83

Topic: Cardiology » Electrocardiography and Non Invasive Electrocardiology

Presentation Type: Oral

P-WAVE AND QT DISPERSIONS IN THE CONTEXT OF SEVERE CAROTID ARTERY DISEASE

Efe Edem

Tınaztepe Hospital, İzmir, Turkey

**Corresponding Author (edemefe@gmail.com)*

edemefe@gmail.com

Abstract Text

Objectives: The aim of the current study was to evaluate the relationship between P-wave and QT dispersions (PWD and QTD) in the context of severe CAD.

Methods: 167 patients who underwent carotid angiography (CA) between May 2009 and June 2017 were retrospectively enrolled in the study. Group 1 consisted of patients who were diagnosed with a carotid stenosis (CS) of <50% on CA in whom eventual medical treatment was applied (n:79). Group 2 consisted of patients who were diagnosed with a ≥50% CS on CA in whom surgery was eventually performed (n:88).

Results: A ROC curve analysis of eventually the two groups demonstrated that PWD was significantly higher in Group 2 (AUC: 0.865995; p<0.0001). On the other hand, ROC curve analysis of the two groups demonstrated that QTD was significantly higher in Group 2 (AUC: 0.759288; p<0.0001). A comparison of the ROC curves of PWD and QTD indicated that PWD was superior to QTD in terms of predicting a carotid artery stenosis of ≥50% (p=0.0248).

Conclusions: Interpreting PWD and QTD seems to be a non-invasive and cost-effective method for identifying high-risk patients for CoAD in the context of severe CAD.

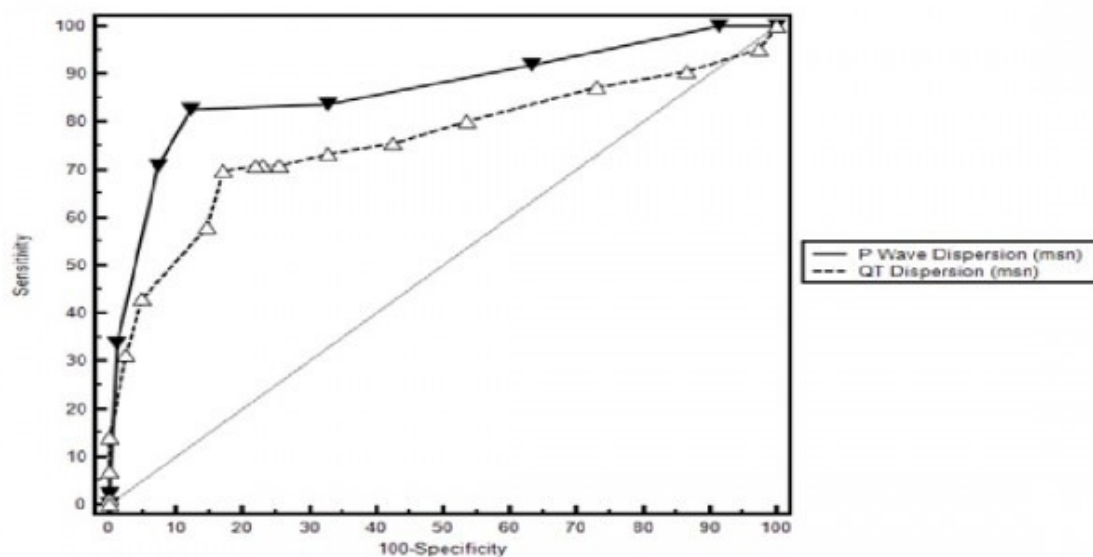


Figure 1 - Comparison of ROC curves of P Wave Dispersion and QT dispersion indicating that PWD was superior to QTD in terms of predicting carotid artery stenosis of $\geq 50\%$ ($p=0.0248$).

	Group 1 (Medical Follow-up) (n:79)	Group 2 (Carotid Artery Surgery) (n:88)	P Value
Age (years)	57.5±11.76	68.97±9.16	p<0.001
Diabetes Mellitus (positive vs. negative)	(n:19 vs n:60) 24.0% vs. 76.0%	(n:32 vs n:56) 36.4% vs. 63.6%	p=0.140
Hyperlipidemia (positive vs. negative)	(n:26 vs n:53) 32.9% vs. 67.1%	(n:33 vs n:55) 37.5% vs. 62.5%	p=0.561
Hypertension (positive vs. negative)	(n:32 vs n:47) 40.5% vs. 59.5%	(n:46 vs n:42) 52.2% vs. 47.8%	p=0.117
Smoking (positive vs. negative)	(n:51 vs n:28) 64.5% vs. 35.5%	(n:45 vs n:43) 51.2% vs. 48.8%	p=0.109
COPD (positive vs. negative)	(n:5 vs n:74) 6.3% vs. 93.7%	(n:25 vs n:63) 28.5% vs. 71.5%	p=0.001
Gender (Male vs. Female)	(n:69 vs n:10) 87.3% vs. 12.7%	(n:61 vs n:27) 69.4% vs. 30.6%	p=0.026

Table 1 - Demographic characteristics of the study group.

ID: 4

Topic: **Cardiology » Electrocardiography and Non Invasive Electrocardiology**Presentation Type: **Oral****EFFECT OF LOWER AND HIGHER CALORIE MEAL ON THE PARAMETERS OF VENTRICULAR REPOLARIZATION IN HEALTHY SUBJECTS****Erdoğan Sökmen, Hacı Mehmet Çalışkan, Mustafa Çelik, Serkan Sivri, Sinan Cemgil Özbek***Kirsehir Ahi Evran Education and Research Hospital, Kirsehir, Turkey***Corresponding Author (erdoganmen@gmail.com)**erdoganmen@gmail.com, hmehmet.40@hotmail.com, muscelik50@gmail.com, drserkansivri@gmail.com, ozbeksc@gmail.com***Abstract Text**

Background: Cardiovascular modulation following meal consumption has been known. Little and conflicting data is present regarding electrocardiographic QT and QTc intervals after meal, and status of ventricular repolarization following meal is not known comprehensively.

Aim: Our aim is to inquire thoroughly the electrocardiographic status of ventricular repolarization after lower and higher calorie meal consumption in a comparative manner.

Methods: 61 healthy individuals were studied before and at the 2nd hour of lunch. They were divided into two groups according to the calorie consumed (higher calorie and lower calorie; median 1580 and 900 kcals, respectively). Calorie consumed was estimated using dietary guidelines. Data was collected from 12-lead ECG both in fasted state and 2nd postprandial hour for each participant. Parameters of ventricular repolarization, namely, JTp, Tp-e, QT, QTc intervals and their ratios, as well as RR intervals, were compared between fasted and postprandial states for every participant.

Results: Tp-e and QTc intervals, and Tp-e/QTc ratio does not significantly change after both higher- and lower-calorie meals. JTp and QT intervals significantly shorten in both groups, regardless of the calorie consumed. While JTp shows positive correlation with RR interval both before and after meal in lower calorie intake group, no correlation was found with RR interval after meal in higher calorie group. Logistic regression analysis revealed that higher calorie intake during meal is a predictor for greater shortening in JTp and QT, compared to lower calorie meal.

Conclusion: Tp-e interval, QTc interval and Tp-e/QTc ratio does not change significantly at 2nd postprandial hour, regardless of the amount of the calorie consumed. However, QT interval shortens, due almost solely to JTp interval shortening. Further, JTp interval shortening following higher calorie meal may not only be associated with increased heart rate, but also higher calorie consumption during meal, possibly through unproportional escalation in neuroendocrin and cardiovascular response. Lastly, higher calorie consumption at meal represents a predictor for greater JTp and QT shortening. This study may provide a new standpoint for further studies pertaining to ventricular repolarization, particularly those conducted on various disease conditions or drug effect of cardiac electrophysiology. However, further large scale studies are warranted to justify our study results.

ID: 496

Topic: **Cardiology » Arrhythmias and Antiarrhythmic Therapy**Presentation Type: **Oral****HEART RATE VARIABILITY IN PATIENTS WITH ACUTE PULMONARY EMBOLISM****Beste Ozben**, Nurten Sayar, Tuba Bayram, Murat Sunbul, Özge Can Bostan, Altuğ Çinçin, Emre Gurel, Hasan Özdil, Alper Kepez, Kürşat Tigen, Emel Eryuksel*Marmara University School of Medicine, Istanbul, Turkey***Corresponding Author (besteozen@yahoo.com)**besteozen@yahoo.com, sayarnurten@gmail.com, dr.tubik@gmail.com, drsunbul@yahoo.com.tr, ozge.can20@hotmail.com, acincin@yahoo.com, emregurelctf@yahoo.com, terslale87@hotmail.com, alperkepez@yahoo.com, mktigen@yahoo.com, emeleryuksel@yahoo.com***Abstract Text**

Background: Heart rate variability is a validated method to evaluate cardiac autonomic system dysfunction and alterations in heart rate variability are used to predict arrhythmic events. Sudden cardiac death is a major cause of mortality in patients with pulmonary hypertension. The aim of this study was to evaluate heart rate variability in patients with acute pulmonary embolism.

Methods: Seventy-one patients with confirmed acute pulmonary embolism and 50 normal subjects were consecutively enrolled. All patients underwent 24-hour holter ECG recording for heart rate variability assessment by time- and frequency-domain analysis. The left and right ventricular functions of the patients and controls were evaluated by speckle tracking echocardiography.

Results: Thirty-four patients had submassive pulmonary embolism while 37 patients had nonmassive pulmonary embolism. The characteristics and heart rate variability parameters of the patients and controls are listed in the Table. Both right and left ventricular functions of the pulmonary embolism patients were decreased compared to controls. Heart rate variability parameters were significantly lower in both acute pulmonary embolism patient groups compared to controls.

Conclusions: Acute pulmonary embolism patients had reduced heart rate variability irrespective of being submassive or nonmassive, which might be indicating a high risk for malignant arrhythmic events.

	Patients with submassive pulmonary embolism (n= 34)	Patients with nonmassive pulmonary embolism (n= 37)	Controls (n= 50)	p
Age (years)	69.0 ± 11.3 ^{ab}	54.8 ± 13.4	36.0 ± 10.0	<0.001
Male sex (n-%)	18 (52.9%)	13 (35.1%)	29 (58.0%)	0.097
Left ventricular ejection fraction (%)	50.7 ± 5.6 ^a	53.3 ± 7.3	55.0 ± 5.0	0.008
Left ventricular global longitudinal strain (%)	16.9 ± 2.9 ^a	18.0 ± 2.0 ^a	20.3 ± 2.2	<0.001
Right ventricular global longitudinal strain (%)	16.6 ± 3.9 ^a	17.9 ± 2.5 ^a	20.7 ± 3.1	<0.001
RR interval (ms)	720.4 ± 114.2 ^a	763.4 ± 91.7 ^a	795.7 ± 83.6	0.006
SDNN (ms)	86.2 ± 49.4 ^a	108.8 ± 38.3 ^a	148.9 ± 32.4	<0.001
SDANN (ms)	73.6 ± 47.2 ^a	96.6 ± 37.2 ^a	140.1 ± 34.9	<0.001
SDNNindex (ms)	37.5 ± 20.0 ^a	43.7 ± 18.6 ^a	56.8 ± 14.3	<0.001
pNN50 (%)	13.7 ± 19.1	7.2 ± 13.2	9.7 ± 9.0	0.144
RMSSD (ms)	33.7 ± 23.9	26.6 ± 19.8	30.9 ± 12.7	0.289

SDNN: Standard deviation of all normal R-R intervals, SDANN: Standard deviation of all the 5-minute R-R interval means, pNN50: Percentage of adjacent RR intervals >50 ms different, RMSSD: Root of mean squared differences of successive R-R intervals

Posthoc analysis: ^a significant compared to controls; ^b significant compared to nonmassive pulmonary embolism patients

ID: 58

Topic: Cardiology » Percutaneous Coronary Interventions in Acute Coronary SyndromesPresentation Type: **Oral****THE SIGNIFICANCE OF AVR DEPRESSION IN ACUTE ANTERIOR MYOCARDIAL INFARCTION**Mustafa Adem Tatlısu¹, **Muhammed Keskin**²¹*Istanbul Medeniyet University, Istanbul, Turkey*²*Sultan Abdülhamid Han Training and Research Hospital, Istanbul, Turkey***Corresponding Author (adem.tatlisu@medeniyet.edu.tr)**adem.tatlisu@medeniyet.edu.tr, drmuhammedkeskin@gmail.com***Abstract Text**

Background: The ST-elevation in lead aVR with extensive ST-segment depression has been found to be a sign of the left main or ostial-proximal left anterior descending artery stenosis. On the contrary, the importance of the ST-segment depression in lead aVR in the setting of acute anterior myocardial infarction (AAMI) is unknown. The vector of aVR is orientated from the cardiac apex to the outflow tract of the right ventricle. Therefore, transmural apical infarction may produce aVR ST-segment depression. The objective of the study was to investigate the association of the aVR ST-segment depression in AAMI with in-hospital clinical events and all-cause mortality.

Methods: This study included 338 consecutive patients with AAMI treated with primary percutaneous coronary intervention (pPCI). Electrocardiograms were obtained just before. Patients were divided into two groups: aVR ST depression ≥ 1 mm as group 1, aVR ST depression < 1 mm as group 2. The baseline characteristics are shown in Table 1. The outcome was in-hospital recurrent myocardial infarction, target lesion revascularization, major adverse cardiac events, and all-cause mortality.

Findings: The aVR ST-segment depression ≥ 1 mm was associated with higher in-hospital clinical events (n=12, 26%) compared with patients without aVR ST-segment depression (n=22, 11.1%). This relationship remained after adjustment for all confounders (95% confidence interval: 1.23-1.73)(Table 2)

Conclusions: The ST-elevation in lead aVR with extensive ST-segment depression has been found to be a sign of the left main or ostial-proximal left anterior descending artery stenosis. This study showed that aVR ST-segment depression in AAMI is also associated with in-hospital clinical events. The ST changes in lead aVR are usually neglected, which are not an innocent sign and should be assessed.

Table 1 Comparison of demographic and clinical characteristics at presentation between patients in group 1 and group 2 (n=244)

Variables	Group 1 (n = 46)	Group 2 (n = 198)	p value
Age (years)	65.9±11.9	54.5±10.6	0.02
Male	30 (65.2)	168 (84.8)	0.01
Hypertension	32 (69.6)	73 (36.8)	0.01
Diabetes mellitus	12 (26)	33 (16.6)	0.15
Hyperlipidemia	14 (30.4)	100 (50.5)	0.03
Smoking	23 (50)	108 (54.5)	0.35
Systolic BP on admission (mmHg)	102±22	113±18	0.01
Killip class >1	26 (56.5)	68 (34.8)	0.01
Door-to-balloon times (min)	32±12	31±13	0.35
Left ventricular EF	36.5±11.8	47.6±5.4	0.01
Post-PCI TIMI 3 flow	23 (50)	175 (88.3)	0.02
Three-vessel disease	25 (54.3)	112 (56.5)	0.12
β-Blockers on admission	9 (19.6)	35 (17.6)	0.64
Hemoglobin (g/dl) on admission	13.9±1.4	14.1±1.4	0.38
Glucose (mg/dl) on admission	150 [82]	128 [59]	0.04
Creatinine (mg/dl) on admission	1.22±1.03	1.19±0.3	0.14
Peak CK-MB (U/l)	278 [231]	128 [146]	0.01
Total cholesterol (mg/dl)	171 [68]	190 [55]	0.08
LDL-cholesterol (mg/dl)	107.2±31.1	121.1±35.2	0.02
HDL-cholesterol (mg/dl)	40.5±16.8	37.2±10.3	0.22
Triglycerides (mg/dl)	112 [71]	139 [95]	0.05

Parametric variables are reported in mean±SD or median [interquartile range]; categorical variables are reported in number (%). BP, blood pressure; EF, ejection fraction; HDL, high-density lipoprotein; LDL, low-density lipoprotein; PCI, percutaneous coronary intervention; TIMI, Thrombolysis in Myocardial Infarction.

ID: 81

Topic: **Cardiology » PI for SHD - Others**Presentation Type: **Oral****TPE INTERVAL AND TPE/QT RATIO IN PATIENTS WITH VIRAL MYOCARDITIS****Ahmet Seyda Yılmaz¹, Fatih Kahraman², Mustafa Yazici³**¹*Rize State Hospital, Rize, Turkey*²*Kutahya Evliya Celebi EAH, Kütahya, Turkey*³*Karadeniz Teknik Universitesi, Trabzon, Turkey***Corresponding Author (ahmetseydayilmaz@gmail.com)**ahmetseydayilmaz@gmail.com, drfkahraman@gmail.com, myazici@ktu.edu.tr***Abstract Text****ABSTRACT**

BACKGROUND: Myocarditis is a disease marked by inflammation and damage of the myocytes. The Tpeak-Tend interval (Tpe interval) in precordial ECG leads reflex an index of transmural dispersion of repolarization. We aimed to predict the rise of ventricular arrhythmia and sudden cardiac death in patients with myocarditis through measuring of Tpe interval and Tpe/QT ratio.

METHODS: From January 2012 to January 2016 patients who admitted to emergency department with acute chest pain and determined elevated troponin I levels prospectively enrolled at the Ahi Evren Thoracic and Cardiovascular Centre. Patients have been done invasive diagnostic catheterization and determined coronary artery disease are excluded from the study. Finally the study population consisted of 67 patients and their ECGs (Electrocardiogram) and clinical features are recorded. 50 control patients without chest pain and proven normal troponin levels are included. The QT, QTc and TPE interval were manually measured with a ruler. Assessment of the ECG were done by 2 cardiologists and 1 computer engineer.

RESULTS: Tpe interval, QT interval and QTc interval were significantly prolonged in myocarditis group similarly (111±17; 85±15; respectively; p<0,001 and 393±43; 363±27; respectively; p<0,001 and 435±41; 400±21; respectively; p<0,001). We also found that TPE/QT ratio and TPE/QTc ratio were significantly higher in myocarditis patients compared to the control group (0,28±0,41; 0,23±0,03; respectively; p<0,001 and 0,25±0,04 ;0,23±0,12; respectively; p<0,001)

CONCLUSION: Tpe interval, QT and tpe/qt ratio may be utilized to specify the rise of myocarditis related ventricular arrhythmia. Myocarditis caused ventricular inflammation compose transmural dispersion of repolarization. This study is the first that novel indices, tpe interval and tpe/qt ratio, of ventricular arrhythmia are increased in patients with myocarditis.

Oral Presentation**Mastering in Transradial Interventions**

Date: 28.03.2019 Time: 09:00 - 10:00 Hall: 5

ID: 209**Topic: Cardiology » Percutaneous Coronary Interventions****Presentation Type: Oral****LEFT DISTAL RADIAL ARTERY ACCESS SITE IN TERMS OF
COMPLICATIONS AND RADIATION EXPOSURE; A COMPARISON
EVALUATION WITH THE RIGHT RADIAL ARTERY AND THE RIGHT
FEMORAL ARTERY IN CORONARY ANGIOGRAPGHY AND
INTERVENTIONS****Elton Soydan, Mustafa Akin***Ege University, Izmir, Turkey***Corresponding Author (eltonsoydan@hotmail.com)**eltonsoydan@hotmail.com, drmustafaakin35@gmail.com***Abstract Text**

BACKGROUND AND AIM: Transradial approach is shown to be more beneficial than the transfemoral approach in terms of vascular complications. Almost all of these studies are made with the right radial artery. Our aim of this study was to compare the new Access site: the left distal artery with the right radial artery and the right femoral artery approach in terms of complications and radiation exposure.

METHODS: Sixty one (61) Patients eligible for coronary angiography and or intervention were included in our study from May 2017 to June 2018. They were divided into three (3) groups according to the Access artery site. Different operators with different experiences performing the procedure were left blind of this study and freely decided the access artery site. The sheath size was 6 French for both the radial and femoral approach. Patients in whom the left distal radial artery was chosen as the access site had their left arm gently bent into their right groin with slight adduction and comfortable position of the hand. The operator stood at the right side of the patient where he could make the arterial puncture and continue with coronary interventions. All patients with a transradial approach had a cocktail of weight adjusted heparin, nitrate and serum physiologic to prevent radial artery occlusion. Demographic features, complications and radiation exposure were recorded during the hospital stay. To compare complications and radiation exposure we made multiple comparisons between the three groups by using Bonferroni and Dunnett T3 test with the SPSS 25 program and a significant value was defined as <0.05.

RESULTS: Mean age was 59.4 and 78.6 % of them was male. Right radial artery was used in 19 patients. Twenty (20) patients had left distal artery used as the access artery site. In the other 22 patients right femoral artery was used. The most common cardiovascular risk factors were Diabetes and Hypertension with 36% and 77% respectively. Almost one third of patients had coronary artery disease with previous intervention. Coronary intervention was contemplated in 40 patients where the left distal radial artery was the most common access site (15 patients). Only one radial spasm and hematoma occurred in the right radial access site. Femoral hematoma was encountered in only one patient in that manual compression was sufficient for treating it. Fluoroscopy time, total air kerma and total dose area product was found similar between the three groups without any significant difference. Only the left distal radial artery access site showed a lower trend towards radiation exposure (total dose area product; p: 0.65). Patients were discharged in a mean time of 3 days. These are the preliminary results of an ongoing study. Lower radiation exposure with the left distal radial artery although insignificant could imply that the newly described access site; The left distal artery causes no higher radiation in comparison with the other access sites.

CONCLUSIONS: Although a small population we found that the newly prescribed access site; The left distal radial artery is associated with no higher fluoroscopy time, radiation exposure and no other complications in comparison with the right radial artery and the right femoral artery. This statistical evaluation encouraged us to increase the study population in order to find a concrete result.

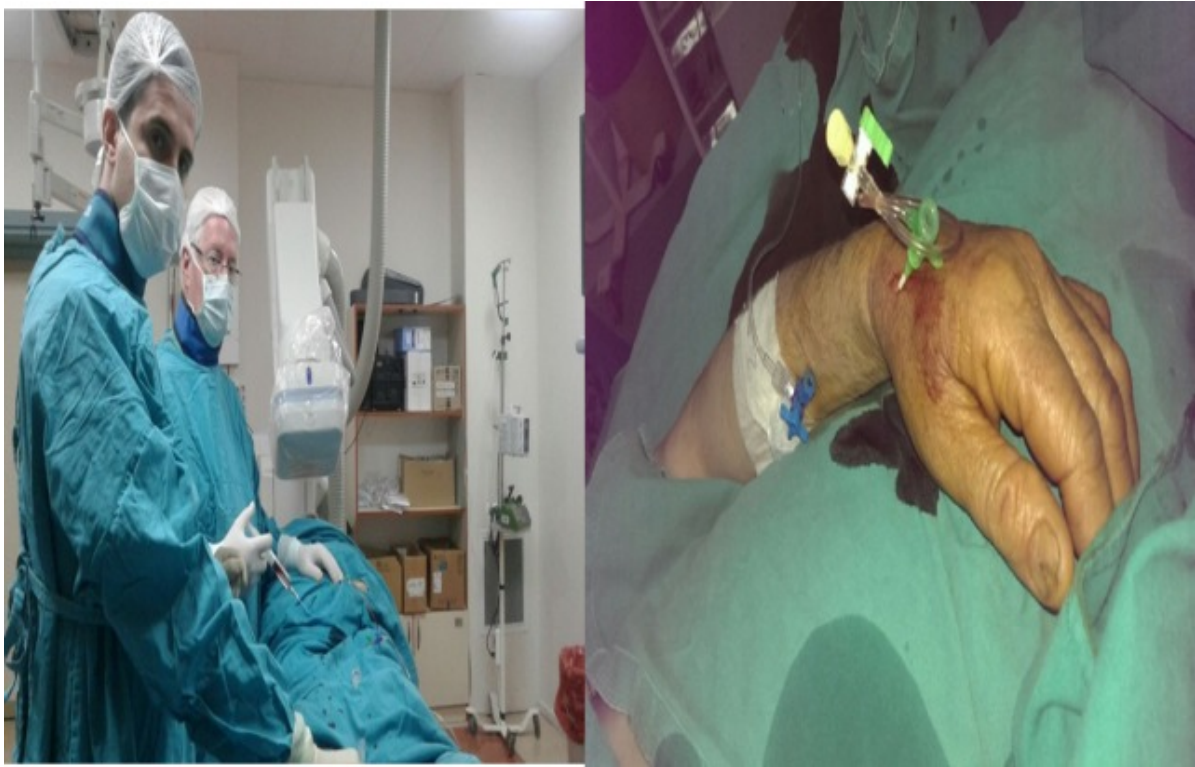

Figure1: Left distal radial artery access site; operator at the right side of the patient.

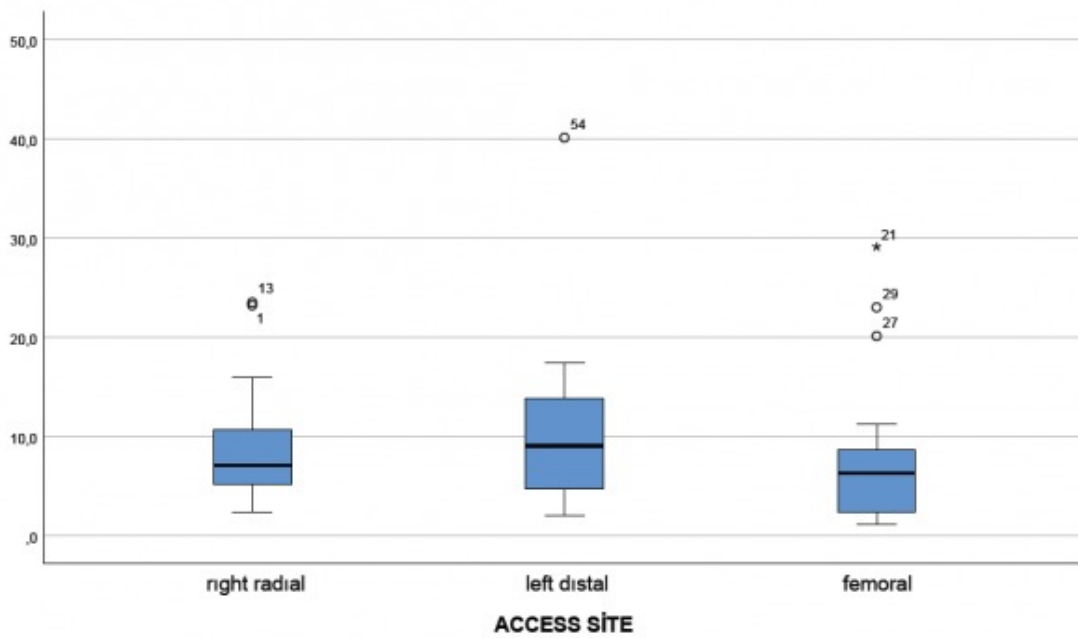


Figure2: Fluoroscopy time.

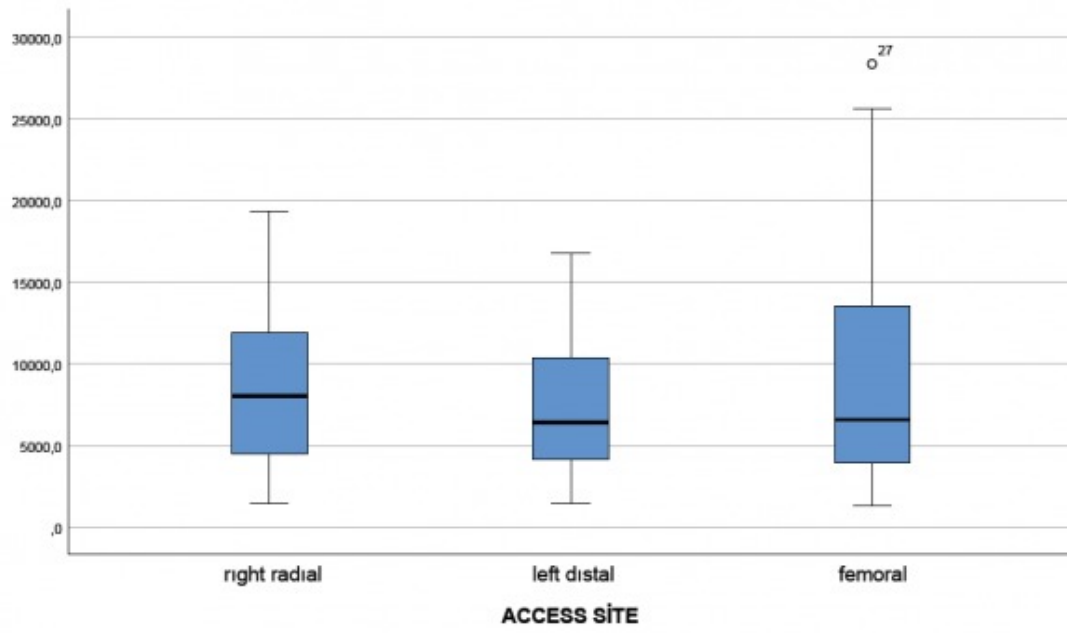
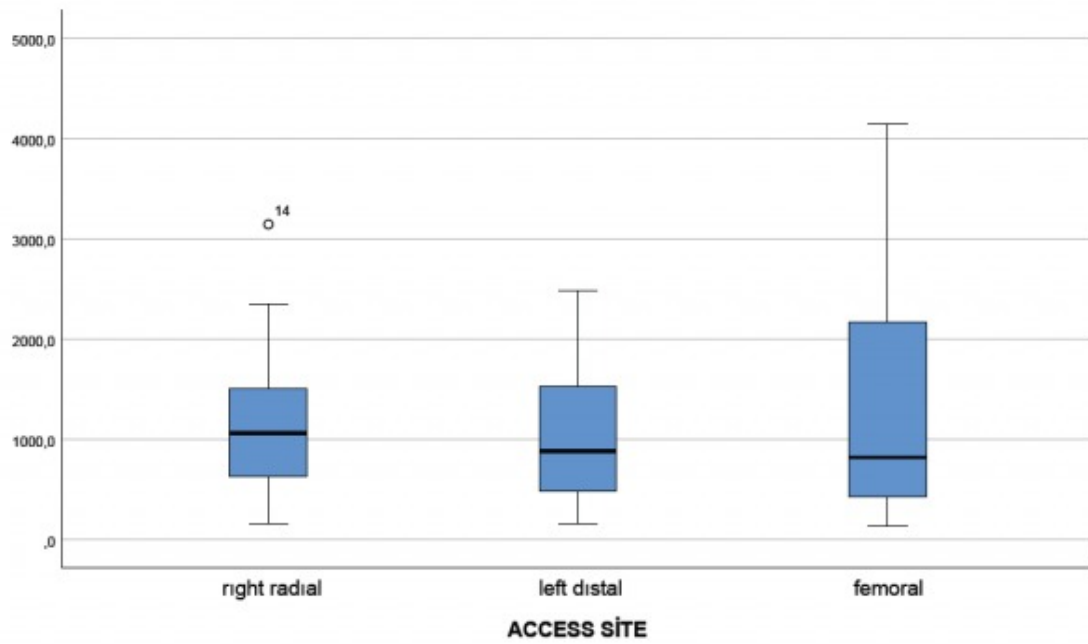


Figure3: Radiation exposure (total air kerma)



Total dose area p

ID: 211

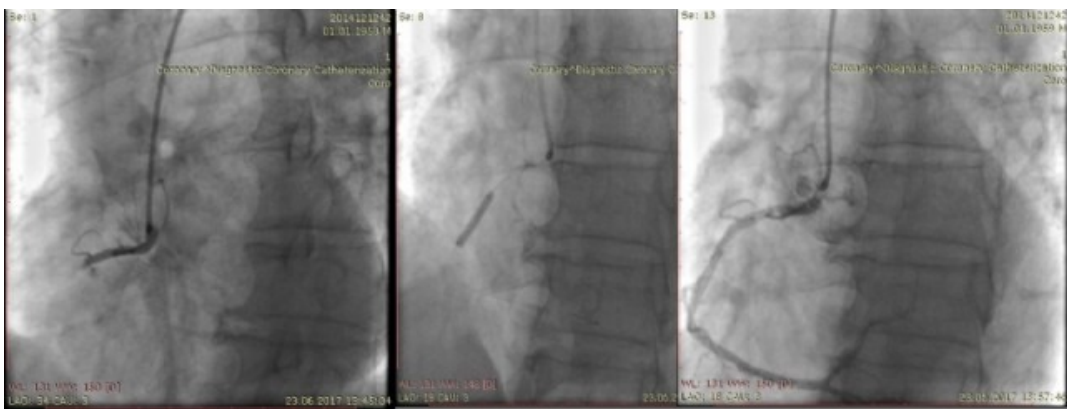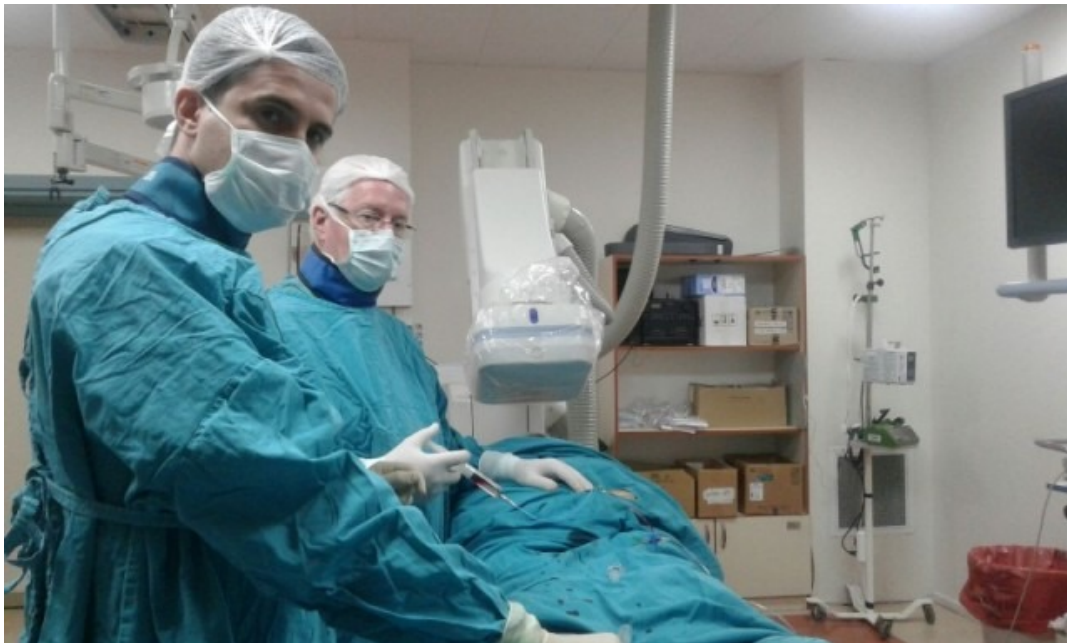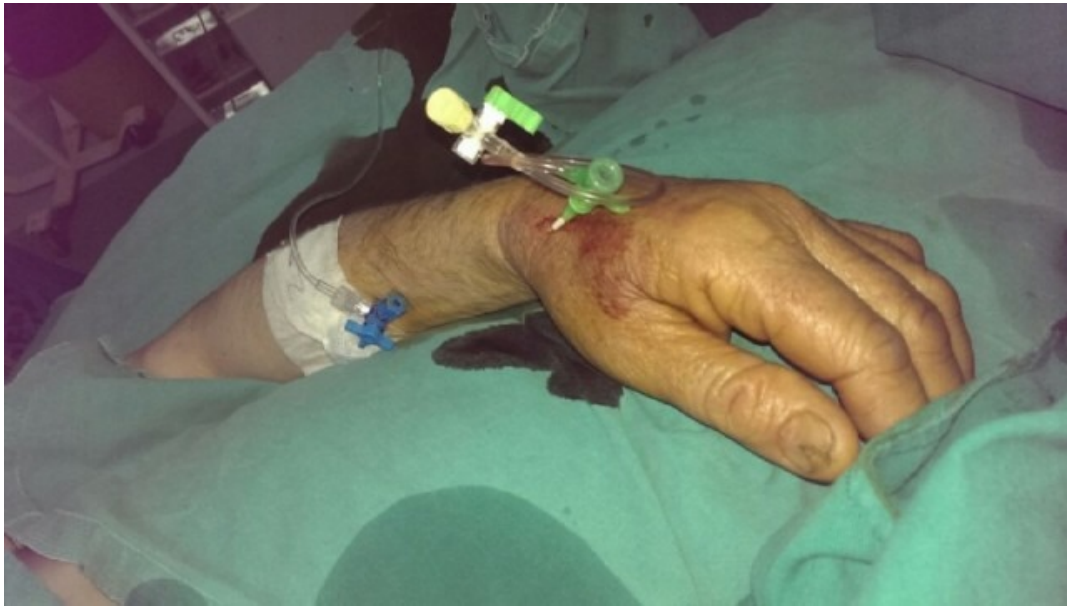Topic: **Cardiology » Percutaneous Coronary Interventions**Presentation Type: **Oral****LEFT DISTAL RADIAL ARTERY ACCESS FOR PERCUTANEOUS
CORONARY INTERVENTIONS****Elton Soydan***Ege University, Izmir, Turkey***Corresponding Author (eltonsoydan@hotmail.com)**eltonsoydan@hotmail.com***Abstract Text**

BACKGROUND AND AIM: Left distal radial artery access site has emerged as a new technique for coronary angiography procedures. By introducing the radial sheath into the left fossa radialis or the so called 'Anatomic snuffbox' we aimed to assess the feasibility of this new access site for coronary interventions.

METHODS: The left distal radial artery was used as radial access site for 46 patients admitted for coronary interventions to our clinic from June 2017 to April 2018. All the patients had a prominent pulse in their left forearm and distal radial artery. Each patient's left arm was gently bent into his right groin with slight adduction and comfortable position of the hand. The operator stood at the right side of the patient where he could make the arterial puncture and continue with coronary interventions. All the patients had a cocktail of weight adjusted heparin, nitrate and serum physiologic to prevent radial artery occlusion. Demographic features and complications were recorded during the hospital stay.

RESULTS: Mean age was 61.4 and 87% of them was male. Puncture time to left distal radial artery was less than one minute. We used Judkins catheters for all the procedures with 6 French dimension. The most predisposing cardiac risk factors were hypertension and smoking with 80.4% and 26.1% respectively. Half of patients had chronic coronary artery disease with previous interventions. Acute coronary syndrome was diagnosed in 15 patients (36.6%) of which 11 of them had primary angioplasty intervention. Elective interventions were performed in 31 patients (67.4%). All the interventions were successfully contemplated without any serious complication. Left anterior descending coronary artery was the most common artery requiring intervention. Two patients with left main coronary artery disease were successfully stented without any complication. Multivessel intervention at the same time was performed in 7 patients (15.3%). Spasm was seen in only one patient that was resolved with intra-arterial nitrate. There was no radial occlusion, or hematoma or bleeding events. The radial sheath was removed at the termination of the procedure with hemostasis provided by manual compression. Patients were discharged in a mean time of 2.2 days.

CONCLUSIONS: Left distal radial artery seems to be a feasible access site for coronary interventions. A learning curve is required for the operator to perform a successful intervention.



Age	61.4±12.2 (40-87)
Length (cm)	170.9±6.5 (153-185)
Weight (kg)	80±10.7 (53-110)
LVEF (%)	0.51±0.7 (0.22-0.60)
Hospital stay (days)	2.2 ± 1.9 (0-10)
Male	40 (87%)
Female	6 (23%)
DM	17 (37%)
HT	37 (80.4%)
AF	2 (4,3%)
Smoking	12 (26.1%)
Chronic CAD	25 (54.3%)
CABG	3 (6.5%)
Peripheral artery disease	1 (2.2%)
Mechanic prosthetic heart valve	1 (2.2%)
Acute coronary syndrome	15 (36.6%)
Anterior STEMI	5 (10.9%)
Inferior STEMI	6 (13%)
Non-STEMI	4 (8.7%)
Elective PCI	31 (67.4%)
Left anterior descending artery intervention	19 (47.9%)
Left circumflex artery intervention	9 (19.7%)
Right coronary artery intervention	16 (30.4%)
Left main coronary artery intervention	2 (4.4%)
Multivessel intervention	7 (15.3)
DES	39 (84.9%)
BMS	7 (15.3%)
Baloon+ Stent	25 (54.3%)
Stent only	19 (41.3%)
Artery puncture time (minutes)	0.85±0.69 (0.5-3.0)
Fluoroscopy time (minutes)	15.5±11.5 (4-63.4)
Radiation exposure (Total air kerma: mGy)	13464±9865 (2347-58325)
Total dose area product: µGy·m2	19287±1493 (309-7610)

ID: 146

Topic: **Cardiology » Percutaneous Coronary Interventions**Presentation Type: **Oral****RADIAL ARTERIAL THROMBOSIS ASSOCIATED AND RISK FACTORS IN PATIENT UNDERGOING RADIAL CORONER ANGIOGRAPHY**

Esra Koç Ay, Adnan Kaya, Ibrahim Feyyaz Naldemir, Cem Özde

*Duzce University, Duzce, Turkey***Corresponding Author (dresraakoc@gmail.com)**dresraakoc@gmail.com, adnankaya@ymail.com, ibrahimnaldemir@duzce.edu.tr, drcemozde@gmail.com***Abstract Text**

Objective: Coronary angiography is the gold standard method for the diagnosis of atherosclerotic coronary artery disease. Radial access is accepted as the gold standard for coronary angiography (CAG) and percutaneous coronary intervention in 2018 ESC / EACTS In myocardial revascularization guidelines. Radial artery thrombosis (RAT) is the most common complication of trans-radial access (TRA). In our study, we aimed to investigate the incidence of RAT and associated risk factors.

Methods: A total of 150 patients who underwent coronary angiography through TRA between January 2018 and November 2018 were included to the study. Color doppler ultrasonography was performed and the proximal and distal radial flow rates were measured 4-6 hours after TRA. Demographic and laboratory data of the patient were recorded. Patients with RAT were accepted as the study group while the others comprise the controls.

Results: Of these 150 patients, 20 (13.3%) of them had RAT (4 (2.7%) of them with partial occlusion, 16 (10.7%) of them with total occlusion). In the univariate analysis, female gender (OR = 2.48, 95% CI: 0.947-6.491, P = 0.064), HT (OR = 0.341, 95% CI: 0.130-0.896, P = 0.029), history of CAD (OR = 3.581, 95% CI: 0.791-16.204, P = 0.098), antiaggregant usage history (OR = 0.378, 95% CI: 0.135-1.056, P = 0.064), compression time (OR = 1.446, 95% CI: 0.309-6.769, P = 0.069), indication for coronary angiography for the patient (elective CAG, ACS presentation) (OR = 3.581, 95% CI: 0.791-16.204, P = 0.098), hematocrit value (OR = 0.916, 95% CI: 0.829-1.012, P = 0.084), neutrophil count (OR = 1.134, 95% CI: 0.979-1.314, P = 0.093), creatinine value (OR = 0.061, 95% CI: 0.004-0.840, P = 0.097), and e-GFR (OR = 1.024, 95% CI: 0.996-1.054, P = 0.094), were found to be statistically significant for RAT. In multivariate analysis; HT (OR = 0.224, 95% CI: 0.068-0.738, P = 0.014), antiaggregant usage history (OR = 0.278, 95% CI: 0.105-0.739, P = 0.010), compression time (OR = 2.280, 95% CI : 1.419-3.662, P = 0.001), hematocrit value (OR = 0.881, 95% CI: 0.782-0.992, P = 0.037) and creatinine (OR = 0.030, 95% CI: 0.002-0.453, P = 0.011) were found to be independent predictors for RAT. Conclusion: Radial artery thrombosis (RAT) is frequently seen after radial intervention. Conventional pulse examination in the diagnosis of RAT may mask the diagnosis of RAT. Color Doppler USG is the gold standard method for RAT diagnosis. Besides, and it can facilitate early diagnosis and treatment of RAT. It would be appropriate to keep radial band duration as short as possible since it increases the RAT rates.

ID: 112

Topic: **Cardiology » Percutaneous Coronary Interventions**Presentation Type: **Oral****PREDICTORS OF PROLONGED PAIN EXPERIENCED AFTER
TRANSRADIAL CORONARY ANGIOGRAPHY**Murat Gul¹, **Burak Açar**²¹*Aksaray University, Aksaray, Turkey*²*Kocaeli University, Kocaeli, Turkey***Corresponding Author (dktr_mrt@hotmail.com)**dktr_mrt@hotmail.com, burakacarmd@yahoo.com***Abstract Text**

Objective. There was no thrombosis, spasm or any complication in the radial artery of the patients who underwent radial coronary angiography, however, the patients described forearm and wrist pain, which sometimes lasts a month after the procedure. In this study, we tried to investigate prevalence of post-procedural pain in our local population and associated factors.

Materials and Methods. This is a cross sectional study in which a total of 100 consecutive patients who underwent elective transradial coronary angiography ± percutaneous coronary intervention between January 2015-2016 were evaluated. The patients were asked presence of disturbing pain in the forearm especially wrist region after the procedure. Verbal rating scale (VRS) was used to evaluate pain assessment. The patients were divided as early pain group (two hours after the procedure) and prolonged pain group (one month after the procedure) and analysis was performed.

Results. A total of 55% patients suffered from pain in early phase (after two hours) and 26% of patients had prolonged pain after one month of radial intervention. The independent predictors of pain in early pain group were male operator ($p=0.004$, OR=3.386, 95%CI: 1.484-7.725), and experience of operator (OR=4.147, 95%CI: 1.637- 10.506, $p=0.003$). On the other hand, younger age of patients (OR=0.955, 95%CI: 0.915- 0.966, $p=0.032$), and experience of operator (OR=3.947, 95%CI: 1.547- 10.047, $p=0.004$) were the independent predictors of prolonged radial pain.

Conclusion. Pain after radial coronary angiography is not uncommon. Experience, operator gender and age of the patients were independent predictors of pain after transradial coronary angiography.

Table. Univariate and multivariate logistic regression analysis to predict pain after transradial coronary angiography

	Univariate			Multivariate		
<i>Independent predictor of pain after two hours</i>						
	OR	CI 95 %	p-value	OR	CI 95 %	p-value
Male operator	3.386	1.484-7.725	0.004	2.794	1.141-6.846	0.025
Inexperienced operator	4.147	1.637-10.506	0.003	5.992	2.028-17.699	0.001
<i>Independent predictor of pain at one month</i>						
Age	0.955	0.915-0.996	0.032	0.950	0.908-0.995	0.029
Inexperienced operator	3.947	1.547-10.047	0.004	5.533	1.884-16.245	0.002

|

ID: 247

Topic: **Cardiology » Percutaneous Coronary Interventions**Presentation Type: **Oral****A RARE COMPLICATION OF TRANSRADIAL CORONARY ANGIOGRAPHY: KNOTTED CATHETER****Emrullah Kızıltunç***Numune Eğitim Ve Araştırma Hastanesi, Ankara, Turkey***Corresponding Author (e.kiziltunc@gmail.com)**e.kiziltunc@gmail.com***Abstract Text**

A Rare Complication of Transradial Coronary Angiography: Knotted Catheter

Transradial route is increasingly used for diagnostic and interventional cardiac procedures. Radial access is recommended over femoral access due to its advantages about vascular complications. But, increasing transradial interventions caused to experience some unique complications about transradial access. Here, we present how we combatted severely kinked and entrapped diagnostic coronary angiography catheter during coronary angiography.

Case Presentation: A 82 year old woman with Type 2 DM, hypertension, atrial fibrillation and previous ischemic stroke was hospitalized with NSTEMI diagnosis. We performed left coronary angiography with 5F Alvimedica JL3,5 diagnostic catheter via right radial artery access. It was hard to cannulate right coronary artery with 5F Alvimedica JR4 diagnostic catheter and after some clock wise rotations we realized that we could not give contrast agent through the catheter. The catheter was knotted and it was impossible to insert any guidewire through the catheter. Reverse rotation did not untie the catheter and we pulled the catheter back to see if it can be flattened but this caused to entrapment of the catheter. At this point, we could not move the catheter forward anymore and the patient had pain in her arm. We decided to catch the catheter with a snare and inserted a 6F sheath to the right femoral artery. A 6F guiding catheter was inserted to the axillar artery and the knotted catheter were caught with a 10 mm snare . We pulled the knotted catheter back with guiding catheter and after flattening we pulled it back from the right radial artery.

Discussion:

Transradial catheterization gained popularity due to its low vascular complication rates but it has some special risks. Catheter knotting is one of the unique complications of transradial cardiac catheterization. Tortuosity of the axillar – subclavian artery and utility of small sized catheters are risk factors of this annoying complication. But the most important think for the prevention of such a complication is the experience of the operator. Catheter manipulation while 0,038 inch guide-wire is inside the catheter can prevent this complication. Sheathless anterograde guiding catheters, long transradial sheaths can also be used to combat this complication. As in our case, snares can be used to handle catheter knottings.

Oral Presentation

PCI in Acute Coronary Syndrome:2019 Agenda

Date: 28.03.2019 Time: 10:30 - 11:30 Hall: 5

ID: 368

Topic: Cardiology » Percutaneous Coronary Interventions

Presentation Type: Oral

**THE EFFECT OF DISTANCE BETWEEN NON-PCI HOSPITALS AND
PRIMARY PCI CENTERS ON SUCCESSFUL MECHANICAL
REPERFUSION IN ST-ELEVATED MYOCARDIAL INFARCTION**

Mustafa Umut Somuncu¹, Ali Riza Demir²

¹Bulent Ecevit University Faculty of Medicine, Zonguldak, Turkey

²Mehmet Akif Ersoy Thoracic and Cardiovascular Surgery Center, Training and Research Hospital, Istanbul, Turkey, ISTANBUL, Turkey

*Corresponding Author (usomuncu@gmail.com)

usomuncu@gmail.com, alirdemir1986@gmail.com

Abstract Text

-	Univariate analysis OR (CI 95%)	p value	Multivariate analysis¶ OR (CI 95%)	p value
Age, years	1.021 (0.991- 1.052)	0.168		
Male, yes	0.757 (0.301-1.900)	0.553		
Peak troponin, mg/dl	1.145 (1.040-1.260)	0.006	1.106 (0.992-1.123)	0.071
DM, yes	1.568 (0.760-3.231)	0.223		
IRA*	1.177 (0.597-2.324)	0.638		
Grade 0 initial TIMI flow	3.565 (1.579-8.052)	0.002	2.371 (0.985-5.710)	0.048
SBP, mmHg†	0.971 (0.955-0.987)	0.001	0.973 (0.954-0.990)	0.002
DBP, mmHg†	0.964 (0.936-0.993)	0.015		
Process timeψ	1.030 (1.005-1.055)	0.019	1.017 (0.991-1.043)	0.212
Door to balloon timeϣψ	1.023 (1.005-1.041)	0.012		
Surrounding districts, yesϣ	3.051 (1.298-7.171)	0.010	2.741 (1.433-5.244)	0.002

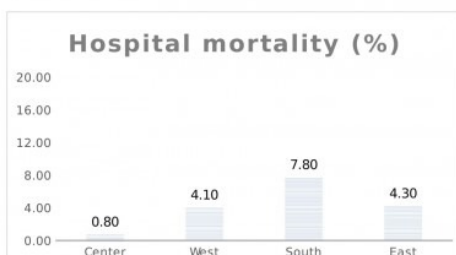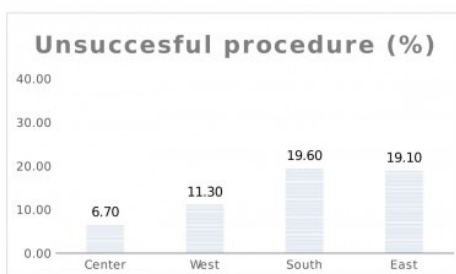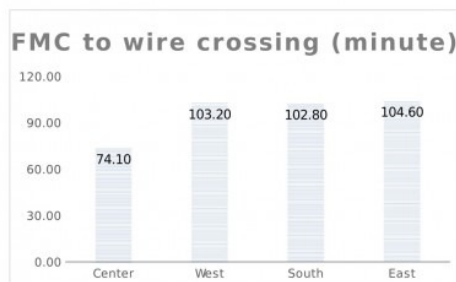
Table 1: Logistic Regression Analysis for Potential Predictors of Unsuccessful Procedure

Background: Early intervention with primary percutaneous coronary intervention (PCI) in patients with ST-elevated myocardial infarction (STEMI) is important to reduce both cardiac mortality and ischemic heart failure. Although the contribution of PCI in the first two hours to the prognosis has been shown, there are contradictory results about whether the treatment in shorter periods provides additional benefit in the literature. In addition, as far as we know, the predictive value of the distance of non-PCI center to PCI centers on procedural and clinical results in STEMI patients has not been described to date. In our study, we aimed to investigate the procedure success and mortality rates of non-PCI hospitals according to the distance from the PCI center.

Methods: In this cross-sectional study, we included 315 patients with STEMI undergoing PCI. The study population was divided into two groups according to the distance of the first medical contact hospitals to the PCI center (town center:120 patients-10km/15 minutes away /surrounding districts (west,east,south):195 patients- 50 km/60 minutes away). Patients with TIMI flow grade 3 was accepted successful process and patients with TIMI 0,1,2 as accepted as no-reflow.

Results: The rate of patients who could not provide TIMI 3 flow was 12.0%. In-hospital mortality was observed in 11 patients (3.4%). There was no significant difference in baseline and procedural characteristics between non-PCI hospitals in city center and surrounding districts. Nevertheless, door-to-balloon time was longer in patients from surrounding districts hospital as expected (103.4±13.8 min. vs. 74.5±16.3 min, p<0.001). Moreover, no reflow (15.9% vs. 5.8%, p=0.008) and in-hospital mortality rates (5.1% vs. 0.8%, p=0.044) were higher in patients from surrounding districts hospitals compared to city center hospitals. In log regression analysis, it was found that low systolic pressure and grade 0 initial TIMI flow rate were independent predictors of no-reflow. Moreover, patients from surrounding district hospitals had 2.7 times increased odds for no-reflow than those with patients from city center hospitals.

Conclusion: Early mechanical reperfusion decreases in-hospital mortality by increasing the success of the procedure in patients with STEMI. The prolongation of door-to-balloon time because of the distance between non-PCI hospitals and PCI center may decrease the success of the process. Increasing the system performance may lead to better clinical results by shortening first medical contact to wire crossing times. Besides, more intensive antithrombotic therapy, perhaps fibrinolytic therapy, may be considered in STEMI patients from surrounding district hospitals.



ID: 387

Topic: **Cardiology » Percutaneous Coronary Interventions**Presentation Type: **Oral****DIRECT STENTING VERSUS STENTING AFTER BALLOON PRE-DILATION IN PATIENTS WITH STEMI FOR SMALL VESSEL CORONARY ARTERIES BY USING BARE-METAL STENTS****Kahraman Cosansu, Harun Kilic***Sakarya University, Education and Research Hospital, Sakarya, Turkey***Corresponding Author (kahraman141@gmail.com)**kahraman141@gmail.com, kahraman141@gmail.com***Abstract Text**

Background: Direct stenting without predilatation is a well-defined, feasible method with bare metal stents(BMSs). However, data evaluating its impact in small vessel coronary artery disease (CAD) with STEMI are lacking. This study was designed to compare composite endpoints between direct stenting and balloon predilatation followed by stent placement using only bare-metal stents in patients with ST-elevated myocardial infarction for small vessel coronary artery culprit lesions.

Methods: Two hundred and fifty-three consecutive patients (mean age, 66.2 ±12.0 years; 86 women) who had small vessel coronary artery and undergone primary stenting for STEMI either conventional stenting (n: 169) or direct stenting (n:84) via a BMSs between March 2013 and December 2017 were retrospectively analyzed. The composite endpoints were compared between the two groups of procedures; stenting with predilatation or direct stenting.

Results: DS was done in 33.2 % of the patients and 66.8 % patients received stenting after predilatation. The rates of MACE, TLR, TVR, MI and ST were not significantly different($p>.05$) between groups at two years. There were also no significant differences in in-hospital rates of death and TLR. Moreover, the procedural complications were similar between groups.

Conclusion: This is the first report to compare stenting with predilatation or direct stenting by using Bare-metal stents in patients with STEMI and small vessel CAD and suggested that direct stenting seems to be as feasible and safe as conventional stenting. Direct stenting also seems to decrease procedural time and radiation exposure without any negative effect on clinic endpoints in this patients group.

ID: 354

Topic: **Cardiology » Percutaneous Coronary Interventions in Acute Coronary Syndromes**

Presentation Type: **Oral**

DISTRIBUTION AND EFFECT OF LOCALIZATION IN SMALL CORONARY ARTERY LESIONS IN PATIENTS WITH ST-SEGMENT ELEVATION MYOCARDIAL INFARCTION TREATED WITH PRIMARY PERCUTANEOUS CORONARY INTERVENTION

Kahraman Cosansu, Harun Kılıc

Sakarya University, Education and Research Hospital, Sakarya, Turkey

**Corresponding Author (kahraman141@gmail.com)*

kahraman141@gmail.com, harunkilic@sakarya.edu.tr

Abstract Text

Background

The treatment of coronary small vessel disease (SVD) remains an unresolved issue. Percutaneous coronary intervention (PCI) of SVD is associated with increased risk of restenosis. We evaluated the impact of location of occlusion on the outcomes of STEMI in SVD.

Methods

We reviewed primary angioplasty cases for STEMI retrospectively from 2013 to 2016 and identified 513 patients with SVD treated with stent diameter of ≤ 2.5 mm. Patients were divided into 3 cohorts depending on the location: proksimal (n: 186), mid (n: 244) and distal (n: 83). Primary end-point was the occurrence of MACE rate at 24 month: a composite of target vessel revascularization(TVR), myocardial infarction(MI), stent thrombosis(ST) and target lesion revascularization(TLR). The secondary endpoints was the in-hospital death and in-hospital TLR rates.

Results

Baseline clinical characteristics did not significantly differ between patients experiencing infarction in the proksimal (36,3%), middle (47,6%) and distal (16,1%) part of the vessel. In SVD patients with STEMI, culprit lesions are frequently located in middle part of coronary artery. The rates of MACE, TLR, TVR, MI, ST and in-hospital TLR were not significantly different between groups ($p>.05$). The rate of in-hospital death was significantly lower in distal than in the proksimal and mid localization($p: .016$).

Discussion

Our study shows that primary PCI procedures for all lesion localizations in small vessel coronary arteries have the same efficacy except in-hospital deaths. Plaque rupture resulting in acute myocardial infarction is more likely to occur in the mid parts of the small coronary vessel.

ID: 82

Topic: **Cardiology » Acute Coronary Syndromes**Presentation Type: **Oral**

THE ASSOCIATION OF LEFT VENTRICULAR END-DIASTOLIC PRESSURE AND ACUTE LEFT VENTRICULAR END-DIASTOLIC PRESSURE CHANGE WITH MIYOCARDIAL BLUSH GRADE AND ST SEGMENT RESOLUTION IN STEMI PATIENTS UNDERGOING PRIMARY PERCUTANEOUS INTERVENTION

Cem Doğan

Kartal Koşuyolu Y.İ.E.A.H, istanbul, Turkey

**Corresponding Author (cemcardio@hotmail.com)*

cemcardio@hotmail.com

Abstract Text

Background: Elevated left ventricular end diastolic pressure (LVEDP) is associated with adverse outcomes in patients with ST elevation myocardial infarction (STEMI). In our study, we aim to investigate the acute changes of LVEDP in patients with STEMI and the relationship of LVEDP with early reperfusion parameters such as ST segment resolution (STR) % and myocardial blush grade (MBG).

Methods: A total of 51 consecutive patients with STEMI were enrolled in the study. Only the patients who underwent successful primary percutaneous coronary intervention (pPCI) with TIMI flow grade 3 were included. LVEDP measurements were performed before (pre-pPCI) and after (post-pPCI) the pPCI. MBG was defined after pPCI. STR% was calculated 60 minutes later after pPCI.

Results: Post-pPCI LVEDP median value was 19 mmHg. Patients were divided to two groups based on <19 mmHg and > 19 mmHg. LVEDP decrease between pre-pPCI and and post-pPCI was 2.9 mmHg (13.3%) (LVEDP change percent) and was statistically significant. (95% CI - 3.45 -2.00 p<0.001). STR% and MBG were significantly different between the two groups (p=0.030 and p=0.01). There was significant positive correlation between LVEDP change and MBG (r: 0.495, p<0.001), STR% (p=0.039, r: 0.290). Post-pPCI LVEDP had a significant negative correlation with MBG (r: -0,438, p= 0.001), STR% (r:-0,501, p <0.001).

Conclusion: In this study, we demonstrated that primary PCI might substantially reduce the LVEDP. Moreover, the amount of decrease in LVEDP and LVEDP levels achieved after pPCI might be associated with myocardial reperfusion assessed by ST resolution on ECG and MBG on angiography.

ID: 175

Topic: Cardiology » Percutaneous Coronary Interventions in Acute Coronary SyndromesPresentation Type: **Oral****THE PROGNOSTIC VALUE OF ADVANCIS SCORE IN PATIENTS WITHOUT ST SEGMENT ELEVATION MYOCARDIAL INFARCTION WHO UNDERWENT PERCUTANEOUS CORONARY INTERVENTION**Tuncay Kırış¹, Fatma Kayaaltı Esin², Eyup Avci³¹*İzmir Atatürk Eğitim Ve araştırma hastanesi, İzmir, Turkey*³*Balıkesir university , Balıkesir, Turkey**drtkiris@hotmail.com, dreyupavci@gmail.com, dreyupavci@gmail.com***Abstract Text**

Introduction: The acute coronary syndrome (ACS), which includes unstable angina pectoris, ST elevation (STEMI), and non ST elevation myocardial infarction, has a wide spectrum of risks for death and adverse cardiovascular outcomes. Early risk stratification of ACS patients can help clinicians to determine prognosis and may therefore be useful in guiding management strategy. Several scoring methods, including Global Registry of Acute Coronary Events (GRACE) , thrombolysis in myocardial infarction (TIMI), and platelet glycoprotein IIb/IIIa in unstable angina: receptor suppression using integrilin therapy (PURSUIT), were developed in order to identify high-risk ACS patients. The ADVANCIS score was developed for predicting the risk of acute kidney injury (AKI) after percutaneous coronary intervention (PCI) in acute coronary syndromes (ACS) patients. This score consisted of 8 parameters, namely age, diabetes mellitus, prior AKI, CKD, and cardiogenic shock, number of intervened vessels, ventilator use, and IABP use. It has been shown that this score had excellent discriminative power for predicting in-hospital mortality in ACS patients underwent PCI. There are no data on the role of predicting long-term mortality of ADVANCIS score in these patients. Therefore, we investigated prognostic value of this score for long term mortality in patients without ST segment elevation myocardial infarction who were undergoing PCI. **Methods:** 426 patients without STEMI treated by PCI were enrolled in this study. Demographics, clinical risk factors, and laboratory parameters were analysed. Also, ADVANCIS score was calculated in all patients. The patients were divided into two groups; survivors or non-survivors.

Results: Non-survivors had higher ADVANCIS score compared with survivors (5 [3-9] vs 2 [1-3], $p < 0.001$). In multivariate analysis, left ventricular ejection fraction (LVEF) (HR: 0.947 [0.929-0.965] , $p < 0.001$), multivessel disease (HR: 1.554 [1.020-2.369], $p = 0.040$), and ADVANCIS score (HR: 1.178 [1.110-1.249], < 0.001) were independent predictors of long-term mortality. The AUC of this score for long-term mortality was 0.764 (95% confidence interval [CI]: 0.714-0.813), $p < 0.001$.

Conclusions: ADVANCIS score may be useful in predicting long-term mortality in non-ST segment elevation myocardial infarction patients treated with PCI.

Table 1. Baseline characteristics of the study population.

Variable	Survivors (n = 370)	Non-survivors (n = 110)	P-value
Age (year)	61 ± 11	70 ± 10	< 0.001
Male n (%)	230 (73)	71 (65)	0.102
Hypertension n (%)	181 (41)	81 (57)	0.002
Diabetes mellitus n (%)	79 (25)	49 (45)	< 0.001
Hyperlipidemia n (%)	76 (21)	24 (22)	0.772
Current smoking n (%)	140 (44)	27 (25)	< 0.001
Prior stroke n (%)	10 (3)	8 (7)	0.065
Ventilatory use n (%)	4 (1)	11(10)	< 0.001
IABP use n (%)	4 (1)	5 (5)	0.039
Multi-vessel PCI n (%)	46 (15)	17 (16)	0.819
History of CIN n (%)	11(4)	19 (17)	< 0.001
LVEF (%)	54 ± 8	47 ± 12	< 0.001
Hemoglobin (g/dl)	14.0 ± 1.7	12.9 ± 2.1	< 0.001
eGFR	85 ± 22	64 ± 25	< 0.001
ADVANCIS score	2 (1-3)	5 (3-9)	< 0.001
Cardiogenic shock n (%)	3 (1)	6 (6)	0.005
Multi-vessel disease n (%)	93 (30)	53 (48)	0.001
Chronic kidney disease n (%)	46 (15)	47 (43)	< 0.001
Medication at discharge			
Beta-blocker n (%)	264 (84)	82 (75)	0.037
ACE-I/ARB n (%)	273 (88)	80 (74)	0.001

Abbreviations: HT: hypertension, DM: diabetes mellitus, IABP: intra-aortic balloon-pump, LVEF: left ventricle ejection fraction, eGFR: estimated glomerular filtration rate, ACE-I: angiotensin-converting enzyme inhibitors, ARB: angiotensin receptor blocker, CIN: contrast induced nephropathy, PCI: percutaneous coronary intervention, ADVANCIS: A for age, D for diabetes mellitus, V for ventilator use, A for prior AKI, N for number of intervened vessels, C for CKD, I for IABP use, and S for cardiogenic shock.

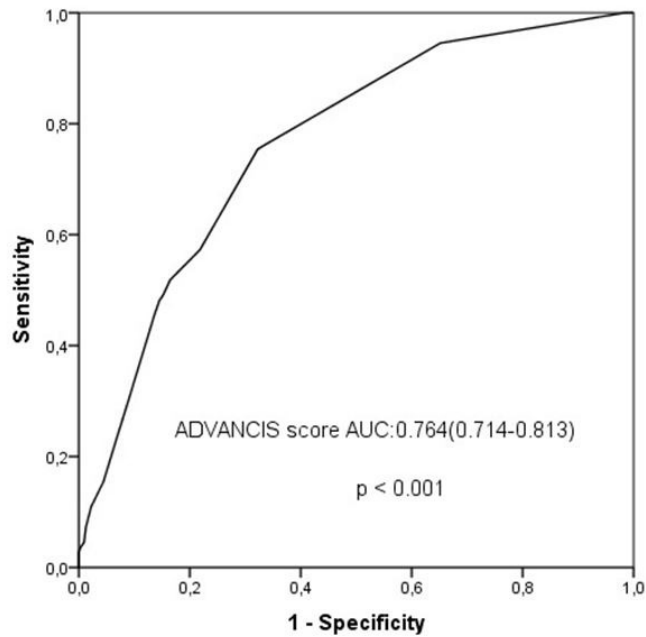
Table. Univariate and multivariate cox proportional hazards analysis for all-cause mortality.

Variable	Univariate		Multivariate	
	HR(95% CI)	P-value	HR(95% CI)	P-value
Age (year)	1.070 (1.051-1.090)	<0.001		
History of HT	1.774 (1.160-2.714)	0.008		
History of stroke	2.020(0.982-4.159)	0.056		
History of DM	2.332(1.596-3.408)	<0.001		
Ventilator use	2.645 (1.952-3.621)	<0.001		
Number of intervened vessel	1.190 (0.708-2.000)	0.511		
IABP use	2.538 (1.032-6.243)	0.043		
Chronic kidney disease	1.245 (1.168-1.327)	<0.001		
Cardiogenic shock	1.971(1.496-2.596)	<0.001		
LVEF (%)	0.939(0.923-0.955)	<0.001	0.947 (0.929-0.965)	<0.001
Hemoglobin(g/dl)	0.760(0.689-0.838)	<0.001		
eGFR	0.971(0.965-0.978)	<0.001		
Beta-blocker usage at discharge	0.620 (0.404-0.952)	0.029		
ACE/ARB usage at discharge	0.446 (0.290-0.686)	<0.001		
History of CIN	1.575 (1.335-1.858)	<0.001		
Multivessel disease	2.313 (1.584-3.379)	<0.001	1.554 (1.020-2.369)	0.040
ADVANCIS score	1.244 (1.188-1.303)	<0.001	1.178 (1.110-1.249)	<0.001

Abbreviations: HT: hypertension, DM: diabetes mellitus, IABP: intra-aortic balloon-pump, LVEF: left ventricle ejection fraction, eGFR: estimated glomerular filtration rate, ACE-I: angiotensin-converting enzyme inhibitors, ARB: angiotensin receptor blocker, CIN: contrast induced nephropathy, ADVANCIS: A for age, D for diabetes mellitus, V for ventilator use, A for prior AKI, N for number of intervened vessels, C for CKD, I for IABP use, and S for cardiogenic shock.

These parameters are not entered in the multivariate analysis in order to prevent multicollinearity.

Abbreviations:HR: hazard ratio; CI: confidence interval; TIA: transient ischemic attack; DM: diabetes mellitus; LVEF: Left ventricular ejection fraction; HT: hypertension; CAD: coronary artery disease; Δ MPV: change in mean platelet volume; ACE: angiotensin-converting enzyme, ARB: angiotensin receptor blockers; IRA: infarct related artery.



ID: 177

Topic: **Cardiology » Percutaneous Coronary Interventions in Acute Coronary Syndromes**

Presentation Type: **Oral**

PERFORATED BALLOON TECHNIQUE: A SIMPLE AND HANDY TECHNIQUE FOR NO-REFLOW TREATMENT

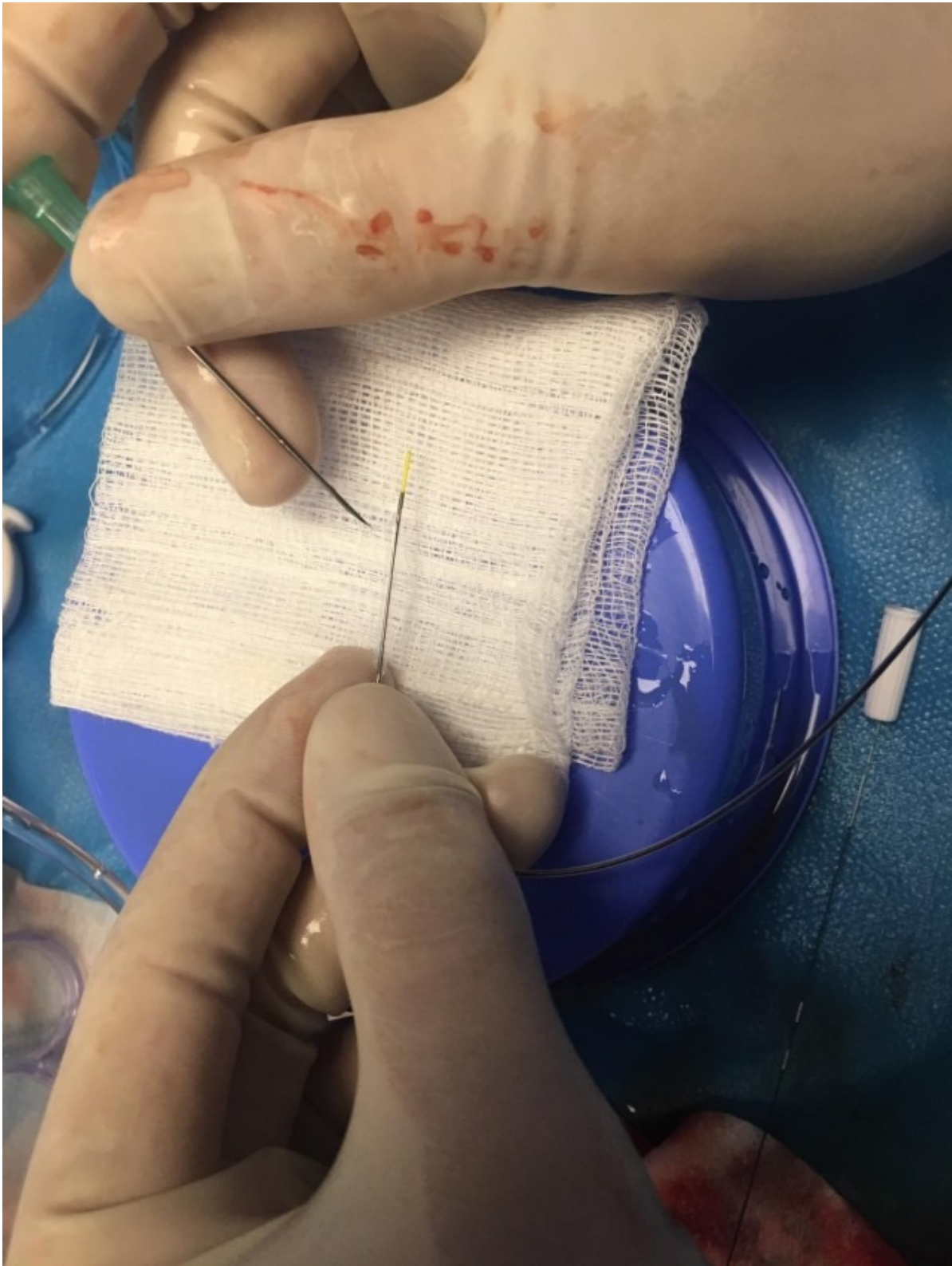Ali Deniz, **Caglar Ozmen***Cukurova University, Adana, Turkey***Corresponding Author (alideniz78@gmail.com)**alideniz78@gmail.com, caglarozm@hotmail.com*

Abstract Text

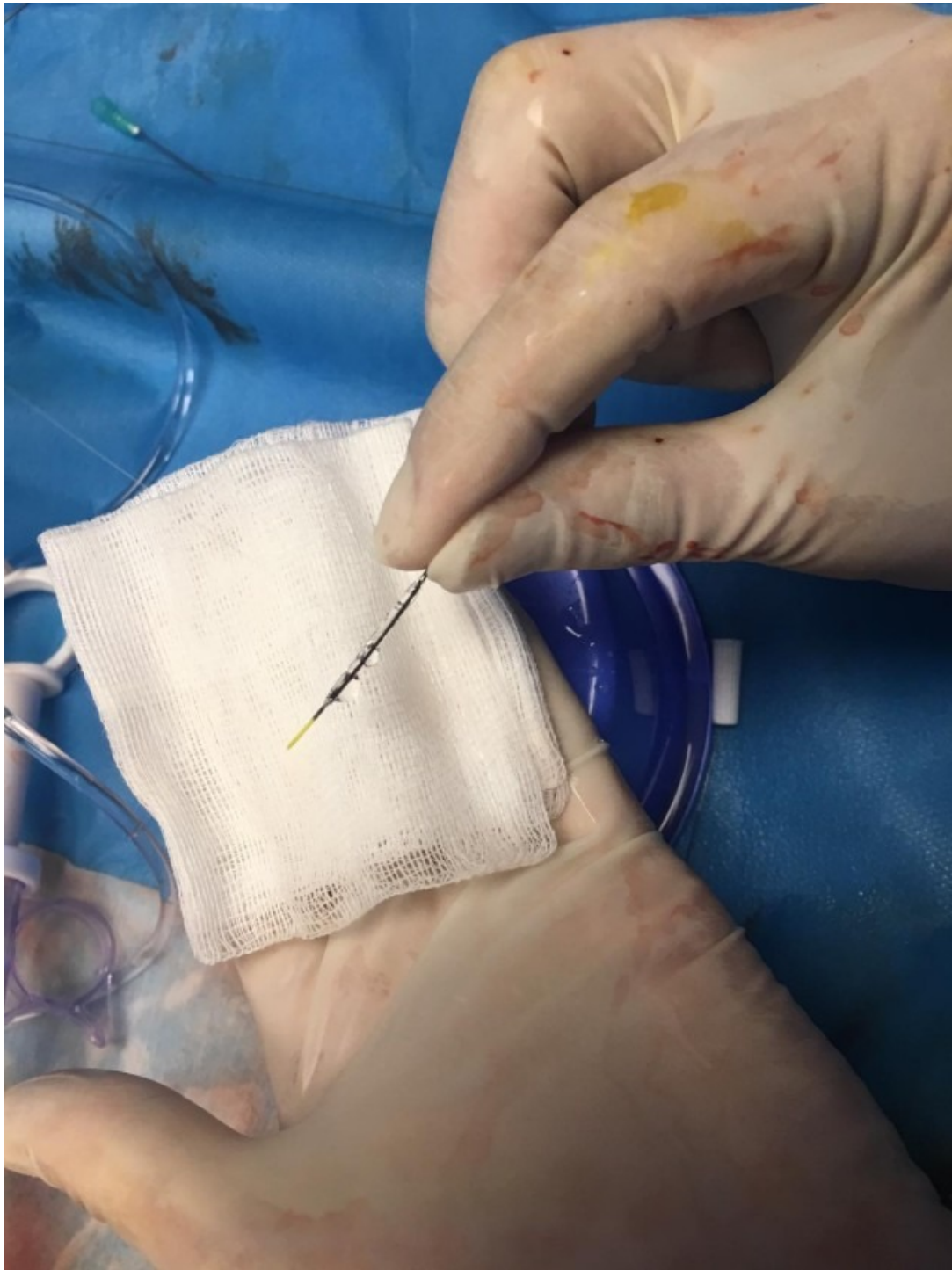
Objective: Occurrence of no-reflow during percutaneous coronary intervention is a serious adverse prognostic event and inability to re-establish better flow is associated with poor outcomes. No-reflow can result in poor healing of the infarct and adverse left ventricular remodeling, increasing the risk for major adverse cardiac events, including congestive heart failure and death. This case describes the use of basic perforated balloon technique to combat no-reflow phenomenon during percutaneous coronary intervention for acute coronary syndrome.

Methods: An 57 year old male patient admitted with acute inferior MI at the third hour of his chest. Right coronary artery was totally occluded at the proximal portion. The lesion was predilated with 2.0x20 mm monorail balloon at 12 atm and 18 atm again but could not

achieve any distal flow. Then the previously used 2.0x20 mm monorail balloon was retrieved and perforated with a injectors needle at four different sites by hand (image 1).



The perforated balloon was flushed from the hub with serum physiological solution and bubbles were removed (image 2).



Then it was inserted to the distal part of the RCA and radio-opaque contrast was injected via the balloon, so we could see distal part of the RCA with TIMI 2 flow (video 1). RCA mid portion was stented with a 3.5x32 mm bare metal stent and the procedure was terminated without any other complication (video 2).

Results: We used basic perforated balloon technique for the patient with acute inferior MI. There were no complications (including air embolism, balloon fragment embolism) related to the use of this technique and TIMI grade III flow was successfully established in these patient.

Conclusions: No-reflow increases mortality and hospital stay in acute MI patients. Antiplatelet agents, thrombus aspiration, distal embolic protection devices, and vasodilator drugs can be used for prevention and treatment of no-reflow. Perforated balloon technique may be some safety concerns about inserting a perforated balloon to the distal part of the coronary and contrast infusion through this balloon, but we did not encounter any complication with this method. Perforating the balloon form multiple sites reduces the risk of coronary dissection due to saline flow because injected saline's pressure is reduced by multiple holes. Perforated balloon technique can be used for no-reflow treatment. This method is available, easy, and safe and has no additional cost.

Oral Presentation

Percutaneous Coronary Interventions: New Techniques for Better Outcomes

Date: 28.03.2019 Time: 11:30 - 12:30 Hall: 5

ID: 39

Topic: **Cardiology » Percutaneous Coronary Interventions**

Presentation Type: **Oral**

EFFECT OF CORONARY ARTERY BIFURCATION ANGLE AND LEFT MAIN CORONARY ARTERY LENGTH ON ATHEROSCLEROTIC LESION LOCALIZATION

Murat Ziyrek¹, Ahmet Lutfu Sertdemir²

¹Sağlık Bilimleri University Education and Research Hospital , Konya, Turkey

**Corresponding Author (muzyrek@yahoo.com)*

muzyrek@yahoo.com, dralsertdemir@gmail.com

Abstract Text

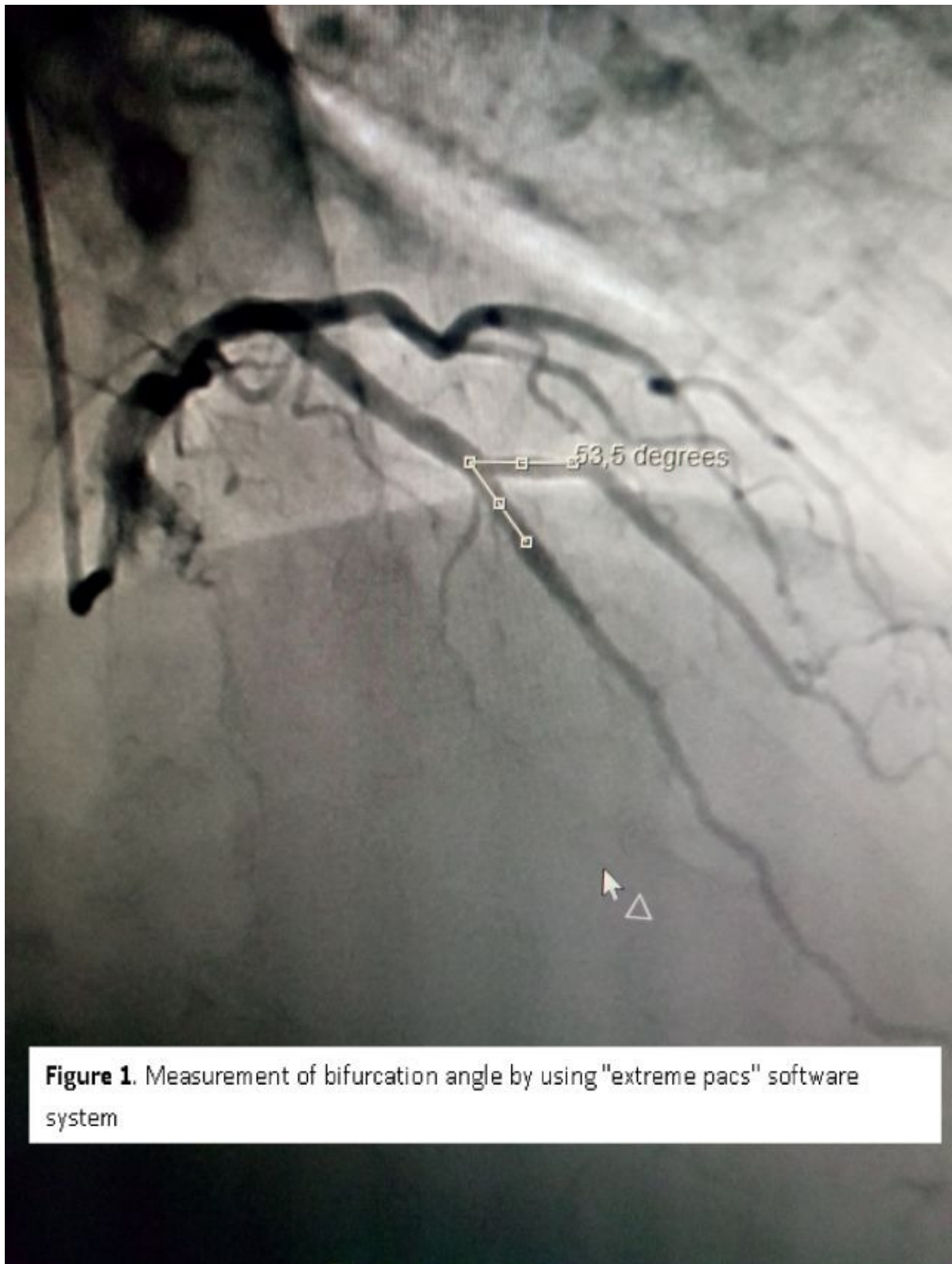
Introduction: Coronary artery disease (CAD) is one of the leading causes of death all around the world. Although percutaneous coronary interventions (PCI) become a common treatment modality of CAD, lesion localization might make the procedures more complex. As the lesion localizes near to the bifurcation site, more complex PCI procedures, overqualified equipments are needed and complication risk increases. Previous studies have showed the direct correlation between wide angulation and significant coronary stenosis. However there is hardly any data about the association between bifurcation angle and lesion localization distance. In this study we analysed the effect of coronary bifurcation angle and left main coronary artery (LMCA) length on the atherosclerotic lesion localization.

Methods: Patients, who underwent coronary angiography between 01.01.2018 - 30.06.2018 were scanned. Patients having atherosclerotic lesions causing more than %50 luminal narrowing and Medina classification score (0,0,0) were evaluated. 5 bifurcation subgroups (LAD-CX, LAD-Dx, CX-OM, RCA-RV, RPD-RPL) were formed. Distance of lesion to the bifurcation site, bifurcation angle and LMCA length were analysed by 2 experienced cardiologists using "extreme pacs" software system (figure 1). Demographic and biochemical data of enrolled patients were obtained. Obtained data statistically analysed.

Results: 78 patients (41 male, 37 female) were included. Demographic and biochemical characteristics of included patients are given in table 1. Of these 78 patients; 27 had lesions distal to the LAD-CX bifurcation, 17 had lesions distal to the CX-OM bifurcation, 20 had lesions distal to the LAD-Dx bifurcation, 7 had lesions distal to the RCA-RV bifurcation, 7 had lesions distal to the RPL-RPD bifurcation. There was a strong negative correlation between bifurcation angle and lesion localization ($r = -0,677$; $p < 0,001$) (figure 2). There was a statistically nonsignificant negative correlation between LMCA length and lesion localization ($r = -0,167$; $p = 0,231$)

Conclusion: In this study, we showed that as the bifurcation angle increases atherosclerotic lesions approach to the bifurcation site. Because interventions encompassing bifurcation sites are more complex, lesions with increased angulation needs more care not to become complex bifurcation procedures.

Variable	Mean value
Age (years)	67,6±8,93
Male gender, n (%)	41 (%52,5)
Hypertension n(%)	50 (%64,1)
Diabetes mellitus n(%)	45 (%57,6)
Fasting blood glucose (mg/dl)	155,3±8,12
LDL (mg/dl)	112,9±31,2
HDL (mg/dl)	40,7±1,0
Triglyceride (mg/dl)	175,5±11,2
Total cholesterol (mg/dl)	186,1±35,6
Urea (mg/dl)	40,8±2,0
Creatinine (mg/dl)	0,99±0,22
AST (mg/dl)	25,1±14,6
ALT (mg/dl)	21,0±9,6
Hemoglobin (g/dl)	13,9±1,53
WBC (10 ⁹ /l)	8,32±1,77
PLT (10 ⁹ /l)	243,43±91,11
MPV (fl)	10,6±0,85
Sodium (mmol/l)	138,3±3,6
Potassium (mmol/l)	4,3±0,5



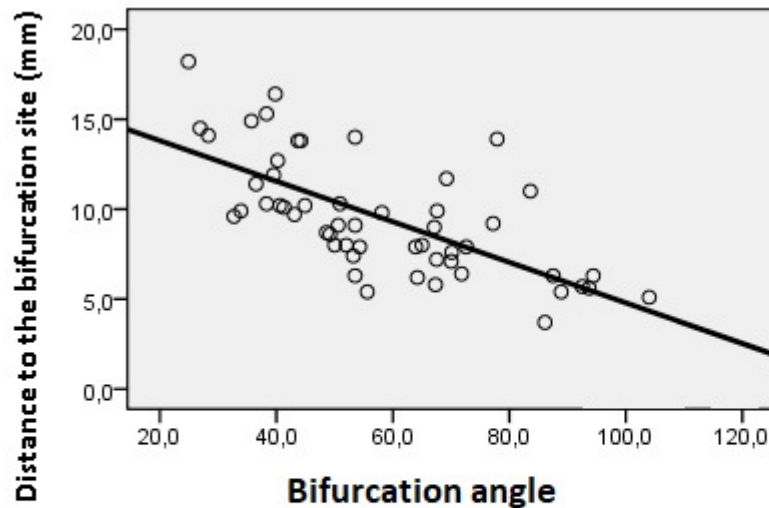


Figure 2. There is statistically significant correlation between bifurcation angle and distance to the bifurcation site

ID: 270

Topic: **Cardiology » Percutaneous Coronary Interventions**

Presentation Type: **Oral**

**NEW TECHNIQUE FOR PREVENTION OF PLAQUE AND THROMBUS
SHIFT IN PATIENTS WITH ACUTE CORONARY SENDROME AND
BIFURCATION LESIONS: KISSING PREDILATATION WITH SEMI-
INFLATED SIDE BRANCH BALLOON**

Hakkı Şimşek¹, Ali Evsen², Lezgin Dursun³

¹Dicle University Heart Hospital, Diyarbakır, Turkey

^{}Corresponding Author (dr.hsimsek@hotmail.com)*

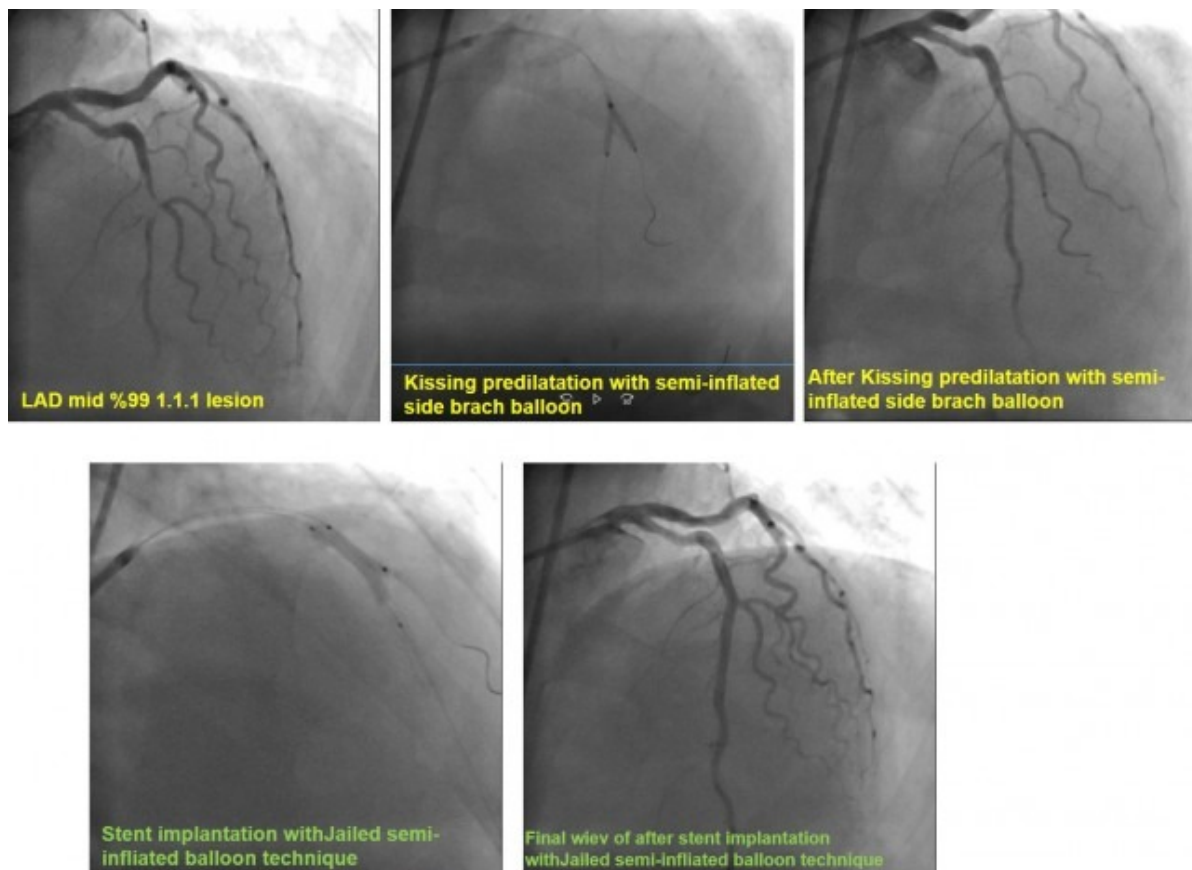
dr.hsimsek@hotmail.com, alievsen@hotmail.com, lezgindursun893@hotmail.com

Abstract Text

Provisional crossover stenting has been commonly accepted as the gold standard in the field of percutaneous coronary intervention (PCI) for bifurcation lesions. However, provisional main-vessel (MV) crossover stenting has a potential risk of side-branch (SB) compromise, which might increase the risk of periprocedural myocardial infarction (MI). In order to prevent SB compromise, the jailed-wire technique (JWT)

was introduced, and various types of pretreatment techniques have been used, such as predilatation with the sequential technique or kissing-balloon technique (KBT) or directional coronary atherectomy and rotational atherectomy. Our case will be located on the successful prevention of the side-branch thrombus and plaque shift with before stenting using kissing balloon predilatation with semi-inflated side branch balloon technique (KBP-SiBT) in acute coronary syndrome.

A 62-year male patient who had no history of previous coronary disease admitted to our emergency department with symptom of chest pain for two days. He was hospitalized in our coronary intensive care unit with subacute anterior myocardial infarction. Electrocardiogram : sinus rhythm 100 beats / minute, V1-4 ST elevation and pathological Q wave . Echocardiography showed EF %43 with septoapical, anteroapical, apicolateral and apical hypokinesia. After premedication and local anesthesia, selective coronary angiography was performed by entering the right femoral artery through puncture. We diagnosed that LMCA normal, CX proximal plate, after CX OM1 plate, RCA proximal plaque, level of D2 LAD %99 occlusion, D2 ostial %95 occlusion with Medina classification of 1,1,1. We used KBP-SiBT before stenting and prevented the side-branch thrombus and plaque shift. After that we implanted stent with jailed semi-inflated balloon technique without loss of side branch ostial lumen Figure.



ID: 18

Topic: **Cardiology » Percutaneous Coronary Interventions**Presentation Type: **Oral****THE SUCCESSFUL RETROGRADE VISUALIZING CHRONIC OSTIAL OCCLUSION OF LEFT MAIN CORONARY ARTERY WITH THE DRILLED BALLOON TECHNIQUE AND IT RECANALIZATION VIA A SAPHENOUS VEIN GRAFT.****Yakup Balaban***Vm Medicalpark Kocaeli, Kocaeli, Turkey***Corresponding Author (yakupbalaban@gmail.com)**yakupbalaban@gmail.com***Abstract Text**

Introduction:

Here we report a case of successful retrograde transradial recanalization and stenting of a chronically ostial occluded left main coronary artery (LMCA) from a saphenous vein graft approach.

Case presentation and Method: A 70-year-old male patient with Coronary artery bypass Graft (CABG) operation 3 years ago underwent coronary angiography with typical angina complaints. It was observed that RCA was totally occluded and LIMA, LAD, Aorta to Obtuse marginal artery graft, Aorta to RCA grafts was open. There was not found any silhouette of the LMCA at the aortic root.

It was seen that the other non-grafted branches of the LMCA was receives blood supply through this thin OM when the Ao OM image is watched. But it was considered that this flow was not enough. 0.014 Guidewire was advanced with retrogradely to the LMCA and then to the aorta through saphenous graft. The LMCA successfully recanalized with a balloon stent applies at the lesion.

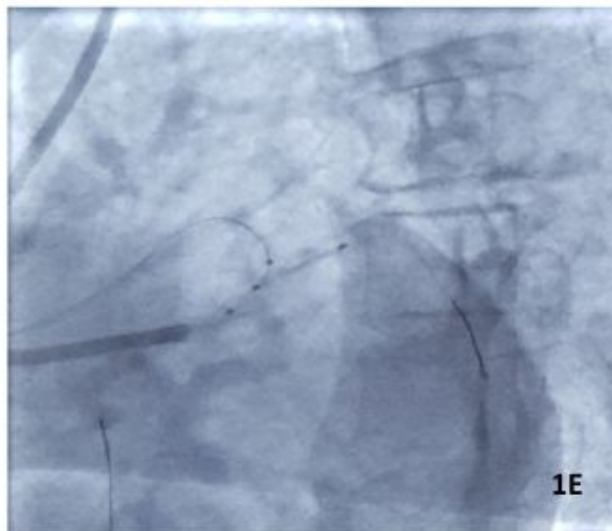
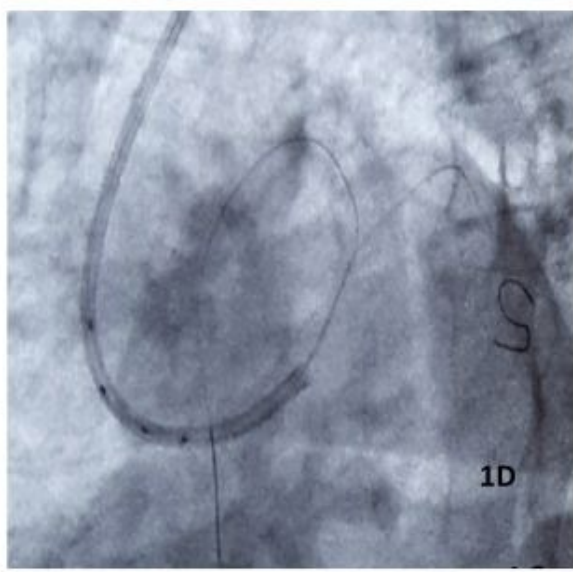
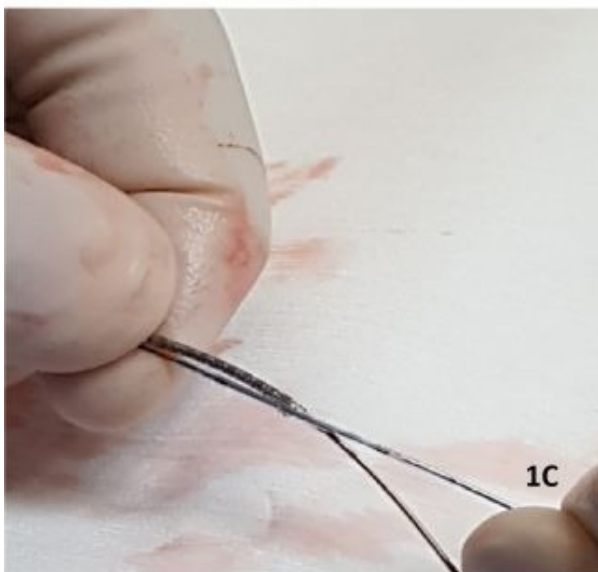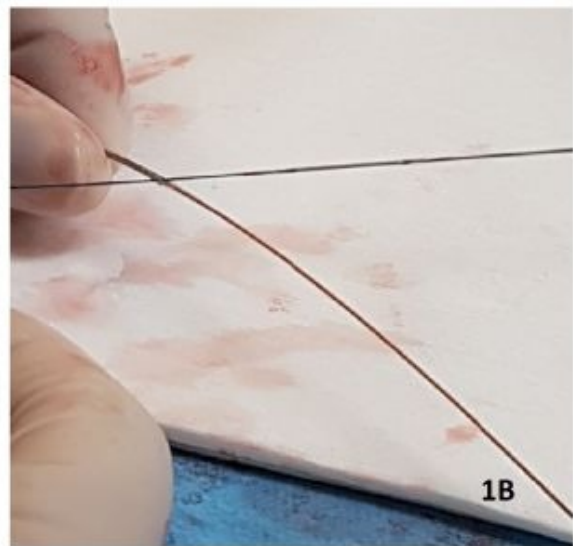
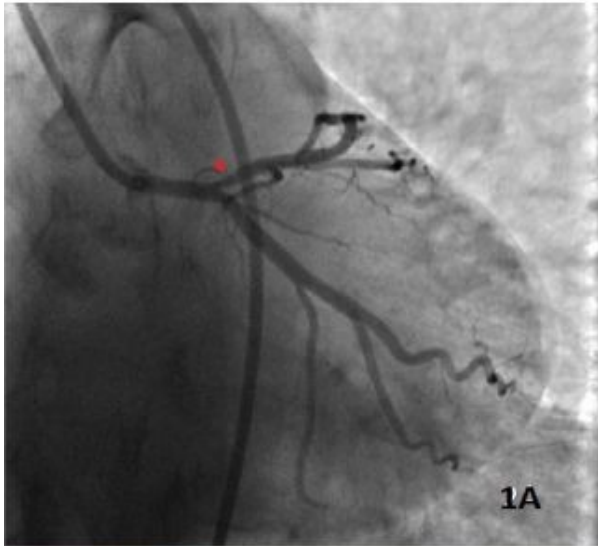
Discussion: The Coronary occlusions can be recanalized retrogradely from the bypass graft or via collaterals that was originated from native coronary. There are clinical studies on retrograde coronary recanalization via native coronary collaterals, whereas in our PubMed-based study, we found only one case report that the LMCA was opened retrogradely via the saphenous graft.

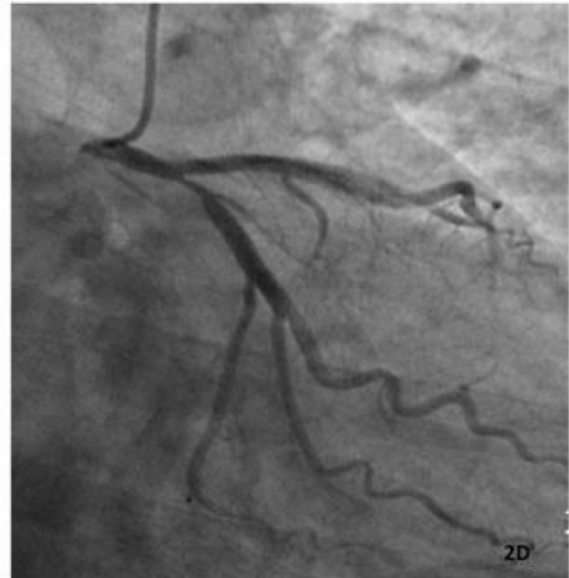
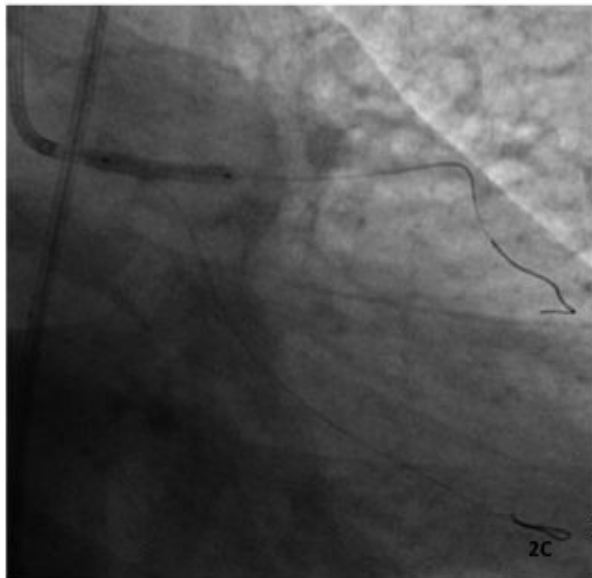
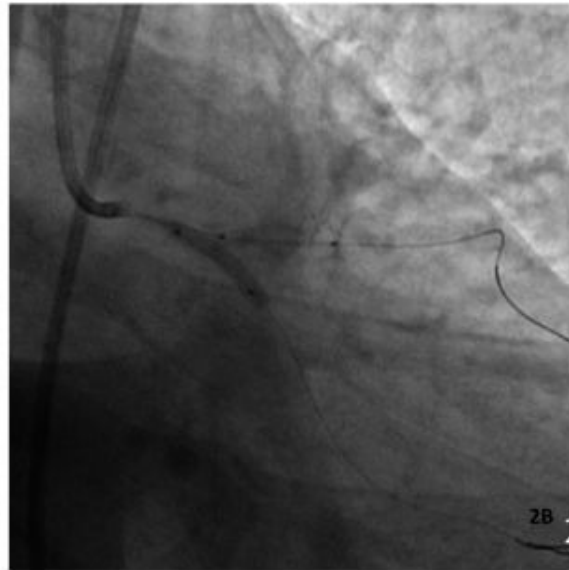
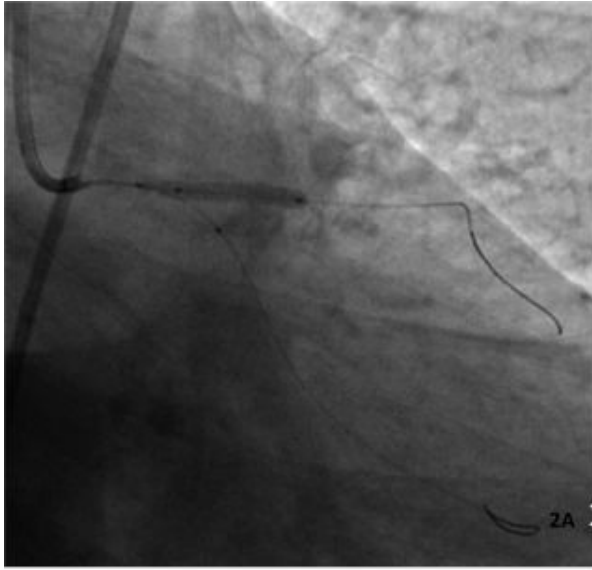
Conclusion: When an osteal occlusion of LMCA is encountered that can not be visualized at the aorta, the LMCA can be recanalized as a retrogradely from the safen graft. This retrograde recanalization method may be a reliable and solution method for LMCA total occlusion cases with saphenous graft.

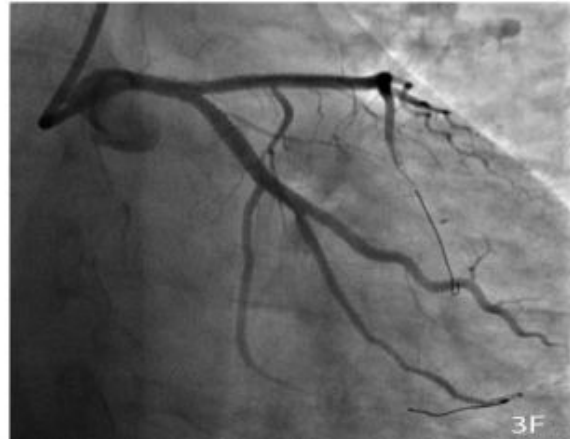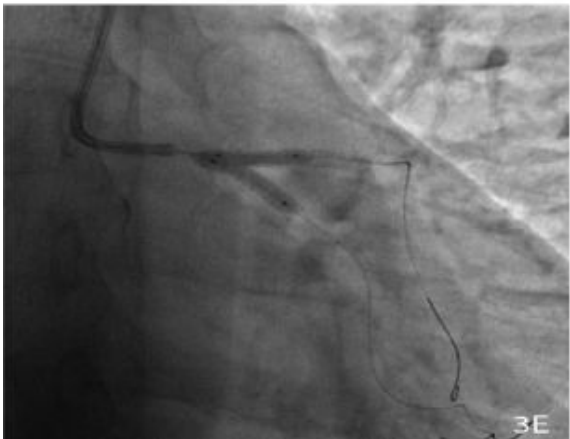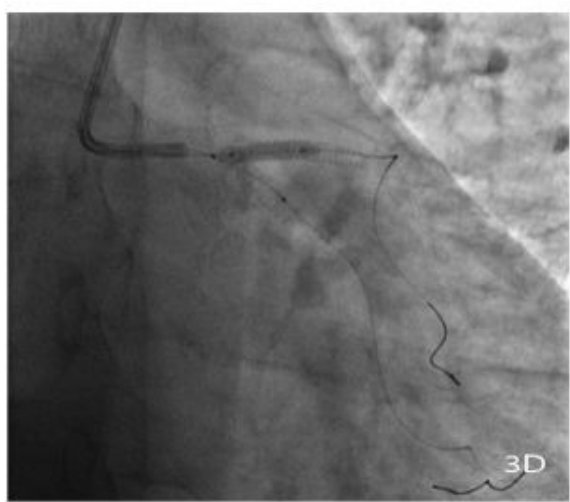
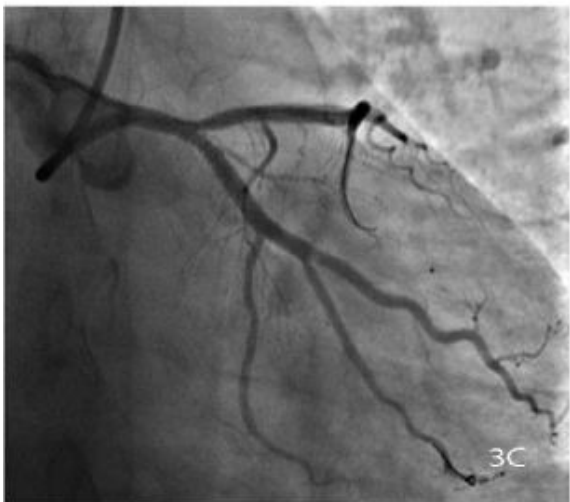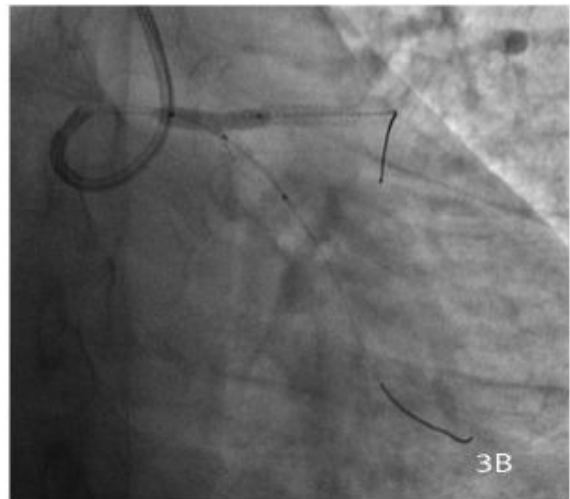
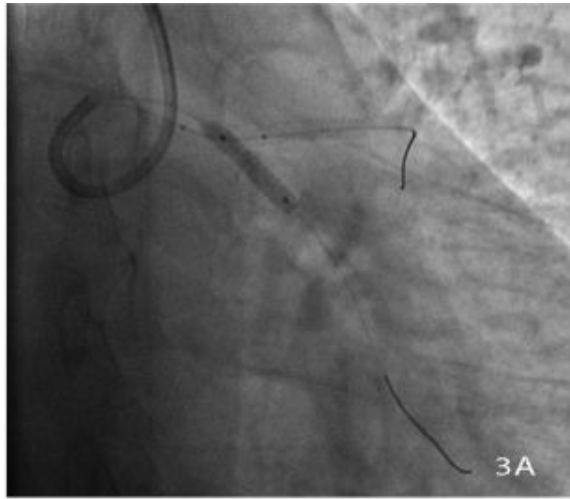
ID: 224

Topic: **Cardiology » Percutaneous Coronary Interventions**Presentation Type: **Oral****A SEQUENTIAL APPROACH FOR THE MANAGEMENT OF OSTIAL CORONARY LESIONS VIA MODIFIED FLOWER PETAL TECHNIQUE****Emrah Ermiş, Hakan Uçar, Samir Allahverdiyev, Erkan Yıldırım***Biruni University, Istanbul, Turkey***Corresponding Author (eermis@biruni.edu.tr)**eermis@biruni.edu.tr, hucar@biruni.edu.tr, dr.samir.av@gmail.com, drerkan23@yahoo.com***Abstract Text**

A 53-year-old male patient presented to the outpatient clinic with the complaint of chest pain related with effort for 2 months. No pathology was observed in the physical examination. ECG and echocardiography were normal. Blood tests revealed dyslipidemia. Exercise stress test was ordered for the smoker patient whose father had a history of CAD. Upon typical chest pain accompanied by significant ischemic change seen on ECG, the test was terminated early and CAG procedure was decided. A stenosis of 70-80% was observed in the LAD ostial on CAG performed via the radial access (Figure 1A). Plaques were detected in the CXA and RCA. When clinical status of the patient and effort test were assessed together, revascularization was decided, but a council decision was made because of the isolated LAD ostial lesion. Minimally invasive single-vessel CABG or PCI was recommended. The patient was informed about possible effectiveness and complications of both procedures. He preferred PCI. The provisional stent technique was planned, but it was cancelled because of the diameter difference between the LMCA and LAD, and modified flower petal technique was chosen to cover LAD ostium. We used a left 3.5 Judkins 7F guiding catheter and started with wiring of both branches (the first wire into the target branch and second wire into the other branch as an anchor wire). A stent-balloon system was prepared outside of the guiding catheter. A second generation everolimus-eluting 3.0*18 mm stent was chosen for the lesion. Then the proximal end of the anchor wire was passed through the final proximal stent strut (Figure 1B). As shown in Figure 1C, another non-compliant 3.0*15 mm balloon was loaded on the anchor wire as an anchor balloon. The stent strut was closed by gently crushing with hand. Stent-balloon system was loaded into the catheter as the stent being on the front (Figures 1 D,E). LAD stent balloon was inflated with 20 atm so as to cover the ostium with holding effect of the balloon directed to CXA, and the stent was implanted (Figure 2A). The stent balloon was then deflated, CXA balloon inflated, deflated, and withdrawn (Figure 2B). Finally, LAD stent balloon was slightly drawn toward LMCA and inflated again to cover LAD ostium well (Figure 2C). However, it was seen on the images taken after the procedure, although distal flow of CXA was not impaired, the proximal part of the CXA was surprisingly affected (Figure 2D). While first kissing balloon procedure alone was planned, stent implantation to CXA with same method was decided, because the effect was not only in CXA ostial. The catheter replaced by EBU catheter. The system was prepared outside of the guiding catheter for CXA this time. The wire and 3.0*15 mm non compliant balloon that will be directed to LAD were passed through the final proximal stent strut. A second generation everolimus-eluting 3.0*18 mm stent was chosen for CXA, and the stent-balloon system was loaded again. CXA stent balloon was inflated with 18 atm and deflated, and then LAD balloon was inflated, and deflated (Figures 3 A, B). Upon this time LAD ostium was affected (Figure 3C). The LAD balloon was inflated for the ostium and then final kissing balloon procedure was performed both to LAD and CXA ostiums together (Figures 3D,E). The last acquired image was good and the operation was terminated. The patient was followed up in the ward after the operation and discharged next day as he was no cardiac symptoms. Despite about 10 months passed from the operation, the patient is still asymptomatic.







ID: 548

Topic: Cardiology » Percutaneous Coronary Interventions in Acute Coronary SyndromesPresentation Type: **Oral****ACUTE TOTAL LMCA OCCLUSION AND SUCCESSFUL TAP STENTING****Atila Iyisoy***Gülhane Training and Research Hospital , Ankara, Turkey***Corresponding Author (aiyisoy@hotmail.com)**aiyisoy@hotmail.com***Abstract Text**

A 40-year-old woman presented to emergency department with acute anterior myocardial infarction (Fig. 1A). Echocardiogram showed ejection fraction was 25% with anterior wall and LV apical hypokinesia. Blood pressure was 60/30 mmHg, pulse 120 /min, O2 saturation 68 without support. The patient was intubated and after initial treatments, coronary angiography was performed via right femoral artery. Cine showed us that left main coronary artery (LMCA) was total occluded proximally (Fig. 1B). Immediately 0,014 floppy guidewires advanced both left anterior descending (LAD) and circumflex (CFX) artery. From LAD to LMCA multiple PTCA was performed with 2,0x20 mm Invader balloon and LAD flow was provided (Fig.1C,1D). Then PTCA was performed CFX proximal with 2,0x20 mm Invader balloon but flow was TIMI 0. Kissing balloon was performed with 2,0x20 mm , 1,5x20 mm balloons from LMCA to CFX and LAD (Fig.1E). After cine showed us that LAD flow was TIMI 2 but CFX flow was TIMI 0 (Fig.1F). We implanted a 3,5x18 mm DES from LMCA to LAD due to the cardiogenic shock and ventricular fibrillation after stent LAD flow was TIMI 3 (Fig.2A,2B). Then we rewired CFX through stent struts with hi torque pilot 150 wire. First, we performed PTCA with 2,5x20 mm balloon and then we implanted a 2,75x22 mm DES with TAP technique at CFX proximal (Fig.2C,2D). After stenting kissing balloon was performed with 3,0x15 and 2,5x12 balloons and the last cine was excellent (Fig.2E,2F). We inserted the intra-aortic balloon pump and the patient was monitored in coronary care unit. 1 day later the patient was extubated and hemodynamics was stable. In her 1 month follow-up; control angiography was very good (Fig.3A,3B).

In presenting ST-segment elevation myocardial infarction due to acute total occlusion LMCA is very rare and has very high mortality rate especially in cardiogenic shock. Rapid revascularization is very important and percutaneous coronary intervention is more rapid and practical than emergency surgery.

Figure 1

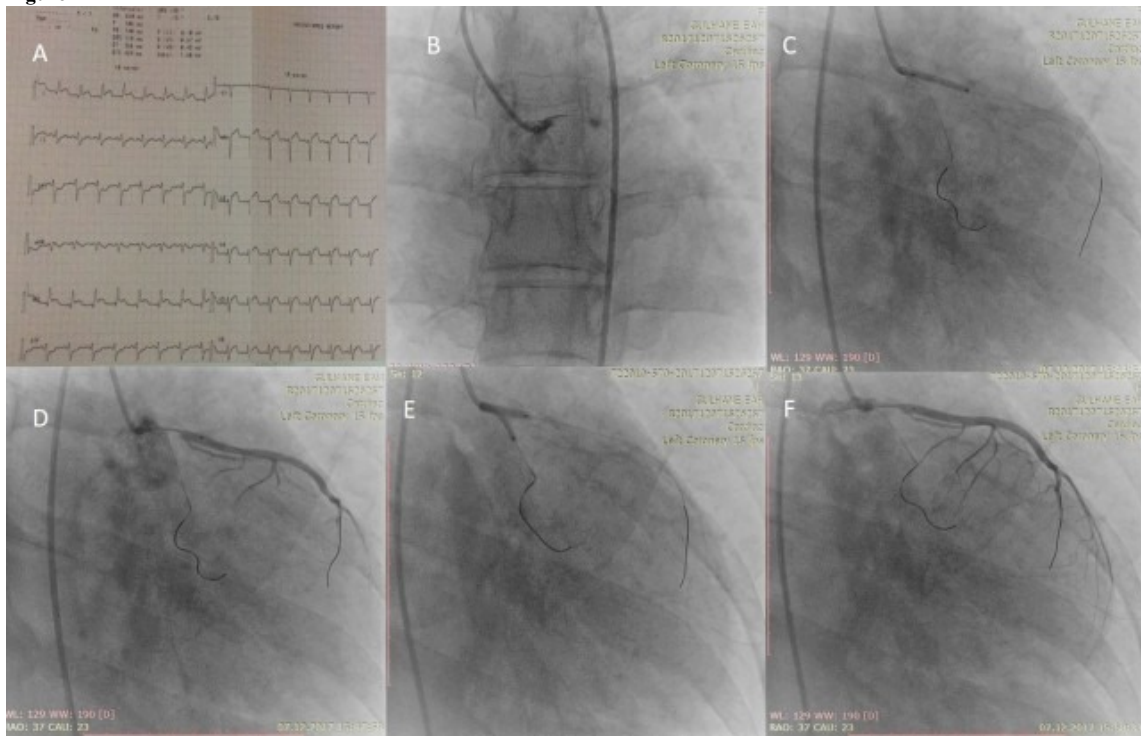
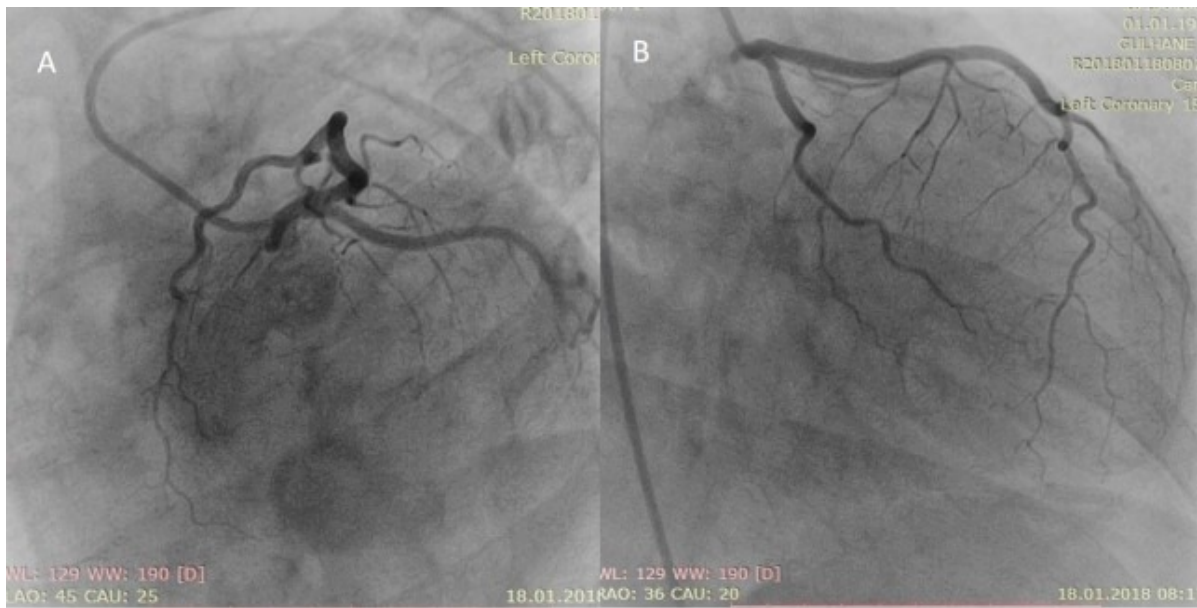


Figure 2

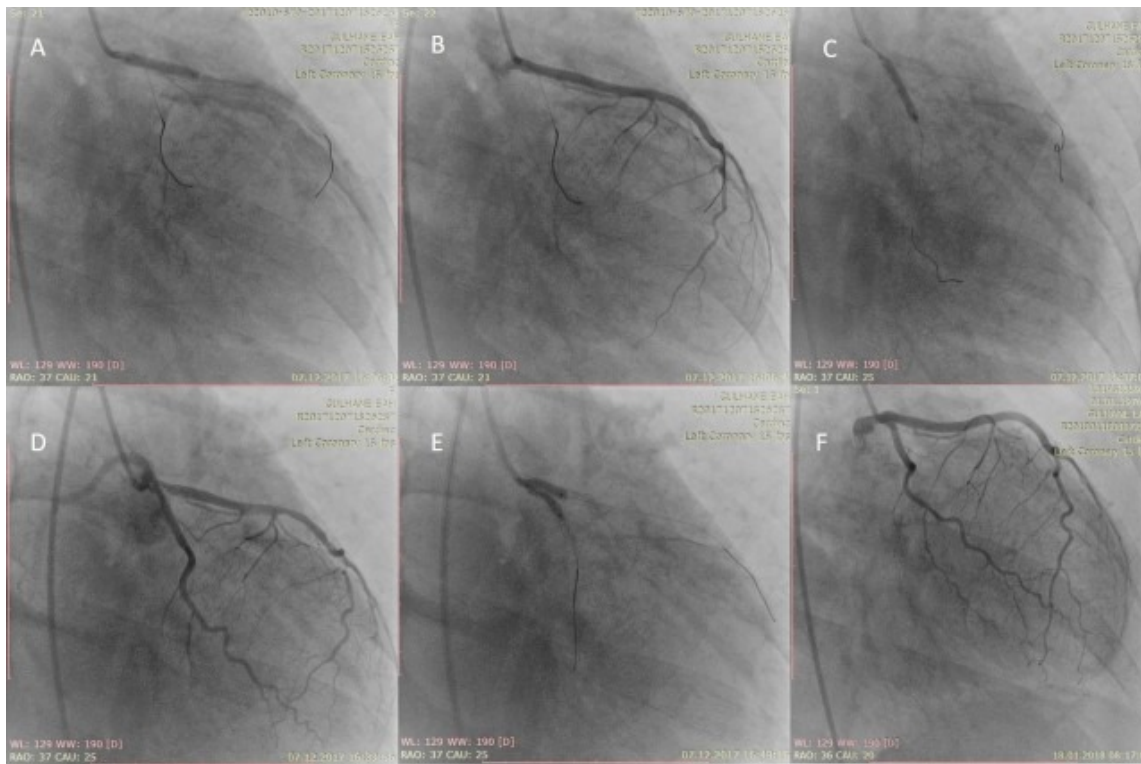

Figure 3



ID: 570

Topic: Cardiology » Percutaneous Coronary Interventions

Presentation Type: Oral

LOCAL DELIVERY OF PACLITAXEL FOR THE PROPHYLAXIS OF RESTENOSIS AFTER EXPERIMENTAL BALLOON DILATATION

Süha Çetin¹, Bernd Hartig²

¹Okan University Hospital, İstanbul, Turkey

²Aalen Hospital, Aalen, Germany

**Corresponding Author (ceramos3@gmail.com)*

ceramos3@gmail.com, bopfi@aol.com

Abstract Text

Introduction: Paclitaxel is an agent with potent antitumor activity that has been approved for clinical use in patients with different types of cancers. It influences the cytoskeleton equilibrium by increasing the assembly of altered microtubules. The aim of this study was to evaluate the safety and efficacy of local delivered paclitaxel after experimental balloon dilatation.

Material and methods: Seventeen domestic pigs underwent balloon dilatation of the proximal left anterior descending artery. In the treatment group (n=8) paclitaxel (10 ml; 10 micromole/L) was delivered using the double-balloon perfusion catheter. The control group (n=9) received only physiological saline under the same circumstances. The animals were sacrificed 4 weeks later. Vessels were perfusion-fixed and histomorphometric analysis was performed using conventional techniques.

Results: The vessel lumen of the treatment group was significantly larger ($2.13 \pm 1.2 \text{ mm}^2$) than that of the control group ($1.38 \pm 0.6 \text{ mm}^2$) ($p < 0.05$). The degree of stenosis in the treatment group was significantly lower ($22.2 \pm 13.2\%$) than that of the control group ($53.7 \pm 21.5\%$) ($p < 0.05$). The intimal area of the treatment group was significantly lower ($0.61 \pm 0.5 \text{ mm}^2$) than that of the control group ($1.78 \pm 1.0 \text{ mm}^2$)

Conclusion: The favorable features of paclitaxel for local application and the advantageous mode of action suggest that this drug seems to be effective and safe for the prophylaxis of restenosis.

Keywords: Paclitaxel, local drug delivery, coronary restenosis

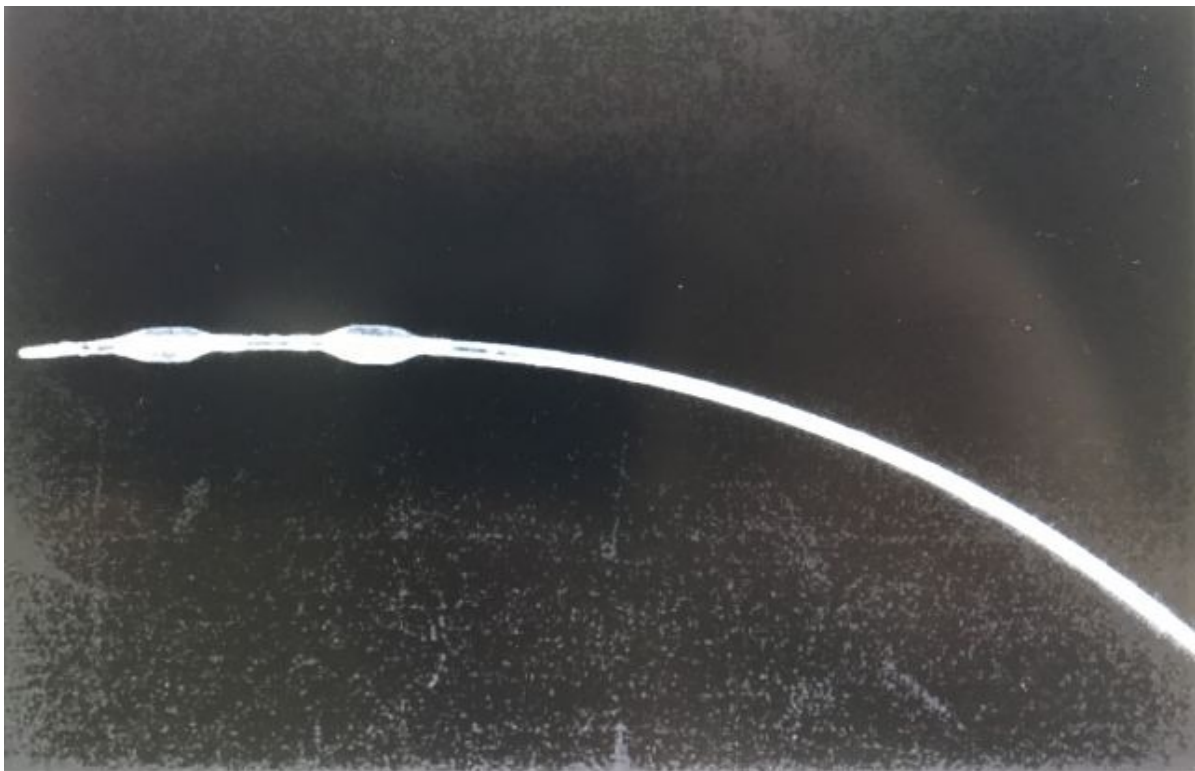


Figure 1: Double-balloon catheter with inflation of the distal and proximal balloons

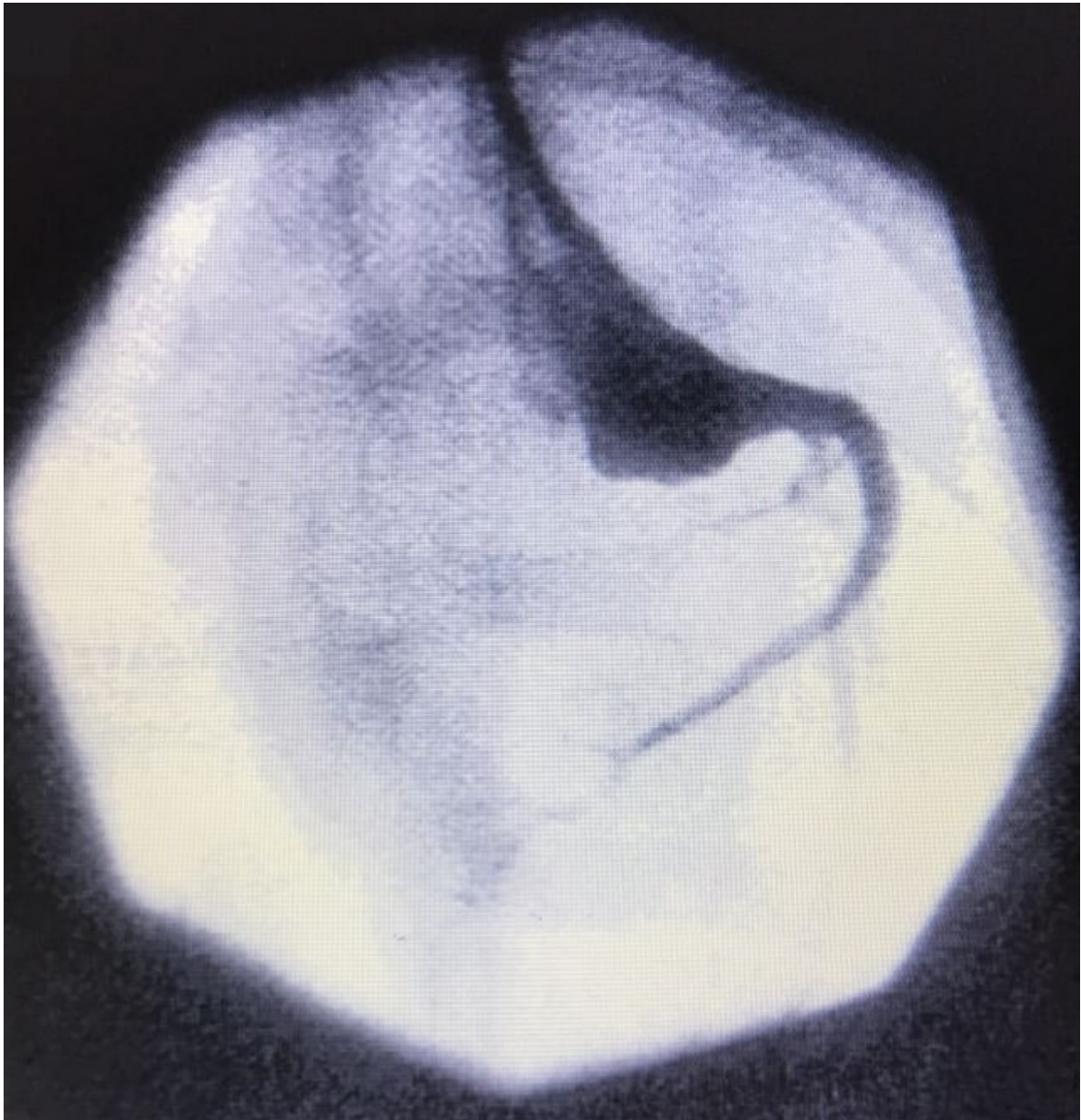

Figure 2: Angiography showing the left atrial descending artery of the pig model

ID: 586

Topic: **Cardiology » Acute Coronary Syndromes**Presentation Type: **Oral****CAN BIOMARKERS POINT OUT THE SEVERITY OF CORONARY ARTERY DISEASE?****Ismail Biyik**¹, Nilgun Isiksacan², Gulcin Sahingoz Erdal², Hulusi Satilmisoglu⁴¹*Usak University, School of Medicine, Education and Research Hospital, Usak, Turkey*²*Bakirkoy Dr. Sadi Konuk Education and Research Hospital, Istanbul, Turkey*⁴*Mehmet Akif Ersoy Thoracic and Cardiovascular Surgery Center, Training and Research Hospital, Istanbul, Turkey***Corresponding Author (ismailbiyikmd@yahoo.com)**ismailbiyikmd@yahoo.com, nisiksacan@gmail.com, gulcinctf@hotmail.com, hulusim@gmail.com***Abstract Text**

Background: Cardiovascular diseases and acute myocardial infarction constitutes of about 30% of all deaths in worldwide. Biomarkers were substantial facilities in the diagnosis, treatment and prognosis of cardiovascular diseases. Biomarkers may predict the severity of cardiovascular diseases at the emergency department. In this study, we aimed to investigate the severity of cardiovascular disease using biomarkers such as cardiac troponins, c-reactive protein and procalcitonin.

Methods: The study patients were randomly selected from patients admitted to the emergency department of our institution with chest pain during the first 3 hours of symptom onset with ST segment elevation on electrocardiography. A total of 166 patients who presented to the emergency department with chest pain and were diagnosed with ST elevation myocardial infarction and underwent coronary angiography, and Syntax scoring was performed all of the study patients. Troponin T, c-reactive protein and procalcitonin analyzes were performed at admission. Troponin T, c-reactive protein and procalcitonin were performed using the e411 autoanalyzer (Roche diagnostics, USA).

Results: Of 166 patients, 157 were male and 19 were women. The age of male patients were between 26 and 87 and it was changed from 45 to 94 for women. The patients were divided into four groups according to Syntax scores. The high sensitive C-reactive protein value of 40 patients with Syntax score < 20 was 6.04 mg / dL. High sensitive C-reactive protein values of 81 patients with a Syntax score of 21 to 30 were 6.09 mg / dL on average. 33 patients with Syntax score from 31 to 40 had average 14.8 mg / dL high sensitive C-reactive protein levels. High sensitive C-reactive protein value of 12 patients with Syntax score > 40 was found to be 21.83 mg / dL. Procalcitonin value was found to be <0.05 ng / mL in all groups. There was no statistically significant difference in procalcitonin measurements between the groups at the time of admission to the hospital. Troponin T values were measured as 375 ng / L in patients with Syntax score <20, 380 ng / L in patients between Syntax score 21 and 30, 460 ng / L in patients between Syntax score 31 and 40 and 710 ng / L in patients with more than Syntax score 40.

Conclusion: In patients with ST elevation myocardial infarction who were admitted to the hospital within the first 3 hours of symptom onset, high sensitive C reactive protein and troponin T measurements performed at the time of admission may be predictive of the severity of coronary artery disease. C reactive protein and cardiac troponin T are not only an acute phase reactant but can also be indicative of the severity of coronary artery disease. The results should be confirmed by large-scale and prospective studies.

Key words: Syntax score, high sensitive C reactive protein, troponin T, acute myocardial infarction, coronary artery disease severity

ID: 590

Topic: **Cardiology » Coronary Artery Disease - CABG Surgery**Presentation Type: **Oral****SYNTAX SCORE AND ANXIETY DISORDERS****Levent Cerit***Near East University, Lefkoşa/KKTC, Turkish Republic of Northern Cyprus***Corresponding Author (drcerit@hotmail.com)**drcerit@hotmail.com***Abstract Text**

Objective: Depression and anxiety disorders are more common in patients with coronary artery disease (CAD) and are strongly associated with lower quality of life, higher medical costs, higher morbidity and mortality rates. Hospital Anxiety and Depression Scale (HADS) is well-validated diagnostic tool for screening of anxiety disorders. SYNTAX score (SS) is the angiographic scoring system and is commonly used to evaluate the severity and complexity of coronary artery disease. This study was conducted with the aim to evaluate the association between serum depression and anxiety and SS.

Methods: Hundred and nine CAD patients not receiving psychotropic treatments who undergo coronary angiography and resulted in coronary artery bypass graft surgery were included in this study. Biochemical, clinical, echocardiographic parameters, and SS were evaluated in all patients. Patients were assessed using the Hospital Anxiety and Depression Scale (HADS). The patients were divided into two groups according to SS (≥ 23 : high(HSSG), < 23 low).

Results: There was no significant difference between two groups with regard to age, gender, hypertension and smoking history. In HSSG the prevalence of diabetes mellitus and hyperlipidemia were significantly higher (59.6% vs 28.3% $p < 0.001$, 64.7% vs 31.6% $p < 0.001$; respectively). There was no significant difference between two groups with regard to laboratory parameteres except thyroid-stimulating hormone and uric acid (3.4 ± 1.3 vs 1.8 ± 0.7 $p < 0.001$, 7.1 ± 3.4 vs 3.0 ± 1.4 $p < 0.001$; respectively). Although HADS anxiety and depression scores were higher in HSSG there was no significant difference between two groups (8.96 ± 5.34 vs 7.83 ± 5.91 . $p = 0.437$, 7.65 ± 4.82 vs 6.63 ± 3.94 $p = 0.549$).

Conclusions: In our study there was no significant difference between two groups with regard to HADS score. Diabetes mellitus and hyperlipidemia were found to be independent predictor of higher SYNTAX score. Further larger studies are needed in this topic.

Keywords: Anxiety, depression, SYNTAX score, diabetes mellitus, hyperlipidemia.

Oral Presentation

Perspectives in Percutaneous Coronary Interventions

Date: 28.03.2019 Time: 13:30 - 14:30 Hall: 5

ID: 396

Topic: **Cardiology » Percutaneous Coronary Interventions**

Presentation Type: **Oral**

RELATIONSHIP MYOCARDIAL BRIDGE SEVERITY AND RED CELL DISTRIBUTION WIDTH; REVIEW OF 139 CASES FROM SINGLE CENTER EXPERIENCE

Ersin Yıldırım

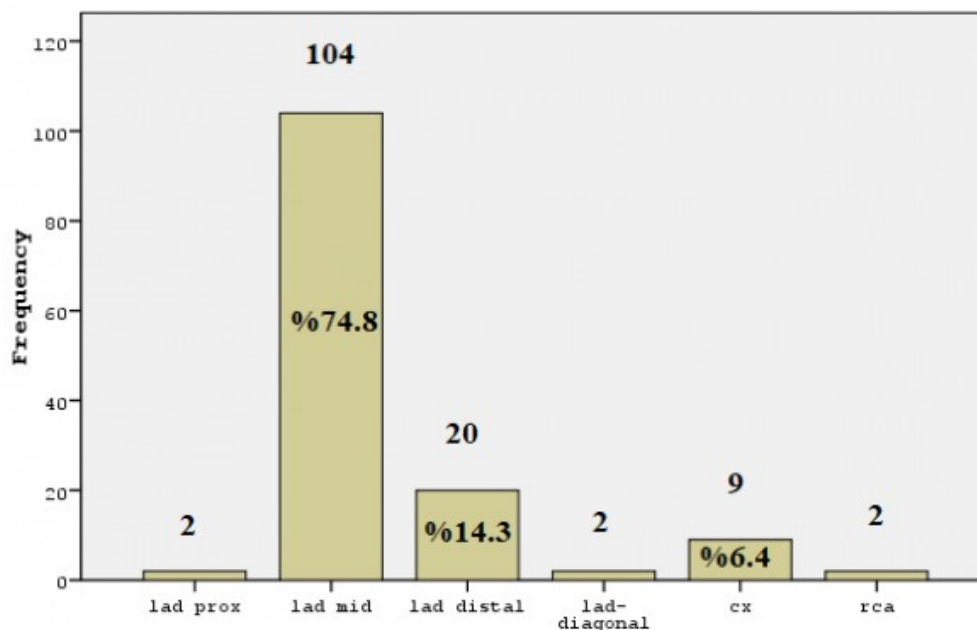
Umraniye Education and Research Hospital, Istanbul, Turkey

**Corresponding Author (ersinyil44@gmail.com)*

ersinyil44@gmail.com

Abstract Text

LOCALIZATION



Variables	≥%50 Stenosis (n=28)	<%50 Stenosis (n=111)	P
Age (years)	51.50±16.23	56.18±11.80	0.086
Sex (female)	4(14.3%)	38(34.2%)	0.040
Diabetes, n (%)	6(21.42%)	20(18.01%)	0.679
Hypertension, n (%)	10(35.71%)	34(30.63%)	0.605
Coexisting severe CAD(≥%50 stenosis)	13(46.42%)	42(37.83%)	0.406
CAD(on proximal of the bridge)	13(46.42)	59(53.2%)	0.525
CAD(on distal of the bridge)	2(7.1%)	20(18%)	0.159
Creatinine (mg/dL)	0.79±0.21	0.75±0.23	0.382
Sodium(mmol/L)	139.12±3.72	140.23±3.44	0.160
Potassium(mmol/L)	4.58±0.48	4.54±0.71	0.725
HDL-cholesterol (mg/dL)	37±11	40±13	0.221
LDL-cholesterol (mg/dL)	133±49	127±27	0.537
Triglycerides (mg/dL)	142±85	140±88	0.913
WBC count (10 ³ /μL)	6.87±1.79	7.13±2.30	0.511
Platelet count (10 ³ /μL)	224.40±54.42	226.57±62.58	0.951
Hemoglobin (g/dL)	13.49±1.32	13.29±1.58	0.811
RDW(%)	14.4±1.1	13.2±0.9	<0.001
MPV (fL)	8.38±0.92	8.45±0.98	0.724
Ejection fraction (%)	59.50±6.43	55.59±11.71	0.020
IVS	12.70±4.54	10.73±2.55	0.035
LVDD	44.10±4.01	49.22±5.60	<0.001

Objective: In this study, angiographic findings of patients with myocardial bridge have been investigated and the relationship between myocardial bridge and red blood cell distribution width was determined.

Method: The cardiac catheterization laboratory database was examined retrospectively. A total of 139 patients who had been underwent coronary angiography and diagnosed with myocardial bridge were included in the study. Angiography images of these patients were reviewed. The patients were divided into two groups according to the their myocardial bridge stenosis severity (≥ 50% stenosis was accepted severe and <%50 stenosis was accepted mild). Demographic characteristics, complete blood counts and biochemical values of each patient were obtained from hospital records.

Results: The distribution of the study population was as following; 28(20.1%) ≥%50 stenosis group and 111(79.9%) <%50 stenosis group. The rate of females was 30.2%. There was no significant difference in the distribution of mean age between the groups. The rate of female gender was significantly higher in the mild stenosis group (34.2% vs 14.3%; p=0,040). No difference was observed between the groups with regard to other demographic characteristics. RDW (14.4±1.1 vs 13.2±0.9; p<0,001) was significantly higher in the ≥ 50% stenosis groups compared to the <%50 stenosis group. No difference was observed between the groups with regard to other laboratory findings. Interventricular septum thickness was observed statistically higher in severe stenosis groups (12.70±4.54 vs 10.73±2.55; p=0.035). No significant difference was observed between the groups in terms of the concomitant coronary artery disease (Table 1). 2 patients (1.4%) had a need for stenting to myocardial bridge in hospital follow up. Localization of the myocardial bridges was shown on the Figure 1.

Conclusion: Myocardial bridges were most frequently observed in LAD mid region in accordance with the literature. There was no relationship was observed between myocardial bridge stenosis severity and concomitant coronary artery disease. The average RDW was significantly higher in the severe coronary artery stenosis group compared to the mild coronary artery stenosis group. High RDW value appears to be a predictor of myocardial bridge severity.

ID: 17

Topic: **Cardiology » Percutaneous Coronary Interventions in Acute Coronary Syndromes**

Presentation Type: **Oral**

MEAN PLATELET VOLUME AND VON WILLEBRAND FACTOR AS BIOMARKERS FOR SHORT-TERM OUTCOMES AFTER PERCUTANEOUS CORONARY INTERVENTION

Mahmoud Elrayes

Mansoura University, Egypt, Mansoura, Egypt

**Corresponding Author (mahmoud_elrayes@mans.edu.eg)*

mahmoud_elrayes@mans.edu.eg

Abstract Text

Baseline platelet size correlates with future residual platelet reactivity. Mean platelet volume(MPV) is a rapid and simple measure in hospital and outpatient settings. An elevated MPV is a strong independent predictor of myocardial infarction(MI)after percutaneous coronary intervention(PCI) . von Willebrand factor(vWF) is a useful clinical marker strongly correlating with the incidence of MI and prognosis after PCI. There is increased vWF release after PCI contributing to endothelial dysfunction and increased incidence of thrombosis and no reflow. To investigate the association between MPV and vWF and incidence of post-PCI MI, we assessed baseline MPV and pre and post PCI vWF antigen activity in 80 patients presented to our hospital (Mansoura specialized medical hospital) for elective PCI and then follow up of the patients was conducted for 6- months period. Statistical analysis was performed using SPSS, version 21. When the 6-months incidence of MI was stratified by baseline MPV, the incidence of myocardial infarction was significantly more frequent with increasing MPV (21 patients (72.4%) with high MPV had MI at 6 months follow up($p=.002$) with mean \pm SD of baseline MPV 14.97 ± 3.76 ($p\leq .001$). When the 6-months incidence of MI was stratified by vWF antigen activity (pre and post PCI), the incidence of MI was significantly more frequent with increasing vWF antigen activity (20 patients (69%) out of 29 patients (100%) with normal pre PCI vWF antigen activity that demonstrated high post PCI vWF activity had MI at 6 months follow up($p=.011$) with mean \pm SD of vWF antigen activity 190.45 ± 38.62 ($p\leq .004$).

ID: 91

Topic: **Cardiology » Percutaneous Coronary Interventions**

Presentation Type: **Oral**

ASSOCIATION BETWEEN CORONARY COLLATERAL CIRCULATION AND CONTRAST INDUCED NEPHROPATHY IN VERY OLD PATIENT UNDERWENT ELECTIVE CORONARY ANGIOGRAPHY

Hasan Kadi¹, Birol Ozkan², Gokhan Alici², Eyup Avci¹, Eyyup Erkiz¹

¹Balikesir University Faculty of Medicine, Balikesir, Turkey

²University of Health Sciences Kartal Kosuyolu Heart Education and Research Center, Istanbul, Turkey

*Corresponding Author (drhkadi@gmail.com)

drhkadi@gmail.com, drbirolozkan@hotmail.com, gokhanalici@yahoo.com, dreyupavci@gmail.com, eyyuperkiz@gmail.com

Abstract Text

Background: Contrast nephropathy (CIN) is an acute renal failure which occurs after exposure to contrast agent and is generally reversible. Coronary collateral circulation (CCC) is the alternative source of blood to an ischemic area in the case of obstruction in the coronary artery. The endothelium plays a key role in the development of coronary collateral circulation as well as in the formation of CIN. However, with the increasing age, the endothelium is aging and its function decreases. Therefore the preventive role of endothelin in the development of CIN should be reduced in very old patients. We planned this study to test our hypothesis.

Methods: Patients aged ≥ 80 years who had at least one major coronary artery completely obstructed and whose blood creatinine level was measured before coronary angiography and on the second day after coronary angiography were included in the study. Acute coronary syndrome, previous coronary interventions or patients with a history of coronary artery surgery and patients with chronic renal failure and underwent hemodialysis were not included in the study. The grading of the collateral circulation was based on the Rentrop classification. Rentrop 0 and 1 poor, Rentrop 2 and 3 were classified as the good CCC. CIN was defined as an increase in the blood creatinine value by 25% or more on the second day after exposure to the contrast agent. Demographic, clinical and laboratory information of the patients were obtained from the files.

Results: While CIN was present in 14 (25%) of the 57 patients included in the study, [CIN (+) group] was not present, and in 43 (75%) of them there was no CIN [CIN (-) group]. 18 of the patients in the study group had good CCC (Good CCC group) and 39 poor CCC (poor CCC group). In the CIN (+) group, 11 patients (79%) had poor CCC and 3 patients (21%) had good CCC. CIN (-) group had poor CCC in 28 patients (65%), good CCC in 15 patients (35%). There was no significant difference between the two groups in terms of CCC development ($p = 0.511$). In the univariate analyzes, basal creatinine level and contrast volume were higher in CIN (+) group. In logistic regression analyzes, which CIN were accepted as independent variables and age, basal creatinine level, body mass index, CCC, DM and contrast volume were accepted as independent variables, basal creatinine level and the contrast agent volume were determined as an independent predictor for CIN ($p=0.004$, odds ratio=5.6, 95% confidence interval=2.14-25.68 and $p=0.002$, odds ratio=1.4, 95% confidence interval=1.01-2.25 respectively).

Conclusion: We did not find any relationship between CCC development and contrast induced nephropathy and CCC was not a predictor for CIN development in very old patients with coronary artery disease underwent coronary angiography. Independent predictors of contrast nephropathy were the volume of contrast agent used and basal creatinine level in this patient group. These results, which we found in our study, might be a sign of decreased endothelial function in very old patients.

ID: 71

Topic: **Cardiology » Percutaneous Coronary Interventions**

Presentation Type: **Oral**

GENE MUTATIONS RELATED WITH VITAMIN D METABOLISM AND SOME OTHER RISK FACTORS MAY CAUSE STENT RESTENOSIS IN CORONARY ARTERY DISEASE PATIENTS

Aysun Erdem Yaman¹, Deniz Kirac²

¹Dr. Siyami Ersek Thoracic and Cardiovascular Surgery Training and Research Hospital, Department of Cardiology, Istanbul, Turkey

²Yeditepe University, Faculty of Medicine, Department of Medical Biology, Istanbul, Turkey

**Corresponding Author (erdemaysun@yahoo.com)*

erdemaysun@yahoo.com, denizyat@hotmail.com

Abstract Text

Objective: Although the in-stent restenosis (ISR) rate has been reduced by drug eluting stents, it is still a problem following coronary angioplasty. ISR is a complex disease which is thought to be several causative mechanisms have not yet been fully identified. The predominant mechanism in the development of ISR is an inflammatory response to vessel wall injury during percutaneous coronary intervention (PCI). Vitamin D status is associated with coronary heart disease and post infarction adverse effects such as heart failure hospitalizations, recurrent acute myocardial infarction and death. Vitamin D is also reported to have anti-inflammatory properties. Thus it may also be related with ISR. Therefore the aim of this study is to investigate the association between vitamin D level, vitamin D receptor (VDR), vitamin D binding protein (VDBP) gene mutations which are related with vitamin D metabolism and some other risk factors with ISR in coronary artery disease (CAD) patients after stent implantation.

Methods: Totally, 93 stent implanted CAD patients were enrolled to the study .Fifty-eight patients were selected as cases who conducted ISR and 35 control subjects were selected from consecutive patients with no adverse cardiovascular events, including ISR, during a 2 years follow up post PCI. Peripheral blood samples were taken from all patients before PCI. Genomic DNA was extracted from 200 µL of blood using commercially available kits according to manufacturer's instructions. DNA purity and concentration were determined by NanoDrop spectrophotometer. rs2228570, rs1544410 in VDR, rs4588 and rs7041 in VDBP were investigated with Real-Time PCR device. Biochemical measurements, such as vitamin D and lipid levels, were performed using appropriate kits. Statistical Package for the Social Science (SPSS) 24.0 was performed for statistical analysis.

Results: At the end of the study, vitamin D deficiency was found statistically significant in patients. rs4588 and rs2228570 mutations were found statistically high in patient group. Also it was found that there is a relation between patients who had myocardial infarction history before stent implantation with rs7041 mutation. Additionally, rs2228570 mutation was found to be related with vitamin D deficiency.

Conclusion: It was considered that vitamin D deficiency and genetic factors which effect vitamin D metabolism may cause ISR. Possible tracking of gene variations and risk factors with some other studies may help to clarify the mechanism of ISR.

ID: 145

Topic: Cardiology » Percutaneous Coronary Interventions

Presentation Type: Oral

USEFULNESS OF SERUM GAMMA-GLUTAMYL TRANSFERASE LEVEL TO PREDICT STENT RESTENOSIS

Murat Gul¹, **Burak Açar**²

¹*Aksaray University, Aksaray, Turkey*

²*Kocaeli University, Kocaeli, Turkey*

**Corresponding Author (dktr_mrt@hotmail.com)*

dktr_mrt@hotmail.com, burakacarmd@yahoo.com

Abstract Text

Objective: The aim of this study was to investigate the usefulness of pre-procedural serum Gamma-Glutamyl Transferase levels in predicting the in-stent restenosis.

Materials and Methods: 552 consecutive patients who had undergone stent implantation and additional repeated coronary angiography for stent restenosis or de novo occlusion were analyzed. Main outcome was the Gamma-Glutamyl Transferase levels in patients whom had stent restenosis.

Results: Pre-procedural Gamma-Glutamyl Transferase level was significantly higher in patients with in-stent restenosis than those without restenosis (33.7 ± 21.4 vs. 23.7 ± 12.8 U/L, $p < 0.001$, respectively). On receiver-operating characteristics curve analysis Gamma-Glutamyl Transferase level >21.5 U/L had 71% sensitivity and 61% specificity (area under the curve 0.677, $p < 0.001$) in predicting in-stent restenosis.

Conclusions: Our results indicate that GGT is a powerful and independent predictor of in-stent restenosis in patients who had undergone stent implantation.

Table 4: Multivariate logistic regression analysis showing independent predictors of in-stent restenosis

Variable	Univariate		Multivariate	
	OR (95% CI)	P Value	OR (95% CI)	P value
Sex	1.468 (1.007-2.140)	0.046	0.824 (.494-1.374)	0.824
Age	0.996 (0.998-1.013)	0.638	-	-
Current Smoker	1.517 (1.082-2.129)	0.016	1.319 (.850-2.048)	0.217
HDL	0.975 (0.959-0.991)	0.002	0.977 (0.959-0.995)	0.012
LDL	0.999 (0.994-1.004)	0.671	-	-
Triglyceride	1.002 (1.00-1.004)	0.059	-	-
GGT	1.039 (1.026-1.052)	<0.001	1.042 (1.028-1.056)	0.001
Hemoglobin	0.992 (0.925-1.064)	0.823	-	-
Stent length	0.987 (0.949-1.027)	0.513	-	-
Stent Diameter	0.619 (0.383-1.001)	0.050	0.494 (0.285-0.854)	0.012
LVEF	0.991 (0.959-1.024)	0.579	-	-
CAG time	0.934 (0.914-0.955)	<0.001	0.928 (0.906-0.951)	<0.001
Diabetes	0.735 (0.514-1.050)	0.090	-	-
Hypertension	0.713 (0.207-1.003)	0.052	-	-
Uric acid	1.196 (1.058-1.352)	0.004	1.205 (1.049-1.383)	0.008

LVEF: left ventricular ejection fraction, HDL: high density lipoprotein, LDL: low density lipoprotein, GGT: gamma glutamyl transferase, KAG: coronary angiography.

ID: 13

Topic: **Cardiology » Percutaneous Coronary Interventions in Acute Coronary Syndromes**

Presentation Type: **Oral**

ACUTE MYOCARDIAL INFARCTION DUE TO ACUTE BARE METAL STENT THROMBOSIS IN A PATIENT WITH SYSTEMIC LUPUS ERYTHEMATOSUS

Erdoğan Sökmen, Serkan Sivri, Mustafa Çelik

256, Kırşehir, Turkey

**Corresponding Author (erdoganmen@gmail.com)*

erdoganmen@gmail.com, drserkansivri@gmail.com, muscelik50@gmail.com

Abstract Text

A 39-year-old female with systemic lupus erythematosus (SLE) and previous history of deep vein thrombosis presented with acute coronary syndrome (ACS). Her parameters of thrombophilia (especially antiphospholipid syndrome) were reported to be negative formerly. Coronary angiography (CA) revealed 85% stenosis in the left anterior descending (LAD) artery at diagonal 1 level with heavy thrombus in the mid portion of LAD immediately after the diagonal 1 and thrombus embolism in distal part of LAD. Intracoronary tirofiban was administered, followed by 24 hour infusion. Control angiography showed thrombus resolution in mid and very distal portions of LAD with residual 85% stenosis and suspected dissection in LAD artery at the level of first diagonal branch. A percutaneous coronary intervention (PCI) with a drug-eluting stent (DES) was considered. However, a bare metal stent (BMS) was implanted instead, since she could not afford a DES. 3 days after discharge, she was re-admitted with ST-elevation ACS despite regular use of dual antiplatelet therapy. CA revealed occlusion of BMS. A balloon angioplasty and thrombus aspiration was performed with restoration of TIMI 3 flow. Intravenous tirofiban was administered for 48 hours. A control CA revealed disappearance of thrombus within BMS. No other intervention was performed and oral warfarin was started as add-on treatment. She was discharged from the hospital 7 days later in good clinical condition. Optimal therapy for ACS in SLE patients is not well established. Oral anticoagulation therapy may be considered as an add-on treatment to dual antiplatelet therapy for selected patients, especially those with previous history of venous thrombosis, even in the absence of antiphospholipid syndrome.

ID: 523

Topic: **Cardiology » Percutaneous Coronary Interventions**

Presentation Type: **Oral**

A DEPLOYED STENT DISLODGE MENT DURING RETRIEVAL OF STENT JAILED SIDE BRANCH GUIDEWIRE: AN UNUSUAL COMPLICATION

Atila Iyisoy

Gülhane Trainig Research Hospital, Ankara, Turkey

**Corresponding Author (aiyisoy@hotmail.com)*

aiyisoy@hotmail.com

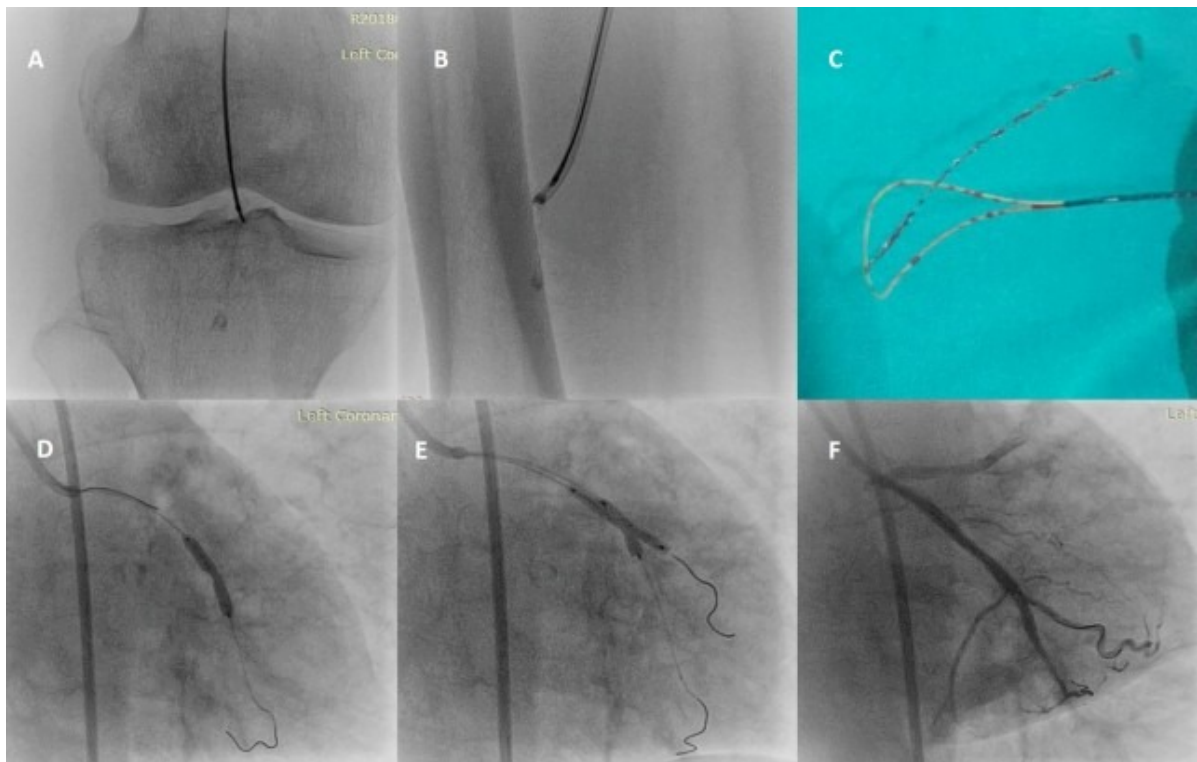
Abstract Text

We report an unusual complication of a deployed stent dislodgement during retrieval of stent jailed side branch guidewire and retrieval from popliteal artery via snare method. A 74 age woman was underwent coronary angiography and it showed critical stenosis of the circumflex artery just before the major obtuse marginalis (Fig.1A). PCI was decided to perform circumflex artery. Through a 6 Fr JL4 guiding catheter a 0,014-inch floppy guidewire was advanced firstly major obtuse marginalis and second 0,014-inch guidewire was inserted to the distal circumflex artery. A 2,5x18 mm drug-eluting stent was advanced to the lesion and we noticed that the side branch guidewire was twisted (Figure 1B). We implanted the stent at a nominal pressure at 9 atm (Figure 1C). The stent balloon was deflated and cine showed us that the stent was fully deployed and jailed side branch guidewire was twisted (Figure 1D). First of all the balloon was retracted into the guiding catheter. After that, the side branch guidewire had to be retracted into the guiding catheter by forcefully manner. Hopefully, we achieved to pull back the jailed wire without any wire-break. But after retraction of the jailed guidewire, implanted stent was lost (Figure 1E). This was an unusual complication while retrieving the jailed side branch guidewire. We noticed that the stent was above the balloon catheter, and stent balloon complex was in the tip of the guiding catheter. The cine angiographic view stent was deformed and elongated (Figure 1E). We pulled back to the entire system and when the system came to the tip of the sheath the stent was caught by sheath and stent was eluded from the balloon and advanced behind the middle part of the sheath (Figure 1F). Then we decided to retrieve the stent via snare method. The stent advanced to the popliteal artery (Figure 2A). We advanced an AndraSnare in the right Judkins catheter and the stent was caught via snare from to the popliteal artery and retrieval (Figure 2B). The stent was deformed and elongated (Figure 2C). Then we decided not to wire side branch and 2,5x18 mm drug-eluting stent was advanced to the lesion and inflated (Figure 2D). After that, we decided to perform final kissing PTCA and the major obtuse marginalis was wired with 0,014 floppy wire and we performed kissing balloon with a 2.5x18 mm and 2,0x15 mm semi-compliant balloons (Figure 2E). When the balloons deflated the angiogram was good and after retrieval the wires and balloons final angiographic result was again good (Figure 2F). The most important cause was that; the guidewires were twisted to each other at two points and when the twisted side branch wire retracts, it may have caused the deployed stent to retrieving and dislodged into the catheter.

Figure 1

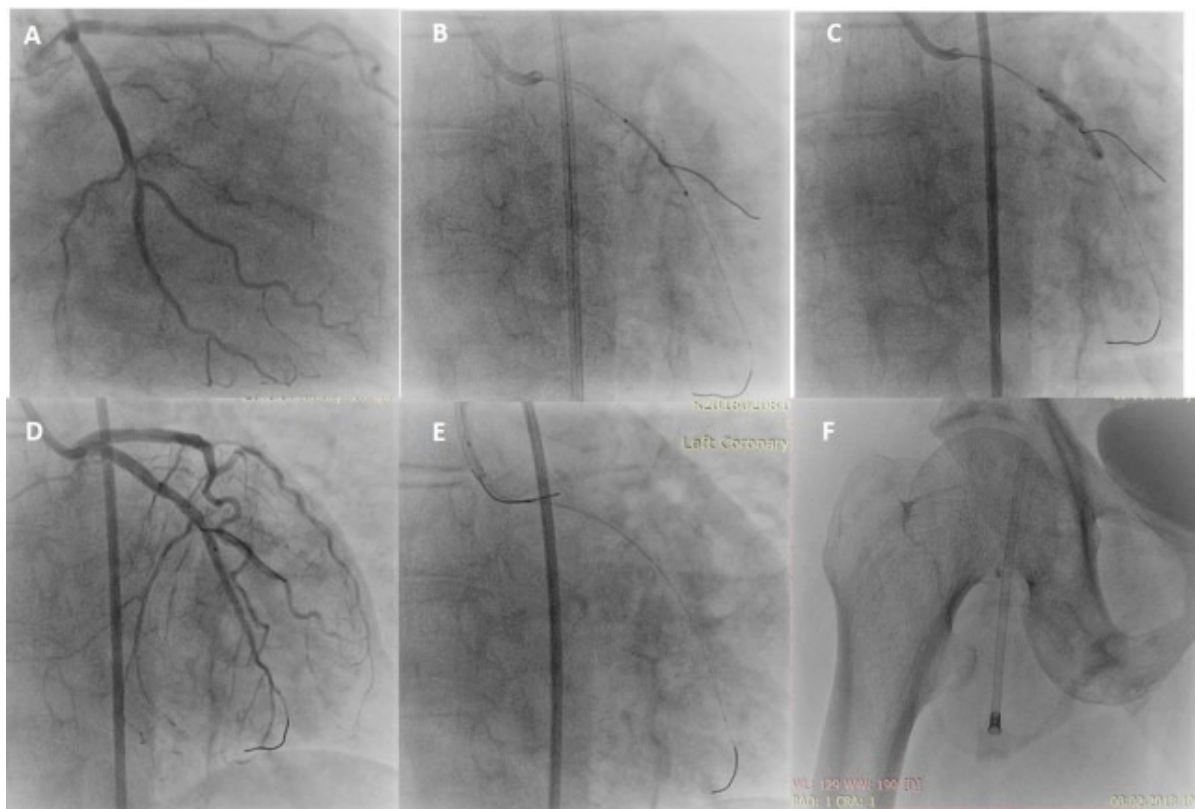

Figure 2



ID: 87

Topic: **Cardiology** » **Percutaneous Coronary Interventions**

Presentation Type: **Oral**

FROG SIGN OF CONTRAST INDUCED SIALADENITIS

Songül Usalp¹, Belma Yaman¹, Hatice Kemal Günsel¹, Levent Cerit¹, Hamza Duygu¹

¹*Near East University, Nicosia, Cyprus*

^{*}*Corresponding Author (dr.songuusalp@hotmail.com)*

dr.songuusalp@hotmail.com, belmayaman@yahoo.com, kemal.hatice@hotmail.com, drcerit@hotmail.com, hamzakard@yahoo.com

Abstract Text

Background: Iodine related sialadenitis is a rare situation among the causes of sialadenitis. We report an 82-years-old man of the iodide-induced sialadenitis following coronary angiography with used nonionic low osmolar contrast media.

Case:

An 82-year-old man presented with an upper abdominal pain having unstable angina pectoris. He was symptomatic with shortness of breath on moderate exertion. He had hypertension, hyperlipidemia, chronic obstructive pulmonary disease.

Coronary angiography was performed using Iohexol (Omnipaque 350, GE Healthcare). A non-ionic monomeric low osmolality contrast medium containing approximately 350 mg I/ml iodide. A total of 60 ml of iodinated contrast media was used. Coronary angiogram revealed normal coronary arteries except %20 narrowing in the proximal left anterior descending artery. So, the patient was treated medically. About 24 hours after the procedure, the patient complained of indolent bilateral swelling on his upper and front neck. In physical examination the submandibular gland was enlarged, palpable and no purulent drainings in any of the ductal openings (Figure 1). The patient was afebrile, and there isn't any enlargement of the parotid gland and respiratory or systemic symptoms. Contrast-induced sialadenitis ('iodide mumps') was suspected on the background of clinical presentation.

Blood tests revealed white blood cell count, haemoglobin, thyroid stimulating hormone, amylase level was normal, serum creatine level 1.35 mg/dl and CRP was 16.07 mg/l. Neck ultrasonography is showing the submandibular gland to have a significantly greater longitudinal diameter and thickness. Structure and size of thyroid and parathyroid gland were normal.

Spiramycin 3 Miu twice a day and prednisolone 80 mg/day were recommended by otolaryngologist. After six days, submandibular swelling exactly resolved, serum CRP level is decreased to 0.7 mg/dl, and follow-up has been eventless (Figure 2).

Discussion:

There have been more than 40 cases of iodide mumps reported in the English language literature since 60 years time. However, it is still unclear that how to develop contrast-induced sialadenitis after the use of either nonionic dimers or nonionic monomers. In the case of high plasma concentrations of iodine (> 10 mg/100 ml), due to renal dysfunction, it can be removed by alternative pathways such as salivary glands (1). Consequently, renal insufficiency considers a substantial risk factor for sialadenitis. Whereas, most of the cases of sialoadenitis complicating contrast media administration are described in patients with normal renal function. Our patient had mild-moderate renal failure so that exposed more iodine load.

In evaluating the patient with sialadenitis, steps should be taken in this following order: history, physical examination, laboratory investigation, radiography, and if indicated fine – needle aspiration biopsy. Ultrasonography can be used to distinguish between solid versus cystic lesions of the gland. Treatment should be directed towards managing the underlying problem and achieving homeostasis. Acute symptoms resolve within one week; however, oedema in the area may last several weeks. Patients with sialadenosis have a good prognosis if their underlying problem is adequately controlled.

Conclusion:

One of the late reactions to iodine contrast agents is sialadenitis, that is a very rare complication and any iodinated contrast medium both non-ionic, and hypo-hyperosmolar agents may cause it.

Figure 1: Bilateral swollen of submandibuler glands at onset

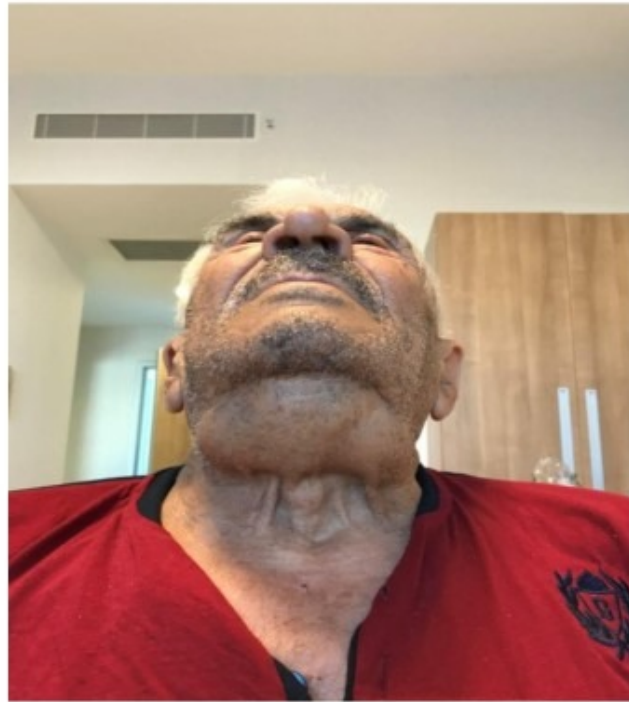
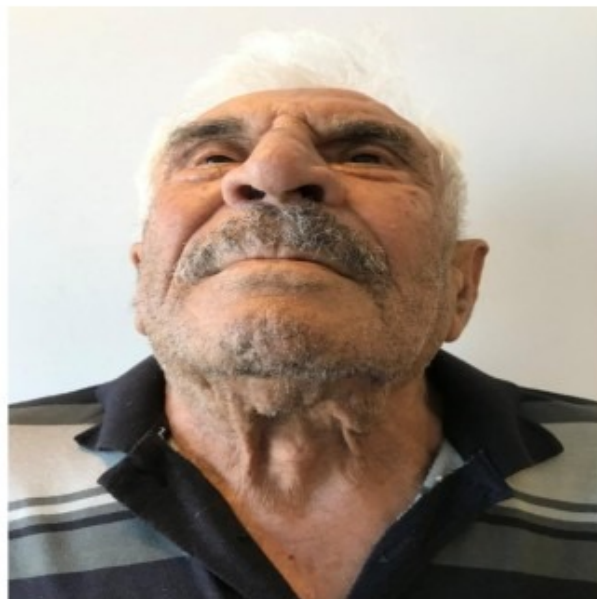

Figure 2: Six day after, the submandibuler glands improved completely.



Oral Presentation**Diagnostic and Therapeutic Challenges in Heart Failure**

Date: 28.03.2019 Time: 14:30 - 15:30 Hall: 5

ID: 297

Topic: **Cardiology » Dilated Cardiomyopathy**Presentation Type: **Oral****A DILATED CARDIOMYOPATHY IN A 14-YEAR-OLD MENTALLY RETARDED BOY RELATED TO SELENOPROTEIN GENE DEFECT**Umit Yuksek¹, Belma Yaman¹, Songül Usalp¹, Levent Cerit¹, Onur Akpınar¹, Neşe Akçan¹, Neslihan Önenli Mungan², Hamza Duygu¹¹Near East University, Nicosia, Turkish Republic of Northern Cyprus²Çukurova University, Adana, Turkey

*Corresponding Author (uyuksek@yahoo.com)

uyuksek@yahoo.com, belmayaman@yahoo.com, dr.songulusalp@hotmail.com, drcerit@hotmail.com, onurakpinar@yahoo.com, dr.neseakcan@gmail.com, munganhno@gmail.com, hamzakard@yahoo.com

Abstract Text

OBJECTIVE: Pediatric dilated cardiomyopathy (DCM) is a rare condition which has an annual incidence rate of 0.5 in 100000 children in North America. It has many underlying causes, but mostly it's idiopathic. The treatment of this condition is well established in adults, but because of the paucity of studies in children, evidence based treatment modalities are lacking in children. We are reporting an interesting case of pediatric DCM who had some unique properties in treatment.

METHODS: A 14-year-old child presented to the cardiology outpatient clinic with an effort dyspnea and abdominal pain for a few weeks. He was mentally retarded and had a tall stature and an epilepsy history. A transthoracic echocardiography was performed which showed a serious left heart dilatation with an EF of 16%, a moderate mitral and a mild aortic regurgitation (Figure 1). Dilated cardiomyopathy was diagnosed. A multidisciplinary etiologic work-up was performed. Cardiac MRI gave nothing related to etiology. Viral infection work-up was negative. His cranial MRI showed a pontocerebellar hypoplasia. All hormonal tests for tall stature were normal whereas serum parathyroid hormone, vitamin D3 and magnesium levels were low. Serum and urinary aminoacid levels suggested selenoprotein gene defects. Molecular analysis for cardiomyopathy, pontocerebellar hypoplasia and selenoprotein gene defects were studied which will give result in a few months. We started coenzyme q 1x300 mg, carnitine 3x500 mg, tiamine 1x250 mg, diuretic and beta-blocker treatments. But, because the tachycardia continued, we also added ivabradine treatment 5 mg 2x1. Ivabradine is not widely used in children and the main studies of this drug excluded patients <18 years of age. So we used low dose of the drug. Afterwards we also started sacubitril/valsartan (ARNI) treatment in 24/26 mg/day dosage. This treatment also has not much experience on children. So we started the minimum dose.

RESULTS: The patient did well with these drug treatments. The pulses went below 70/min. No kidney function abnormality or electrolyte disturbances were noted. After consultation with pediatric psychiatry (because of mental retardation), we implanted DDD ICD-CRT pacemaker to the patient. We discharged the patient. Two months after we started ARNI and ivabradin treatment, a control echocardiography showed a slight improvement in EF (22%). The patient had no decompensation episode.

CONCLUSION: Pediatric DCM's are rare but their prognosis is not good. We showed in our 14-year-old patient that well established treatments for adult DCM patients may be used safely and may show some benefit in this population.

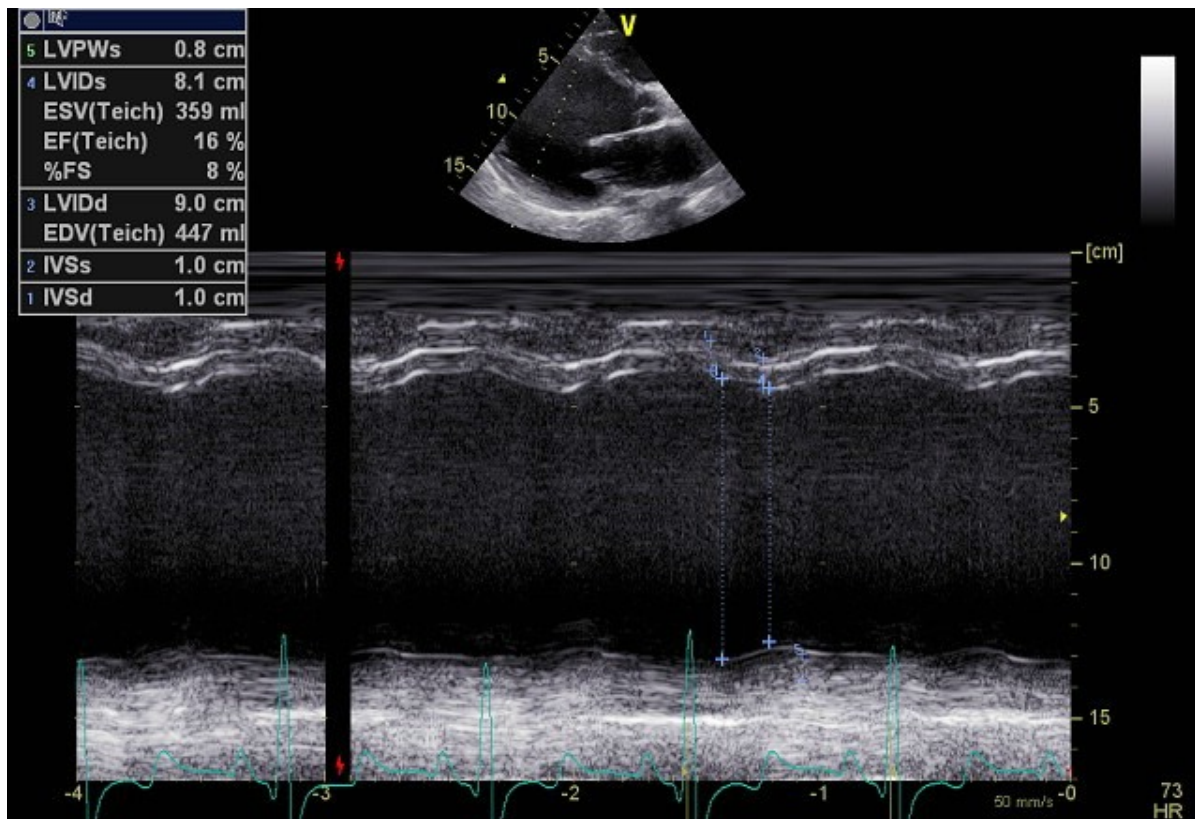


Figure 1.

ID: 383

Topic: Cardiology » Chronic Heart Failure

Presentation Type: Oral

EVALUATION OF THE RELATIONSHIP BETWEEN FUNCTIONAL CAPACITY AND RIGHT VENTRICULAR FUNCTIONS, PULMONARY ARTERIAL STIFFNESS AND HEMATOLOGICAL PARAMETERS IN PATIENTS WITH HEART FAILURE (ISCHEMIC-NON-ISCHEMIC)

Mustafa Demir¹, Atila Iyisoy²

¹Clinic of Cardiology Tekden Hospital, Denizli, Turkey

²Department of Cardiology Training and Research Hospital, Ankara, Turkey

*Corresponding Author (mstdemir@gmail.com)

mstdemir@gmail.com, aiyisoy@hotmail.com

Abstract Text**Objectives:**

Heart failure (HF) is a complex clinical syndrome that results from any structural or functional impairment of ventricular filling or ejection of blood. Functional capacity is an important entity for patients with heart failure to fulfill their basic daily needs. It is a well-known fact that functional capacities not directly related to left ventricular ejection fraction. Exercise response of patients with heart failure is complicated and it is one of the topics that is not still clarified. In this study, we aimed to evaluate the relationship between functional capacity and right ventricular functions, pulmonary arterial stiffness (PAS) and blood parameters in HF patients with reduced ejection fraction (LVEF \leq 40%). In addition, we aimed to evaluate the differences between two groups (ischemic and nonischemic HF).

Methods:

Among stage C HF patients LVEF $<$ 40% on transthoracic echocardiography, 64 clinically stable patients were enrolled. According to the etiology of HF, patients were divided into two groups: ischemic and non-ischemic. Functional capacities of the patients included in the study were determined by NYHA functional classification and 6 minute walking test (6MWT). Additionally, uses of the drugs as well as demographic characteristics such as age, gender and clinical history are recorded from all patients.

Results:

There was no significant difference in terms of clinical and demographic properties between two groups. In our study, according to 6MWT, female patients, shorter people and the elderly ones walked less distance. When the whole group made the correlation of hematological parameters with 6MWT, GFR, hemoglobin, and lymphocyte levels were correlated positively; N/L ratio, Urea, LDH and pro-BNP levels were significantly correlated negatively. No statistically significant difference was found upon comparison of the left heart structures between the two groups ($p>0.05$). In our study, pulmonary arterial stiffness (PAS) was used in the assessment of the pulmonary vascular bed as a new echocardiographic parameter, it was found to be higher in patients with HF. Besides the increased value of PAS in HF patients, a significant negative correlation between the 6MWT determining functional capacity and PAS was seen. This relationship remained significant in the sub-analysis of the two groups. Moreover, PAS and right ventricular function parameters such as TAPSE, S' were found negatively correlated, this finding was compatible with the literature. These findings suggest that PAS may be an early precursor of the right ventricular dysfunction.

Conclusion:

In this study, we aimed to demonstrate the functional capacity determiners in patients with HF. Male gender, height and age affected 6MWT and it was compatible with literature. We determined that Hgb, GFR and albumin levels had a significant positive correlation with 6MWT independently of etiology, but Pro-BNP, N/L ratio and LDH had a significant negative correlation with 6MWT. We can conclude that HF exhibits similar effects on cardiac functions regardless of etiology. In our study, PAS, one of the parameters evaluating pulmonary vascular bed, increased in both groups. Moreover, both 6MWT and right ventricular systolic functions have a significant negative correlation with PAS. In the light of this information, PAS may determine the functional capacity and prognosis in patients with HF. Furthermore, PAS can be used as an early predictor of the right ventricular dysfunction.

ID: 420**Topic: Cardiology » Chronic Heart Failure****Presentation Type: Oral****RELATION BETWEEN PROGNOSTIC NUTRITIONAL INDEX AND LEFT VENTRICULAR FUNCTION IN PATIENTS WITH A ISCHEMIC CARDIOMYOPATHY****Onder Ozturk¹, Unal Ozturk¹***¹Diyarbakir Gazi Yasargil Education and Research Hospital, Diyarbakir, Turkey***Corresponding Author (droozturk21@hotmail.com)**droozturk21@hotmail.com, drunalozturk@gmail.com*

Abstract Text**Relation Between Prognostic Nutritional Index and Left Ventricular Function in Patients with a Ischemic Cardiomyopathy**

Objective: Nutritional status has been related to clinical outcomes in patients with heart failure. We assessed the association between nutritional status, indexed by prognostic nutritional index (PNI), and left ventricular function in ischemic cardiomyopathy patients hospitalized for acute heart failure.

Methods: A total of 67 patients (age 63±14, 62% men) hospitalized for a acute heart failure. Based on the LVEF, they were classified into 2 groups: LVEF < 30% (Group 1, n=23), LVEF> 30% (Group 2, n=44). PNI was calculated as $10 * \text{serum albumin (g/dL)} + 0.005 * \text{total lymphocyte count (per mm}^3\text{)}$. Echocardiographic examinations were performed using the parasternal longitudinal axis and apical 4-chamber windows in accordance with the recommendations of the American Echocardiography Committee. One-way ANOVA and Chi-square analyses were used to compare differences among parameters.

Results: There were no significant differences among clinical parameters of patients (Table 1). eGFR, albumine, creatinine, hemoglobin, lymphocyte count were significantly lower in Group 1 than Group 2 patients ($p < 0.05$). PNI was significantly lower in Group 1 than Group 2 patients (37.5 ± 5.9 and 43.7 ± 6.8 , $p = 0.036$).

Conclusions: Our results suggested that, LVEF is important predictor of nutritional index.

Table 1: Clinical characteristics of patients.

Variables	LVEF (<30%) n=23	LVEF (≥30%) n=44	p value
Age (years)	65.7±16	61.3±13	0.545
Sex (F/M)	8/15	18/26	0.478
Heart rate (beats/min)	94.3±16.9	87.3±13.5	0.644
Hypertension	9 (40%)	11 (25%)	0.052
Diabetes	7 (30%)	12 (28%)	0.728
Smoking	14 (61%)	24 (56%)	0.338
BMI (kg/m ²)	23.6±5.7	25.4±3.5	0.779
Hypercholesterolemia	6 (25%)	15(34%)	0.714
Egfr	41±23	49±17	<0.05
Albumin (g/dL)	3.1±0.6	3.7±0.5	<0.05
Glucose (mg/dL)	168±76	157±55	>0.05
Creatinine (mg/dL)	2.3±1.6	1.7±1.1	<0.05
Hemoglobin (g/dL)	10.5±2.3	11.5±1.9	<0.05
Lymphocyte count, 10 ⁹ /L	0.8±0.6	1.4±0.5	<0.05
Prognostic nutritional index (PNI)	37.5±5.9	43.7±6.8	p=0.036
Platelet count, 10 ⁹ /L	178±87	193±92	>0.05

ID: 320

Topic: Cardiology » Chronic Heart Failure

Presentation Type: Oral

THE RELATIONSHIP BETWEEN PROPORTIONAL PULSE PRESSURE AND CARDIAC INDEX IN PATIENTS WITH HEART FAILURE

Abdullah Özçelik, Ahmet Soylu, Sümeyye Fatma Özer, Mükremin Coşkun, Yakup Alsancak, Ahmet Seyfeddin Gürbüz

Necmettin Erbakan University, Meram Medical Faculty, Konya, Turkey

**Corresponding Author (drabdullahozcelik@gmail.com)*

drabdullahozcelik@gmail.com, asoylu44@gmail.com, smyyftmzr@hotmail.com, mukremincoskun@gmail.com, dryakupalsancak@gmail.com, ahmetseyfeddingurbuz@hotmail.com

Abstract Text

OBJECTIVE: Heart failure is a problem that affects more than 20 million people in the world and increases the prevalence. Cardiac hemodynamic status, which informs us about the adequacy of organ perfusion, can be estimated with noninvasive parameters such as cardiac output and cardiac index (CI). In this study, we aimed to investigate the relationship between CI with pulse pressure (PP) and proportional pulse pressure (PPP) in patients with low ejection fraction, so that we could predict the cardiac hemodynamic status with a simple test such as blood pressure measurement in this patient group.

METHODS: 100 patients who applied to our cardiology outpatient clinic or who were admitted to our cardiology clinic, and had a heart failure diagnosis and had an ejection fraction $\leq 40\%$ were enrolled. Blood pressure measurement was performed manually with a sphygmomanometer based on mercury. Echocardiographic evaluation was performed using conventional echocardiography and tissue doppler imaging. Patients included in the study were divided into two groups, CI < 2.2 L/min/m² and ≥ 2.2 L/min/m². The two groups were compared in terms of demographic features, clinical features, left ventricular ejection fraction (LVEF), myocardial performance index (MPI), PP and PPP.

RESULTS: The average age of the patients included in the study was 67,00 [15,00] and 77% of the patients were male. In our study, there was no significant difference between low and high CI groups in terms of baseline demographic and clinical characteristics (table 1). In addition, echocardiographically measured LVEF, mitral and tricuspid valve E / A ratios, systolic pulmonary artery pressure, right ventricle, lateral wall and septal wall MPI values were also found to be similar between the two groups. The most important finding of our study was that the PP and the PPP were statistically significantly lower in the group with low CI compared to the group with high CI (p < 0.001). In addition, the CI showed a strong positive correlation with the PPP (r:0.584, p<0.001) (Figure 1).

CONCLUSIONS: The PPP in heart failure patients was found to be strongly correlated (r:0.584, p<0.001) with the CI. This data obtained in our study showed that PPP, which was easily obtained with a physical examination finding at the first evaluation of heart failure patients, provided extremely important information for evaluating the hemodynamic status of heart failure patients and could be used for estimating the severity of heart failure.

Figure 1

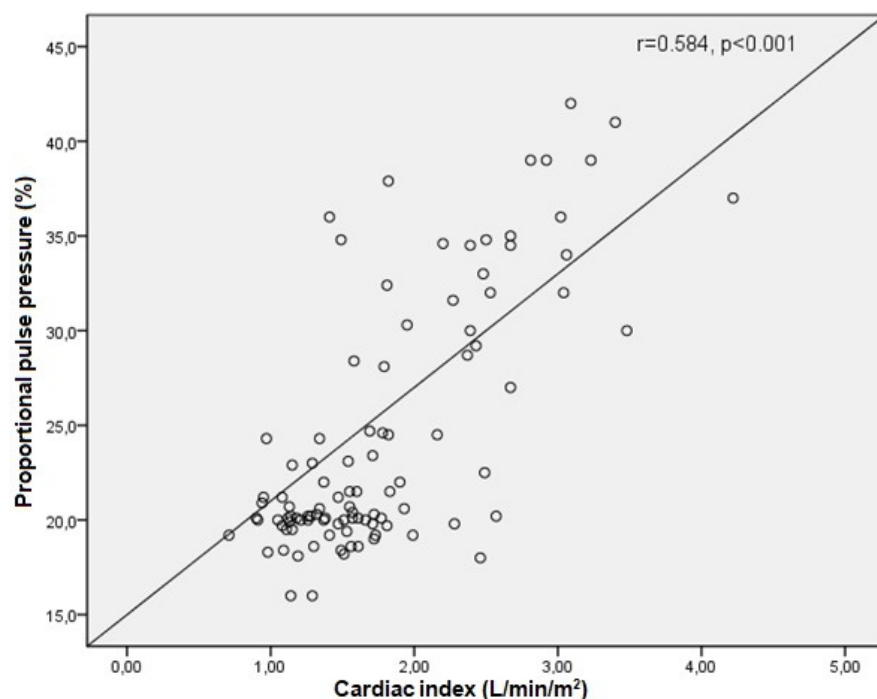


Table 1

Parameters	Study group (n= 100)	Cardiac index < 2.2 L/min/m ² (n=75)	Cardiac index ≥ 2.2 L/min/m ² (n=25)	P value
Age, year	67 (15)	67 (16)	63 (14)	0.456
Gender: male, n (%)	77 (77)	57 (76)	20 (80)	0.789
Heart rate, beats / min	73 (15)	70 (18)	80 (22)	0.049*
Mean BP, mmHg	90 (7)	92 (7)	86 (11)	0.002*
Pulse pressure, mmHg	22.50 (10)	22 (3)	37 (10)	<0.001*
Proportional pulse pressure, %	20.80 (9.90)	20.20 (3.20)	33 (7.60)	<0.001*
Proportional pulse pressure ≥%25, n(%)	29 (29)	8 (10.7)	21 (84)	<0.001*
Cardiac output, L/min	2.96 (1.81)	2.75 (0.92)	5.12 (1.11)	<0.001*
Diabetes mellitus, n(%)	53 (53)	41 (54.7)	12 (48)	0.646
Hypertension, n(%)	65 (65)	49 (65.3)	16 (64)	1.000
Chronic kidney disease, n(%)	23 (23)	17 (22.7)	6 (24)	1.000
Hyperlipidemia, n(%)	32 (32)	23 (30.7)	9 (36)	0.628
Cerebrovascular event, n(%)	12 (12)	9 (12.2)	3 (12)	1.000

ID: 296

Topic: Cardiology » Chronic Heart Failure

Presentation Type: Oral

PREDICTORS OF CARDIOTOXICITY IN PATIENTS WITH BREAST CANCER RECEIVING ANTHRACYCLINE-BASED CHEMOTHERAPY

Muhammet Dural, Kadir Uğur Mert

Eskişehir Osmangazi University, Faculty of Medicine, Eskişehir, Turkey

**Corresponding Author (muhammet_dural@hotmail.com)*

muhammet_dural@hotmail.com, kugurmert@gmail.com

Abstract Text

Objective: Anthracycline-induced cardiotoxicity (AiC) is multifactorial and overall incidence is 9%. In this study, we aimed to reveal the predictors of AiC in patients with breast cancer receiving anthracycline-based chemotherapy (AbC).

Methods: In this retrospective cohort study, 252 patients with breast cancer who received AbC were included. Pre-AbC left ventricular ejection fraction (LVEF) and LVEF values within one year after AbC were obtained from the medical records. Baseline characteristics of patients and the predictors of AiC were evaluated by univariate and multivariate logistic regression analyzes.

Results: In the study population, a total of 32 (12.7%) patients had AiC. In univariate analysis, patients with cardiotoxicity were likely to have higher pre-treatment serum uric acid level, higher cumulative doxorubicin equivalent dose, and lower pre-treatment serum total bilirubin and direct bilirubin levels. In multivariate logistic regression analysis, serum uric acid level (odds ratio: 1.42, 95% CI: 0.981-2.053, P=0.046) and doxorubicin equivalent dose (odds ratio: 1.03, 95% CI: 1.017-1.046, P<0.001) were found to be the independent predictors of AiC.

Conclusions: Our study shows that in patients with breast cancer receiving AbC pre-treatment serum uric acid level and doxorubicin equivalent dose of anthracycline administered are the independent predictors of AiC.

Keywords: Fragmented QRS, anthracycline, chemotherapy, breast cancer

ID: 79

Topic: **Cardiology » Chronic Heart Failure**Presentation Type: **Oral****PREVALENCE AND IMPLICATIONS OF CORONARY ARTERY DISEASE
IN AN UNSELECTED TURKISH COHORT OF PATIENTS WITH HEART
FAILURE AND PRESERVED EJECTION FRACTION****Bülent Özlek, Cem Çil, Oğuzhan Çelik***Muğla Sitki Kocman University Training and Research Hospital, Muğla, Turkey***Corresponding Author (bulent_ozlek@hotmail.com)**bulent_ozlek@hotmail.com, drcemcil@gmail.com, droguzhancelik@hotmail.com***Abstract Text**

Objectives: Coronary artery disease (CAD) plausibly explains the pathophysiology of heart failure with preserved ejection fraction (HFpEF), because myocardial ischemia causes diastolic and systolic dysfunction, which are both common in patients with HFpEF. Therefore, we investigated the prevalence and clinical implications of CAD in a large Turkish population of patients with HFpEF.

Methods: The APOLLON (A comprehensive, Observational registry of heart failure with mid-range and preserved ejection fraction) is a multicenter and observational study conducted in Turkey. Consecutive patients admitted to the cardiology clinics who had heart failure with mid-range ejection fraction or HFpEF were included (NCT03026114). Patients with HFpEF were divided into two groups: with CAD and without CAD. We performed a post-hoc analysis of data from this large study.

Results: The study population included 819 (mean age of 66.83 ± 10.71 years, 57.8% women) HFpEF patients from 11 sites in Turkey. Prevalence of CAD was 33.1% in patients with HFpEF. Compared to patients without CAD, those with CAD were more likely to be male (57.2 vs 34.9%, $p < 0.001$) and smoker (20.3 vs 13.5%, $p = 0.012$). Patients without CAD had higher prevalence of New York Heart Association class III or IV symptoms ($p < 0.001$), paroxysmal nocturnal dyspnea (38.5 vs 24%, $p < 0.001$), palpitation (54.6 vs 40.2%, $p < 0.001$), fatigue (68.6 vs 53.1%, $p < 0.001$), jugular vein distention (23.4 vs 14.4%, $p = 0.003$), peripheral edema (35.9 vs 25.1%, $p = 0.002$), and history of hospitalization for heart failure (HF) in the last year (21.7 vs 12.2%, $p = 0.001$) (**Figure 1**). In line with these clinical findings, patients without CAD had higher N-terminal pro-B-type natriuretic peptide levels (698 vs 377 pg/ml, $p < 0.001$). Compared to patients with CAD, those with patients without CAD had also higher prevalence of atrial fibrillation (47.1 vs 20.3%, $p < 0.001$). As expected, prevalence of diabetes mellitus (40.6 vs 24.5, $p < 0.001$), hyperlipidemia (42.8 vs 14.1%, $p < 0.001$), and history of cerebrovascular accident (7.7 vs 3%, $p = 0.008$) was higher in CAD group. Atrial fibrillation was the main etiology (40.5%) of HF in patients without CAD.

Conclusions: The results of our study revealed that HFpEF patients without CAD have more signs and symptoms of HF. Compared to the previous HFpEF studies, the prevalence of CAD is significantly lower in patients with HFpEF in Turkey. Prospective studies are needed on this subject in our country.

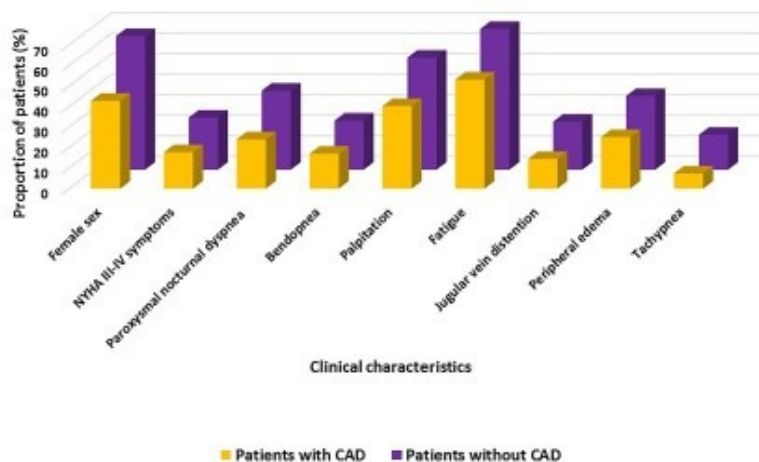


Figure 1: Clinical characteristics of patients with CAD vs without CAD

Oral Presentation

New Pharmacotherapeutic Options in Heart Failure

Date: 28.03.2019 Time: 16:00 - 17:00 Hall: 5

ID: 560

Topic: **Cardiology » Chronic Heart Failure**

Presentation Type: **Oral**

A REAL-WORLD PATIENT RESPONSE TO SACUBITRIL/VALSARTAN: A RETROSPECTIVE ANALYSIS OF PATIENTS WITH HEART FAILURE WITH REDUCED EJECTION FRACTION.

Sercan Okutucu¹, **Cengiz Sabanoglu**², Begum Yetis Sayin¹, Hakan Aksoy¹, Mehmet Kadri Akboga³, Ali Oto¹

¹Memorial Ankara Hospital, Ankara, Turkey

²Kırıkkale Yuksek Ihtisas Hospital, Kirikkale, Turkey

³Gazi University, Ankara, Turkey

*Corresponding Author (sercanokutucu@yahoo.com)

sercanokutucu@yahoo.com, drchingiz23@gmail.com, begumyts@yahoo.com, haksoy63@yahoo.com,
mkakboga@yahoo.com, seo8882@gmail.com

Abstract Text

Introduction: Angiotensin receptor neprilysin inhibitor (ARNI, sacubitril/valsartan) reduced heart failure (HF)-admissions and cardiovascular mortality in the PARADIGM-HF-trial. However, little is known about use of ARNI or impact in real-world practice. Herein, we aimed to present real world patient response to ARNI.

Methods: This analysis included data from medical records of patients with HF and reduced ejection fraction (HFrEF) (n = 107) who were treated with ARNI between 2015 and 2019. All patients had New York Heart Association (NYHA) functional class II-IV, left ventricular ejection fraction $\leq 35\%$. In 21 patients (20%) functional capacity were NYHA class II.

Results: Most patients (88 patients, 87.2%) had ARNI treatment at the dose of 49/51 mg twice a day. A 24/26mg twice daily dosage was started in 17.8% of patients. In 39 patients (36.4%) 97/103 mg twice a day dosage could be gradually achieved. Most common adverse reaction was symptomatic hypotension. In 3 patients, ARNI treatment was discontinued because of persistent symptomatic hypotension. Among study population, ARNI treatment was initiated after clinical stabilization in 47 patients (44%) before hospital discharge. There was angioedema in 1 patient (0.9%) after initiation ARNI. In 2 patients (1.8%) ARNI treatment were discontinued due to hyperkalemia. In 2 patients there were pruritus and in 1 patient refractory cough was observed. ARNI treatment associated with improvement in MLWHFQ scores (44.4 ± 14.2 vs. 35.4 ± 13.5 , $p < 0.001$) and reduction of NT-proBNP levels.

Conclusion: The findings of this real-world investigation suggest ARNI is associated with symptom improvements in patients with HFrEF. ARNI treatment is generally tolerated well and most common side effect is symptomatic hypotension.

ID: 248

Topic: Cardiology » Chronic Heart Failure

Presentation Type: Oral

WHAT CAN BE DONE TO PREVENT HYPOTENSION AND ACUTE RENAL FAILURE IN PATIENTS USING ARNI ?

Emrah Erdal, Mehmet Inanir

*Abant Izzet Baysal University Hospital, Bolu, Turkey***Corresponding Author (dr.emraherdal@gmail.com)**dr.emraherdal@gmail.com, mdmehmetinanir@yahoo.com***Abstract Text****OBJECTIVE**

Angiotensin receptor-neprilysin inhibitor (ARNI) has recently been used in the treatment of heart failure. Studies have shown that all causes of mortality, morbidity and hospitalization decrease in those who use this treatment. ARNI treatment is increasing in our country. But, there are side effects such as hypotension and kidney failure. The aim of this study is to determine the risk of hypotension and renal failure and what measures we can take.

METHODS

20 patients (3 female, 17 male participants) using sacubitril-valsartan were included in the study. Ejection fraction of patients was $< 35\%$. The mean age of the participants was 66.8 years. The mean duration of treatment was 15 days-9 months (mean: 5 months).

RESULTS

Symptomatic improvement and decrease in NYHA classification were observed in 19 patients. 1 patient did not benefit from the treatment. Hypotension developed in 6 patients. Acute renal failure occurred in 2 patients and the treatment was terminated. A slight reduction in renal function was observed in 3 patients. 1 patient died due to unknown reason. In 1 patient, nail disorder developed and adverse effect was reported. Patients with acute renal failure were followed up with chronic renal failure. Patients with hypotension were using spironolactone

and furosemide together. After the diuretic treatment dose was reduced, hypotension was stopped and treatment was continued.

CONCLUSIONS

ARNI treatment appears to improve symptoms in patients with heart failure. However, hypotension and acute renal failure may develop in patients using this treatment. Especially patients with chronic renal failure are at risk. Similarly, patients taking spironolactone and furosemide together are at increased risk of hypotension and acute renal failure. Therefore, ARNI should be used carefully in these patients and the diuretic dose should be reduced.

ID: 201

Topic: Cardiology » Chronic Heart Failure

Presentation Type: Oral

WHAT ARE THE EFFECTS OF SACUBUTRIL/VALSARTAN TREATMENT ON THE HEART FUNCTIONS? CAN IT INCREASE THE EJECTION FRACTION?

Tuğba Kemaloğlu Öz

Medipol University Çamlıca Hospitals , İstanbul, Turkey

**Corresponding Author (tugbakemalogluoz@gmail.com)*

tugbakemalogluoz@gmail.com

Abstract Text

OBJECTIVES: Heart failure (HF) currently affects at least 38 million people worldwide. The aims of HF treatment are to improve their symptoms, exercise capacity and quality of life, prevent hospitalization, and reduce cardiac and total mortality. It was thought that angiotensin receptor neprilysin inhibitors (ARNIs) could have potential to regulate favorably the neurohormonal imbalance that characterizes HF. The first generation ARNI, sacubutril/valsartan, is found more beneficial than enalapril for reducing sudden cardiac death, death from worsening HF, of hospitalization from HF (PARADIGM-HF). However, there is not any prospective echocardiographic data about the effect of sacubutril/valsartan on heart functions and reverse remodelling left ventricle. So, the aim of our study was the evaluate the effects of sacubutril/valsartan treatment on left ventricular (LV) functions using new echocardiographic technology including three dimensional echocardiography (3DE) and 3D strain parameters.

METHODS: The patients age ≥ 18 years who have indication to use sacubutril/valsartan as recommended in the ESC heart failure guideline recorded to our study. All patients underwent to two dimensional (2D) and three dimensional (3D) echocardiography (3DE) for evaluate the basal cardiac function before the start sacubutril/valsartan treatment. Patients who were eligible to continue to take maximum tolerated sacubutril/valsartan dose during follow up period underwent to second 2D and 3DE 3 months after study drug treatment.

RESULTS: A total of 100 patients (27% female), including 55 (55 % of total patients) in the ischemic HF group and 45 (45% of total patients) patients in the non-ischemic HF group who could continue to take maximal tolerated sacubutril/valsartan treatment during three months were enrolled the study. The mean age was 64.8 ± 14.1 and they were taken mean 248.0 ± 123.5 mg sacubutril/valsartan during 3 months therapy. Our findings revealed a significant decrease in end-diastolic and end-systolic dimensions, volumes, and volume indexes in both groups. Also, significant decreases were seen in LV mass and LV mass indexes, however, stroke volume, stroke volume index, and 2D and 3D EF were increased and all strain parameters improved after three months sacubutril/valsartan treatment in two groups. Additionally, there was not any significant difference in all echocardiographic parameters pre and post-treatment period between two groups.

CONCLUSIONS: To the best of our knowledge, this is the first prospective study to show the effects of sacubutril/valsartan treatment on LV functions using echocardiography. In patients with HF with reduced EF (ischemic or non-ischemic), sacubutril/valsartan significantly improved LV systolic functions and leads to reverse remodelling after 3 months treatment.

ID: 101

Topic: **Cardiology » Chronic Heart Failure**Presentation Type: **Oral**

COMPARISON OF ANGIOTENSIN CONVERTING ENZYME INHIBITOR (ACEI) AND ACEI PLUS ANGIOTENSIN RECEPTOR BLOCKER (ARB) COMBINATION THERAPY IN HEART FAILURE WITH ISCHEMIC ORIGIN

Ebru Ipek Turkoglu¹, Serdar Payzın²

¹*Kemalpasa State Hospital, İzmir, Turkey*

²*Ege University, İzmir, Turkey*

**Corresponding Author (dripek73@yahoo.com)*

dripek73@yahoo.com, dripek73@yahoo.com

Abstract Text

Background: Angiotensin converting enzyme inhibitors (ACEI) are well known for reducing the mortality in heart failure (HF). Although the knowledge of the beneficial effects of angiotensin converting enzyme inhibitor (ACEI) are dose dependent and these drugs should be used in doses with proven efficacy, many patients could not receive these dosages because of side effects like hypotension. Angiotensin receptor blockers (ARB) have showed no superiority to ACEI in HF but there are limited studies for comparison of high dose ACEI to low dose ACEI + ARB combination. In this study, we aimed to compare echocardiographic features of HF patients with ischemic origin between to treatment groups for 6 months.

Method: HF patients of ischemic origin and left ventricle ejection fraction (LVEF) < 35% with a functional class of 3-4 of NYHA have been studied. Patients have been divided into two treatment groups as high dose enalapril and low dose enalapril + losartan combination therapy and checked in every 3 months for a 6 month period with echocardiography. LVEF, LV end-diastolic diameter (LVED), LV end-diastolic volume (LVEDV) and LV mass index (LVMI) have been checked. 21 patients in enalapril arm and 18 patients in combination arm have completed the study.

Results: The demographics of 2 groups were statistically similar. Both groups did not show any statistically significant alteration on LVED, LVEDV and LVMI during the 6 months period. Initial LVEF did improve in both groups during the study period similarly. Hyperpotasemia was more in number in the combination arm but not statistically significant

Conclusion: This study has showed that, both enalapril and low dose combination therapy for the treatment of patients with HF of ischemic origin were with improved LVEF in the end of the study period. The few in number of patients and inadequate dosage of enalapril because of hypotension were the limiting factors, which kept us to make a sweeping statement

LVEF	Enalapril (n=23)	Low dose enalapril + losartan	p
1. LVEF (initial)	29.7+/-5.6%	27.2+/-4.8%	ns
2. LVEF (3. mo)	30.6+/-6.0%	32.1+/-4.8%	ns
3. LVEF (6. mo)	32.5+/-5.0%	33.6+/-6.4%	ns

ID: 25

Topic: **Cardiology » Dilated Cardiomyopathy**Presentation Type: **Oral****SEVERE FUNCTIONAL MITRAL REGURGITATION IS ASSOCIATED WITH INCREASED PULMONARY VASCULAR RESISTANCE IN HEART TRANSPLANT CANDIDATES****Cem Doğan***Kartal Koşuyolu Y.İ.E.A.H, istanbul, Turkey***Corresponding Author (cemcardio@hotmail.com)**cemcardio@hotmail.com***Abstract Text**

Objective: Because of the heterogeneity of previous studies, the effect of severe functional mitral regurgitation (FMR) on pulmonary vascular resistance (PVR) and other invasive haemodynamic parameters is still not well-defined in patients with advanced heart failure. Therefore we aimed to evaluate the association of FMR with invasive haemodynamic parameters in heart transplant candidates.

Methods: A total of 238 patients were included to study and were divided into two groups: 1) those with severe FMR; and 2) those with non-severe FMR.

Results: Seventy-six patients had severe FMR and 162 patients had non-severe or no FMR. The systolic and mean pulmonary arterial pressures and pulmonary artery wedge pressure (mmHg) were higher in the patients with severe FMR compared to those with non-severe FMR [58.5 (48.0-70.0) vs. 45.0 (36.0-64.0), $p<0.001$; 38.0 (30.2-46.6) vs. 31.0 (23.0-39.5), $p=0.004$; 25.0 (20.0-30.0) vs. 21.0 (14.0-27.0), $p<0.001$, respectively]. The patients with severe FMR had higher PVR (WU) values compared to those with non-severe FMR [4.0 (2.3-6.8) vs. 2.6 (1.2-4.3), $p=0.001$, respectively]. Severe FMR was a significant predictor of increased rates of pulmonary hypertension, combined pre- and post-capillary pulmonary hypertension, $PVR \geq 3$ and $PVR \geq 5$ WU [OR: 2.65, 95% CI (1.2-5.7), $p=0.0116$; OR: 2.3, 95% CI (1.3-4.2), $p=0.0025$; OR: 2.0, 95% CI (1.1-3.6), $p=0.0097$; and OR: 3.2, 95% CI (1.5-6.7), $p=0.0015$, respectively].

Conclusion: The patients with severe FMR had higher pulmonary arterial pressures and PVR values than those with non-severe FMR. Therefore, the presence of severe FMR seems to be an unfavourable risk factor for PVR in heart transplant candidates.

ID: 419

Topic: **Cardiology » Chronic Heart Failure**Presentation Type: **Oral****THE PREVALENCE OF BONE TISSUE METABOLISM DISORDERS IN PATIENTS IN EARLY PERIOD AFTER HEART TRANSPLANTATION**Volha Sujayeva¹, Ema Rudenka², Larisa Rachok¹, Olga Koshlataja¹, Alesia Vavilova¹, **Ganna Kravchenko¹**¹*State Institution «Republican Scientific and Practical Centre “Cardiology”, Minsk, Belarus*²*Belarusian State Medical University, Minsk, Belarus***Corresponding Author (sujayeva@bk.ru)**sujayeva@bk.ru, a.kravchenko2312@gmail.com, a.kravchenko2312@gmail.com, koshlataja.olga@gmail.com, a.kravchenko2312@gmail.com, a.kravchenko2312@gmail.com***Abstract Text**

BACKGROUND: Heart transplantation is common treatment method for patients with end-stage heart failure. Prevention of rejection requires life-long immunosuppressive therapy, which causes a number of side effects – such as an increased fracture risk. Common knowledge FRAX scale is an approved algorithm to estimate the 10-year probability of osteoporotic fracture. However, the pathogenesis of osteoporosis in patients after heart transplantation puts in question the application of FRAX scale in this case.

METHODS: The study included 19 patients (mean age 54±9.4 years, 17 men and 2 women) after heart transplantation (mean term 6.55±5.8 months). We used FRAX scale without BMD (bone mineral density) in all patients for estimation the osteoporotic fracture risk. FRAX data was rated on nomogram recommended by The National Osteoporosis Guideline Group (NOGG). As a result of the assessment, a high, medium and low risk of osteoporotic fractures could be identified. After that, we used morphometry of the lumbar-thoracic spine in lateral projection to verify bone tissue metabolism disorders.

RESULTS: According to data of FRAX scale without BMD the 10-year probability of osteoporotic fracture was 3.74±1.31% and 0.74±0.4% for hip fracture. After evaluating the data using nomogram, we have found that all patients had a low 10-year probability of osteoporotic fracture. However the morphometry of the lumbar-thoracic spine revealed wedge deformities in the thoracic vertebrae in 4 (21.05%) patients. Thus, despite the low probability of osteoporotic fractures according to the data of FRAX scale, every fifth patient in the early period after heart transplantation had pronounced asymptomatic disorders of bone tissue metabolism. Therefore, a prevention method for these complications should be developed and implemented.

CONCLUSIONS: The prevalence of bone tissue metabolism disorders in patients in the early period after heart transplantation is significantly higher than their probability on the FRAX scale.

ID: 78

Topic: Cardiology » Diabetes Mellitus and Cardiovascular Disease

Presentation Type: Oral

HIGH BURDEN OF DIABETES MELLITUS IN PATIENTS WITH HEART FAILURE WITH MID-RANGE AND PRESERVED EJECTION FRACTION

Bülent Özlek, Eda Özlek

Mugla Sitki Kocman University Training and Research Hospital, Mugla, Turkey

*Corresponding Author (bulent_ozlek@hotmail.com)

bulent_ozlek@hotmail.com, demircioglueda@hotmail.com

Abstract Text

Objectives: Prevalence of heart failure (HF) in diabetes is very high, and the prognosis for patients with HF is worse in those with diabetes than in those without diabetes. Therefore, we aimed to examine the effect of diabetes on the clinical characteristics and etiology in a large Turkish cohort of patients with heart failure with mid-range (HFmrEF) and preserved ejection fraction (HFpEF).

Methods: This is a multicenter, observational and cross-sectional study conducted in 7 regions of Turkey. Consecutive patients admitted to the outpatient cardiology clinics who had HFmrEF or HFpEF were included (NCT03026114). Patients were classified into two groups as diabetics and nondiabetics. We performed a post-hoc analysis of data from this large, comprehensive study.

Results: The study comprised 1065 (mean age of 67.1±10.6 years, 54% women) HFmrEF and HFpEF patients from 11 sites in Turkey. Among participants, 319 (30%) were diabetic and 746 (70%) were nondiabetic. Diabetic patients had higher prevalence of orthopnea (36.1 vs 28.2%, p=0.011), reduced exercise tolerance (86.5 vs 80.8%, p=0.025), chest pain (31 vs 23.5%, p=0.01), and pulmonary crepitations (27.9 vs 19.6%, p=0.003). **Figure 1** shows the distribution of comorbidities in two groups. Compared to nondiabetic patients, those with diabetic patients had also higher prevalence of hypertension (83.4 vs 73.1%, p<0.001), anemia (6.6 vs 2.4%, p=0.001), chronic kidney disease (19.7 vs 9.2%, p<0.001), obstructive sleep apnea (8.2 vs 4.7%, 0.026), hyperlipidemia (41.7 vs 17.6%, p<0.001), coronary (53.6 vs 35.8%, p<0.001) and peripheral artery disease (4.7 vs 1.7%, p=0.006). However, prevalence of atrial fibrillation was higher in a nondiabetic group (39.1 vs 27.9%, p<0.001). Diabetic patients were also differed from nondiabetics for having a worse diastolic function (grade 3 diastolic dysfunction was 32.6 vs 25.3%, respectively; p=0.019). The leading etiologic factor of HF was ischemic heart disease in diabetic group (41.1 vs 26.7%, p<0.001), and the most common cause of HF was atrial fibrillation in nondiabetic group (31.2 vs 19.4%, p<0.001).

Conclusions: The present study supports that diabetic patients are more symptomatic and have more burden of comorbidities in a large Turkish population of HFmrEF and HFpEF. This registry provides a comprehensive contribution to analyze the effect of diabetes in this patient group.

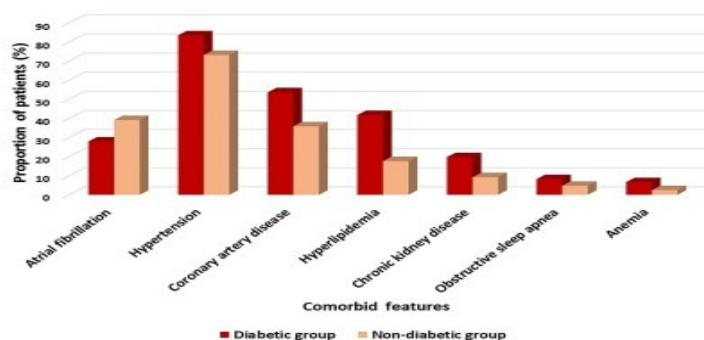


Figure 1: Comorbid features of patients with diabetic vs nondiabetic

Oral Presentation

Echocardiographic Findings in Patients With Chronic Kidney Diseases

Date: 28.03.2019 Time: 17:00 - 18:30 Hall: 5

ID: 457

Topic: **Cardiology » Cardiac Imaging - Echocardiography**

Presentation Type: **Oral**

RIGHT AND LEFT VENTRICLE MECHANICAL DISPERSION IN END-STAGE RENAL DISEASE PATIENTS: DOES HEMODIALYSIS HAVE ACUTE EFFECT ON THIS NEW PARAMETER?

Nurten Sayar, Beste Özben Sadıç, Mustafa Kürşat Tigen, Hasan Özdil, Yusuf Emre Gürel, Altuğ Çinçin, Ahmet Anıl Şahin, Arzu Velioglu, Murat Sünbül

Marmara University School of Medicine , İstanbul , Turkey

**Corresponding Author (sayarnurten@gmail.com)*

sayarnurten@gmail.com, besteozben@yahoo.com, mktigen@yahoo.com, terslale87@hotmail.com, emregurelctf@yahoo.com, acincin@yahoo.com, aanilsahin@hotmail.com, arzuvelioglu@gmail.com, drsunbul@yahoo.com.tr

Abstract Text

Objective: Mechanical dispersion (MD) is a new parameter for the assessment of dyssynchrony of the ventricles. Increased MD is associated with arrhythmic events . ESRD patients have higher mortality and arrhythmic events with respect to controls. Also acute volume changes during dialysis may cause ventricular dyssynchrony due to electrolyte shifts. In this study we compared the mechanical dispersion of right and left ventricles in ESRD patients with healthy controls as well as pre and post hemodialysis.

Methods: Thirty hemodialysis patients (15 female) with a mean age of 55.1±14.2 years and 29 healthy controls (mean age: 36.5 ± 13.4 years) were included in the study. Patients with a history of myocardial infarction, pulmonary emboli, echocardiographically detected LVEF < 50 % and significant valvular disease were excluded from the study. Conventional echocardiography and 2D speckle-tracking measurements were done before and immediately after dialysis. Mechanical dispersion is the standard deviation of time to peak strain of different myocardial segments. For right ventricle (RV) it is six segment and designated as RVSD6 and here in this study for left ventricle we studied only apical four chamber view so designated as LVSD6.

Results: The LVSD6 values for controls, and ESRD patients during pre and post dialysis time period were as follows, respectively : 35.1 ± 16.1 msec vs 66.7 ±26.8 msec vs 70.7 ±23.9 msec. For the RVSD6 values the MD parameters for controls and ESRD patients during pre and post dialysis time period were 33.3 ± 19.0 msec vs 77.4 ±40.4 msec vs and 90.6 ±51.2msec, respectively. With respect to healthy controls, both LV and RV mechanical dispersion is increased. Biventricular mechanical dispersion did not change significantly immediately after dialysis in ESRD patients. There is an inverse correlation between RVSD6 pre- dialysis and RV global longitudinal strain values ($r = -0.3$, $p = 0.028$) but not with post-dialysis RVSD6 or LVSD6.

Conclusion: This is the first study in the literature studying mechanical dispersion in ESRD patients. There is no acute effect of hemodialysis on biventricular dyssynchrony but increased with respect to controls. Right ventricle dyssynchrony increased with reduced RV global longitudinal strain values in ESRD patients.

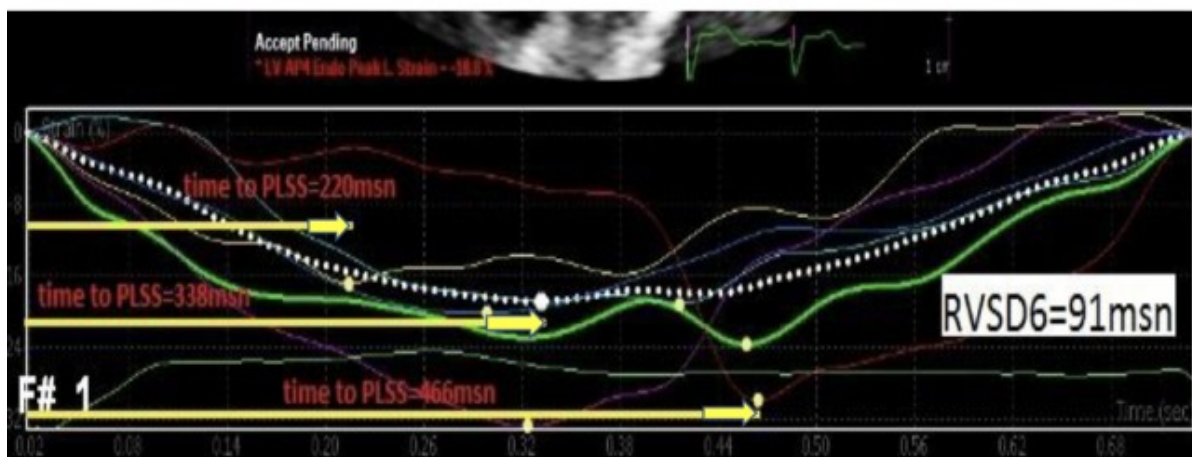
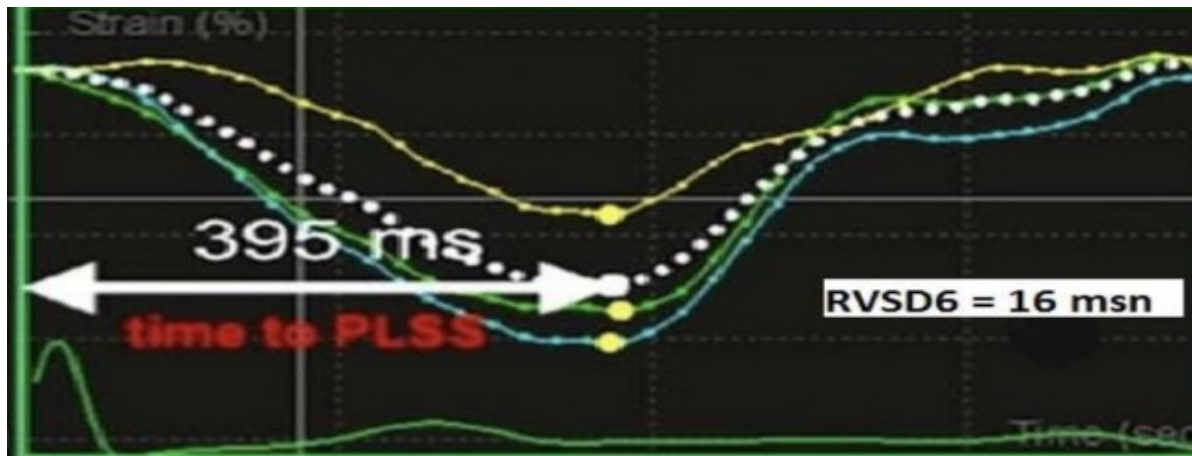
	Predialysis (n= 30)	Postdialysis (n= 30)	Controls (n= 29)	P1	P2	P3
Age (years)	55.1 ± 14.2		36.5 ± 13.4		<0.001	
Male sex (n-%)	15 (50%)		9 (31%)		0.138	
LVSD6 (msn)	66.7 ±26.8	70.7 ±23.9	35.1 ± 16.1	0.55	<0.001	<0.001
RVSD6 (msn)	77.4 ±40.4	90.6 ±51.2	33.3 ± 19.0	0.41	<0.001	<0.001
LV-GLS (%)	-14.1 ±2.6	-14.0 ±3.3	-18.0 ±2.5	0.99	<0.001	<0.001
RV-GLS (%)	-16.6 ± 3.7	-14.4 ± 3.5	20.3 ± 2.6	0.010	<0.001	<0.001

LVSD6: Left ventricle six segment mechanical dispersion; RVSD6: Right ventricle six-segment mechanical dispersion; GLS: global longitudinal strain |

P1: comparison between predialysis and postdialysis

P2: comparison between predialysis and controls

P3 comparison between postdialysis and controls



ID: 466

Topic: **Cardiology » Cardiac Imaging - Echocardiography**Presentation Type: **Oral****EVALUATION OF ACUTE EFFECT OF HEMODIALYSIS ON RIGHT VENTRICLE FUNCTION BY TWO-DIMENSIONAL SPECKLE- TRACKING ECHOCARDIOGRAPHY**

Nurten Sayar, Beste Özben Sadıç, Ahmet Anıl Şahin , Hasan Özdil, Murat Sünbül, Altuğ Çinçin, Yusuf Emre Gürel, Mustafa Kürşat Tigen, Arzu Veliöglu

Marmara university School of Medicine , İstanbul , Turkey

**Corresponding Author (sayarnurten@gmail.com)*

*sayarnurten@gmail.com, besteozben@yahoo.com, aanilsahin@hotmail.com, terslale87@hotmail.com,
drsunbul@yahoo.com.tr, acincin@yahoo.com, emregurelctf@yahoo.com, mktigen@yahoo.com,
arzuvelioglu@gmail.com*

Abstract Text

Objective: Cardiovascular mortality is nine times higher in dialysis patients. Right ventricle is physiologically more vulnerable to acute volume and pressure loads compared to left ventricle. Acute volume shifts during dialysis may have subtle effects on right ventricular (RV) mechanical functions. In this study we investigated the acute effects of hemodialysis on RV function assessed by two-dimensional speckle-tracking echocardiography.

Method: Thirty hemodialysis patients (15 female) with a mean age of 55.1±14.2 were included in the study. Patients with a history of myocardial infarction, pulmonary emboli ,echocardiographically detected LVEF< 50 % and significant valvular disease were excluded from the study. Both vital signs and echocardiographic parameters were measured before and immediately after hemodialysis.

Results: The average fluid removal after dialysis was 2520±1133 ml. Systolic blood pressure declined significantly immediately after dialysis (148.8±28.8 mmHg vs 124.9±27.9 mmHg, p<0.001) whereas there were no difference in heart rate (79±12 beats/min vs 81±13 beats/min, p= 0.42) and diastolic blood pressure (84.5±13.7 mmHg vs 78.7± 19.9 mmHg p=0.09). TAPSE (23.1±7.1 vs 20.3±6.3, p=0.046) and tricuspid annular velocity s'(13.1 ±3.3 cm/sec vs 11.9 ± 3.3 cm/sec, p=0.021) and inferior vena cava diameter (14.8±4.6 vs 11.8±4.6, p<0.001) decreased significantly after dialysis. RV global longitudinal strain also dramatically decreased (-16.48±5.82 vs -14.35±3.57, p=0.01) post-dialysis (Table 1).

Conclusions: Dialysis deteriorates RV function immediately after dialysis. Careful patient monitoring is needed, especially in patients with LV failure where RV function is utmost importance.

	Predialysis (n= 30)	Postdialysis (n= 30)	p
Systolic blood pressure (mmHg)	148.8 ± 28.9	124.9 ± 27.9	<0.001
Diastolic blood pressure (mmHg)	84.5 ± 13.7	78.7 ± 19.9	0.09
Heart rate (/min)	79 ± 12	81 ± 13	0.42
RA area (cm²)	16.7 ± 5.5	15.6 ± 7.1	0.223
PA VTI (cm)	21.6 ± 4.7	18.8 ± 6.4	0.002
RV diameter (mm)	30.6 ± 7.1	31.9 ± 9.0	0.212
RVOT diastolic diameter (mm)	31.0 ± 6.7	31.4 ± 6.7	0.727
RVOT systolic diameter (mm)	15.1 ± 7.8	18.9 ± 8.7	0.011
RVOT-fractional shortening (%)	52.2 ± 20.9	41.7 ± 20.0	0.017
RV enddiastolic area (cm²)	15.6 ± 5.0	15.8 ± 6.0	0.761
RV endsystolic area (cm²)	8.2 ± 2.8	8.4 ± 5.0	0.891
Fractional area change (%)	46.5 ± 9.1	49.2 ± 12.2	0.383
TAPSE (mm)	23.0 ± 7.1	20.35 ± 6.3	0.046
RV e' (cm/sn)	9.4 ± 2.9	8.1 ± 3.3	0.093
RV a' (cm/sn)	15.8 ± 5.6	14.7 ± 4.3	0.331
RV s' (cm/sn)	13.1 ± 3.3	11.9 ± 3.3	0.021
RV myocardial performance index	0.7 ± 0.2	0.6 ± 0.2	0.093
Inferior vena cava max (mm)	14.8 ± 4.6	11.8 ± 4.6	<0.01
RV-GLS (%)	-16.48 ± 3.76	-14.35 ± 3.57	0.010

RA: right atrium; PA: pulmonary artery; VTI: velocity time integral; RV: right ventricle; RVOT: right ventricular outflow track; TAPSE: tricuspid annular plane systolic excursion; GLS: global longitudinal strain

ID: 482

Topic: **Cardiology » Cardiac Imaging - Echocardiography**Presentation Type: **Oral****EVALUATION OF ACUTE EFFECT OF HEMODIALYSIS ON BIATRIAL FUNCTIONS IN END-STAGE RENAL DISEASE PATIENTS ASSESSED BY TWO-DIMENSIONAL SPECKLE-TRACKING ECHOCARDIOGRAPHY****Nurten Sayar, Beste Özben Sadıç, Altuğ Çinçin, Murat Sünbül, Yusuf Emre Gürel, Hasan Özdil, Mustafa Kürşat Tigen, Ahmet Anıl Şahin, Arzu Velioglu***Marmara University School of Medicine , İstanbul, Turkey***Corresponding Author (sayarnurten@gmail.com)**sayarnurten@gmail.com, besteozben@yahoo.com, acincin@yahoo.com, drsunbul@yahoo.com.tr, emregurelctf@yahoo.com, terslale87@hotmail.com, mktigen@yahoo.com, aanilsahin@hotmail.com, arzuvelioglu@gmail.com***Abstract Text**

Objective: With the advance of speckle-tracking echocardiography, not only volumes but also phasic functions of atria can be studied. Decreased left atrial functions are associated with cardiovascular mortality in different cardiac populations including end-stage renal disease patients whereas little is known about the clinical significance of right atrial functions. Also we do not know the acute effect of hemodialysis on bi-atrial functions in this special population. In this study we compared right and left atrial peak longitudinal and conduit strain values with healthy controls. Also studied whether acute volume removal has any acute effect on atrial phasic functions.

Method: Thirty hemodialysis patients (15 female) with a mean age of 55.1 ± 14.2 and 29 healthy controls with a mean age of 36.5 ± 13.4 were included in the study. Patients with a history of myocardial infarction, pulmonary emboli , echocardiographically detected LVEF<50 % and significant valvular disease were excluded from the study. Echocardiographic measurements were performed before and immediately after hemodialysis.

Results: The right atrial peak longitudinal strain (PLS) values are as follows: control $39.2 \pm 9.8\%$, predialysis $27.2 \pm 10.4\%$ and post-dialysis $23.8 \pm 9.7\%$. RA-PLS is significantly impaired in ESRD patients but there is no change before and after the dialysis. The left atrial PLS values are as follows: controls: $41.1 \pm 12.2\%$, pre-dialysis: $25.7 \pm 14.6\%$, post-dialysis $21.6 \pm 10.9\%$. Like in RA-PLS, LA-PLS is significantly impaired in ESRD patients but there is no change before and after the dialysis. Biatrial conduit functions are also listed in Table 1.

	Predialysis (n= 30)	Postdialysis (n= 30)	Controls (n= 29)	P1	P2	P3
Age (years)	55.1 ± 14.2		36.5 ± 13.4		<0.001	
Male sex (n- %)	15 (50%)		9 (31%)		0.138	
RA-PLS strain (%)	27.2 ± 10.4	23.8 ± 9.7	39.2 ± 9.8	0.391	<0.001	<0.001
RA- conduit (%)	12.5 ± 7.7	10.5 ± 5.6	13.1 ± 5.1	0.343	0.384	0.045
RV-GLS (%)	-16.6 ± 3.7	-14.4 ± 3.5	20.3 ± 2.6	0.010	<0.001	<0.001
LA-PLS strain (%)	25.7 ± 14.6	21.6 ± 10.9	41.1 ± 12.2	0.285	<0.001	<0.001
LA- conduit (%)	14.1 ± 1.3	11.4 ± 0.9	14.6 ± 4.7	0.475	0.103	0.004
LV-GLS (%)	-14.1 ± 2.6	-14.0 ± 3.3	-18.0 ± 2.5	0.99	<0.001	<0.001

RA: Right atrial; LA: Left atrial; PLS: Peak longitudinal strain; GLS: Global longitudinal strain

P1: comparison between predialysis and postdialysis

P2: comparison between predialysis and controls

P3: comparison between postdialysis and controls

Conclusions: Although biatrial phasic functions assessed by 2D speckle-tracking echocardiography are decreased in ESRD patients, there is no acute effect of hemodialysis on these indices.

ID: 401

Topic: **Cardiology** » **Cardiac Imaging - Echocardiography**

Presentation Type: **Oral**

A NEW PARAMETER FOR THE ASSESSMENT OF RIGHT VENTRICLE ARTERIO-VENTRICULAR COUPLING IN CHRONIC HEMODIALYSIS PATIENTS: TAPSE/SPAP RATIO

Nurten Sayar, Beste Özben Sadıç, Hasan Özdil , Yusuf Emre Gürel , Murat Sünbül, Altuğ Çınçın , Ahmet Anıl Şahin , Arzu Velioglu, Mustafa Kürşat Tigen

Marmara University School of Medicine, Istanbul, Turkey

**Corresponding Author (sayarnurten@gmail.com)*

sayarnurten@gmail.com, besteozben@yahoo.com, terslale87@hotmail.com, emregurelctf@yahoo.com, drsunbul@yahoo.com.tr, acincin@yahoo.com, aanilsahin@hotmail.com, arzuveliolglu@gmail.com, mktigen@yahoo.com

Abstract Text**Objective:**

The ratio of echocardiography-derived tricuspid annular plane systolic excursion (TAPSE) and pulmonary arterial systolic pressure (PASP) (TAPSE/PASP) has been described as an index of in vivo RV shortening in the longitudinal axis versus developed force in patients with heart failure and was introduced as a non-invasive, indirect measurement of RV contractile function and RV-pulmonary arterial (PA) coupling. It has been shown that the lower the ratio, the poorer the survival in heart failure and idiopathic pulmonary hypertension patients. This new parameter has not been evaluated in detail in patients with end-stage renal dialysis patients. Also we do not know whether TAPSE/PASP will change during hemodialysis which is a good model for acute volume shifts. In this study we studied this new parameter in ESRD patients with respect to controls and also pre and post dialysis changes.

Methods: Thirty hemodialysis patients (15 female) with a mean age of 55.1 ± 14.2 and 29 healthy controls with a mean age of 36.5 ± 13.4 were included in the study. Patients with a history of myocardial infarction, pulmonary emboli, echocardiographically detected LVEF < 50 % and significant valvular disease were excluded from the study. Both vital signs and echocardiographic measurements were done before and immediately after hemodialysis.

Results: The TAPSE/SPAP was significantly higher in healthy controls compared to pre and post-dialysis values in patients with ESRD (control: 1.31 ± 0.41 mm/mmHg vs pre-dialysis: 0.80 ± 0.39 mm/mmHg vs post-dialysis: 0.65 ± 0.30 mm/mmHg). Right ventricle global longitudinal strain values also decreased significantly compared to controls as well as pre and post-dialysis (control: $-20.3 \pm 2.6\%$ vs pre-dialysis: $-16.6 \pm 3.7\%$ vs post-dialysis: $-14.4 \pm 3.5\%$). There is a significant correlation between TAPSE/SPAB and RV GLS ($r = 0.33$, $p = 0.023$) whereas no correlation between other echocardiographic RV indices such as: RV fractional area change or TDI of tricuspid annulus s' velocity or myocardial performance index .

	Predialysis (n= 30)	Postdialysis (n= 30)	Controls (n= 29)	P1	P2	P3
Age (years)	55.1 ± 14.2		36.5 ± 13.4		<0.001	
Male sex (n- %)	15 (50%)		9 (31%)		0.138	
TAPSE/sPAP (mm/mmHg)	0.80 ± 0.39	0.65 ± 0.30	1.31 ± 0.41	0.016	<0.001	<0.001
RV-GLS (%)	-16.6 ± 3.7	-14.4 ± 3.5	-20.3 ± 2.6	0.010	<0.001	<0.001

TAPSE: Tricuspid annular plane systolic excursion; sPAP: Systolic pulmonary artery pressure

RV-GLS: Right ventricle global longitudinal strain |

P1: comparison between predialysis and postdialysis

P2: comparison between predialysis and controls

P3: comparison between postdialysis and controls

Conclusion:

TAPSE/PASP ratio is an easily measured parameter which has shown to be an independent predictor of survival in heart failure and pulmonary hypertension patients. We found that this ratio is reduced in ESRD patients compared to healthy controls and interestingly it can reflect acute RV contractility changes together with GLS measurement assessed by 2D speckle-tracking echocardiography.

ID: 448

Topic: **Cardiology » Cardiac Imaging - Echocardiography**Presentation Type: **Oral****THE ACUTE EFFECT OF HEMODIALYSIS ON PLASMA NT-PRO BNP LEVELS IN PATIENTS WITH END-STAGE RENAL DISEASE**

Nurten Sayar, Beste Özben Sadiç, Hasan Özdil, Murat Sünbül, Altuğ Çinçin, Yusuf Emre Gürel, Ahmet Anıl Şahin , Mustafa Kürşat Tigen, Arzu Veliöglu

Marmara University School of Medicine, İstanbul, Turkey

**Corresponding Author (sayarnurten@gmail.com)*

sayarnurten@gmail.com, besteozben@yahoo.com, terslale87@hotmail.com, drsunbul@yahoo.com.tr, acincin@yahoo.com, emregurelctf@yahoo.com, aanilsahin@hotmail.com, mktigen@yahoo.com, arzuvelioglu@gmail.com

Abstract Text

Objective: Natriuretic peptide is considered as a marker of cardio-renal syndrome. It is also a useful marker of fluid overload in hemodialysis patients. It is well known that dialysis decrease plasma natriuretic levels, chronically. In this study we investigated the acute effect of hemodialysis on plasma NT-pro BNP level in end-stage renal disease patients.

Method:Thirty hemodialysis patients (15 female) with a mean age of 55.1±14.2 were included in the study. Patients with a history of myocardial infarction, pulmonary emboli ,echocardiographically detected LVEF < 50 % and significant valvular disease were excluded from the study. Plasma samples for NT-pro BNP level assessment were taken before and immediately after hemodialysis as well as 2D conventional echocardiographic and speckle-tracking measurements.

Results: The average fluid removal after dialysis was 2520±1133 ml. Both left and right atrial volume indexes decreased significantly after dialysis, respectively (LAVI: 33.60 ± 14.95 ml /m² vs 25.62 ± 10.68 ml /m², p=0.003 and RAVI:37.41 ml /m² ± 19.68 vs 31.28 ± 17.63 ml /m², p=0.017). Also the mitral E/e' decreased (13.13 ±12.31 vs 10.32 ±7.94, p= 0.012) but hemodialysis did not change right ventricle systolic and diastolic areas significantly. Interestingly, plasma level of NT- pro BNP level increased significantly immediately after dialysis from 15000 ±14027 pg/ml to 16347 ± 13731 pg/ml , (p<0.004 Table 1). In addition; predialysis NT- pro BNP levels were significantly correlated with predialysis right ventricular global longitudinal strain values (r= - 0.353 p= 0.012).

Table 1: Comparison of NT-pro BNP levels and echocardiographic variables before and after hemodialysis

	Predialysis (n= 30)	Postdialysis (n= 30)	p
Systolic blood pressure (mmHg)	148.8 ± 28.9	124.9 ± 27.9	<0.001
Diastolic blood pressure (mmHg)	84.5 ± 13.7	78.7 ± 19.9	0.09
Heart rate (/min)	79 ± 12	81 ± 13	0.42
NT-pro BNP (pg/mL)	15000 ± 14027	16347 ± 13731	0.004
Left atrial area (cm²)	18.36 ±4.97	15.76 ±4.17	0.011
LAVI (mL/m²)	33.60 ± 14.95	25.62 ± 10.68	0.003
RAVI (mL/m²)	37.41 ± 19.68	31.28 ± 17.63	0.017
Mitral E (cm/s)	91.42 ±43.57	74.07 ±40.91	0.003
Mitral A (cm/s)	94.35 ±29.60	88.89 ±23.04	0.284
Deceleratin time (msn)	141.28 ± 37.63	142.76 ± 40.14	0.861
Mitral lateral e' (cm/s)	7.97 ± 3.07	7.82 ± 2.49	0.712
Mitral lateral a' (cm/s)	11.82 ±3.88	10.14 ±3.00	0.005
Mitral lateral s' (cm/s)	7.64 ±1.77	7.53 ± 1.78	0.761
Mitral E/A	1.07 ± 0.72	0.83 ± 0.35	0.021
Mitral E/e'	13.13 ±12.31	10.32 ±7.94	0.012
RVEDA (cm²)	15.56±15.78	15.78±5.97	0.761
RVESA (cm²)	8.25±2.84	8.36±5.01	0.891

LAVI: Left atrial volume index; RAVI: Right atrial volume index; RVEDA: Right ventricle end-diastolic area; RVESA: Right ventricle end-systolic area

Conclusion: The acute effect of volume shift during dialysis may have detrimental effects on ventricular loading conditions. Careful monitoring is mandatory in this high risk patients.

ID: 400

Topic: Cardiology » Cardiac Imaging - Echocardiography

Presentation Type: Oral

THE ACUTE EFFECT OF HEMODIALYSIS ON PLASMA HS- TROPONIN T LEVELS IN END-STAGE RENAL DISEASE PATIENTS

Nurten Sayar, Beste Özben Sadıç, Altuğ Çinçin, Murat Sünbül, Yusuf Emre Gürel, Ahmet Anıl Şahin, Hasan Özdil, Mustafa Kürşat Tigen, Arzu Velioglu

Marmara University School of Medicine, İstanbul, Turkey

*Corresponding Author (sayarnurten@gmail.com)

sayarnurten@gmail.com, besteozben@yahoo.com, acincin@yahoo.com, drsunbul@yahoo.com.tr, emregurelctf@yahoo.com, aanilsahin@hotmail.com, terslale87@hotmail.com, mktigen@yahoo.com, arzuvelioglu@gmail.com

Abstract Text

Objective: The majority of patients with end-stage renal disease (ESRD) have chronically elevated concentrations of troponin levels. This increase can partially be explained by impaired excretion as majority of patients with ESRD have concomitant coronary artery disease and valvular heart disease. The acute effect of hemodialysis on plasma concentration of troponin can not be explained by decreased renal secretion but more of a cardiac insult. In this study we investigated the acute effect of hemodialysis on plasma hs-Troponin T levels in ESRD patients.

Method:Thirty hemodialysis patients (15 female) with a mean age of 55.1±14.2 were included in the study. Patients with a history of myocardial infarction, pulmonary emboli, echocardiographically detected LVEF < 50 % and significant valvular disease were excluded from the study. Plasma samples for hs- Troponin T level assessment were taken before and immediately after hemodialysis as well as 2D conventional echocardiography and speckle-tracking measurements.

Results: The plasma level of hs-Troponin T level increases significantly from pre-dialysis value of 97.43 ± 92.08 ng/L to post-dialysis value of 111.15 ± 100.01 ng/L, p=0.001. Right ventricle global longitudinal strain (GLS) decreased significantly immediately after hemodialysis (-16.48 ± 3.76 vs -14.35 ± 3.57, p=0.010), whereas left ventricular GLS change remained insignificant (Table 1). These changes can not be explained by increased inflammation as C-reactive protein levels did not change significantly post-dialysis. In addition, predialysis hs-Troponin T level was significantly correlated with predialysis right ventricular global longitudinal strain (r= - 0.517 p<0.001).

Table 1. Comparison of plasma hs-Troponin T Levels and 2D Global Longitudinal Strain (GLS) | Values of Right and Left Ventricle Before and After Hemodialysis

	Predialysis (n= 30)	Postdialysis (n= 30)	p
Systolic blood pressure (mmHg)	148.8 ± 28.9	124.9 ± 27.9	<0.001
Diastolic blood pressure (mmHg)	84.5 ± 13.7	78.7 ± 19.9	0.09
Heart rate (min)	79 ± 12	81 ± 13	0.42
hs-Troponin T (ng/L)	97.43 ± 92.08	111.15 ± 100.01	0.001
hs-CRP(mg/L)	21.40±25.75	22.18±25.12	0.49
LV-GLS (%)	-14.03 ±2.67	-14.02 ±3.30	0.99
RV-GLS (%)	-16.48 ± 3.76	-14.35 ± 3.57	0.010

Conclusion: Plasma hs-Troponin T levels increase significantly during hemodialysis in patients with ESRD, which may have a detrimental effect on survival. Future studies are needed to investigate the role of acute post-dialysis Troponin level increase in cardiovascular outcomes in this high risk population.

ID: 147

Topic: **Cardiology » Cardiac Imaging - Echocardiography**Presentation Type: **Oral****EVALUATION OF ACUTE EFFECT OF HEMODIALYSIS ON RIGHT VENTRICLE FUNCTION BY TWO-DIMENSIONAL SPECKLE-TRACKING ECHOCARDIOGRAPHY****Hasan Özdil**, Yusuf Emre Gürel, Murat Sünbül, Altuğ Çinçin, Ahmet Anıl Şahin, Beste Özben Sadıç, Mustafa Kürşat Tigen, Nurten Sayar*Marmara University School of Medicine, Istanbul, Turkey***Corresponding Author (terslale87@hotmail.com)**terslale87@hotmail.com, emregurelctf@yahoo.com, drsunbul@yahoo.com.tr, acincin@yahoo.com, aanilsahin@hotmail.com, besteozben@yahoo.com, mktigen@yahoo.com, sayarnurten@gmail.com***Abstract Text**

Objective: Cardiovascular mortality is nine times higher in dialysis patients. Acute effects of volume shift during dialysis may have subtle effects on right ventricular (RV) mechanical functions. In this study we investigated the acute effects of hemodialysis on RV functions assessed by two-dimensional speckle-tracking echocardiography.

Method: Thirty hemodialysis patients (15 female) with a mean age of 55.1±14.2 were included in the study. Patients with a history of myocardial infarction, pulmonary emboli ,echocardiographically detected LVEF<50 % and significant valvular disease were excluded from the study. Both vital signs and echocardiographic studies were done before and immediately after hemodialysis in the same day.

Results: The average fluid drainage after diaysis was 2520±1133 ml. Systolic blood pressure declined significantly immediately after dialysis (148.8±28.8 mmHg vs 124.9±27.9 mmHg, p<0.001) wheras there were no difference in heart rate (79±12 beats/min vs 81±13 beats/min, p=0.42) and diastolic blood pressure (84.5±13.7 mmHg vs 78.7± 19.9 mmHg p=0.09). TAPSE (23.1±7.1 vs 20.3±6.3, p=0.046) and tricuspid annular velocities (13.1±3.3 vs 11.9±3.3, p=0.021), inferior vena cava diameter (14.8±4.6 vs 11.8±4.6, p<0.001) decreased significantly after dialysis. RV global longitudinal strain values dramatically decreased (-16.48±5.82 vs -14.35±3.57, p=0.01)

Conclusions: Dialysis deteriorates RV function immediately after dialysis. Careful patient monitoring is needed, especially in patients with LV failure where RV function is utmost importance.

ID: 161

Topic: **Cardiology » Preventive Cardiology**Presentation Type: **Oral****EARLY DETECTION OF SUBCLINICAL UREMIC CARDIOMYOPATHY USING TWO-DIMENSIONAL SPECKLE TRACKING ECHOCARDIOGRAPHY**

Batur G. Kanar*Marmara university, İstanbul, Turkey***Corresponding Author (baturkanar@hotmail.com)**baturkanar@hotmail.com***Abstract Text**

Purpose: Cardiovascular disease (CVD) is highly prevalent in the setting of chronic kidney disease (CKD). Such coexistence of CVD and CKD—the so-called “cardiorenal or renocardiac syndrome”—contributes to exponentially increased risk of cardiovascular (CV) mortality. Uremic cardiomyopathy is a characteristic cardiac pathology commonly found in CKD. The aim of this study is to evaluate left ventricular (LV) systolic and diastolic dysfunction in patients with various stages of CKD using conventional, tissue Doppler and speckle tracking echocardiography (STE).

Methods: Sixty-four CKD patients, aged 52.5 ± 15 years old, were enrolled in the study. Patients were divided into 3 groups depending on their estimated glomerular filtration rate (eGFR). Group 1 (≥ 60 mL/min per 1.73 m²), group 2 (≤ 60 mL/min per 1.73 m²), and group 3 (≤ 60 mL/min per 1.73 m² and on regular dialysis for at least 12 months). Pulsed-Doppler and tissue Doppler studies were used to estimate LV filling pressure E/e'. Using 2DSTE, longitudinal, circumferential, and radial functions of the LV have been measured.

Results: The three groups did not differ with regard to age, sex, body mass index, and metabolic profile, while there were significant differences in hemoglobin level, blood pressures, and eGFR (Table 1). The conventional echocardiography and STE measurements were shown in Table 1. The three groups did not differ with regard to LV radial and circumferential strain, while there was a statistically significant difference in LV longitudinal strain. Severity of the kidney dysfunction appears to parallel with the rise of E/e'.

Conclusion: In CKD, although the longitudinal systolic function was reduced, LV ejection fraction (EF) may remain within normal limits due to the preservation of the circumferential and radial functions. Longitudinal fibers are typically oriented in the subendocardium and thus are more vulnerable to wall stress and fibrosis in contrast to the midwall circumferential fibers, which are not as greatly affected. Given its relatively greater contribution to LV EF, increased circumferential strain can therefore maintain stroke volume, despite significant loss of subendocardial strain. In conclusion, early detection of uremic cardiomyopathy might provide useful information for the risk stratification and decide the proper dialysis therapy in these patients.

	Group 1 (n=21)	Group 2 (n=21)	Group 3 (n=22)	p value
Systolic blood pressure (mmHg)	132.9±9.9	142.8±10.1	151.8±14.5	0.01
Diastolic blood pressure (mmHg)	82.1±7.8	91.3±12.2	95.3±12.5	0.03
Hemoglobin (g/dl)	11.1±1.1	9.7±1.0	8.7±1.2	<0.001
eGFR (mL/min/1.73m ²)	74.8±9.2	53.6±8.1	42.3±10.4	<0.001
LV ejection fraction (%)	61.2±5.1	60.8±4.8	59.4±5.2	0.34
LV end-diastolic diameter (mm)	44.3±4.2	46.1±4.7	46.9±5.5	0.41
Interventricular diameter (mm)	10.1±2.0	10.9±2.1	11.2±2.9	0.12
LV posterior wall diameter (mm)	9.8±1.7	9.9±2.0	10.5±2.5	0.16
E/e'	7.4±1.4	8.2±1.9	10.9±3.2	<0.001
LV longitudinal strain (-%)	24.0±2.7	20.5±2.4	17.5±2.9	<0.001
LV circumferential strain (-%)	21.8±3.2	22.2±3.0	22.9±3.1	0.10
LV radial strain (-%)	38.1±5.3	38.7±5.4	39.0±5.5	0.23

Oral Presentation

Surgical Solutions for Coronary Artery Disease

Date: 28.03.2019 Time: 08:00 - 09:30 Hall: 6

ID: 299

Topic: **Cardiovascular Surgery » Coronary Bypass Surgery**

Presentation Type: **Oral**

LONG-TERM OUTCOME OF IN-SITU SKELETONIZED BILATERAL THORACIC ARTERY FOR LEFT CORONARY CIRCULATION.

Michael Cresci¹, Francesco Cabrucci¹, Marco De Martino¹, Giulia Chiuselli¹, Sandro Gelsomino², Edvin Prifti³, Massimo Bonacchi¹

¹*University of Florence, Florence, Italy*

²*Maastricht University, Maastricht, Netherlands*

³*University of Tirana, Tirana, Albania*

**Corresponding Author (michael.cresci@stud.unifi.it)*

michael.cresci@stud.unifi.it, francesco.cabrucci@stud.unifi.it, marco.demartino12@gmail.com, giulia.chiuselli@gmail.com, sandro.gelsomino@maastrichtuniversity.nl, edvinprifti@hotmail.com, mbonacchi@unifi.it

Abstract Text

Background.We aimed to analyze the outcomes in a patient population using a standardized technique for coronary artery bypass consisting in total arterial myocardial revascularization with in-situ skeletonized bilateral thoracic artery for left coronary circulation (ISS-LITA-LCC-TAMR). We also explore potential predictors of long-time unfavorable outcomes.

Methods.One-thousand-three-hundred-twenty-five consecutive patients undergoing ISS-LITA-LCC-TAMR between January 1997 and May 2017, were included prospectively in this study. Follow up was 100% complete and ranged from 1 to 245 months. Median follow-up (100% complete) was 103 months (IQR 61 to 189 months).

ResultsDuring follow up there were 131 deaths (9.8%), 146 repeat revascularizations (11.0%) and 229 major adverse cardiac events (MACE, 17.2%). Eighteen-year freedom from these events were 62.6±9.3%, 62.5±6.3% and 53.9±11.0 %, respectively. Multivariable models showed that left ventricular ejection fraction ≤ 35%, chronic obstructive pulmonary disease, peripheral vascular disease (p<0.0001), chronic kidney disease and age ≥80 years (p=0.002) were independent predictors of diminished long-term survival. Moreover, peripheral vascular disease and off-pump coronary artery bypass (both, p<0.001) predicted repeat revascularization. Finally, age ≥ 80 years, peripheral vascular disease, left ventricular ejection fraction ≤ 35%, (all, p<0.0001), off-pump coronary artery bypass (p=0.0003) and chronic pulmonary obstructive disease (p=0.0004) were independent predictors of MACE during long-term follow-up.

Conclusions.Coronary artery bypass using ISS-LITA-LCC-TAMR configuration resulted in satisfactory long-term results with low incidence of death and late events and may represent a technique of choice in selected CABG patients. Larger and long-term prospective studies are, however, warranted.

ID: 88

Topic: Cardiovascular Surgery » Coronary Bypass Surgery

Presentation Type: Oral

**EVALUATION OF DEPRESSION AND ANXIETY IN CORONARY ARTERY
BY-PASS SURGERY PATIENTS**

Melike Elif Teker Açikel

S.B.Ü. Haseki Eğitim ve Araştırma Hastanesi, İstanbul, Turkey

**Corresponding Author (melikelif_teker@hotmail.com)*

melikelif_teker@hotmail.com

Abstract Text

OBJECTIVE; Many studies indicate that coronary artery bypass graft surgery patients affected by depression and anxiety between 30% and 40% of all cases. Recent evidence suggests that both depression and anxiety increase the risk for mortality and morbidity after coronary artery bypass graft surgery independent of medical factors.

The objective of this this clinical study is to evaluate the psychological effects of the CABG surgery on patients.

METHODS; Beck Depression Inventory and Beck Anxiety Inventory tests were performed in 65 patients in pre-operative period and post-operative 3rd, 7th and 30th days. None of the patients was used psychotropic drugs. None of the patients had any chronic psychological illness.

RESULTS; Both anxiety and depression levels were increased significantly following coronary artery bypass graft operation when compared with pre-operative level in all patients. We found that, post-operative depression and anxiety levels were higher than the pre-operative period ($p < 0.001$). However after post-operative 3rd day, there was no statistical changing in depression and anxiety level compared with post-operative 7th and 30th day

CONCLUSIONS; We suggest that good management of the psychological condition of the cardiac surgery candidates, as well as post by-pass patients, will improve quality of life and cardiovascular outcomes in these patients.

ID: 338

Topic: **Cardiovascular Surgery » Coronary Bypass Surgery**Presentation Type: **Oral****DOES URGENT OFF-PUMP TO ON-PUMP CONVERSION WORSEN THE EARLY OUTCOME OF CORONARY ARTERY BYPASS GRAFTING SURGERY?****Abdusalom Abdurakhmanov, Oybek Mashrapov***Republican Research Center of Emergency Medicine, Tashkent, Uzbekistan***Corresponding Author (ab.abdurakhmanov@yandex.com)**ab.abdurakhmanov@yandex.com, docmashrap@yahoo.com***Abstract Text**

Backgrounds and objectives: Off-pump coronary artery bypass grafting (OPCAB) has been shown to be an effective strategy for surgical revascularization. conversion to on-pump during off-pump coronary artery bypass surgery (CABG) increases morbidity and mortality. We analyze its impact on immediate outcome.

Methods: All patients undergoing isolated CABG between 2013 and 2018 were included. Patients were grouped according to their intraoperative conversion to cardiopulmonary bypass: (1) conversion for visualization or for hemodynamic instability, and (2) no conversion (OPCAB). Postoperative mortality and the postoperative complications (death, myocardial infarction, heart failure, rhythm disturbances, wound infections and cerebrovascular accident) were compared between patients with and without conversion. Results: A total of 1007 patients were operated off pump and 44 (4,4%) patients required a conversion. Postoperative death was more frequent among patients who were converted urgently (11.6% vs. 2.3%, $p < 0.001$, respectively). Incidence of such postoperative complications as: heart failure and rhythm disturbances were higher among urgently converted patients (18,2% vs 3,8%, $p < 0.001$, and 15,9% vs. 5,8%, $p < 0.001$, respectively). Conversion was an independent predictor of these events (OR = 4,97, 95%CI: 1.79 to 13,3; OR = 9.73, 95%CI: 4,52 to 20,92; and OR 2,74, 95%CI: 1.17 to 6,41, respectively). Emergency conversion from off- to on-pump CABG dramatically worsens early outcome after off-pump CABG.

ID: 32

Topic: **Cardiovascular Surgery » Coronary Bypass Surgery**Presentation Type: **Oral****RANDOMIZED TRIAL OF ENDOSCOPIC VERSUS OPEN RADIAL ARTERY HARVEST FOR CORONARY REVASCULARIZATION****Muhammed Tamim, Yaser Alkadi, Donia Alhassan***King Fahd Military Medical Complex, Dhahran, Dhaharn, Saudi Arabia***Corresponding Author (mttamim@yahoo.com)**mttamim@yahoo.com, ykadi@yahoo.com, donya.alhassan@gmail.com***Abstract Text****Objectives**

Endoscopically harvested radial artery as a graft for coronary revascularization had become a standard of care in many centers. The aim of this randomized study was to assess graft quality 1 year after the operation comparing open and endoscopically harvested radial artery.

Methods

We followed 50 patients who underwent non emergent on-pump coronary artery bypass grafting prospectively randomized to either endoscopic radial artery harvest (ERA) or open radial artery harvest (ORA). Follow-up 64-slice cardiac computed tomography, echocardiography were utilized to assess wall motion abnormality and left ventricle function at a 6 months and 1-year follow-up. In addition, the influencing factors of radial artery graft patency were evaluated. One interventional cardiologists and consultant radiologist assigned graft patency and disease grades independently.

Results

Any patency of endoscopically harvested radial artery grafts was 93% (48/50) and perfect patency was 83% (45/50) 1 year after coronary revascularization. The implanting surgeon and graft harvester, patient factors, graft properties, medication, and target territory did not influence the patency rates of the radial artery graft. The only significant and strong parameter to predict perfect graft patency was the severity of the target vessel stenosis ($P < .001$). Patency rates of endoscopically (82%) and conventionally (80%) harvested radial arteries were not different ($P = .822$).

Conclusions

Patency rates 1 year after endoscopic radial artery harvesting are comparable to the open technique. On the basis of our results, we attempt to use the radial artery as a bypass graft only for target coronary arteries with 90% or greater stenosis. We recommend endoscopic harvesting as the technique of choice to harvest the radial artery.

ID: 294

Topic: **Cardiovascular Surgery » Coronary Bypass Surgery**Presentation Type: **Oral****SURGICAL TREATMENT OF LEFT MAIN CORONARY ARTERY(LMCA):
SINGLE CENTER EXPERIENCE****Hasan Toz¹**, Gülsüm Türkyılmaz¹, Ahmet Akgül²¹*Bakırköy Dr.Sadi Konuk Eğitim Araştırma Hastanesi, İstanbul, Turkey*²*İstanbul Üniversitesi Sağlık Bilimleri Fakültesi Dekanı, İstanbul, Turkey***Corresponding Author (tozhasan@hotmail.com)**tozhasan@hotmail.com, oztrose@hotmail.com, aakgul@hotmail.com***Abstract Text****INTRODUCTION**

Left main coronary artery normally provides the flow of 64% of the left ventricular myocardium. Severe ischemic damage to the myocardial tissue of the left main coronary stenosis may occur. The prognosis is poor in cases with left main coronary artery stenosis and annual mortality is 10-15%. Successful myocardial revascularization in occlusive disease of the left main coronary artery provides a long and high quality of life for patients. In this study, patients who underwent surgical intervention for left main coronary artery disease were evaluated.

MATERIALS-METHODS

1 sempterber 2015 - 1 july 2018 total 45 cases in our clinic operated by the left main coronary artery stenosis. 32 of the cases were male, 17 of the cases were female. 17 of the patients were operated in emergency terms. Other cases have been recognized after the elective coronary angiography and operated in the early period.

RESULTS

2 to 5 vein bypass grafts were used in patients. Positive inotropic support was applied to 18 patients during the early postoperative period due to low heart rate, in 5 patients needed preoperative intra aortic balloon pump support,in 9 cases needed intra aortic balloon pump support in postoperative early period. 9 patients were exitus due to the low heart flow in the early period.

DISCUSSION

The critical shortness of the left main coronary artery, which provides the blood supply of a significant portion of the left ventricular myocardium, always confronts the patient with massive anterolateral myocardial infarction.This results in severe left ventricular dysfunction or death in patients. The critical stenosis of the left main coronary artery requires coronary artery bypass graft.It is possible to wait for a short period of preoperatively in some selected patients with left main coronary artery stenosis. However, patients with preoperative acute myocardial infarction or severe chest pain symptoms should be taken into operation without waiting. Intra aortic balloon pump application is recommended in patients with inadequate medical treatment in decreasing preoperative ischemia.

ID: 279

Topic: **Cardiovascular Surgery » Coronary Bypass Surgery**Presentation Type: **Oral****INVESTIGATION OF THE EFFECT OF LOCAL LIDOCAINE (ON ATRIUM) ON ATRIAL RHYTHM DISORDERS IN OFF-PUMP CORONARY SURGERY****Yusuf Velioglu¹, Ferhat Borulu²**¹*Abant İzzet Baysal University Faculty of Medicine , bolu, Turkey*²*Atatürk University Faculty of Medicine, Erzurum, Turkey***Corresponding Author (yusufvelioglu@gmail.com)**yusufvelioglu@gmail.com, fborulu@gmail.com***Abstract Text****Abstract****Objectives**

Rhythm disorders such as atrial fibrillation are frequently seen in both intraop and postoperative periods of off-pump coronary bypass surgery. The aim of this study was to evaluate whether the frequency of rhythm disturbance affecting the hemodynamics of the patient during manipulation of the during off-pump coronary surgery can be reduced by local lidocaine administration on the atrium.

Methods and patients

Between February 2017 and June 2018, 135 patients who underwent isolated off-pump coronary artery surgery in our clinic were divided into two separate groups and included in the study. Patients who had rhythm disorder before and were returned to on-pump surgery during surgery were excluded from the study. Local lidocaine was applied to atrium in some patients before heart manipulations were started. Standard applications were made for the other group. All rhythm disorders developed during surgery were recorded and medical interventions were recorded. Routine follow-up and rhythm disturbances in postoperative follow-up were recorded and compared with all demographic features.

Results

Atrial fibrillation was similar in both groups in 17.1% and 18.3% in the intraoperative period. Other rhythm disturbances such as bradycardia and ventricular arrhythmia and related medical interventions were significantly lower in the local lidocaine group ($p = 0.02$ and $p = 0.03$). Although atrial fibrillation was less common in the same group during postoperative period, this difference was not statistically significant. There was no significant difference between the two groups in terms of demographic features and postoperative follow-up.

Conclusions

In particular, local lidocaine administration on the atrium may be useful in reducing intraoperative dysrhythmias during off-pump coronary bypass surgery. Atrial fibrillation may be reduced in postoperative period, but larger and other factors are needed.

ID: 195

Topic: **Cardiovascular Surgery » Coronary Bypass Surgery**Presentation Type: **Oral****STERNUM CLOSURE WITH STERNAL CABLE IN OPEN HEART SURGERY: OUR EXPERIENCE**Elif Coşkun¹, Levent Altınay¹¹Zonguldak Bülent Ecevit University Faculty of Medicine , Zonguldak, Turkey*Corresponding Author (drelfco@gmail.com)drelfco@gmail.com, laltinay@gmail.com**Abstract Text****Sternum closure with sternal cable in open heart surgery: our experience**
Abstract**Background.** We present our clinical experience with the sternal cable which is a novel sternum closure device.**Methods.** Twenty-two patients who undergone an open heart surgery with sternotomy between January 2017 – December 2018 included in this retrospective study. Patient data were collected from the patient records. Thirteen (59,1%) patients were male and 9 (40,9) patients were female. The mean age was $65,23 \pm 9,46$ years. Twenty patients (90,9%) had hypertension, 12 (54,5%) patients were smokers, 13 (59,1%) patients had diabetes, 11 (50%) patients had impaired thyroid gland functions (TFT). Five (22,7%) operations were done under emergency conditions and 17 (77,3%) operations were elective operations. The demographic data were presented in Table 1.**Results.** Seventeen (77,3%) patients were operated for coronary artery disease (CAD), two (9,1%) patients were operated for ascending aortic dissection, one (4,5%) patient was operated for aortic and mitral valve disease, two (9,1%) patients were operated for ascending aortic aneurysm. Mean time of intensive care unit (ICU) stay was $4,45 \pm 5,03$ days, mean time of in-hospital stay was $13,09 \pm 7,64$ days. Four (18,2%) patients had sternal dehiscence. The mortality rate was 22,7% (5 patients).**Conclusion.** Sternum closure cable is an alternative sternal closure device which can be used safely and effectively in selected patients.**Keywords:** Sternal cable, sternum dehiscence, open heart surgery, obesity

Table 1. Demographic data

		Mean±SD	Count
Age		65±9	
Gender	Male		13
	Female		9
BMI		1,90±0,27	
HT	Yes		20
	No		2
Smoking	Yes		12
	No		10
DM	Yes		13
	No		9
DM Medication	None		11
	Insulin		4
	OAD + Insulin		6
	OAD		1
COPD	Yes		10
	No		12
Obesity	Yes		8
	No		14
CRI	Yes		2
	No		20
Carotid artery disease	Yes		1
	No		21
PAD	Yes		1
	No		21
CVI	Yes		2
	No		20
Preoperative EF		49±9	
Preoperative status	Elective		17
	Emergency		5
HbA1c		6±4	
Fasting glucose		218±95	
Albumin		4±1	
Hb		18±24	
Sedimentation rate		39±28	
LDL		107±51	
Impaired TFT	Yes		11
	No		11

ID: 429

Topic: Cardiovascular Surgery » Research

Presentation Type: Oral

CULTURE RESULTS IN TUNNELED CENTRAL VENOUS CATHETERS

Arzu Şenol, Sefa Şenol

Feti Sekin Educational and Research Hospital, Elazig, Elaziğ, Turkey

asenol2017@gmail.com, ssenol2014@gmail.com

Abstract Text

OBJECTIVE: Tunneled central venous catheters used for the provision of hemodialysis are associated with excess morbidity and mortality. Catheter related exit site and blood stream infections are major risks of their use. The aim of this study was to examine the culture results in permanent catheters of vital importance in hemodialysis patients.

METHODS: A retrospective review of 86 patients (30: female, 56: male, mean age: 58 ± 17 years) with hemodialysis catheter was performed between 2016 and 2018. After the catheter was inserted into the study since the A-V fistulas did not meet the need for dialysis or they did not meet the dialysis requirements, the removed catheters were removed. Patients without any symptoms or symptoms of infection were included in the study.

RESULTS: 15 of the inserted hemodialysis catheters were femoral (17.4%) and the rest were jugular hemodialysis permanent catheter (82.5%). Staphylococcus epidermidis and Staphylococcus aureus were the most common microorganisms.

CONCLUSIONS: Even if there is no sign of congestion or infection in the persistent hemodialysis catheters, it is likely that the majority of patients will have positive growth cultures even after 2 months and alternative applications should be developed for the prevention of catheter infections and for long-term use in needy patients.

Oral Presentation

Progress in Basic and Experimental Understanding in Cardiovascular Medicine

Date: 28.03.2019 Time: 09:30 - 11:00 Hall: 6

ID: 506

Topic: **Cardiology » Gene Therapy in Cardiovascular Disease**Presentation Type: **Oral**

THE EFFECT OF ANGIOTENSIN CONVERTING ENZYME I/D GENE POLYMORPHISMS ON SILAZAPRIL EFFECT IN ACUTE MYOCARDIAL INFARCTION PATIENTS

Onder Ozturk, Unal Ozturk*Diyarbakir Gazi Yasargil Education and Research Hospital, Diyarbakir, Turkey***Corresponding Author (droozturk21@hotmail.com)**droozturk21@hotmail.com, drunalozturk@gmail.com*

Abstract Text

Objective: Carriers of the D-allele of ACE insertion/deletion (I/D) polymorphism display elevated serum and cardiac ACE activity and thus may be exposed to higher angiotensin II levels than those with the I-allele. ACE DD-genotype was associated with augmented neurohumoral activation and cardiac dilatation, as well as poor prognosis after an acute myocardial infarction. Patients with acute anterior myocardial infarction who have ACE DD genotype are high risk of heart failure and death. Myocardial performance index (MPI) is an easily measured index for the assessment of global heart function, combining both systolic and diastolic components. MPI has been shown to be independent of HR, blood pressure, loading conditions and the geometry of the ventricles and can be used to evaluate the function of both the RV and the LV. We aimed to investigate the effect of Angiotensin Converting Enzyme I/D gene polymorphisms on left ventricular function in patients with acute anterior myocardial infarction treated with silazapril.

Methods: Overall 84 patients with a first acute anterior myocardial infarction (MI) were included in this cross-sectional study. DNA was isolated from peripheral leukocytes. Based on the polymorphism of the ACE gene, they were classified into 2 groups: Deletion/Deletion (DD) genotype (Group 1, n=36), Insertion/Deletion (ID), Insertion/Insertion (II) genotypes (Group 2, n=48) (Figure 1). Cardiac evaluation with echocardiography was performed within 24 hours of admission to cardiology care unit and after fifth day admission to cardiology unit. LV MPI by TDI was obtained from the apical four-chamber view by placing the sample volume at the lateral mitral annulus. Measurements of TDI isovolumic contraction time (tICT) were obtained by measuring from the end of a'-wave (atrial-contraction wave) to the onset of s-wave (myocardial systolic wave); TDI isovolumic relaxation time (tIRT) was obtained by measuring between the end of the S-wave and the onset of the e'-wave (early-diastolic wave); TDI ejection time (tET) was measured from onset to the end of s-wave (Fig. 1). LV MPI was then calculated as $(tICT + tIRT)/Tet$ (Figure 2). Student's t test, paired t test and Chi-square analyses were used to compare differences among subjects with different genotypes.

Results: There were no significant differences among clinical parameters of patients (Table 1). LV MPI was significantly higher in patients who have ACE DD genotypes than in patients who have ACE ID/II genotype at admission (0.45 ± 0.17 versus 0.41 ± 0.22), ($p < 0.05$). After five days later silazapril treatment, LV MPI was significantly lower in patients who have ACE DD genotypes than in patients who have ACE ID/II genotype (0.37 ± 0.16 versus 0.39 ± 0.24), ($p < 0.05$).

Conclusion: Our results suggested that, ACE Gene I/D polymorphism may influence early cardiac remodeling after acute myocardial infarction. Also ACE inhibitor therapy may reverse deleterious effects of D allele on the left ventricular remodeling.

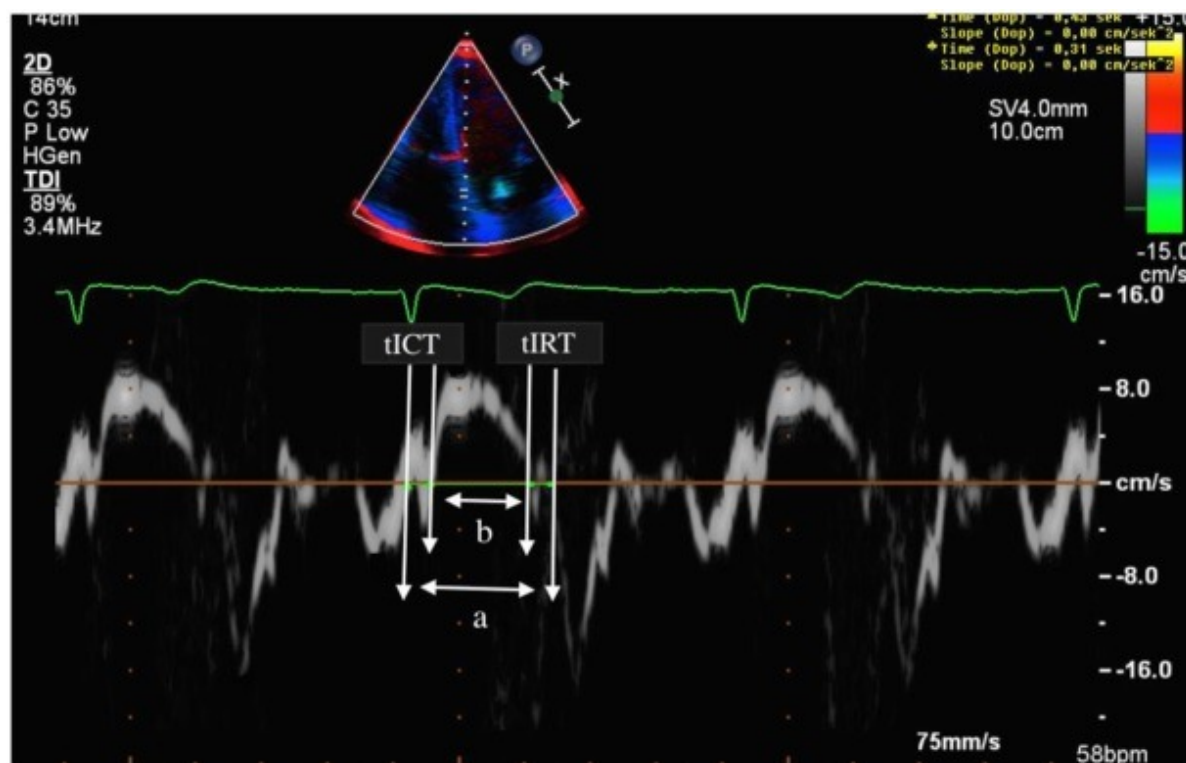
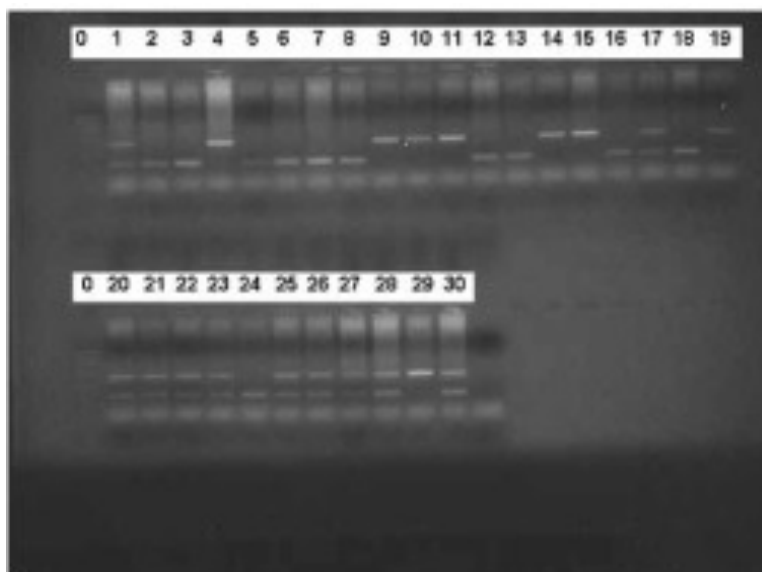


Table 1. Clinical characteristics of patients.

Variables	ACE DD Genotype (n=36)	ACE ID /II (n=48)	p Value
Age , years	57±12	56±11	NS
Gender, F/M	7/29	11/37	NS
BMI, kg/m ²	24.3±3.5	22.7±2.8	NS
Hypertension, n(%)	11(32%)	9 (20%)	NS
Diabetes Mellitus, n(%)	4 (12 %)	4 (8 %)	NS
Current Smoking, n(%)	20 (56 %)	30 (62 %)	NS
Hypercholesterolemia, n(%)	9 (24 %)	16 (33 %)	NS

ID: 72

Topic: **Cardiology » PI for SHD - Others**Presentation Type: **Oral****RELATION OF APOLIPOPROTEIN E (APOE) GENE POLIMORPHISM WITH SEVERITY OF CORONARY ARTERY DISEASE (CAD) IN PATIENTS WITH STABLE ISCHEMIC HEART DISEASE****Ahmet Seyda Yılmaz¹, Şenol Çitli²**¹*Rize State Hospital, Rize, Turkey*²*Tokat Gop University, Tokat, Turkey***Corresponding Author (ahmetseydayilmaz@gmail.com)**ahmetseydayilmaz@gmail.com, drsenolcitli@hotmail.com***Abstract Text**

BACKGROUND: Atherosclerosis which is a cause of coronary heart disease (CHD) starts from early age and reveals increased age. This inflammatory process is aggravated by age, smoking, hypercholesterolemia, hypertension, diabetes mellitus, genetic. We aimed to observe which isoform of APO E gene has more extensive coronary lesions in patients with stable coronary artery disease.

METHODS: From January 2017 to December 2017, 110 patients have chest pain and determined coronary artery disease by coronary angiogram are consecutively included. After the angiogram syntax score was calculated by tool of website calculator (www.syntax.com). According the Syntax score which demonstrate severity and complexity of coronary arteries patients divided into two groups. APOE genotypes gathered into three groups: E4 (3/4 and 4/4 genotypes), E3(3/3 genotype), E2 (2/2 and 2/3 genotypes) and compared with syntax groups.

RESULTS: A total of 98 patients with their coronary angiography and genotype of APOE analyze. 81 of patients (%82,6) had E3E3 allele ; 6 of patients(%6,1) had E2E3 allele; 10 patients (%10,2) had E3E4 allele and 1 patient(%1) had E2E4 allele. Due to the contrast effect of E2 and E4 on CHD we excluded patients with E2E4 allele from the study. We assessed first, distribution of APOE genotype E2 (E2E3), E3(E3E3 and E3E4), E4(E3E4) in 3 groups of syntax scores. Total of 6 patients of E2 allele were in low syntax score group. 83 patients of E3 allele were in low risk group of syntax score. 10 patients of E3 allele were in medium group and 4 patients were in high risk group of syntax score. 7 patients of E4 allele subjects were in low risk and 1 of was in high risk group of syntax score. When the individuals are separated into groups of syntax score and compared with APOE genotypes, E2 alleles were in low syntax score group versus E3 and E4 alleles significantly and E4 alleles were in high syntax score group versus E2 and E3 alleles significantly either ((E2 versus E3): P = 0,046; (E3 versus E4): P= 0,034; (E2 versus E4): P=0,003). If we compare APOE groups according the Syntax scores, the score was tendency to be lower in E2 allele group versus E4 (P=0,013) and E2 versus E3 (P=0,040)

CONCLUSION: In conclusion we reported the first study has been done with patients have stable angina to evaluate the genetic determinant of CAD extensity and found that E2 allele is more related with less extensity of CAD in stable ischemic heart disease.

ID: 68

Topic: Cardiovascular Surgery » Research

Presentation Type: Oral

INDUCIBLE VASCULAR OCCLUSION MODEL

Mustafa Etili, Oğuz Karahan

Alanya Alaaddin Keykubat Üniversitesi, Alanya/Antalya, Turkey

**Corresponding Author (mustafaetli@yahoo.com)*

mustafaetli@yahoo.com, oguzk2002@gmail.com

Abstract Text

Introduction: Vascular occlusion is usually undesirable situation that can be using for treatment sometimes. Therefore, creation of local occlusion models which has not disrupts surrounding endothelium is important. We investigated to the effects of the hypericum extract on vascular endothelium with special light spectrum.

Material and Method: Nine rabbits were used for study as control (n:3), sham (n:3), and experiment (n:3) groups. Alone intraarterial hypericum extract (03 mg/kg) was applied control group; intraarterial hypericum extract (03 mg/kg) with special light spectrum was applied experiment group; intraarterial special light spectrum was applied experiment group. Aortic tissues were obtained at the second hour of experiment and histopathologically investigated.

Findings: Normal histological visualisation was detected in sham and control groups in regards to intima, media and adventitia layers. Differently in experiment group, foam cell infiltration was observed in aortic intima, endothelial ondulation and local separations detected in tunica media. Moreover, prominence was detected in vaso vasorum.

Conclusion: Normally harmless hypericum extract, changed its effects while application of special light spectrum and induce thrombosis with inducing endothelial injury.

ID: 193

Topic: Cardiovascular Surgery » Research

Presentation Type: Oral

BREAST CANCER MAY BE TREATED BY DABIGATRAN DURING VENOUS THROMBOEMBOLISM PROPHYLAXIS: IN VITRO STUDY IN MCF CELL LINE

Salih Güler¹, Emre Kubat¹, Özer Aylin Gürpınar²¹Gülhane Trainig and Research Hospital, Ankara, Turkey²Hacettepe University Faculty of Science, Ankara, Turkey

*Corresponding Author (drsalihguler@gmail.com)

drsalihguler@gmail.com, ekubat@gmail.com, ozergurpinar@gmail.com

Abstract Text

OBJECTIVE: Thromboembolic disorder is a serious risk factor in cancer patients. Acute venous thromboembolism is the second leading cause of death after the malignancy itself. Recurrent venous thromboembolism and bleeding complications are high risk factors in anticoagulant treatment for acute venous thromboembolism in cancer patients. However, there is only a few data suggest that anticoagulant drugs may have an effect on cancer cells. Therefore in this study we aimed to investigate the effects cytotoxic activity of dabigatran on MCF-7 breast cancer cell line.

METHODS: MCF-7 cells were cultured in a 96-well at 50.000 cells/ml initial cell density and cells were treated with five different dilutions of dabigatran (Dilution I: 24 µM; Dilution II: 12 µM; Dilution III: 6 µM; Dilution IV: 3 µM and Dilution V: 0.75 µM). Only the cell culture medium without dabigatran were served as control. At 24 hours, cell morphology and cell viability were evaluated. Cell viability was analyzed through methylthiazole tetrazolium (MTT) assay.

RESULTS: The cells exposed to dabigatran showed a significant difference compared to normal fibroblastic morphology. The cells displayed degeneration as nuclear condensation and rounded cell morphology. All dilutions of dabigatran was cytotoxic at 24 hours incubation ($p < 0.05$) (Table 1). These results indicates that dabigatran may reduce cell proliferation in tumor tissue.

Table 1. MTT results at 24th hour in each dilution of dabigatran compared to control group

Dilutions	Mean	sd	p value
D1	0.127	0.021	0.000
D2	0.137	0.019	0.000
D3	0.245	0.034	0.000
D4	0.288	0.036	0.000
D5	0.274	0.042	0.000
Control	0.433	0.073	-

Mean: Absorbance (OD), sd: standart deviation, *P values compared to control group.

Dilution I: 24 µM; Dilution II: 12 µM; Dilution III: 6 µM; Dilution IV: 3 µM and Dilution V: 0.75 µM.

CONCLUSIONS: Based on the results of this study, we concluded that dabigatran may be used not only prophylaxis of venous thromboembolism but also preventing of cell proliferation especially in breast cancer patients. However, more comprehensive studies are needed to confirm our results.

ID: 164

Topic: **Cardiovascular Surgery » Research**Presentation Type: **Oral****EFFECTS OF VITAMIN C ON TOXICITY OF DABIGATRAN: AN IN VITRO STUDY****Emre Kubat***Gülhane Training and Research Hospital, Ankara, Turkey***Corresponding Author (ekubat@gmail.com)**ekubat@gmail.com***Abstract Text**

OBJECTIVE: A nonvitamin-K oral anticoagulant dabigatran is commonly used in the prophylaxis and treatment of systemic embolism and deep vein thrombosis. Our previous studies showed that dabigatran exhibits in vitro cytotoxic effect on different cells. Therefore in this study we aimed to investigate the effects of different dilutions of vitamin C on toxicity of dabigatran.

METHODS: L929 mouse fibroblasts were cultured in a 96-well at 50.000 cells/ml initial cell density and cells were treated with 3 µM of dabigatran. Then, vitamin C was applied in five different dilutions (Dilution I: 0.60 mM; Dilution II: 0.30 mM; Dilution III: 0.15 mM; Dilution IV: 0.075 mM and Dilution V: 0.0375 mM). Only the vitamin C without dabigatran and cell culture medium were served as control. At 24 and 48 hours, cell morphology was evaluated; cell viability was analyzed through methylthiazole tetrazolium (MTT) assay and apoptosis was assessed by propidium iodide (PI) / acridine orange staining.

RESULTS: The results of MTT assay showed that the maximum cell viability was shown in dilution V at 48 hours ($p < 0.05$) (Table 1). This indicates that vitamin C has a positive effect on cell viability at low concentrations. In contrast, vitamin C induce apoptosis at high concentration of vitamin C (Figure 1).

CONCLUSIONS: Based on the results of this study, we concluded that vitamin C has a protective effect on cells at low concentrations in an in vitro model. Therefore, it is considered that vitamin C may be used as an supportive agent in dabigatran treatment. However, further studies are needed to gain a better understanding of this effect of vitamin C.

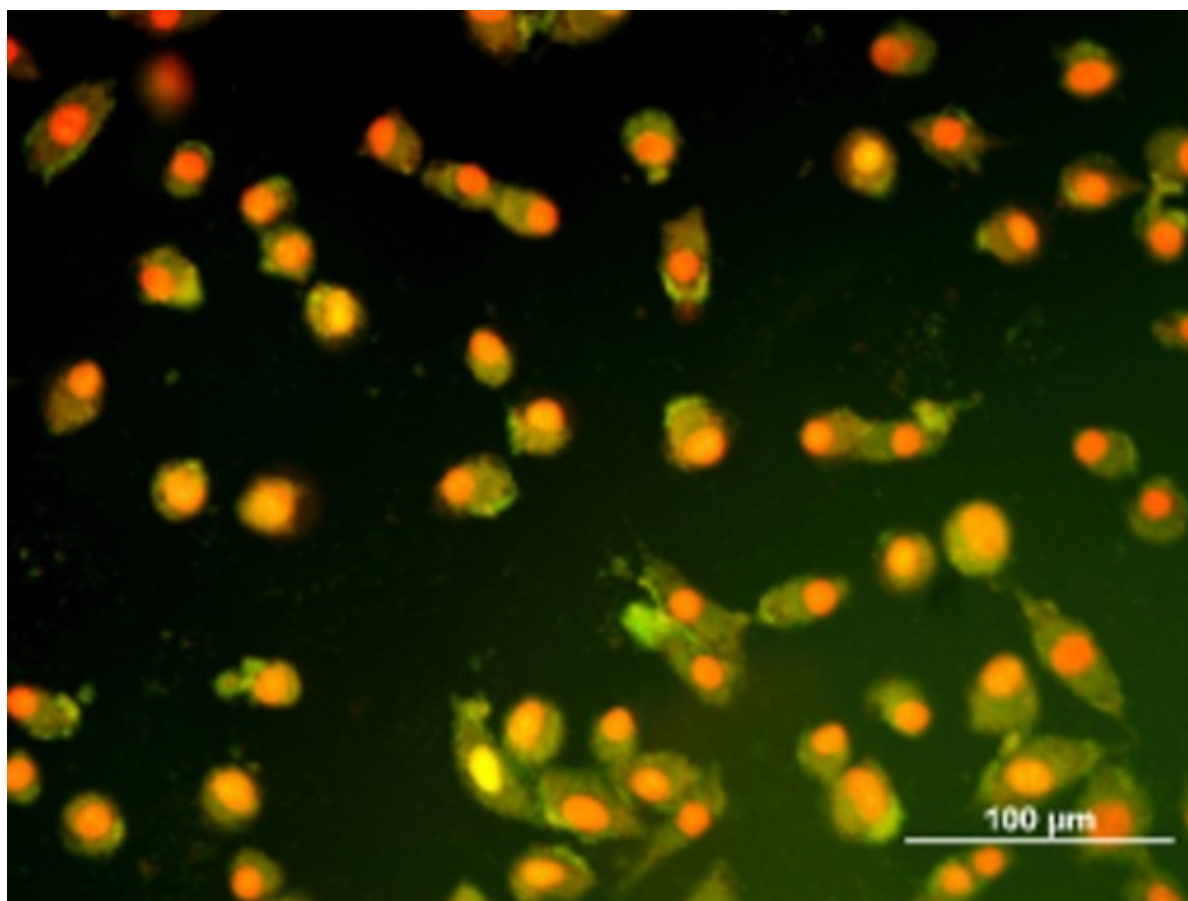


Figure 1. AO/PI staining of L929 mouse fibroblasts exposed to dabigatran and vitamin C in dilution I.

Table 1. MTT results at 24 and 48 hours in each dilution compared to control group

24 h	D+CI	D+CII	D+CIII	D+CIV	D+CV	CI	CII	CIII	CIV	CV	Control
Mean	1.489	1.548	1.559	1.539	1.529	1.571	1.767	1.871	1.888	1.774	1.512
sd	0.466	0.342	0.250	0.290	0.060	0.602	0.364	0.091	0.071	0.352	0.140
p	1.000	1.000	1.000	1.000	1.000	1.000	0.973	0.795	0.746	0.968	-
48 h	D+CI	D+CII	D+CIII	D+CIV	D+CV	CI	CII	CIII	CIV	CV	Control
Mean	1.498	1.506	1.936	1.667	2.154	1.225	1.344	1.182	1.873	1.604	0.996
sd	0.368	0.298	0.305	0.153	265	0.318	0.303	0.310	0.403	0.300	0.446
p	0.999	0.999	0.111	0.851	0.005	1.000	1.000	0.999	0.220	0.959	-

ID: 107

Topic: **Cardiovascular Surgery » Research**Presentation Type: **Oral****EFFICIENCY OF MINIMIZED CIRCUITS ON HEART ROLLER PUMP ON SYSTEMIC INFLAMMATORY RESPONSE SYNDROME AND MULTIORGAN EFFECT IN A RAT MODEL****Tugra Gencpinar¹, Gokmen Akkaya², Cagatay Bilen², Pinar Akokay¹, Nuran Ay Dereli¹, Osman Yilmaz¹, Kivanc Metin¹, Serdar Bayrak¹**¹*Dokuz Eylul University, İzmir, Turkey*²*Ege University, İzmir, Turkey***Corresponding Author (tugra01@yahoo.com)**tugra01@yahoo.com, akkayagokmen@gmail.com, cagataybilen@hotmail.com, pinarakokay@gmail.com, st.nuranay@yahoo.com, osman.yilmaz@deu.edu.tr, kivanc.metin@deu.edu.tr***Abstract Text**

Background: The aim of this study was to compare the effects of line length shortening on systemic inflammatory response syndrome and myocardial protection in a rat model of cardiopulmonary bypass from a histological point of view.

Materials and Methods: Twelve adult male Wistar Albino rats weighing more than 180 g (400-450 gr) were randomly selected by the Experimental Animals Local Ethics Committee and divided into two groups. In one group, the pump lines were kept 1 meter shorter. The right jugular vein and the tail artery were cannulated using a 16-gauge catheter. Animals received 500 IU/kg i.v. heparin sodium. Throughout the experiment, the cardiac index and the rectal temperature were found to be 2.4 mL and 36°C, respectively. The total line volume was maintained at 8 mL. The roller pump was adjusted to supply a blood flow of 6-28 mL/min (mean 10 mL/min) similar to the cardiac output of rats. The CPB duration was 15 minutes. Following the sacrifice, tissue samples were collected from heart, liver and kidney for histomorphological examinations.

Results: All histochemical and histomorphological analyses were performed by two blinded researchers. Histochemical examinations revealed band loss in cardiomyocytes, mononuclear (MNL) cell infiltration and impaired fibrillar organization in longer-line group. Additionally, sinusoidal dilatation in the liver, low level of congestion, focal necrosis and periportal MNL infiltration were noticed in the same group. In shorter-line group, on the other hand, MNL cell infiltration, band loss in myofibrilles and cardiomyocyte degeneration were rarely observed compared to the longer-line group. In addition, higher liver congestion and lower MNL cell infiltration was observed in the shorter-line group. No significant difference was found for kidney samples.

Conclusion: In the shorter-line roller pump test model; less multiorgan damage and systemic inflammatory response were observed. In cardiac surgery, it may be applicable to keep the CPB lines as close to the table as possible, especially in pediatric cases.

ID: 553

Topic: Cardiology » Diabetes Mellitus and Cardiovascular Disease

Presentation Type: Oral

THE PROTECTIVE ROLE OF MOXONIDINE ON DIABETIC CARDIOMYOPATHY

Ismail Polat Canbolat, Oytun Erbas

Istanbul Bilim University, Faculty of Medicine, Istanbul, Turkey

*Corresponding Author (p_canbolat@yahoo.com)

p_canbolat@yahoo.com, p_canbolat@yahoo.com

Abstract Text

Objective: Moxonidine is a centrally-acting imidazoline receptor agonist that lowers blood pressure by decreasing sympathetic nerve activity centrally. An improvement in insulin sensitivity following moxonidine therapy has also been demonstrated in insulin-resistant obese patients with mild hypertension. We investigated the effect of moxonidine on preventing diabetic cardiomyopathy.

Methods: Diabetes was induced by intraperitoneal (i.p.) injection of streptozocin for 14 rats. No drug was administered to the remainder of rats (n=7) (control group). The rats with blood glucose levels 250 mg/dl and higher were included in this study. Then, four-teen diabetic rats were randomly divided into 2 groups; diabetes group treated with 1 mL/kg saline (Diabetes) (n=7), and diabetes group treated with 0.4 mg/kg/day moxonidine, (Physiotens, Abbott) (Diabetes + moxonidine) (n=7) was administrated by i.p. for four weeks. The animals were euthanized and blood samples were collected by cardiac puncture for biochemical analysis and removal of the heart were performed for histopathological examination.

Results: In diabetic rats, cardiac muscle cell thickness (hypertrophy), TGF-beta, MDA and fibronectin immunexpression were increased significantly when compared to control group. Administration of resveratrol in diabetic rats causes a significant reduction both in cardiac muscle cell thickness, TGF-beta, MDA and fibronectin immunexpression in these rats (Table-1).

Conclusion: Our animal study demonstrated that moxonidine has a protective role against diabetic cardiomyopathy. Clinical research is needed.

Keywords: moxonidine, diabetic cardiomyopathy, TGF-beta, fibronectin, MDA

Normal Control (Group-1)	Diabetes (saline treatment)(Group-2)	Diabetic rat (moxonidinetreatment) (Group-3)	
Cardiac muscle cell thickness(% of control)	100	117.3.5 ± 3.9 *	108.4 ± 2.09 #
Immunoexpression Fibronectin percent (%)	12.8 ± 2.05	39.1 ± 5.6 *	20.4 ± 4.3 #
Blood glucose (mg/dl)	95.6 ± 7.8	385.7 ± 10.6 **	415.3 ± 13.5
TGF-Beta (pg/ml)	9.7 ± 1.2	31.9 ± 3.6 *	22.5 ± 3.3 #
MDA (nM)	76.3 ± 11.2	345.4 ± 21.6 *	215.3 ± 10.5 #

* p<0.001, saline treatment diabetic rats compared control group

** p<0.000, saline treatment diabetic rats compared control group

p<0.05, moxonidinetreatment diabetic rats compared saline treatment diabetic rats

ID: 246

Topic: **Cardiology » Preventive Cardiology**Presentation Type: **Oral**

EVALUATION OF ENDOTHELIAL DYSFUNCTION IN PATIENTS WITH NONALCOHOLIC FATTY LIVER DISEASE

Bahar Tekin Tak, Firdevs Ayşenur Ekizler

Turkiye Yuksek Ihtisas Training and Research Hospital, Ankara, Turkey

**Corresponding Author (tekinbahar@yahoo.com)*

tekinbahar@yahoo.com, firdevs_bsk@hotmail.com

Abstract Text

Objective: Nonalcoholic fatty liver disease (NAFLD) is the liver-mediated disorder of metabolic syndrome which is one of the most common causes of chronic liver disease in developed countries. There are some etiological factors common to this disease and metabolic syndrome which are accepted as cardiovascular risk factors such as diabetes mellitus, obesity, and dyslipidemia. In recent studies it has been shown that NAFLD itself was an atherosclerotic risk factor and has been related to several cardiovascular events. Arterial endothelium is the layer in which atherosclerosis develops. Thus, endothelial dysfunction is one of the main causes of atherogenesis and increases the risk of cardiovascular disease. The aims of this study are to appraise endothelial function by flow-mediated dilation (FMD) measurement which is accepted as noninvasive methods, and the cardiovascular risk (CVR) profile in patients with non-alcoholic fatty liver disease (NAFLD).

Methods: A total of 66 consecutive patients with NAFLD, who were examined in Liver Disease Outpatient clinic and 56 age- and sex-matched controls were included in the study. Complete blood counts and biochemical parameters including lipid profile and fasting glucose were measured using standard methods. Anthropometric assessments of height and weight were evaluated and body mass index (BMI) (kg/m²) was calculated. Endothelial function was determined by flow-mediated dilation (FMD) and nitroglycerin-mediated dilation (NMD) measured via high-resolution external ultrasonography. The CVR profile was calculated according to the Framingham equation.

Results: The age, gender distribution and smoking rates were similar between patients with NAFLD group and control group. At the time of the baseline characteristics, the median age of the NAFLD patients was 53.2 years. According to initial measurements, there weren't any significant differences in brachial artery diameter between the NAFLD and control groups (2.44 ± 0.37 mm vs. 2.46 ± 0.38 mm, $p=0,7$ respectively). In patients with NAFLD, the FMD ratio was significantly lower than in controls ($2,69 \pm 0.27$ mm vs. $2,79 \pm 0.29$, respectively, $P=0.021$). NMD in response to sublingual nitroglycerin did not differ between the NAFLD and control groups ($3,11 \pm 0.11$ mm vs. $2,97 \pm 0.41$, respectively, $p =0.125$). The CVR profile was significantly higher in the NAFLD group than in the control group.

Conclusion: Our study demonstrates that the risk of endothelial dysfunction and cardiovascular events in NAFLD patients is higher than that of healthy control subjects matched by age and gender. Endothelial dysfunction is associated with coronary atherosclerosis in the very early phases of disease and is indicative of disease grade. In conclusion, it may be thought that possible treatment options targeting disease or endothelial dysfunction may be effective in reducing cardiovascular risk in NAFLD patients.

ID: 350

Topic: **Cardiovascular Surgery » Diagnosis and Treatment of Valvular Heart Disease**

Presentation Type: **Oral**

**NOVEL PATHWAY IN RHEUMATIC MITRAL VALVE DISEASE:
CYTOCHROME P450 AND GLUTATHIONE S TRANSFERASE ISOZYME
EXPRESSION**

Erdal Şimşek¹, Gülçin Şimşek², Mehmet Fazıl Tolga Soyal³, Pınar Kaygın⁴, Ali Cemal Düzgün⁵, **Emre Külahcıoğlu¹**, Sezen Yılmaz Sarıaltın⁶, Sadi Kaplan⁷, Serpil Oguztuzun⁴

¹University of Health Sciences, Turkiye Yuksek Ihtisas Training and Research Hospital, Ankara, Turkey

²University of Health Sciences, Kecioren Training and Research Hospital, Ankara, Turkey

³Atilim University Faculty of Medicine Medicana International, Ankara, Turkey

⁴Kirikkale University, Faculty of Arts and Sciences, Kirikkale, Turkey

⁵University of Health Sciences, Ankara Training and Research Hospital, Ankara, Turkey

⁶Ankara University, Faculty of Pharmacy, Ankara, Turkey

⁷Hacettepe University, Ankara, Turkey

*Corresponding Author (erdaldr@yahoo.com)

erdaldr@yahoo.com, gulguler1975@yahoo.com, tolgasoyal@gmail.com, erdaldr@yahoo.com, drcemalduzgun@gmail.com, emrekulahcioglu@gmail.com, erdaldr@yahoo.com, skpn1966@hotmail.com, soguztuzun@yahoo.com

Abstract Text

Background: Cytochrome P450 CYP1A1, glutathione S-transferase pi (GSTP1) and omega (GSTO1) isozymes were searched and compared with the patients with the diagnosis of rheumatic mitral valve disease and the cause of ischemic mitral valve insufficiency to find the relation of the oxidative stress with rheumatic mitral valve disease.

Methods: Control group who were operated on with the cause of ischemic mitral valve insufficiency (group I, n:14) while study group consisted of the patients with the diagnosis of rheumatic mitral valve disease (group II, n:29). Paraffin sections (4 µm thick) of mitral valve materials were stained with hematoxylin and eosin. CYP1A1, GSTP1, and GSTO1 immunohistochemical markers were studied. The specimens were evaluated using light microscopy at 40- to 400-fold magnification.

Results: %20.7 of GSTP1 isozyme protein expression was seen in the study group; however, no expression in the control group. No statistically significant differences in the level of GSTO1, GSTP1 and CYP1A1 protein expression between study and control group was observed (p>0.05; p=0.487, p=0.070, p=0.153; respectively). There was no significant association between protein expressions and patient's demographic variables (p > 0.05).

Conclusions: In this study, GSTP1 isozyme may be related with the rheumatic mitral valve disease. The strategy that prevents the oxidative stress for the patients who had rheumatic mitral valve disease could be a valuable choice of searching to affect the disease progression.

ID: 428

Topic: Cardiology » Diabetes Mellitus and Cardiovascular Disease

Presentation Type: Oral

HBA1C IS IMPORTANT IN PATIENTS WITH CORONARY ARTERY DISEASE

Sefa Şenol

Feti Sekin Educational and Research Hospital, Elazig, Turkey, Elazig, Turkey

**Corresponding Author (ssenol2014@gmail.com)*

ssenol2014@gmail.com

Abstract Text

OBJECTIVE: In this study, non-diabetic myocardial infarction with ST elevation, representing acute myocardial infarction and non-diabetic patients with no history of myocardial infarction have compared.

METHODS: Subjects included 90 non-diabetic patients who suffered a myocardial infarction with ST elevation, representing acute myocardial infarction (group 1), 90 non-diabetic patients with no history of myocardial infarction , who were scheduled for coronary artery bypass graft surgery, representing coroner arter disease (group 2), and 90 healthy controls (group 3).

RESULTS: Groups 1 and 2 had higher levels of hypertension and HbA1c, low-density lipoprotein cholesterol, high-density lipoprotein cholesterol, and fasting plasma glucose (levels compared to those of group 3. Groups 1 and 2 had similar fasting plasma glucose and HbA1c levels. fasting plasma glucose and HbA1c levels of groups 1 and 2 were significantly higher than those in the control group (P = 0.001, P = 0.034 and P = 0.001).

CONCLUSIONS: Prediabetes and diabetes were frequently seen in both groups, but most patients were unaware. HbA1c represents a good choice for screening and follow-up evaluations of prediabetes and diabetes in patients with coroner arter disease.

Oral Presentation

Today's Practise of Congenital Heart Surgery

Date: 28.03.2019 Time: 11:15 - 12:15 Hall: 6

ID: 404

Topic: **Cardiovascular Surgery » Research**

Presentation Type: **Oral**

THE CORRELATION OF RAPHAE STRUCTURE TO THE INTERLEAFLET TRIANGLES IN FETAL/PEDIATRIC AORTIC STENOSIS SPECIMENS

Saadullah Ahmed, Vi - Hue Tran, Andrew C. Cook

Institute of Cardiovascular Science - University College London, London, United Kingdom

**Corresponding Author (saadullah.ahmad.15@ucl.ac.uk)*

saadullah.ahmad.15@ucl.ac.uk, v.tran@ucl.ac.uk, a.cook@ucl.ac.uk

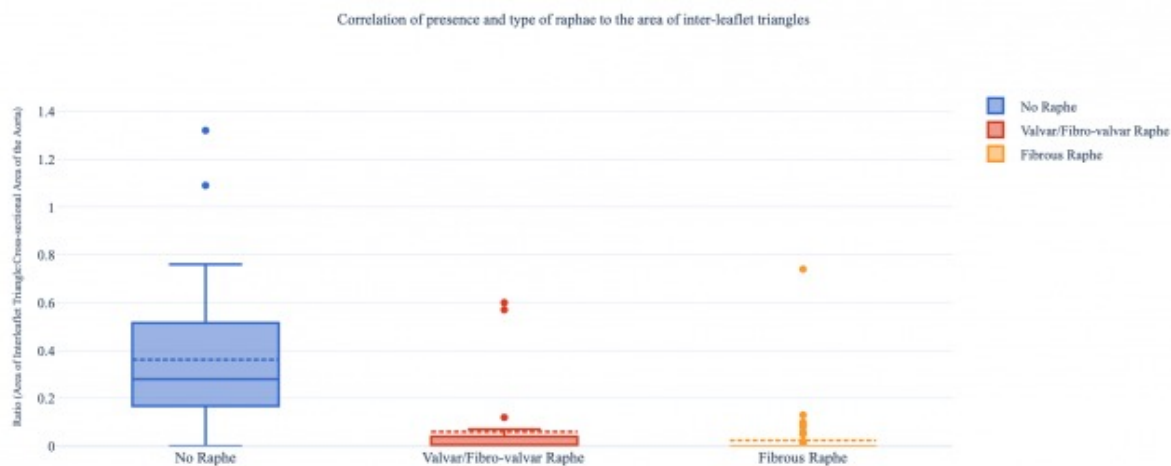
Abstract Text

Background: Interleaflet triangles are crucial for the normal functioning of the aortic valve. Loss or reduction in the area of interleaflet triangles, often seen as a result of fusion between valvar leaflets, makes the valve stenotic. Replacement of commissures by raphae has been noted at the sites of fusion. Composition of raphae is surgically relevant, as presence of valvar tissue can aid valve repair. Whereas, the interleaflet triangles have been studied in the past, the composition of raphae has not been studied in detail. This study is the first to our knowledge assessing the composition of raphae morphologically and correlating it to the area of interleaflet triangles.

Method: A total of 124 commissures and raphae in aortic valve specimens of the fetal/pediatric age group were analyzed. Presence and composition of raphae based on presence of an infolding or the arterial wall or valvar tissue or both was noted by gross inspection. In order to calculate the area of the interleaflet triangles, the base was measured as the distance between the nadirs of the two adjacent leaflets, and the height determined by measuring the distance from the apex of the triangle to the midpoint of the base. The diameter of the aorta was measured, and circumference of the ventriculo-arterial junction and cross-sectional area of the aorta were calculated using π . All measurements were performed using a Vernier caliper. A ratio of area of interleaflet triangles to the cross-sectional area of the aorta was calculated, individually, to standardize the measurements, accounting for variability in sizes of the specimens.

Results: The mean ratio in the setting of no fusion between leaflets was 0.36, as compared to an average mean ratio of 0.06 where fusion was present. Raphae consisting of valvar tissue had a mean ratio of 0.06, whereas, raphae composed only of arterial wall had a mean ratio of 0.02. One-way ANOVA analysis showed f-ratio value = 41.0 and a p-value < 0.00001.

Conclusions: Raphae consisting of valvar tissue are associated with larger corresponding interleaflet triangles. Corroboration of interleaflet triangle size by echocardiography may aid in the selection of cases for surgical repair of the valve rather than valve replacement, in the pediatric age-group.



Raphe	<i>n</i>	Mean	SD	Median	q1	q3
No Raphe	41	0.36	± 0.28	0.28	0.17	0.52
Valvar/Fibro-valvar Raphe	26	0.06	± 0.15	0	0.0	0.04
Raphe consisting of arterial wall	57	0.02	± 0.10	0	0.0	0.0

ID: 6

Topic: **Cardiovascular Surgery » Congenital Heart Disease**Presentation Type: **Oral**

EVALUATION OF SURGICAL TREATMENT IN PATIENTS WITH TOTAL ANOMALOUS PULMONARY VENOUS CONNECTION: FIFTEEN YEARS OF SINGLE INSTITUTE EXPERIENCE

Gökmen Akkaya, Çağatay Bilen, Yüksel Atay

*Ege University, Izmir, Turkey***Corresponding Author (akkayagokmen@gmail.com)**akkayagokmen@gmail.com, cagataybilen86@gmail.com, yuksel.atay@ege.edu.tr*

Abstract Text

Objective: In this study, we present our fifteen years of outcomes following surgical repair total anomalous pulmonary venous connection. Thereby we sought to assess possible risk factors effects both hospital and late term follow up morbidity and mortality.

Methods: A retrospective study was carried out between 2002- 2017 by including a total of 41 patients who were operated on with the diagnosis of total anomalous pulmonary venous connection. Patients' demographic data, preoperative medical findings, operative values and post-discharge findings, echocardiography and computed tomography results were collected.

Results: There was 3 hospital mortality. The mean age of the patients was measured as 9 ± 11.68 months. The mean weight of the patients before the operation were found to be 3720 ± 2042 gr. Nineteen of the patients were in supracardiac, 13 were intracardiac, 8 were infracardiac, and one was in mixed type TAPVC. Mean cardiopulmonary by-pass time was 84.78 ± 25.84 minutes and mean aortic cross-clamp time was 57.24 ± 15.17 minute. No patient required reoperation in late term follow-up.

Conclusion: Thanks to developed surgical techniques and medical care, nowadays, surgical treatment may be utilized with similar mortality and morbidity rates regardless of coexisting cardiac defects to all types of TAPVC at every age and provides satisfactory results in late term follow-up.

ID: 35

Topic: **Cardiovascular Surgery » Congenital Heart Disease**Presentation Type: **Oral**

JUNCTIONAL ECTOPIC TACHYCARDIA FOLLOWING EARLY REPAIR OF TETRALOGY OF FALLOT

Ahmed Elmahrouk, Mohamed Ismail, Ahmed Jamjoom

King Faisal Specialist Hospital and Research Center, Jeddah, Saudi Arabia

**Corresponding Author (a_marouky@hotmail.com)*

a_marouky@hotmail.com, mfismail@yahoo.com, jamjoom_ahmed@hotmail.com

Abstract Text

Background: Junctional ectopic tachycardia is a serious arrhythmia that frequently occurs after tetralogy of Fallot repair. Arrhythmia prophylaxis is not feasible for all pediatric cardiac surgery patients and identification of high risk patients is required. The objectives of this study were to characterize patients with JET, identify its predictors and subsequent complications and the effect of various treatment strategies on the outcomes in selected TOF patients undergoing total repair before 2 years of age.

Methods: From 2003 to 2017, 609 patients had Tetralogy of Fallot repair, 322 were included in our study. We excluded patients above 2 years and patients with preoperative arrhythmia. 29.8% of the patients (n= 96) had postoperative JET.

Results: JET patients were younger and had higher preoperative heart rate. Independent predictors of JET were younger age, higher preoperative heart rate, cyanotic spells, non-use of B-blockers and low Mg and Ca (p= 0.011, 0.018, 0.024, 0.001, 0.004 and 0.001; respectively). JET didn't affect the duration of mechanical ventilation nor hospital stay (p= 0.12 and 0.2 respectively) but prolonged the ICU stay (p= 0.011). JET resolved in 39.5% (n=38) of patients responding to conventional measures. Amiodarone was used in 31.25% (n=30) of patients and its use was associated with longer ICU stay (p= 0.017). Ventricular pacing was required in 4 patients (5.2%). Median duration of JET was 30.5 hours and 5 patients had recurrent JET episode. Timing of JET onset didn't affect ICU (p= 0.43) or hospital stay (p= 0.14) however, long duration of JET increased ICU and hospital stay (p= 0.02 and 0.009; respectively).

Conclusion: JET increases ICU stay after TOF repair. Preoperative B-blockers significantly reduced JET. Patients with preoperative risk factors could benefit from preoperative arrhythmia prophylaxis and aggressive management of postoperative electrolyte disturbance is essential.

ID: 355

Topic: **Cardiovascular Surgery » Adult Congenital Heart Disease**Presentation Type: **Oral****PULMONARY VALVE REPLACEMENT IN PATIENTS WITH CORRECTED TETRALOGY OF FALLOT****Tugra Gencpinar***Dokuz Eylül University Faculty of Medicine, Izmir, Turkey***Corresponding Author (tugra01@yahoo.com)**tugra01@yahoo.com***Abstract Text**

Abstract: Tetralogy of Fallot (TOF) is one of the most common cyanotic congenital heart defects and its treatment is performed surgically. In surgically corrected TOF patients, the development of pulmonary insufficiency in the following years may result in severe right heart failure. In this study, we present our experience with patients who underwent pulmonary valve replacement (PVR).

Method: Between January 2010 and January 2019, patients who had undergone surgery for fallot tetralogy and who had undergone pulmonary valve replacement after pulmonary valve failure were included in the study. Demographic data, clinical features, echocardiographic findings, hospital and intensive care stay, PVR-related complications and prognosis were retrospectively evaluated.

Results: A total of 18 patients (6 female, 12 male, mean age 17 ± 7 years) were included in the study. Age range of the patients during PVR operation ranged from 8 to 58 years (Table 1). In the preoperative evaluation of the patients, 10 of them were NYHA class II, 6 were class III, and 2 were class IV. 7 of the patients were operated with peripheral cannulation and 11 of them were operated with central cannulation which was operated with normothermic extracorporeal circulatory device. No accompanying surgical procedure was detected. The study revealed perioperative death only one patient (5%). Ventricular septal defect (VSD) was closed with patch. One patient was reoperated due to sternum dehiscence. The mean duration of intensive care and hospital stay was 2 and 8 days, respectively. Postoperative echocardiography showed normal bioprosthetic valve performance at 1 month follow-up. A 58-year-old patient with pulmonary artery aneurysm was resected and pulmonary outflow tract patchplasty was performed (Figure 1). 6 patients (33%) had comorbidity related to lung diseases. Most of the patients had a significant decrease in right heart size and tricuspid regurgitation (TR). The mean follow-up period was 3 ± 2.2 years. In the postoperative follow-up period, all patients are followed up with antiplatelet therapy aspirin in NYHA class I clinical condition.

Discussion: Patients with complete correction due to TOF have increased over time due to secondary pulmonary insufficiency. The timing of pulmonary valve replacement in these patients is very important for the improvement of right ventricular function and long-term survival. In experienced centers, PVR is performed with low morbidity and mortality (especially beating heart normothermic extracorporeal circulation support). This study gave the results of mid-term follow-up. Long-term studies are needed.

Key words: Congenital heart diseases; Pulmonary valve surgery; Tetralogy of Fallot; Reoperation

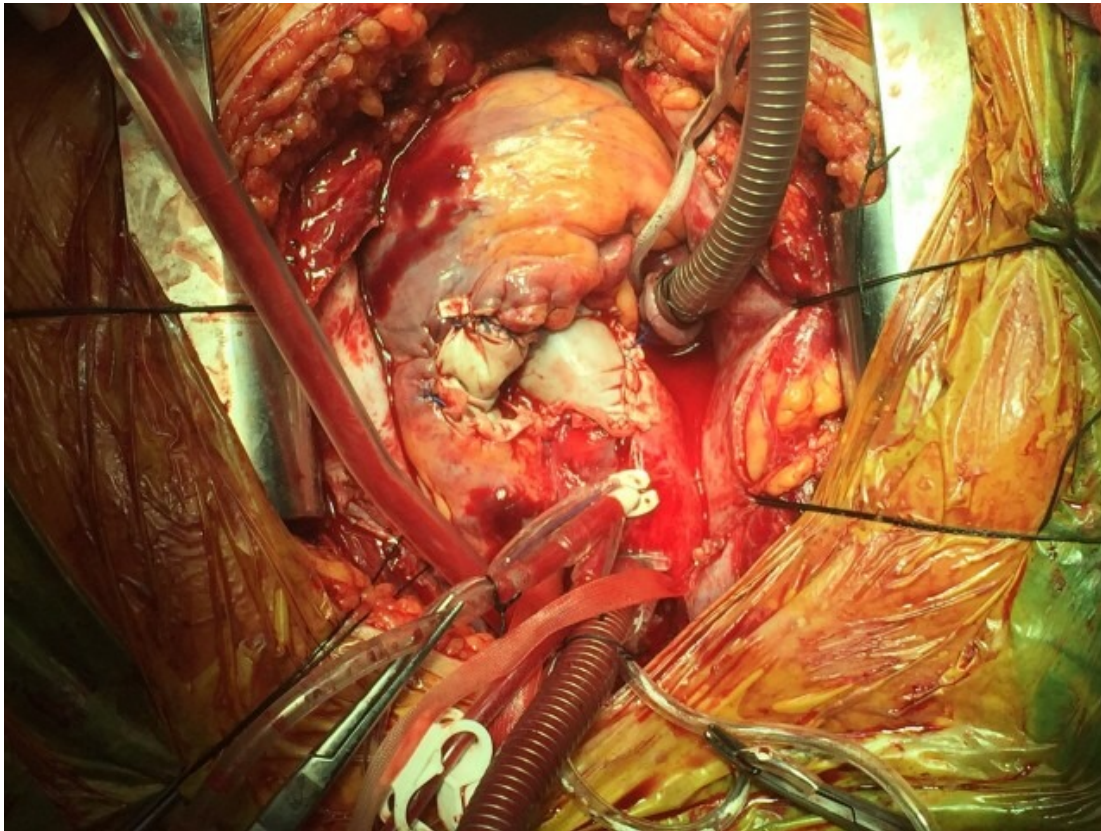


Table 1: Evaluation of patients with tetralogy of Fallot followed by pulmonary valve replacement

Patients	Sex	Age	Intensive Care Unit (Day)	Cannulation Type	Comorbids	Hospitalization Period (Day)	Prognosis
1	M	13	1	central	pneumothorax	7	discharged
2	M	16	1	central		7	discharged
3	M	10	1	central	Bronchiectasis	6	discharged
4	M	12	1	central	VSD	Ex	Ex
5	M	11	2	central		5	discharged
6	M	9	1	central	Bronchitis	8	discharged
7	M	12	2	central		5	discharged
8	F	19	2	central	Asthma	6	discharged
9	F	18	1	central	BT Shunt	6	discharged
10	F	8	1	central	Allergic Rhinitis	6	discharged
11	M	19	7	peripheral	Viral Pneumonia	6	discharged
12	F	34	2	peripheral		7	discharged
13	M	15	9	peripheral		30	discharged
14	M	21	2	peripheral		8	discharged
15	M	8	2	central		5	discharged
16	F	28	2	peripheral		8	discharged
17	F	58	1	peripheral	Pulmonary Artery Aneurysm	14	discharged
18	M	8	2	peripheral		6	discharged

ID: 432

Topic: **Cardiology » Diseases of Aorta**Presentation Type: **Oral****THE ECHOCARDIOGRAPHIC ASSESSMENT OF AORTIC ANNULUS,
SINUS OF VALSALVA AND ASSENDING AORTA DIAMETERS IN
CHILDREN****Sebnem Paytoncu***Manisa City Hospital, Manisa, Turkey***Corresponding Author (sebnempaytoncu888@hotmail.com)**sebnempaytoncu888@hotmail.com***Abstract Text****Objective:**

The aim of this study was to evaluate the aortic valve and to determine cardiac z scores aortic annulus, sinus of valsalva and assending aorta in children.

Methods:

This cross-sectional study included 70 children, 28 (40 %) were female and 42 (60 %) were male, ranging in age from 0 to 18 years (mean 5.69±5.85). Aortic valve measurements were performed during routine echocardiographic evaluation of patients who applied to the pediatric cardiology clinic between 2018 September and October. Three consecutive measurements were performed for each of the parameters and the average value was obtained. Measurements of aortic annulus, sinus of valsalva and assending aorta were made along the long axis of aorta during systole, with the aortic valve leaflets open to their maximal dimension. The indexed aortic parameters were obtained by these values divided body surface area. SPSS15.0 software was used for all statistical analysis.

Results:

The mean aortic annulus was 13±5.3 mm, sinus of valsalva was 17.3±7.19 mm, assending aorta was 15.97±6.64 mm. The average indexed aortic annulus was 22.77± 8.8 mm, indexed sinus of valsalva was 30.51 ±12.33 mm, assending aorta was 28.4±11.98 mm. When Z score values of all patients were examined, dilatation of 4 patients were available: Aortic annulus dilatation (z score 3.2) was in one patient, assending aorta dilatation (z score 3.82) was in one patient, dilatation of sinus of valsalva (z score 3.53) was in one patient, annulus, sinus of valsalva and assending aortic dilatation was in other patient (respectively; z scores 3.57, 5.98, 3.24). One of them had VSD (perimembranous, small) with subaortic membrane and mild aortic insufficiency and the other had prolapsus and insufficiency of mitral valve.

Conclusion:

Echocardiographic evaluation of the aortic valve is part of a routine echocardiographic examination. In this cross-sectional study, it was noteworthy that in our randomized patient group, 4 of our 70 patients (5.7 %) had z scores above 3. We aimed to emphasize that aortic dilatations, aneurysms and ruptures will be detected early in the neonatal period when our study is repeated in large patient groups with aortic valve pathologies and connective tissue diseases.

ID: 291

Topic: **Cardiovascular Surgery » Congenital Heart Disease**Presentation Type: **Oral****DUCT DEPENDENT CYANOTIC NEONATES WITH PDA STENTING POSE A UNIQUE CHALLENGE ON NEXT STAGE SURGICAL INTERVENTION.**

Aitizaz Uddin Syed, Mansour Bader Al Mutairi, Abdul Hameed Al Najjar, Saad Qasim Khushal, Abdul Quadeer Qader, Mustafa Al Muhaya, Mofeed Morsy

Madinah Cardiac Center, Madinah Munawwarah, Saudi Arabia

**Corresponding Author (aitizaz@hotmail.com)*

aitizaz@hotmail.com, mutairim4@gmail.com, drnajjar2000@yahoo.com, drsaad68@hotmail.com, asalaty2@yahoo.com, mustafa_muhaya@yahoo.com, morsym@gmail.com

Abstract Text

Objectives: Thirty consecutive neonates with cyanotic duct dependent lesions were initially palliated with PDA stenting in our center. Of these, 20 babies have undergone one or more surgical procedures. We assessed the pulmonary arteries indexed growth and requirement of further pulmonary arteries rehabilitation in this subset.

Methods: From January 2014 to December 2018 thirty consecutive neonates with cyanotic congenital heart disease had PDA stenting as initial palliation. Eighty percent were ventilated prior to the procedure. Procedural success was 100 %. Survival to discharge was 96 %. All patients were followed up prospectively. 18 patients of this group have undergone further surgical procedures

Results: 90 % of the neonates had origin stenosis of one of the branch pulmonary arteries before PDA stenting. The indexed branch Pulmonary artery size was significantly smaller which grew after stenting the PDA. At the time of surgical procedure (Glenn etc.) Stent division/ ligation required additional PA plasty in 90 % of the cases. The pulmonary arteries in the midterm follow up needed further rehabilitation by stent placement in two third cases.

Conclusions: PDA stent provide excellent palliation in cyanotic neonates. Despite an origin stenosis, the stent allowed growth in the size of both pulmonary arteries. However, majority required surgical augmentation and further stenting of pulmonary arteries in the midterm. Vigilant monitoring of pulmonary artery size is required during follow up imaging of these babies. Stents in PDA cause pulmonary arteries fibrosis and narrowing.

ID: 194

Topic: Cardiovascular Surgery » Congenital Heart Disease

Presentation Type: Oral

STAGED CORRECTIVE TREATMENT IN PEDIATRIC PATIENTS WITH CONGENITAL HEART DEFECT, SEVERE PULMONARY HYPERTENSION AND MARKEDLY ELEVATED PULMONARY VASCULAR RESISTANCE

Emrah Şişli, Serdar Epçaçan

*University of Medical Sciences, Van Training and Research Hospital, Van, Turkey***Corresponding Author (dresisli@gmail.com)**dresisli@gmail.com, drserdar1980@gmail.com*

Abstract Text

Objective: Early diagnosis of congenital heart disease (CHD) is crucial for preventing pulmonary hypertension (PAH) and related conditions. In the cases of severe PAH with markedly elevated pulmonary vascular resistance index (PVRI) and minimal response to acute pulmonary vascular reactivity testing (AVT), the corrective treatment of the CHD can be challenging. The aim of this study is to evaluate our results of staged corrective treatment in this particular group of patients.

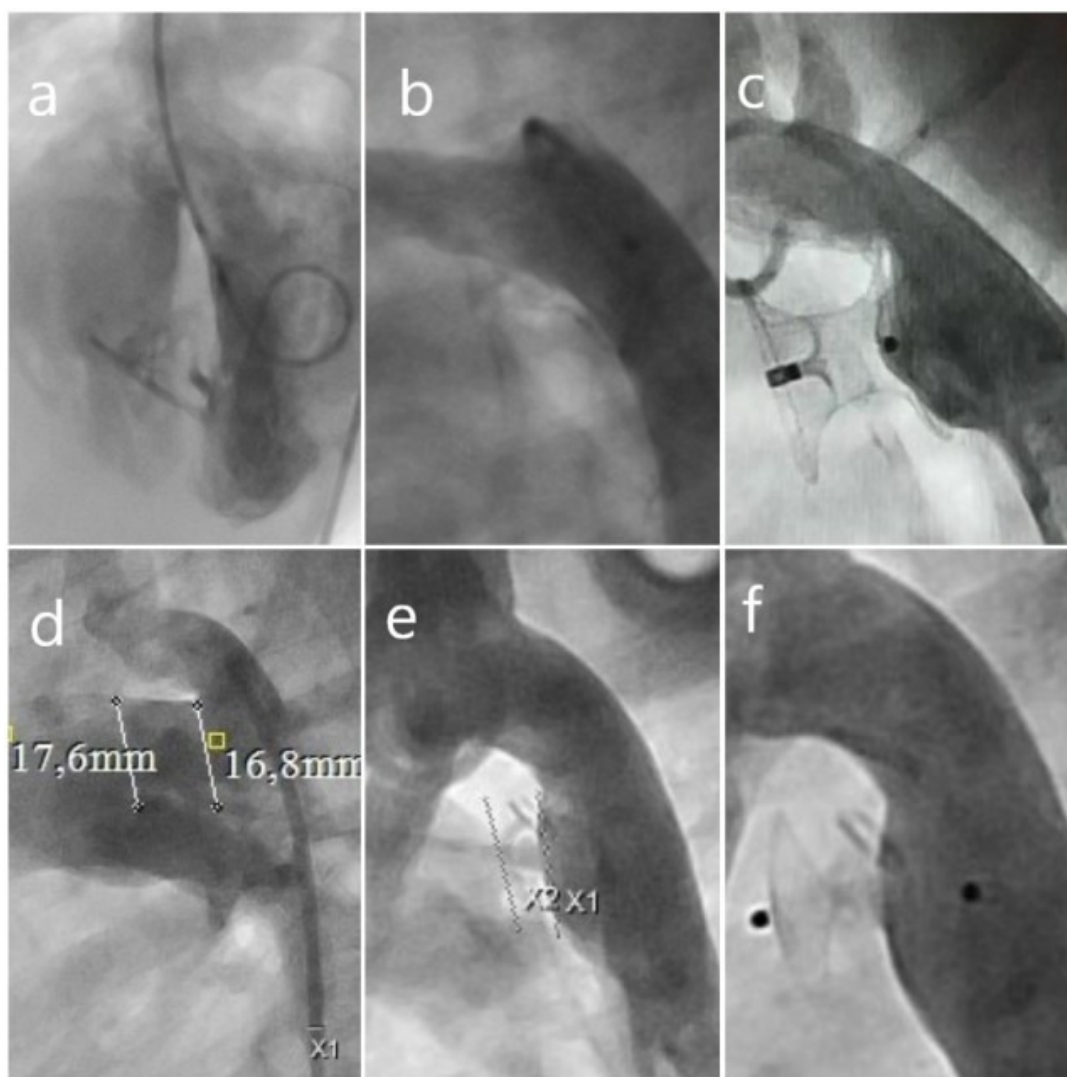
Methods: Pediatric patients with CHD, who underwent cardiac catheterization because of severe pulmonary hypertension between January 2015 and December 2018 were analyzed. The inclusion criteria were PVRI >6, PVR/SVR>0.3 and minimal response to AVT.

Results: 8 patients matched the inclusion criteria and 6 of them had Down syndrome. Demographic and angiographic features of the patients are seen on table. Five patients had both large ventricular septal defect (VSD) and patent ductus arteriosus (PDA), while two had isolated large PDA and another with multiple muscular VSDs. The PDA was percutaneously closed and the catheterization was repeated after at least one year to evaluate hemodynamic changes and determine the surgical correction for VSD, in the patients with co-occurrence of PDA and VSD (Figure 1a-c). Hemodynamic study revealed a positive AVT. All of these patients had surgical VSD closure. In the cases of isolated large PDA (Figure 1d), banding of the PDA was performed and the control catheterization, which was performed one year later, revealed markedly decreased PAB and PVRI, so the residual shunt was percutaneously closed at the same procedure (Figure 1e, f). The largest defect was closed percutaneously and targeted therapy with bosentan was started in the patient with multiple large VSDs. The control catheterization was performed one year later and there was not a significant difference by means of hemodynamic parameters in control catheterization and the residual defects seemed to be enlarged, so no further intervention or surgery was done. There was not an evidence of pulmonary hypertension in any of patients except in the case with multiple muscular VSDs on follow-up period.

Conclusions: Our results showed that, despite the elevated PVRI and insufficient response to AVT for safe and complete correction, staged treatment consisting of initial interventional closure of PDA in co-occurrence of VSD and PDA, and surgical banding of PDA with small residual shunt in the presence of large PDA may lead to decrease in pulmonary hypertension and PRVI and provide the opportunity of successful complete repair in patients under 5-year-old. However, further studies with larger case series are needed to make more evident comments.

Patient	Gender	Age at 1st	PVRI	1st	Age at 2nd	PVR2	2nd
---------	--------	------------	------	-----	------------	------	-----

no		intervention (Year)	(Woods Units.m2)	intervention	intervention (Year)	(Woods Units.m2)	intervention
1	Female	3.5	9	Percutaneous PDA closure	4.5	5.6	Surgical VSD closure
2	Female	5.2	12.1	Percutaneous VSD closure	6	9	-
3	Male	3	8.4	Percutaneous PDA closure	5	5	Surgical VSD closure
4	Female	3.5	9.8	PDA banding	4.5	4	Percutaneous PDA closure
5	Female	3.3	7.4	Percutaneous PDA closure	5	5.6	Surgical VSD closure
6	Female	4	7.2	Percutaneous PDA closure	5.2	3.8	Surgical VSD closure
7	Female	4	7.7	PDA banding	4.7	4.1	Percutaneous PDA closure
8	Male	3.1	8.1	Percutaneous PDA closure	5.9	5.3	Surgical VSD closure (fenestrated)



ID: 511

Topic: **Cardiovascular Surgery » Congenital Heart Disease**Presentation Type: **Oral****OFF-PUMP PULMONARY VALVE REPLACEMENT USING INJECTABLE STENTED TISSUE VALVE: OUR CLINICAL EXPERIENCE**

Sercan Tak, Ali Kutsal

*Dr.Sami Ulus Kadın Doğum Çocuk Sağlığı ve Hastalıkları Eğitim ve Araştırma Hastanesi, Ankara, Turkey***Corresponding Author (sercantak@gmail.com)**sercantak@gmail.com, akutsal@gmail.com***Abstract Text**

Objective: Among the long term complications seen after tetralogy of Fallot(TOF) operations, pulmonary regurgitation(PR) is the most common. Severe PR causes right ventricular dilatation and dysfunction, which can result in decreased exercise tolerance, heart failure, malign arrhythmia and sudden death. The most preferred approach in patients with significant PR is pulmonary valve replacement(PVR) with cardiopulmonary bypass(CPB). As an alternative to this, injectable PVR technique which is less invasive and can be performed without using CPB have been developed. In this study, we aimed to present the surgical results of PVR operations performed with this minimally invasive method in our clinic.

Methods: Between 2013-2018, 12 patients, median age 9.5 (1 - 16), with previous TOF surgery and severe PR were performed operation for injectable PVR purposes. A tissue valve mounted on a self-expanding stent, the No-React Injectable BioPulmonic, in sizes 15(n = 1), 19(n= 2), 21(n = 1), 23(n = 1), 25(n = 1), 27(n = 3), 29(n = 1), 31(n = 2) implanted without using CPB. Intraoperative transesophageal echocardiography (TEE) was performed to all patients for control of valve placement and function.

Results: Injectable biopulmonic valve placement was successfully performed in 9 of the 12 patients. In 3 patients, PVR had to be performed by conventional technique with CPB, due to detection of a problem with the valve in the intraoperatif TEE after injectable valve placement. According to the TEE, left ventricular outflow tract was pressed in 1 patient and right pulmonary artery was obstructed in 1 patient by the valve stent. In 1 patient, injectable valve movements was limited by one of the native pulmonary cusp. No mortality was seen. Mean mechanical ventilation time was 8 hours (2 – 20 hr), mean intensive care unit stay was 1.3 days (1-4 days) and mean hospital stay was 9 days (4-17 days). Mean inotropic score of patients was 20 (0-120). All patients were followed up for 2 months to 5 years and a hemodynamic disorder requiring re-operation was not detected in any patient.

Conclusions: Significant PR occurs after total correction of TOF can be treated with injectable pulmonic tissue valve. Short operation time and avoiding side effects of CPB are the advantages of this off-pump procedure compared the conventional method. As it is a new developing method, studies with larger series are needed.

ID: 467

Topic: **Cardiovascular Surgery » Research**Presentation Type: **Oral**

**OUR CLINICAL EXPERIENCE WITH VENTRICULOATRIAL SHUNT IS AN
ALTERNATIVE TREATMENT APPROACH AT
VENTRICULOPERITONEAL SHUNT DISTAL DYSFUNCTION IN
PEDIATRIC PATIENTS WITH HYDROCEPHALUS**

Hüseyin Sicim, **Gökhan Erol**, Ertan Demirdaş*Gulhane Training and Research Hospital , ANKARA, Turkey***Corresponding Author (drhuseyinsicim@gmail.com)**drhuseyinsicim@gmail.com, drgokhanerol@gmail.com, dr.ertandemirdas@gmail.com***Abstract Text**

Introduction:

Ventriculoperitoneal shunts for the treatment of hydrocephalus are the first choice because of the ease of application, easier revision of the shunt and less fatal shunt infections. It is necessary to select an alternative location for shunt distal in patients with abdominal adhesions due to previous abdominal operation, peritonitis, cerebrospinal fluid causing peritoneal irritation and abdominal pseudocyst. Ventriculo-atrial shunts are not the first choice because of the high risk of complications, but in some cases it is necessary. This study was planned to present the results of patients who underwent ventriculoatrial shunt as an alternative in such patients.

Materials and Methods:

Four pediatric patients who underwent ventriculoatrial shunting due to ventriculoperitoneal shunt dysfunction were included in the study at Gülhane Training and Research Hospital between 2015-2017. Three patients had intraventricular pressure increase due to distal type shunt catheter obstruction and one patient had peritoneal pseudocyst. All patients underwent general anesthesia in the trendelenburg position and the anterior of sternocleidomastoid muscle was incised at lateral side of neck and the carotid artery and internal jugular vein were found. Next, purse suture was placed in the internal jugular vein with prolene suture. Dysfunctional shunt catheter was removed and the distal of catheter was placed in the right atrium cavity through the internal jugular vein with the appropriate location adjusted with scopy. The location of the catheter was confirmed by scopy again.

Results:

The mean age of the patients was 32 ± 6.1 months. Patients were followed-up for 11.2 ± 3.5 months postoperatively. During the follow-up period, no revision was needed for the ventricular atrial shunt. Shunt catheter infection and dysfunction were not detected in the patients who were operated.

Conclusion:

In conclusion, despite the limited number of cases, the ventriculoatrial shunt is technically feasible in patients with ventriculoperitoneal shunt dysfunction and should be kept in mind as an alternative method with satisfactory results.

Oral Presentation

Surgical Solutions for Congenital Heart Defects

Date: 28.03.2019 Time: 13:00 - 14:00 Hall: 6

ID: 153

Topic: **Cardiovascular Surgery » Congenital Heart Disease**

Presentation Type: **Oral**

ISOLATED CONGENITAL CORONARY ARTERY ABNORMALITIES IN CHILDHOOD

Tamer Yoldaş

Dr. Sami Ulus Maternity, Children's Health and Diseases Training and Research Hospital, Ankara, Turkey

**Corresponding Author (tameryoldas@gmail.com)*

tameryoldas@gmail.com

Abstract Text

Objective Congenital coronary anomalies (CCAs) are a rare entity, which is mostly asymptomatic. Their association with myocardial ischemia and sudden death is the major significance in clinical cardiology and cardiac surgery. The overall incidence of congenital coronary artery anomalies is difficult to ascertain. Furthermore, confusion exists as to whether a specific subtype, known as a myocardial bridge, is a normal variant or an anomaly. Such anomalies are detectable by imaging modalities and, according to various definitions, their prevalence ranges from 0.21 to 5.79%. The aim of this study is to review the clinical course, diagnosis and treatment of CCAs in childhood.

Methods: A total of 27 children with isolated CCA were evaluated retrospectively. The demographic characteristics, presentation symptoms, diagnostic modalities, treatments and clinical progresses of patients were examined.

Results: The 13 children were male and 14 children were female. The median age was 17 months (1-168 months). The 11 patients had anomalous left coronary artery from the pulmonary artery (ALCAPA), 15 patients had coronary artery fistulae (CAF) and one patient had anomalous origin of coronary artery from the opposite sinus of Valsalva. The congestive heart failure symptoms were major presenting sign in infants with ALCAPA. The older children had dyspnea, syncope and angina pectoris on effort. All patients with ALCAPA had abnormal Q waves in leads I, aVL, and precordial leads V4 to V6 in ECG. Echocardiography showed left ventricle dilatation and dysfunction, mitral regurgitation, increased echogenicity of the papillary muscle and adjacent endocardium and abnormal origin of left coronary artery in these patients. The diagnostic cardiac catheterization was performed to these patients and showed the dilated right coronary artery, filling of the left coronary artery from collaterals and passage of contrast material from the left coronary to the main pulmonary artery. Surgical treatment was performed all ALCAPA patients. All patients with CAF were asymptomatic and all of these patients were incidentally detected by echocardiographic evaluation of a typical continuous heart murmur. The most common site of drainage was the right atrium, followed by the right ventricle and the pulmonary artery. The treatment modalities of CAF patients were surgical ligation in 8 patients, interventional closure in 3 patients and clinical follow-up in 4 patients.

Conclusions: Isolated congenital coronary anomalies are a very rare disease and individualized treatment strategies in pediatric patients are necessary. Treatment options are predetermined by individual anatomy and the experience of the treating center.

ID: 418

Topic: Cardiovascular Surgery » Adult Congenital Heart Disease

Presentation Type: Oral

TRANSESOPHAGEAL ECHOCARDIOGRAPHIC FINDINGS OF ANOMALOUS LEFT CORONARY ARTERY FROM PULMONARY ARTERY**Günseli Abay***Siyami Ersek Göğüs Kalp ve Damar Cerrahisi Eğitim ve Araştırma Hastanesi, İstanbul, Turkey***Corresponding Author (abaygünseli1@gmail.com)**abaygünseli1@gmail.com***Abstract Text**

Introduction:

Anomalous origin of the left coronary artery (LCA) from the pulmonary artery (ALCAPA) is a rare but serious congenital defect that presents symptoms mostly within the first few months of life. However 5-10% cases can survive past infancy into adulthood. The diagnosis has been based on coronary angiography finding but echocardiographic assesment helps to confirm the diagnosis and provides additional anatomic information. Transesophageal echocardiography (TEE) allows fast assesment novel views of complex cardiac abnormalities and can aid in perioperative monitoring during the surgical procedure⁽¹⁾. This case report provides TEE pictures and intraoperative images of two patients with adult type ALCAPA syndrome.

Case Report

Case 1.

A 26 year old woman with ALCAPA presented chest pain and dyspnea symptoms, which progress since 2 months. Electrocardiogram showed no abnormalities. With suspected angina pectoris, cardiac catheterization was performed which showed dilated and ectatic right coronary artery and the retrograde LCA flow draining into the main pulmonary artery which confirmed the ALCAPA. The patient was scheduled for closure of anomalous LCA ostium from MPA along with left internal mammary artery (LIMA) anastomosis to LCA. In intraoperative TEE assessment midosephageal (ME) short axis view revealed a large LCA connected to the main pulmonary artery (MPA). The right coronary artery (RCA) which was 9 mm in diameter was seen to be dilated, ectatic and turtuous (figure).

Case 2.

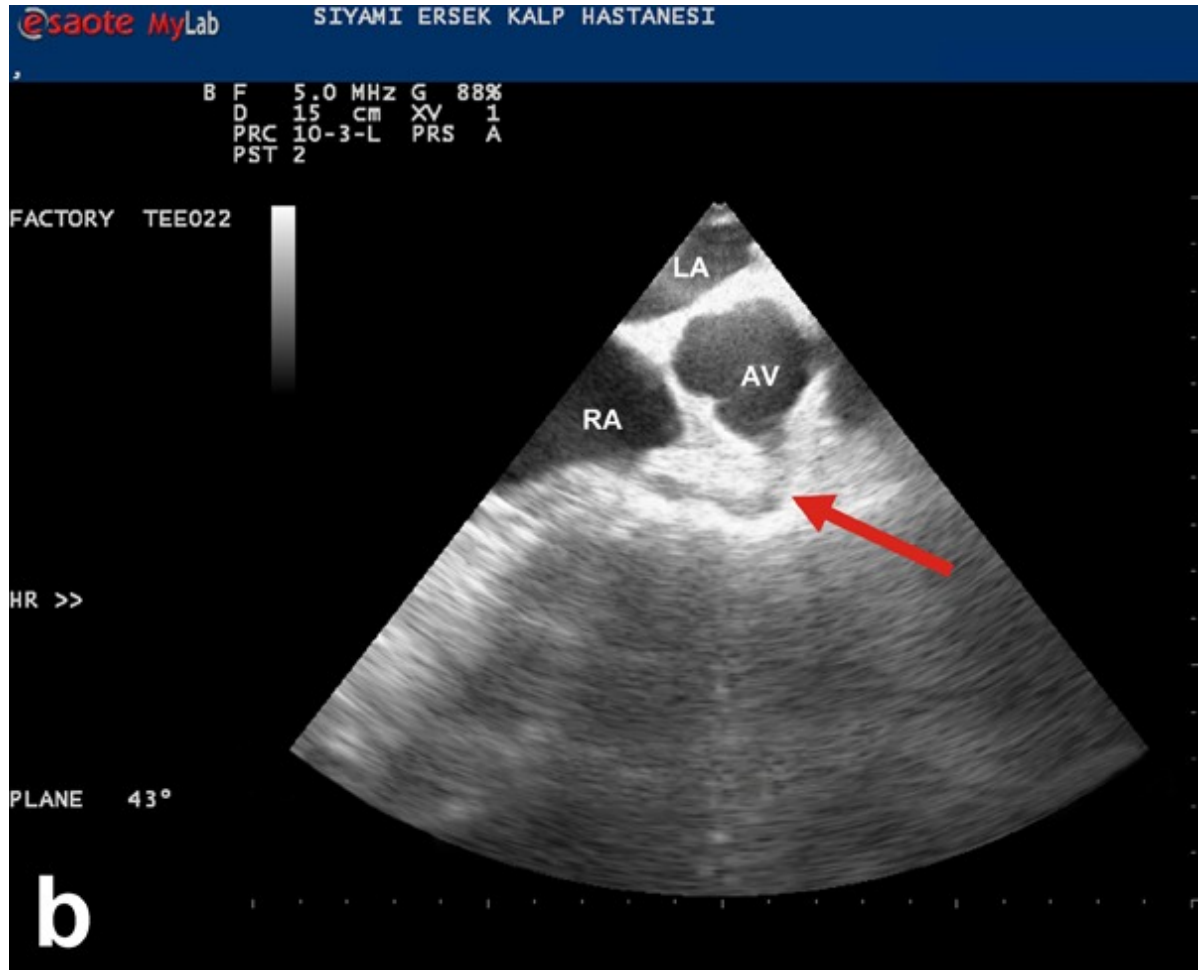
A 37-year-old woman was admitted to our clinic with chest pain progress since 3 months. She was hemodinamically stable and electrocardiogram showed no abnormalities. Cardiac catheterization revealed dilated and ectatic RCA and left to right shunt at the level of MPA and completed the diagnosis of ALCAPA. The patient was scheduled for surgical repair and along with LIMA anastomosis to LCA. In TEE assessment, midosephageal basal short-axis of the aortic valve showed dilated, ectatic and turtuous LCA draining into the proximal MPA. Besides same view revealed the large ostium of RCA draining into the aorta. In the transgastrik short axis view showed scarring in the antero-lateral papillary muscle

Discussion:

Presentation of ALCAPA in adulthood is rare. Multidetector computed tomography and magnetic resonance imaging are very accurate but expensive and not easily available modalities in assessment of the ALCAPA syndrome. On the other hand, 2-D echocardiography is a noninvasive diagnostic modality which provides fairly accurate diagnosis. Both 2-D images and color Doppler may identify origin of LCA from MPA by showing turbulent flow at the ostium. LCA ostium which is sometimes not visible on transthoracic echocardiography could be seen well on TEE. It also demonstrates the retrograde flow from the LCA to the MPA. The presence of retrograde flow is dependent on the development of collaterals between the left and right coronary artery system. Abnormal dilation of the RCA reflects development of extensive collaterals between left and right coronary artery system. Another finding which is not sensitive but highly specific is abnormal brightness of the left ventricular papillary muscles.

Reference:

1. Chgurupati K, Sukesan S, Louhale PS, Dharan BS, Koshy T. Comprehensive intraoperative transesophageal echocardiography of anomalous left coronary artery from pulmonary artery. Echocardiography 2018 Mar; 35(3):391-395.



ID: 514

Topic: Cardiovascular Surgery » Congenital Heart Disease

Presentation Type: Oral

OUR INSTITUTIONAL APPROACH FOR NEONATAL AORTIC COARCTATION

Ozge Pamukcu, Aydin Tuncay, Ali Baykan, Cagdas Vural, Kazim Uzum, Nazmi Narin

Erciyes University, Kayseri, Turkey

**Corresponding Author (ozgepamukcu2002@yahoo.com)*

ozgepamukcu2002@yahoo.com, draydintuncay@gmail.com, alibaykan@erciyes.edu.tr, cvural@erciyes.edu.tr, kuzum@erciyes.edu.tr, nazmi.narin@gmail.com

Abstract Text

OUR INSTITUTIONAL APPROACH FOR NEONATAL AORTIC COARCTATION

Background:

Aortic coarctation accounts for % 8 of congenital heart diseases, one of the most important causes of childhood morbidity and mortality. In this study, we aimed to share our institutional experience in newborn aortic coarctation management: transcatheter versus surgical.

Methods:

This study included 59 newborn cases admitted to our department between the dates 1999-2016. Data records of the patients, echocardiographic records, cardiac catheterization, angiocardiography and surgical records were evaluated retrospectively.

Results:

Thirty-seven of 59 patients were male. Ten cases were diagnosed prenatally and the rest of patients admitted with complaints like: dyspnea (%43.8), tachypnea (%35.4), cyanosis (%35.4). During physical examination at the time of admission, the most common finding is femoral arterial pulse absence/weakness (81,2 %). In addition to the coarctation, 10 cases had arcus aorta hypoplasia, 7 patients bicuspid aortic valve, 7 patients valvular aortic stenosis. 9 patients required PGE1 infusion before treatment. Treatment options for aortic coarctation were surgery and percutaneous aortic balloon angioplasty. 21 patients were corrected surgically and balloon angioplasty were done for 38 patients. After initial treatment mean 25,2±24,5 months later, 57,1% of patients that balloon angioplasty were done and 28.5% of surgically corrected patients required second treatment approach. Main complications of percutaneous angioplasty were aneurysm %3, femoral thrombosis %1. On the other hand; main complications of surgery were bleeding in %14,2 and paraplegia in %7,1. Seven patients who had severe aortic hypoplasia were died: 5 during surgery 2 after surgery. Except for 2 cases all cases came to control visits regularly. During the follow-up period 8 patients developed hypertension and drugs were initiated.

Conclusions:

There is no clear consensus on the choice of aortic coarctation treatment: it varies depending on the experience of the clinic. Although previously percutaneous balloon Angioplasty in neonatal period is thought to be controversial; today with the advance of new equipment and experience it is well accepted treatment strategy. Re-coarctation rates are similar with surgery and complication rates were less than the surgery. However, there was such a bias that the patients who had aortic hypoplasia were referred to surgery which effected success and complication rate of surgery. That is why it is unfair to tell a conclusion that one of these 2 treatment strategies is superior to the other. But there is no doubt that balloon angioplasty is the best choice for postsurgical coarctation.

ID: 365

Topic: **Cardiovascular Surgery » Congenital Heart Disease**Presentation Type: **Oral****ASSESSMENT OF LEFT VENTRICULAR FUNCTIONS IN CHILDREN
AFTER SUCCESSFUL REPAIR OF AORTIC COARCTATION****Fatmaalzahraa Mostafa, Inas Abdelsatar, Soha Imam, Rem Ebrahim, Hosam Ebrahim, Mohamed Sameer,
Ragab Sayed***Cairo University, Cairo, Egypt***Corresponding Author (fatmaalzahraah@hotmail.com)**fatmaalzahraah@hotmail.com, inassaad66@yahoo.com, soha318@yahoo.com, esmail_reem@yahoo.com,
hossam.cardiology@gmail.com, pediatric_medo@yahoo.com, dr_ragab226@yahoo.com***Abstract Text****Background:** Left ventricular dysfunction was observed after repair of coarctation of the aorta (COA) before development of left ventricular concentric hypertrophy.**Aim:** The aim of this study was to assess the the LV fuction after COA repair.**Methods:** Thirty pediatric patients with COA repair underwent echocardiographic examinations using Conventional echo, TDI and 2D-STE. Results: There was a significant reduction of (FS, EF, MAPSE at the LW LV) in cases compared to the control group (p value < 0.05) measured by M-mode. The LV systolic function assessed by TDI and 2-D-STE showed a significant reduction of (S' LW LV, IVA at LW LV, IVA at the septum, LS basal and GRS) in cases compared to control group (p value< 0.05). There is significant increase in GCS in case compared to control group, the conventional Doppler derived MPI of LV in post coarctation repair cases was significantly prolonged compared to control. Analysis of mitral annulus velocities including E', A', E'/A' ratio and E/E' ratio revealed worsening of the left ventricular diastolic mechanics in the post COA repair cases compared to healthy controls. The E' wave velocity (at the left ventricular lateral wall) was significantly lower in post COA repair cases compared with controls (p value< 0.05), E'/A' ratio was significantly lower in post COA repair cases compared with controls (p value< 0.05). The E/E' ratio was significantly higher in the post COA repair cases compared to the control group (p value< 0.05). There was significant RV systolic dysfunction in patients with post coarctation repair compared to normal control.

Significant positive correlation was found between the left ventricular mass and age of patient, duration after intervention, blood pressure in right arm, diastolic blood pressure in left leg, S' LW LV, E' velocity septum and Averege E'.

Conclusions: LV systolic and diastolic dysfunction are found in patients after COA repair.

Keywords: Aortic Coarctation - Left ventricle - Tissue Doppler- 2D Speckle Tracking

ID: 115

Topic: **Cardiovascular Surgery » Congenital Heart Disease**Presentation Type: **Oral****CAVOPULMONARY ANASTOMOSIS IN PATIENTS LESS THAN 3 MONTHS OLD****Mohamed Ismail¹, Ahmed El-mahrouk², Tamer Hamouda³, Ahmed Jamjoom², Mohamed Shihata²**¹*Mansoura University, Mansoura, Egypt*²*King Faisal Specialist Hospital & Research Center, Jeddah, Saudi Arabia*³*Benha University, Benha, Egypt***Corresponding Author (mfismail2299@yahoo.com)**mfismail2299@yahoo.com, a_marouky@hotmail.com, tamerhamoda@yahoo.com, jamjoom_ahmed@hotmail.com, mshihata@gmail.com***Abstract Text**

BACKGROUND: The bidirectional cavopulmonary shunt (BCPS) has become a well-established procedure for the palliation of functionally univentricular hearts. There was a combination of factors not to do BCPS in young infants including, unfavorable results after classic Glenn shunt in babies and uncertainty regarding the reactivity of the pulmonary vasculature in this group of patients.

METHODS: This retrospective study includes all consecutive newborns who underwent Glenn procedure between 2007 and 2017. We will divide them into 2 groups, group A (n=26) who underwent Glenn under 90 days of age, and group B (n=307) more than 90 days.

RESULTS: Age was 57.8±23.3 days in group A and 544.2±128.21 days in group B (p<0.001). Group A had male 22(84.6%) while group B had 178 (58%) (p=0.005). Body weight was also found to be significant 4.67±1.67 kg in group A and 10.26±8.5 kg in group B (p=0.004). Discharge oxygen saturation, time to Fontan, ICU stay and length of stay were not significantly different. Take down Glenn and established BT shunt was detected in one patient (7.69%) of group A, while only one case of group B (0.33%) was taken down (p<0.001). Ten cases of group A had extra-cardiac Fontan (38.46%), and 61 (19.86%) of group B had their Fontan. Early mortality was reported in one patient of group A (3.85%). In group B early mortality occurred in 6 patients (1.96%) with no significance. Late mortality was recorded in 1 patient of group A (3.85%) while 7 patients (2.24%) died during follow up of group B before the age of Fontan.

CONCLUSION: Early Glenn shunt can be done safely in patients less than 3 months of age, with early and late mortality similar to older Glenn patients.

ID: 372

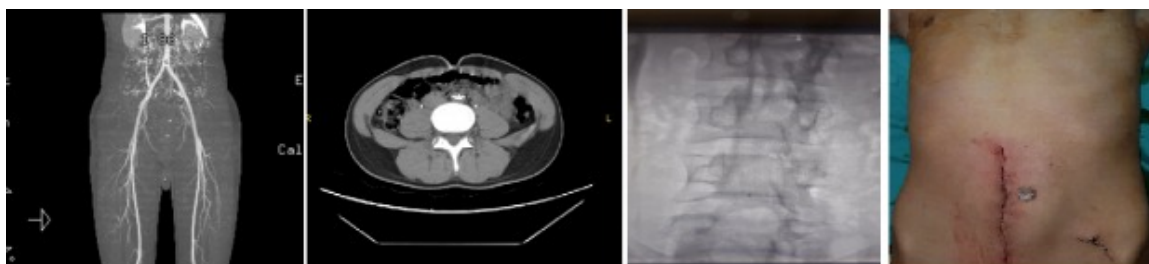
Topic: **Cardiovascular Surgery » Adult Congenital Heart Disease**Presentation Type: **Oral****LATE MIGRATION OF AN AMPLATZER ATRIAL SEPTAL OCCLUDER
TO THE ABDOMINAL AORTA****Esra Ertürk Tekin***Mersin City Training and Research Hospital, Mersin, Turkey***Corresponding Author (dresraer@yahoo.com)**dresraer@yahoo.com***Abstract Text****ABSTRACT:**

Introduction: Transcatheter closure of an atrial septal defect (ASD) with an atrial septal occluder (ASO) is a minimally invasive method that is becoming popular. This method has been increasingly used, and complications have been rare. Most previous reports described the dislocation of the ASO mainly in the right pulmonary arteries or the right atrium. Dislocation of the occluder into the systemic circulation is rare.

Case Presentation: We present a 23-year-old male patient who had an endovascular closure of secundum atrial septal defect 5 years ago. He had experienced a cryptogenic syncope 10 days ago. The occluder was later found in the abdominal aorta. ASO stuck in iliac bifurcation was surgically removed.

Discussion: Although closure of ASD by percutaneous occluder device has a lot of advantages, device embolization is still major complication. Surgical management is the only method to remove embolized devices.

Key words: Atrial septal occluder, Late migration, Cardiovascular Surgery



ID: 165

Topic: Cardiovascular Surgery » Adult Congenital Heart Disease

Presentation Type: Oral

SURGICAL RESCUE OF AN EMBOLIZED ASD CLOSURE DEVICE

Ihsan Bayraktar

Mersin City Training and Research Hospital, Mersin, Turkey

**Corresponding Author (drihsanbayraktar@hotmail.com)*

drihsanbayraktar@hotmail.com

Abstract Text

Surgical Rescue Of An Embolized ASD Clousure Device

Objective: Transcatheter closure of atrial septal defect (ASD) with Amplatzer septal occluder (ASO) is an established, safe, and efficient procedure with high success. Nevertheless device embolization remains to be a major complication that requires immediate intervention for retrieval and correction of the heart defect.

Method: Here we report a case of successful closure of a secundum ASD in a 23-year-old woman by a 30 mm Amplatzer septal occluder (device size/waist diameter)[VM1] which embolized into the main pulmonary artery at 4 hours following the procedure, which caused palpitation and nonsustained ventricular tachycardia. As a result we had to remove the device surgically. Instead of a standard pulmonary artery dissection [VM2] we preferred enter through right atriotomy and carefully pulled the device back which implanted in the main pulmonary artery into the right ventricle. This was followed by removal of the device from the right atriotomy. Following these the atrial septal defect was closed according to standard surgical procedure.

Results: Our approach, which included removal of ASO without dissection of the pulmonary artery, shortened the surgery time and appears to be the safer than pulmonary artery dissection.

Conclusion: Careful consideration should be given to surgical or transcatheter closure of a heart defect life-threatening complications although rare can occur. We recommend the use of these devices only in centers where cardiac surgery support is available. Our approach appears to be a faster and safer method vs. Pulmonary artery dissection.

Key Words: ASD, embolized ASO, surgical removed.

ID: 573

Topic: Cardiology » PI for SHD - ASD,VSD,PDA Closure

Presentation Type: Oral

SHORT AND MID-TERM EFFECTS OF TRANSCATHETER ATRIAL SEPTAL DEFECT CLOSURE TREATMENT ON NUTRITIONAL STATUS, APPETITE, ANTHROPOMETRIC MEASUREMENTS

Ozge Pamukcu, Nazmi Narin, Ali Baykan, Onur Tasci, Nihal Hatipoglu, Suleyman Sunkak, Cagdas Vural, Kazim Uzum

Erciyes University, Kayseri, Turkey

**Corresponding Author (ozgepamukcu2002@yahoo.com)*

ozgepamukcu2002@yahoo.com, nazmi.narin@gmail.com, abaykan@erciyes.edu.tr, dr_onurtasci@hotmail.com, nihalhatipoglu@yahoo.com, suleymansunkak@gmail.com, cagdas_vural@hotmail.com, kazimuzum@erciyes.edu.tr

Abstract Text

Objectives:

The aim was to investigate the changes in nutritional status, growth, symptoms of patients before and after the transcatheter closure of atrial septal defect (ASD).

Method:

The study was prospective and case-control and carried out in our Pediatric Cardiology Clinic. 27 ASD (14 girls, 13 boys) patients (age:12-197 months mean:88.2±58.2) and as control group, 25 healthy subjects (11 girls, 14 boys) (age:10-187 months, mean:67.5±53) were enrolled in the study. Anthropometric measurements (weight and height according to age, Z scores of body mass index (BMI), under the age of 6 years weight according to height and Z scores, over the age of 6 years weight percentage according to height) were performed at hospital admission. WHO Anthro/ AnthroPlus programs were used to evaluate these measurements. The patients' subjective appetite evaluation was performed using a 100 mm long Visual Analog Scale-VAS. Children's Eating Behavior Questionnaire-CEBQ was applied to parents.

Results:

There was no significant difference between the Z scores of the patients anthropometric measurements when compared to the control group ($p>0,05$). The questionnaire asked to parents about appetite, frequency of illness, rapid breathing, fatigue and weight gain. In the ASD group, there was a significant difference in the fast fatigue parameter when compared to the control group ($p =0.013$, 16 vs 6). In the first month, there was a significant increase in the weight according to age and BMI Z scores of the ASD closure patients ($p=0.000$ and $p=0.002$). Before ASD closure 13 patients were defined as anorexia , after the defect closure only 1 patient was defined as anorexia ($p=0.002$). Significant improvement was observed in other symptoms except rapid breathing. In the patient group all measurements showed a significant improvement when compared with first values. A significant increase was observed in terms of weight Z scores according to age and BMI Z scores in the postoperative 1st month ($p=0.000$ and $p=0.005$).

Conclusion:

Nutritional deficiency and growth retardation is an important problem in ASD patients. Treatment of patients should be planned at the appropriate time. Percutaneous ASD closure therapy is evident in the positive effect on nutritional and growth.

ID: 572

Topic: Cardiology » PI for SHD - ASD,VSD,PDA Closure

Presentation Type: Oral

SHORT AND MID-TERM EFFECTS OF TRANSCATHETER VENTRICULAR SEPTAL DEFECT CLOSURE TREATMENT ON NUTRITIONAL STATUS, APPETITE, ANTHROPOMETRIC MEASUREMENTS

Onur Tasci, Nazmi Narin, Ozge Pamukcu, Nihal Hatipoglu, Suleyman Sunkak, Cagdas Vural, Kazim Uzum, Ali Baykan

Erciyes University, Kayseri, Turkey

**Corresponding Author (dr_onurtasci@hotmail.com)*

dr_onurtasci@hotmail.com, nazmi.narin@gmail.com, ozgepamukcu2002@yahoo.com, nihahalhatipoglu@yahoo.com, suleymansunkak@gmail.com, cagdas_vural@hotmail.com, kazimuzum@erciyes.edu.tr, abaykan@erciyes.edu.tr

Abstract Text

Objectives:

The aim was to investigate the changes in nutritional status, growth, symptoms of patients before and after the transcatheter closure of ventricular septal defect (VSD).

Method:

The study was prospective and case-control and carried out in our Pediatric Cardiology Clinic. 20 VSD (13 girls, 7 boys) patients (age: 2-171 months median: 27 months) and as control group, 25 healthy subjects (11 girls, 14 boys) (age: 3-187 months, median: 46 months) were enrolled in the study.

Anthropometric measurements (weight and height for age, Z scores of body mass index (BMI), under the age of 6 years weight for height and Z scores, over the age of 6 years weight percentage for height) were performed at hospital admission. WHO Anthro/ AnthroPlus programs were used to evaluate these measurements. The patients' subjective appetite evaluation was performed using a 100 mm long Visual Analog Scale (VAS). Children's Eating Behavior Questionnaire-CEBQ was applied to parents.

Results:

When the anthropometric measurements of the patients were compared with the control group, the weight for height, BMI and BMI Z scores were significantly higher in the control group ($p=0,016$, $p=0,029$ and $p=0,019$). The questionnaire asked to parents about appetite, frequency of illness, rapid breathing, fatigue and weight gain and results were similar.

In the first month, there was a significant increase in the weight for age z score, weight for height, BMI and BMI Z scores of the VSD closure patients ($p=0,05$ $p=0,048$ $p=0,012$ and $p = 0.018$).

Before VSD closure 9 patients were defined as anorexia, after the defect closure only 2 patient was defined as anorexia ($p=0,099$). Although not statistically significant difference, improvement was observed in other symptoms as well. In the patient group all anthropometric measurements showed improvement in the mid-term when compared with first values, but differences were not statistically significant.

Conclusion:

Nutritional deficiency and growth retardation is an important problem in VSD patients. Treatment of patients should be planned at the appropriate time. Percutaneous VSD closure therapy is evident in the positive effect on nutritional and growth.

Oral Presentation

Minimally Invasive Cardiac Surgery: Shaping the Future

Date: 28.03.2019 Time: 14:15 - 15:15 Hall: 6

ID: 421

Topic: Cardiovascular Surgery » Minimally Invasive and Robotic Cardiac Surgery

Presentation Type: Oral

CONTINUOUS RETROGRADE CARDIOPLEGIA ENSURE SAFE MINIMALLY INVASIVE AORTIC VALVE REPLACEMENT THROUGH THORACOTOMY

Shunsuke Sato, Takashi Azami

Yodogawa Christian Hospital, Osaka, Japan

**Corresponding Author (satosyun@outlook.com)*

satosyun@outlook.com, a104167@ych.or.jp

Abstract Text

Objective

Minimally invasive aortic valve replacement through thoracotomy (MICS AVR) has difficulties due to complication of selective cardioplegic perfusion and difficulty of tie-down of biological valve to aortic annulus. We present a safe approach of MICS AVR using continuous retrograde cardioplegia through anterior thoracotomy. Continuous retrograde cardioplegia allows excellent continuous homogenous cooling of the heart during the ischemic period. Anterior thoracotomy facilitates cannulation of ascending aorta, and allows our all manipulations using the fingertips without the aid of a knot pusher or long-shafted surgical instruments.

Method

We entered thoracic space through anterior 3rd intercostal space with resection of 4th costal cartilage, and resection of 3rd costal cartilage if aortic cannulation was required.

Cardiopulmonary bypass was established with the femoral artery /or the ascending aorta, and the right femoral vein and inferior vena-cava. After clamping of ascending aorta, right atrium was opened and continuous retrograde cardioplegia was administered through a coronary sinus cannula.

We performed MICS AVR using this method in 5 patients between June 2018 and November 2018. There were 3 women. Median age of patients was 71 years (range: 43–77 years). Femoral artery cannulation was performed in 2 cases, and ascending aorta in 3 cases. Two patients required ascending aortic cannulation had shaggy descending aorta, and one patient had severe atherosclerosis obliterans. One patient required patch plasty of Valsalva sinus because of severe calcification on ascending aorta.

Results

There was no patient requiring defibrillation or extra weaning time after declamping of aorta. Knot-pushers were not required.

Extubation in operative theater was in 2 patients. Hospital stay was 8-14 (median 12) days after operation. There was no hospital death.

Conclusion

MICS AVR using continuous retrograde cardioplegia is a safe technique.

ID: 10

Topic: Cardiovascular Surgery » Minimally Invasive and Robotic Cardiac SurgeryPresentation Type: **Oral****INFRA-AXILLARY MINI-THORACOTOMY FOR AORTIC OR DOUBLE VALVE REPLACEMENT AND AORTOPLASTY FOR MODERATELY SIZED DILATATION OF ASCENDING AORTA.****Mahmut Akyildiz, Ahmet Refik Turgut, Taner Şerif Taner Şerif Küçükcerit, Noyan Temuçin Oğuş***Medistate Kavacık Hospital, Istanbul, Turkey***Corresponding Author (ahmetrt@hotmail.com)**ahmetrt@hotmail.com, ahmetrt@hotmail.com, ahmetrt@hotmail.com, ahmetrt@hotmail.com***Abstract Text****BACKGROUND AND AIM:**

We prefer right infra-axillary mini-thoracotomy (RIAMT) for minimally invasive aortic or mitral or double valve replacement. Its cosmetic superiority over standard sternotomy was apparent, and remoteness from the ascending aorta was compensated for by using long-shafted minimally invasive instruments. Meanwhile, if aortic dilatation is moderate (<45 mm diameter) and another minimally invasive cardiac valve procedure (aortic or double valve replacement) is being performed and patient is not marfanoid, we have concomitantly reduced the diameter of the ascending aorta with a longitudinal J-shaped incision by this right infra-axillary mini-thoracotomy technique.

METHODS:

Between July 2012 and July 2018, we have performed 315 operations using this approach. Aortic valve replacement group of this study has included 130 patients, double valve replacement group of this study has included 35 patients and 56 aortoplasty were performed.

Surgical technique:

The right thorax was opened via a small, vertical right axillary skin incision and a third intercostal thoracotomy was performed. Cardiopulmonary bypass was established through the right femoral artery and bicaval venous cannulation. The ascending aorta was clamped with flexible clamp. All sutures, for prosthetic valve seating, were tied down with the aid of a knot pusher. Other minimally invasive long shafted instruments were also utilized.

RESULTS:

As concomitant procedures, annular patch enlargement was performed in five patients, right coronary artery bypass grafting in two (totally in six) and mitral valve repair in one (totally in nineteen) patients. The length of skin incision was 8.5±0.5 cm for a double valve procedure. No case was converted to sternotomy. Between 1 and 72 months of follow-up, there were 5 (3.87%) (totally 1.58%) in-hospital mortality, and 2 long-term mortality, all the other patients were alive, and no valve-related complications were observed. The mean age was 50±9 (range, 15-77) years, of which 160 (50.79%) were female (57 % in mitral group). 61 patients had rheumatic complex valve diseases as the predominant lesion in aortic valve replacement group, 7 patients had bicuspid valve, and 29 patients had isolated aortic valve insufficiency.

CONCLUSIONS:

This approach offers multiple advantages including cosmetic superiority, and facilitates direct access to the rib-cage by cutting only skin and subcutaneous fat. Despite these advantages, the ascending aorta is relatively distant compared with fore-chest thoracotomy or partial sternotomy. This procedure may carry a potential risk of stroke associated with retrograde perfusion through the femoral artery, this approach is limited by the longer cross-clamp and cardiopulmonary bypass times, which have raised some concerns in fragile, and high risk patients.

Keywords: Infra-axillary, mini-thoracotomy, aortic and double valve replacement, aortoplasty

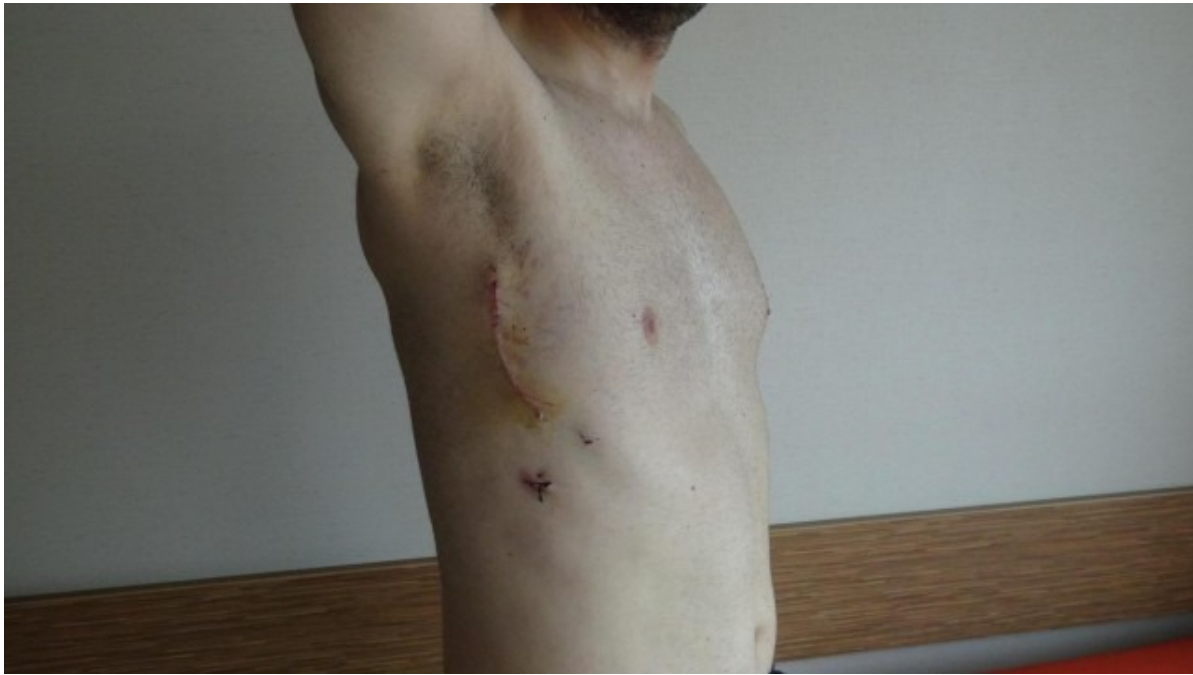

Figure - 1: Infra-axillary mini-thoracotomy

Table 1: Infra-axillary mini-thoracotomy for aortic and double valve replacement andaortoplasty		
Aorticvalve replacement (AVR)	49	37.70 %
AVR+ Aortoplasty	41	31.55 %
AVR+CABGX1(SV-RCA)	2	1.53 %
AVR+ Mitral Ring Annuloplasty	1	0.76 %
AVR+ Mitral valve replacement (MVR)	20	15.40 %
AVR+ MVR + Aortoplasty	15	11.53 %
Triplevalve replacement	2	1.53 %
.	Total 130 / 315 patients	100 %
(mitral and tricuspid valve replacements: 9)		

ID: 303

Topic: Cardiovascular Surgery » Minimally Invasive and Robotic Cardiac SurgeryPresentation Type: **Oral****MINIMALLY INVASIVE AORTIC VALVE REPLACEMENT WITH CENTRAL CANNULATION: A MINIMALLY INVASIVE METHOD TO OVERCOME LIMITED RESOURCES.****Mohammed Sanad***Mansoura University, Mansoura, Egypt***Corresponding Author (mohammedsanad2008@yahoo.com)**mohammedsanad2008@yahoo.com***Abstract Text**

Objective: With Development of Less invasive approaches to aortic valve surgery (MIAVR), they are becoming more technically and logistically demanding. However, in some developing countries, few centers have started using these approaches with standard equipment and as a routine method. We sought to intervene intraoperative and post-operative clinical outcomes after MIAVR.

Methods: From June 2015 to present, a total of 48 patients had underwent isolated aortic valve surgery, via upper Inverted T upper hemisternotomy in Mansoura University Hospital and Nasser Institute for research and treatment, Egypt. Central cannulation and equipment were used in all cases. Cases with heavy calcifications with included. Major adverse cardiac events were compared to standard Aortic Valve replacement.

Results: Exposure and feasibility for cannulation were assessed. The mean length of skin incision was 5.1 ± 0.7 cm. one In-hospital mortality was recorded. However, 24-hour mediastinal drainage was comparable to standard median sternotomy approach. Fewer patients received transfusions. Early after operation, pain scores were lower after MIAVR and shorter postoperative length of stay shorter.

Conclusions: With lack of logistics and equipment in developing countries, MIAVR not only remains a cosmetic advantage, but a significant reduction of blood product use, respiratory, pain, and resource utilization advantages over full sternotomy with no changes in equipment. MIAVR can be feasible, safe and easily educable method with a rapid learning curve in low resources areas.

ID: 414

Topic: Cardiovascular Surgery » Minimally Invasive and Robotic Cardiac SurgeryPresentation Type: **Oral****AORTIC VALVE NEOCUSPIDIZATION WITH GLUTARALDEHYDE-TREATED AUTOLOGOUS PERICARDIUM VIA J-MINISTERNOTOMY: SHORT-TERM SINGLE-CENTER OUTCOMES****Evgeny Rosseykin, Evgeny Kobzev***Federal State Institution , Khabarovsk, Russia***Corresponding Author (rosseykin@mail.ru)**rosseykin@mail.ru, kobzeffsurg@mail.ru***Abstract Text**

BACKGROUND. Aortic valve replacement (AVR) using prosthesis remains the gold standard in the treatment of aortic valve disease. However, a search for new surgical techniques is currently ongoing, which makes it possible to avoid the need to take anticoagulants, which reduce the risk of infection of the prosthesis and improve postoperative survival. One such technique is aortic valve neocuspidization with glutaraldehyde-treated autologous pericardium (Ozaki procedure). Currently, minimally invasive AVR became a standard of care in many centers. The mini-invasive approach was developed as an alternative to AVR from a complete sternotomy. This technique has been developed to reduce the surgical injury and have a number of advantages in hospital outcomes than full sternotomy. We evaluated our experience using mini-access for the Ozaki procedure.

METHODS. In this retrospective single-centre study, we evaluated 33 consecutive patients who underwent Ozaki procedure via J-ministernotomy between March 2016 and November 2018. There were 17 patients with aortic stenosis, 9 with aortic regurgitation, 7 with aortic stenoregurgitation, 4 with infective endocarditis. 19 patients had tricuspid aortic valve, 13 patients had bicuspid valve, 1 had unicuspid valve. The median age was 54 (range, 14-76). There were 21 male and 12 female patients. Preoperative echocardiography revealed a peak pressure gradient average of 75 ± 23 mmHg and a mean pressure gradient of 43 ± 15 mmHg. Surgical annular diameter was 24.0 ± 4.2 mm. The primary endpoints were early death and major adverse cardiac and cerebrovascular events; the secondary end points were freedom from reoperation and overall mortality.

RESULTS. Mean cross-clamp and cardiopulmonary bypass times were 116 ± 23 and 150 ± 35 min, respectively. There were no conversions to full sternotomy or to a prosthetic valve replacement. Early outcomes included 1 death due to myocardial infarction. During follow-up (mean 23 ± 11 months) one patient died of non-cardiac reason and one patient needed reoperation due to tear of noncoronary cusp. Postoperative echocardiography revealed a peak pressure gradient average of 9.2 ± 5.7 mmHg 1 week after the procedure and 10.1 ± 5.3 mmHg 23 ± 11 months after the procedure.

CONCLUSIONS. Ozaki procedure can be safely conducted through a partial J-ministernotomy with good short-term clinical outcomes and neo-valve haemodynamics. However, long-term follow-up in a larger cohort is warranted to assess the durability of the neo-valves.

ID: 423

Topic: Cardiovascular Surgery » Minimally Invasive and Robotic Cardiac SurgeryPresentation Type: **Oral****EARLY OUTCOMES OF MINIMALLY INVASIVE LAD REVASCULARIZATION VS PCI IN RANDOMIZED CLINICAL TRIAL****Vadim Popov**, Egor Malysenko, Maxim Novikov, Giorgiy Edzhibiya, Amiran Revishvili*A.V. Vishnevsky National Medical Research Center of Surgery, Moscow, Russia***Corresponding Author (la4ge@yandex.ru)**la4ge@yandex.ru, la4ge@yandex.ru, la4ge@yandex.ru, la4ge@yandex.ru, la4ge@yandex.ru***Abstract Text****BACKGROUND:** To evaluate in-hospital results of prospective RCT ENPILA (EndoACAB vs PCI for LAD Revascularization)**METHODS:** Our prospective RCT includes 100 patients. Inclusion criterion is isolated critical LAD lesions, suitable for either EndoACAB, or PCI revascularization. EndoACAB (Endoscopic-Assisted Coronary Artery Bypass) consists of harvesting IMA with endoscopic techniques and LAD direct vision anastomosis formation through the anterolateral minithoracotomy 3-4 cm length using myocardium stabilizer. There are 2 groups, 50 patients each. 1st group includes patients, who underwent LAD EndoACAB procedure. 2nd group includes patients, who underwent PCI to LAD. Postoperative check points in both groups evaluated in 24 and 48 weeks. To evaluate the adequacy of myocardial revascularization primal endpoints were analyzed, including major adverse cardiovascular events (MACE), such as death, non-lethal MI, recurrent revascularization; and secondary endpoints: conversion, bleeding in perioperative period, pain, quality of life. This trial includes 52 patients by far, 1st group includes 25 patients and 2nd group includes 27 patients.**RESULTS:** In 1st group EndoACAB procedure was successfully performed in all patients (100%) from the 1st group. In PCI group no complications have also occurred. There were no significant difference in primary and secondary endpoints during in-hospital period in both groups. All patients in early in-hospital period underwent coronarangiography and shuntography. Incomplete myocardial revascularization, technical difficulties and other complications weren't detected.**CONCLUSION:** Minimally invasive endoscopic-assisted myocardial revascularization results were comparable to the PCI results during in-hospital period.

ID: 476

Topic: Cardiovascular Surgery » Minimally Invasive and Robotic Cardiac SurgeryPresentation Type: **Oral****VIDEO-ASSISTED THORACOSCOPIC SURGERY FOR MANAGEMENT OF OPERATION COMPLICATIONS OF ROBOTIC HEART SURGERY****Murat Akkuş***Istanbul Mehmet Akif Ersoy Thoracic and Cardiovascular Surgery Training and Research Hospital, İstanbul, Turkey***Corresponding Author (akkusmdr@gmail.com)**akkusmdr@gmail.com***Abstract Text**

Objective: Robotic heart surgery is gaining popularity as a minimally-invasive intervention among cardiovascular surgeons. It may not always be possible to resolve some complications due to limited maneuverability of the instruments during or after robotic operations and open surgery may be required. We aimed to present the use and outcomes of video-assisted thoracoscopic surgery (VATS) for complications of robotic heart surgery.

Methods: From May 2013 to June 2018, a total of 429 cases were robotically operated in our hospital, 186 patients for ASD, 110 patients for mitral valv procedures and 133 patients for robotically-assisted coronary bypass grafting operations. Due to development of complications, 12 cases (2.79%) had VATS performed; these were 6 males and 6 females with mean age of 40.41 (25-56) years. Cases had VATS performed due to peroperative foreign body falling into the thorax (needle) for 2 cases, tamponade in 1 case, laceration of pulmonary parenchyma for 1 case, hemorrhage in 4 cases and hematoma in 4 cases.

Results: All cases were performed via 3 portal thoracoscopy using the port placement used before robotic surgery and with no additional port incision. Cases for foreign bodies were removed at the end of the robotic surgery by VATS. The lung parenchyma laceration case, tamponade case and 4 hemorrhage cases were performed on the 1st day in postoperative period. Two out of 4 the hematoma cases were underwent VATS procedure on the postoperative 2nd day, 1 case on the 3rd day and 1 case on the 4th day respectively. The case underwent for VATS due to tamponade was identified the left atrial hemorrhage and the atrial wall was sutured; however, sternotomy was performed due to hemodynamic instability. The lung parenchyma laceration case was repaired primary suturing. Who underwent VATS procedure due to hemorrhage had identified from the intercostal vascular bleeding in all 4 cases and the bleeding control were obtained with electrocautery. The cases underwent for operation due to hematoma could have determined no hemorrhage foci and leakage was considered linked to anticoagulant therapy. All hematoma cases were performed drainage. The length of hospital stay for cases were 5.3 (3-8) days. Additional complications were not observed in cases and there was no mortality.

Conclusions: VATS is safe and feasible method to resolve complications of robotic heart surgery. It provides satisfactory outcomes with comfortable and aesthetic surgery by reducing the requirements for open surgery

ID: 265

Topic: Cardiovascular Surgery » Minimally Invasive and Robotic Cardiac SurgeryPresentation Type: **Oral****INTRACARDIAC FOREIGN BODY REMOVAL IN FEMALE PATIENTS:
SUBMAMMARIAN ANTERIOR THORACOTOMY IS A COSMETIC
OPTION****Rukiye Derin Atabey, Yigit Akcali***Erciyes University, Kayseri, Turkey***Corresponding Author (rukiyeatabey@hotmail.com)**rukiyeatabey@hotmail.com, yigitakcali@gmail.com***Abstract Text**

OBJECTIVE. The cardiac injuries due to foreign bodies may be iatrogenic or accidental. Recently the incidence of iatrogenic cardiac injuries has increased due to more availability in the field of catheter-based diagnostic and therapeutic procedures. Iatrogenic foreign body injuries to heart can be removed either through a surgical or percutaneous approach. Open-heart surgery, usually performed via a median sternotomy, will be unavoidable when the non-surgical retrieval of the foreign body is not possible. In these cases, sternotomy wound can cause serious cosmetic problems especially in women. We therefore performed a right submammary anterior thoracotomy for better cosmesis during surgical removal of an intracardiac foreign body.

CASE REPORT. A 21-year-old female patient consulted for difficulty in removing the guide wire during the insertion of a central venous catheter in the emergency department where she presented because of kidney problems following pregnancy. A physical examination revealed relatively stable vital signs, except for mild tachycardia (blood pressure, 115/ 80 mmHg; heart rate, 106 bpm; respiratory rate, 24/min). A guide wire of central venous catheter, which oscillates with systole, was identified in her neck (Video 1). An urgent chest X-ray and fluoroscopy revealed an image of this guide wire extending towards to heart shadow. There was no pericardial fluid accumulation and any sign of contrast extravasation in echocardiography. In addition, echocardiographic exam revealed that the tip of the guide wire was entrapped by tricuspid valve. However, there was no tricuspid regurgitation. When the guide wire was wanted to retreat, the valve was moving, too. The tip of the guide wire was interpreted as anchored to the valve, and its percutaneous retrieval would be challenged and complicated. An open-heart surgery was planned to remove the guide wire. Cardiopulmonary bypass was established via a submammary incision with anterior thoracotomy (Figure 1). A right atriotomy incision was made, and the guide wire anchored to tricuspid septal leaflets was removed without damage to the valve. Postoperative recovery was uneventful.

CONCLUSIONS. A right submammary anterior thoracotomy through fourth intercostal space gives best exposure for the foreign bodies in the right chambers of heart, and its postoperative wound healing is uneventful with better cosmetic results.

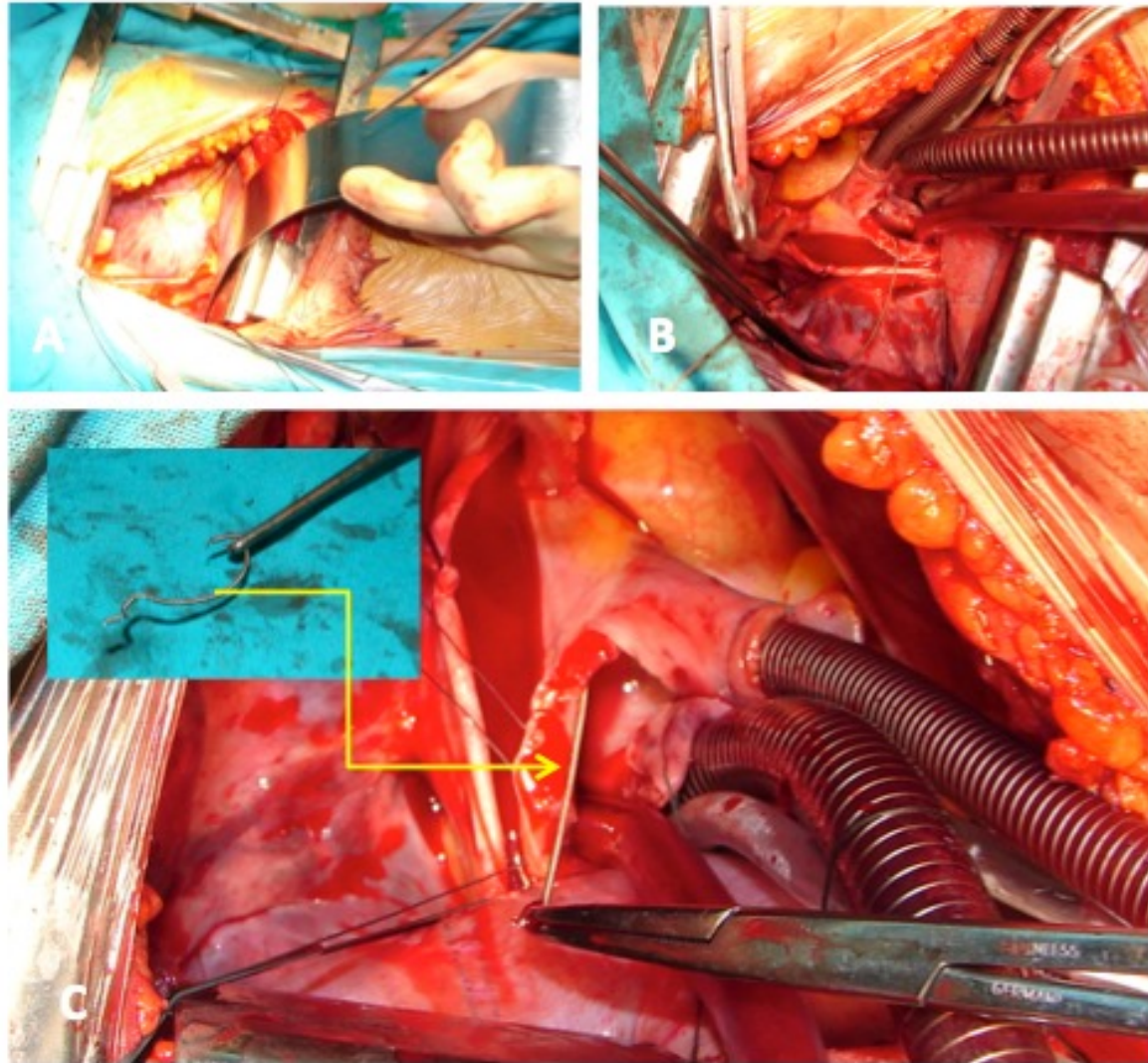


Figure 1. Establishing cardiopulmonary bypass via a minimized anterior thoracotomy (A, B). Removal of the anchored guide-wire without damage to the valve; small picture shows the tip of guide-wire (arrow) (C).

Oral Presentation**Aortic Dissection: An Urgent Need for Success**

Date: 28.03.2019 Time: 15:15 - 16:15 Hall: 6

ID: 462**Topic: Cardiovascular Surgery » Thoracic and Thoracoabdominal Aortic Dissections and Aneurisms****Presentation Type: Oral****RESULTS OF FALSE LUMEN STATUS OF DIFFERENT METHODS FOR AORTIC ARCH TREATMENT IN STANFORD A AORTIC DISSECTION****Qing Zhou, Yunxing Xue, Dongjin Wang***The Affiliated Drum Tower Hospital of Nanjing University Medical School, Nanjing, China***Corresponding Author (qingzhou_gl@163.com)**qingzhou_gl@163.com, albert_xue@163.com, dongjinwang_gl@163.com***Abstract Text**

Background: Different methods are applied for aortic arch treatment in Stanford A aortic dissection, but it's lack of long term results of false lumen status of different methods. This retrospectively study will analyze the effect of the false lumen status of different methods in a single center.

Methods: From January 2010 to December 2015, 139 cases(of which 108 males and 31 females) were finally selected after excluding the cases who died during hospitalization, whose perioperative clinical data were incomplete, follow-up information were incomplete, and DeBakey type II aortic dissection and the cases with descending aorta dilatation. The average age was 50.3 ± 11.6 years (22-76 years). According to the methods for aortic arch and descending aorta, 139 cases were divided into 5 groups: 24 cases in AR((including ascending aorta replacement, ascending aorta + hemi-arch replacement and ascending aorta + island-arch replacement), 9 cases in AR+SET(including ascending aorta + hemi-arch replacement + stent elephant trunk and ascending aorta + island-arch replacement + stent elephant trunk), 42 cases in Arch+SET(ascending aorta + arch replacement + stent elephant trunk), 22 cases in AR+ TBS(ascending aorta + triple branched stent) and 42 cases in AR+FS(ascending aorta + arch fenestrated stent). Statistical analysis the size of true lumen and the status of false lumen among these five groups in the level of aortic arch, the distal end of stent, diaphragm, celiac artery, renal artery and iliac artery postoperatively.

Results: Different levels of descending aorta in each group have showed varying degrees of true lumen open and thrombosis of false lumen during follow-up period. Among them, cases with aortic arch treatment and stent implantation have showed higher ratio of thrombosis of false lumen.

Conclusions: Effects of different stents were similar, which all promoted the process of thrombosis of false lumen.

ID: 252

Topic: Cardiovascular Surgery » Thoracic and Thoracoabdominal Aortic Dissections and AneurismsPresentation Type: **Oral****RESULTS OF SURGICAL TREATMENT OF TYPE A AORTIC DISSECTION**Azman Ateş, **Ümit Arslan**, Eyupserhat Çalık, Yahya Ünlü*Atatürk University, Erzurum, Turkey***Corresponding Author (kvcumit@gmail.com)**azmanates@atauni.edu.tr, kvcumit@gmail.com, eyupserhatcalik@hotmail.com, yahyaunlu@hotmail.com***Abstract Text**

Objective: In this retrospective study, we aimed to present the results of surgical treatment of type A aortic dissections.

Methods: The study included 68 patients who were diagnosed with type A aortic dissection and underwent surgery treatment between 2000 and 2018. The diagnosis was based on clinical examination, telecardiography, transthoracic echocardiography and computerized tomography. Type of operation and time of mortality and mortality rates were recorded. Retrograde and antegrade coronary cardioplegic perfusion were used in all patients for myocardial protection.

Results: The study consisted of 68 patients (male/female, 40/28) with a mean age of 57.53±13.3 years (min-max: 29-80). According to anatomical involvement of the aorta, 40 (58.9%) patients had Type I and 28 (41.1%) patients had Type II aortic dissection. Hypothermic total circulatory arrest (16 0C) was used in 30 patients. Bentall modifications, especially Flanged technique was performed to 15 patients and aortic valve resuspension was performed to 20 patients. Cumulative mortality rate was 32.3% (22/68). 20 patients died in the first month and general causes of death were low cardiac output syndrome, bleeding and cerebrovascular events. one case died because of gastrointestinal bleeding on day 53rd, an one patient died due to intracerebral hemorrhage on day 75th.

Conclusion: acute aortic dissections should be operated with acceptable risk. We suggest that the aortic root, aortic valve and coronary arteries should be evaluated in detail before ascending aorta replacement is performed.

ID: 120

Topic: Cardiovascular Surgery » Thoracic and Thoracoabdominal Aortic Dissections and AneurismsPresentation Type: **Oral****PULSATION ARTEFACT: A RIDDLING CAUSE OF MISDIAGNOSIS DURING MANAGEMENT OF THORACIC AORTIC DISSECTION.****Macit Bitargil***Şişli Hamidiye Etfal Research and Training Hospital, İstanbul, Turkey***Corresponding Author (mctbtr@hotmail.com)**mctbtr@hotmail.com***Abstract Text**

Acute traumatic injury of the thoracic aorta is a highly lethal condition. It most often occurs following a high- speed motor-vehicle accidents. The thoracic aortic injury is the second most common cause of death in blunt trauma patients. Contrast-enhanced computed tomographic (CT) angiography of the chest and transesophageal echocardiography (TEE) are the main imaging modalities for diagnosing blunt aortic injury. Although each of these has high sensitivity for this injury there is always a possibility of misdiagnosis. The ‘pulsation artefact’ is the most common cause of misdiagnosis while reading the CT. It is caused by pulsatile movement of the ascending aorta during the cardiac cycle between end-diastole and end-systole. Here we are presenting a case of “pulsation artefact” that misled the surgical team. An 70-year-old female patient was admitted with symptoms of epigastric pain following a high- speed motor vehicle accident. CT showed a flap on ascending aorta and the diagnosis of dissection was confirmed by radiology department. Emergent surgical repair of the ascending aorta was recommended by the surgical team, but during the operation the external appearance of the ascending aorta was normal so the surgical procedure was terminated. Since the Control CT was normal the previous suspicious flap on first CT was considered as “pulsation artefact”. Patient is discharged in a good condition after 3 days following surgery. In conclusion a “pulsation artefact” may mislead the surgical team and should be kept in mind.

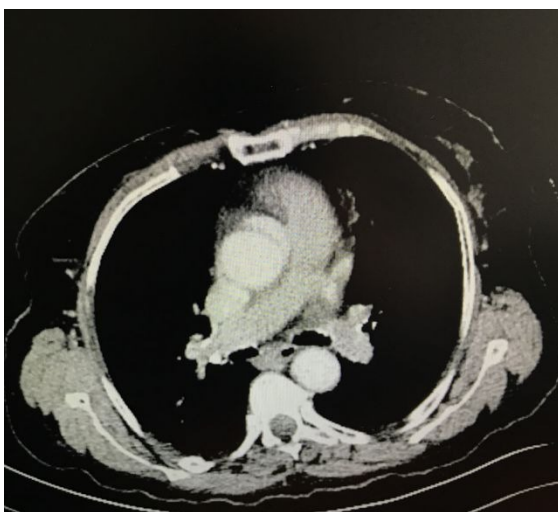


Figure 1: Contrast-enhanced computed tomographic angiography of the chest shows the misleading flap like pulsation artefact in the ascending aorta.

ID: 54

Topic: Cardiovascular Surgery » Thoracic and Thoracoabdominal Aortic Dissections and AneurismsPresentation Type: **Oral****COMPARISON OF EARLY RESULTS OF PATIENTS WITH AND WITHOUT AORTIC VALVE INTERVENTION IN ACUTE TYPE A AORTIC DISSECTIONS**

Selim Aydin¹, Bahar Temur¹, Mutlu Senocak², Ismail Yucesin Arslan², Mehmet Yilmaz², Tamer Kehlibar², Mehmet Fikri Yapici³, Azmi Ozler³

¹*Acibadem Mehmet Ali Aydinlar University Atakent Hospital, Istanbul, Turkey*

²*Dr. Siyami Ersek Thoracic and Cardiovascular Surgery Training and Research Hospital, Istanbul, Turkey*

³*Memorial Atasehir Hospital, Istanbul, Turkey*

**Corresponding Author (selim.aydin@acibadem.edu.tr)*

selim.aydin@acibadem.edu.tr, bahar.temur@acibadem.edu.tr, mutlusenocak@yahoo.com, dryucesin@yahoo.com, drmehmetyilmaz@gmail.com, tamerkehlibar@gmail.com, fikri.yapici@gmail.com, azmi.ozler@memorial.com

Abstract Text**Objectives:**

In this study, we compared the results of early morbidity and mortality between patients with acute type A aortic dissection who received only supracoronary ascending aortic replacement with and without valve intervention.

Patients and Methods:

A total of 147 patients who were operated due to acute type A aortic dissection in our hospital between January 2003 and November 2011 were included in this study. Ninety-three patients underwent supracoronary ascending aortic and hemiarch replacement without intervention to the aortic valve (group 1), and aortic valve resuspension or valve replacement in addition to 54 patients (group 2). Patients' demographic and preoperative data, perioperative and first 30 day morbidity and mortality rates were compared.

Results:

The ages of the patients were $58,79 \pm 11,59$ years in group 1 and $51,89 \pm 13,30$ years in group 2 ($p=0,0005$). The time from application to operation was statistically higher in group 1 ($p=0,001$). As the operation data, the duration of operation was significantly higher in group 2 ($p=0,030$) and the antegrade cerebral perfusion usage was statistically higher in group 1 ($p=0,034$). Twenty-three patients (24,73%) in group 1 and 22 patients (40,74%) in group 2 were died. The first 30-day mortality rate was statistically higher in group 2 ($p=0,043$). There are no statistically difference in other parameters.

Conclusion:

If there is no organic pathology in the native valve and the aortic root is not very large, supracoronary aortic replacement can be performed without intervention to the valve regardless of the degree of valve insufficiency due to dissection.

ID: 503

Topic: Cardiovascular Surgery » Thoracic and Thoracoabdominal Aortic Dissections and Aneurisms

Presentation Type: Oral

THE TIMING OF SURGERY FOR TYPE I AORTIC DISSECTION

Mustafa Dađlı, Ahmet Nihat Baysa

University Of Health Sciences Konya Education And Research Hospital, Konya, Turkey

**Corresponding Author (drmustafaaaa@gmail.com)*

drmustafaaaa@gmail.com, anbaysal@hotmail.com

Abstract Text

OBJECTIVE,

Surgery for type 1 oartic dissection should be conducted emergently; however, night surgeries require additional capacity and negatively affect next day surgeries. Therefore, we operate on patients admitted at night on the next morning if they have no critical complications.

METHODS,

Between January 2016 and January 2019, 22 patients undergoing surgery for type 1 oartic dissection were evaluated. We retrospectively evaluated our strategy for such cases to ensure successfull treatment and sufficient capacity for accepting new critical cases. The operative outcomes were compared between the emergency surgery group (n:16) , including patients receiving surgery immediately after arrival, and the urgent surgery group (n:6) , including cases receiving surgery on the next morning.

RESULTS,

No difference in the ascending aorta diameter, ratio of those with and without false lumen thrombosis, and operative procedure was observed between the groups. the operative mortality was 50% for emergency group (8/16 patient) and 33% for the urgent surgery group (2/6 patient).

CONCLUSIONS

The findings indicate that patients who are admitted at midnight can be successfully treated by surgery performed on the next morning if they do not have any critical complivations or remarkable computed tomography findings.

ID: 464

Topic: Cardiovascular Surgery » Thoracic and Thoracoabdominal Aortic Dissections and AneurismsPresentation Type: **Oral****ROOT MANAGEMENT STRATEGY IN STANFORD A AORTIC DISSECTION****Dongjin Wang**, Qing Zhou, Yunxing Xue, Jun Pan*The Affiliated Drum Tower Hospital of Nanjing University Medical School, Nanjing, China***Corresponding Author (dongjinwang_gl@163.com)**dongjinwang_gl@163.com, qingzhou_gl@163.com, albert_xue@163.com, xyxkakashi@163.com***Abstract Text**

Background: There is no standard method for root management in Stanford A aortic dissection (TAAD) involving the aortic root. We retrospectively observed the results of different surgical methods for TAAD patients and analyzed the risk factors of aortic insufficiency (AI) and aortic dilation in the midterm follow-up period.

Methods: The clinic data of 351 acute Stanford A aortic dissection patients received surgical therapy at Department of Thoracic and Cardiovascular Surgery, Nanjing University Medical School Affiliated Nanjing Drum Tower Hospital from January 2008 to December 2015 were analyzed retrospectively. There were 272 male and 79 female patients, aging from 22 to 83 years with a mean age of (52±13) years. According to root size, aortic valve structure and the status of dissection involvement, these patients were divided into three major groups: 218 cases with root reconstruction using Dacron felts, 34 cases with root reconstruction concomitant with aortic valve resuspension repair and 99 cases in with Bentall procedure. Proper shape based on the status of dissection involvement of Dacron patch was cut and put between the middle and outlayer of aorta, then inside the inner layer one band Dacron felt was sutured with the aorta and the new middle layer with Dacron patch as mentioned above. In some cases the prolapsed aortic valve were re-suspended to the aortic cusp. Clinical outcomes among the 3 procedures were compared by χ^2 test and analysis of variance.

Results: Cross-clamp, cardiopulmonary bypass, and circulatory arrest times of all the patients were (250±78), (171±70) and (31±10) minutes, respectively. The 30-day mortality was 9.2% (33/351), while no difference among the 3 procedures (9.6%, 8.8% and 9.1%). In the average follow-up time of (26±23) months (range from 0.5 to 90.0 months), survival rates were similar among the 3 procedures (77.7%, 77.4% and 77.8%). Only one patient received redo Bentall procedure because of severe aortic regurgitation and dilated aortic root (50 mm).

Conclusions: The indication of root management of acute Stanford A aortic dissection is based on the diameter of aortic root, structure of aortic leaflets, and the dissection involvement. For most acute Stanford A aortic dissection patients, aortic root reconstruction is a feasible and safe method.

ID: 480

Topic: Cardiovascular Surgery » Thoracic and Thoracoabdominal Aortic Dissections and AneurismsPresentation Type: **Oral****AORTIC ARCH REPLACEMENT IN ACUTE TYPE A AORTIC DISSECTION: IS IT TIME TO CHANGE PARADIGM?****Igor Vendramin, Daniela Piani, Andrea Lechiancole, Veronica Ferrara, Matteo Meneguzzi, Sandro Sponga, Ugolino Livi***S. Maria della Misericordia University Hospital, Udine, Italy***Corresponding Author (igor.vendramin@asuiud.sanita.fvg.it)**igor.vendramin@asuiud.sanita.fvg.it, danielapiani89@gmail.com, andrea.lechiancole@asuiud.sanita.fvg.it, danielapiani89@gmail.com, matteo120387@gmail.com, sandro.sponga@asuiud.sanita.fvg.it, ugo.livi@asuiud.sanita.fvg.it***Abstract Text****Background and aim**

Despite in-hospital mortality from IRAD remains high recent reports show a trend towards a more extensive arch surgery for patients presenting with type A acute aortic dissection (TA-AAD). Our study aimed to evaluate the impact of an aggressive arch surgery on short and mid-term outcomes in the modern era.

Methods

Three hundred and thirty-one patients with TA-AAD were admitted at our Institution between 1977-2017. They were divided into 3 groups according to the surgical strategy: GROUP-A: retrograde femoral artery perfusion and deep systemic hypothermia (1977-2004; n=142), GROUP-B: standard antegrade right axillary artery perfusion and moderate hypothermia (2005-2012; n=102), GROUP-C: right axillary artery perfusion with modified intraoperative setting and moderate hypothermia (2013-2017; n=87). Data was collected and analysed retrospectively.

Results

Overall in-hospital mortality: 34.7% in Group-A (mean-age 61.5±12.5years), 13.7% in Group-B (mean-age 63.8±12.8years) and 5.6% in Group-C (mean-age 64.2±11.1years) (p<0.01). Concerning total arch replacement, in-hospital mortality in Group-C vs Group-B decreased significantly (0% vs 20%, p<0.01). Overall 1-year and 5-years survival was 56.3±4.1% and 47.9±4.2% in Group-A, 79.4±4% and 69.6±4.6% in Group-B, 89.5±3.3% and 87.5±3.8% in Group-C (p=0.001, p=0.03 B vs C). In the arch replacement subset overall 5 years survival was 97%±3 in Group-C (p=0.03 arch vs emiarch). Group (p=0.001), CEC-time (p=0.003), re-exploration (p=0.001) and AKD (p=0.049) were predictors for in-hospital mortality in a univariate analysis; re-exploration (HR 4.2) in a multivariate analysis, Group was protective factor (HR=0.25).

Conclusions

In our experience current intraoperative and post-operative management seem to decrease the risk of in-hospital mortality and to improve mid-term overall survival. Better survival was demonstrated in total arch replacement group, especially in long-term follow-up, thus justifying a more aggressive surgical approach in younger patients.

ID: 461

Topic: **Cardiovascular Surgery » Thoracic and Thoracoabdominal Aortic Dissections and Aneurisms**

Presentation Type: **Oral**

CLINICAL OUTCOMES OF ATAAD PATIENTS MIMICS ACS WITH PREOPERATIVE ORAL ANTI-PLATELET THERAPY

Yunxing Xue, Qing Zhou, Dongjin Wang

*The Affiliated Drum Tower Hospital of Nanjing University Medical School, Nanjing, China***Corresponding Author (albert_xue@163.com)**albert_xue@163.com, qingzhou_gl@163.com, dongjinwang_gl@163.com***Abstract Text**

Background: Acute Stanford type A aortic dissection(aTAAD) is often misdiagnosed as acute coronary syndrome(ACS), anti-platelet therapy for ACS will influence the timing and outcome of aTAAD. We reviewed the surgical outcome of these misdiagnosed aTAAD patients.

Methods: From January 2011 to October 2015, 309 aTAAD patients have received surgical therapy in our department, among them 15 patients had misdiagnosed as ACS and taken oral anti-platelet therapy. We retrospectively reviewed the data of perioperative and follow-up period.

Results: The average age was 60.6±8.7 years old of these 15 patients(9 male, 6 female). 5 patients took orally aspirin, 10 took aspirin and clopidogrel. 2 patients had received operation 7 days after stopping the agents, 3 days for 3 patients, 1 day for 1 patient, and the other 5 patients received emergency operation without stopping the agents. The cardiopulmonary bypass time was 259.7±64.8 minutes, aortic cross-clamp time was 181.0±51.7 minutes, and selective cerebral perfusion and lower body arrest time was 34.9±8.1 minutes. There were 2 in-hospital deaths due to circulation failure (mortality 13.3%). The average drainage volume in the first 24 hours after operation was 800.7±598.8ml. During a mean follow-up period of 20.6±17.4 months, one patient had suddenly death.

Conclusions: aTAAD misdiagnosed as ACS was not rare, anti-platelet therapy will increase the risk of bleeding. The decision of operation time rely on considering balance between the rupture risk of aortic dissection and the hemorrhage risk of anti-platelet therapy. Emergency operation for these patients will increase the bleeding and transfusion.

ID: 392

Topic: **Cardiovascular Surgery » Thoracic and Thoracoabdominal Aortic Dissections and Aneurisms**

Presentation Type: **Oral**

COMPARISON OF MORTALITY AND MORBIDITY RATES OF SYRIAN AND TURKISH PATIENTS OPERATED FOR ASCENDING AORTIC DISSECTION

Erdinç Eroglu, Mehmet Acıpayam, Alptekin Yasım

Kahramanmaraş Sutcu Imam University , Kahramanmaraş, Turkey

**Corresponding Author (erdinc046@hotmail.com)*

erdinc046@hotmail.com, mehmetacipayam@gmail.com, alpyasim@hotmail.com

Abstract Text

Objective:

To compare the mortality and morbidity rates of Turkish and Syrian patients operated for ascending aortic aneurysm and dissection in our clinic between 2016 and 2018.

Method:

Fifty-three patients who underwent surgery due to ascending aortic dissection and aneurysm were evaluated retrospectively. Of the patients, 30 were Turkish (Group 1) and 24 were Syrian (Group 2).Surgical procedures were the same in both groups. The groups were compared in terms of operative and postoperative results. Predictor factors were investigated for mortality and neurological complications

Results:

There was no difference between the two groups in terms of organ malperfusion, shock and loss of consciousness when compared to both groups in terms of preoperative features. The duration of stay in the intensive care unit, the length of hospital stay and the time to withdraw from the ventilator were shorter in group 2. Mortality rates in group 1 were higher, but not statistically significant.In addition, when all patients were evaluated for mortality predictions, only neurological complication was found to be effective in multivariant analysis.

Discussion and Conclusion:

Due to the increased surgical experience of the clinics, emergency surgical treatment of ascending aortic dissections and aneurysms can be performed successfully. In these operations performed in our clinic, it was realized that Syrian patients were extubated earlier and showed faster clinical improvement, so that they were discharged early. However, there is a need for large series of publications with more patients to show such a difference.

Keywords: Ascending aortic aneurysm, aortic surgery, mortality

ID: 558

Topic: Cardiovascular Surgery » Thoracic and Thoracoabdominal Aortic Dissections and AneurismsPresentation Type: **Oral****ARTERIAL CANNULATION OF THE INNOMINATE ARTERY FOR PROXIMAL AORTIC SURGERY****Bülent Mert, Kamil Boyacıoğlu, Adil Polat***Health Science University Bağcılar Research and Training Hospital, İstanbul, Turkey***Corresponding Author (mebulkvc@hotmail.com)**mebulkvc@hotmail.com, kamilboyacioglu@yahoo.com.tr, dradilpolat@gmail.com***Abstract Text**

Objective: Innominate artery cannulation has gained some popularity over the last decade as an alternative to axillary artery cannulation for providing selective antegrade cerebral perfusion during repair of the ascending aorta and arch. Here we present our experience and clinical outcomes with this technique.

Methods: A total of 25 patients (mean age 56.52±12.2 years; range, 38 to 76 years) underwent innominate artery cannulation with a side graft during proximal aortic surgery performed by way of a median sternotomy between December 2011 and January 2019. 16 patients were male (64%). Indication for surgery was a degenerative aneurysm in 18 (72%), an acute type A dissection in 6 patients (24%), a post-TEVAR retrograde type A dissection in 1 (4%). Operations performed were ascending aortic replacement (n = 7, 28%), aortic root replacement (n = 6, 24%) and aortic valve and ascending aortic replacement (n = 6, 24%). Ascending aortic and total arch replacement (n = 1, 4%), ascending aortic and partial arcus replacement (n = 2, 8%), aortic root and partial arcus replacement (n = 2, 8%), aortic valve, ascending aortic and partial arcus replacement (n = 1, 4%). Concomitant procedures included coronary artery bypass (n = 4, 16%), antegrade stent graft delivery to the proximal descending thoracic aorta (n = 1, 4%), mitral valve repair (n = 1, 4%), patent foramen ovale repair (n = 1, 4%) and ascending aorta to left common carotid bypass with neck incision (n = 1, 4%). The patients were cooled to 24 °C or 26 °C, and circulatory arrest was established except for 1 patient.

Results: The operative mortality rate was 0%. There was one (4%) permanent neurologic dysfunction, one (4%) temporary neurological dysfunction and one (4%) temporary cognitive dysfunction that resolved successfully. One patient (4%) required postoperative dialysis. Six patients (24%) required postoperative re-exploration due to bleeding or pericardial effusion.

Conclusion: Cannulation of the innominate artery is a simple, reproducible, safe, and effective technique for proximal aortic surgery and avoid extra surgical incisions which may be site for local complications. It is especially useful in cases requiring hypothermic circulatory arrest to deliver antegrade cerebral perfusion.

ID: 562

Topic: **Cardiovascular Surgery » Research**Presentation Type: **Poster****BILATERAL ERECTOR SPINAE PLANE BLOCK FOR ACUTE POST OPERATIVE AORTIC DISSECTION PAIN****Incila Ali, Seray Türkmen, Nihan Altintepe, Feryaz Kızıltan, Mete Gürsoy, Nihan Kayalar***Okmeydanı Training and Research Hospital, Istanbul, Turkey***Corresponding Author (incilali@hotmail.com)**incilali@hotmail.com, drserayturkmen@yahoo.com.tr, nihanaltintepe@gmail.com, k.feryaz@gmail.com, metegursoy35@gmail.com, nkayalar@hotmail.com***Abstract Text****BILATERAL ERECTOR SPINAE PLANE BLOCK FOR ACUTE POST OPERATIVE AORTIC DISSECTION PAIN****Introduction**

Cardiac surgery is associated with significant post-operative pain and intravenous opioids are the preferred treatment. However, some patients experience significant opioid side effects, including respiratory depression and somnolence which may cause atelectasis, hypoxia, hypercapnia, and prolonged intubation.

We present a patient with severe incisional pain and respiratory depression treated successfully with bilateral erector spinae plane blocks.

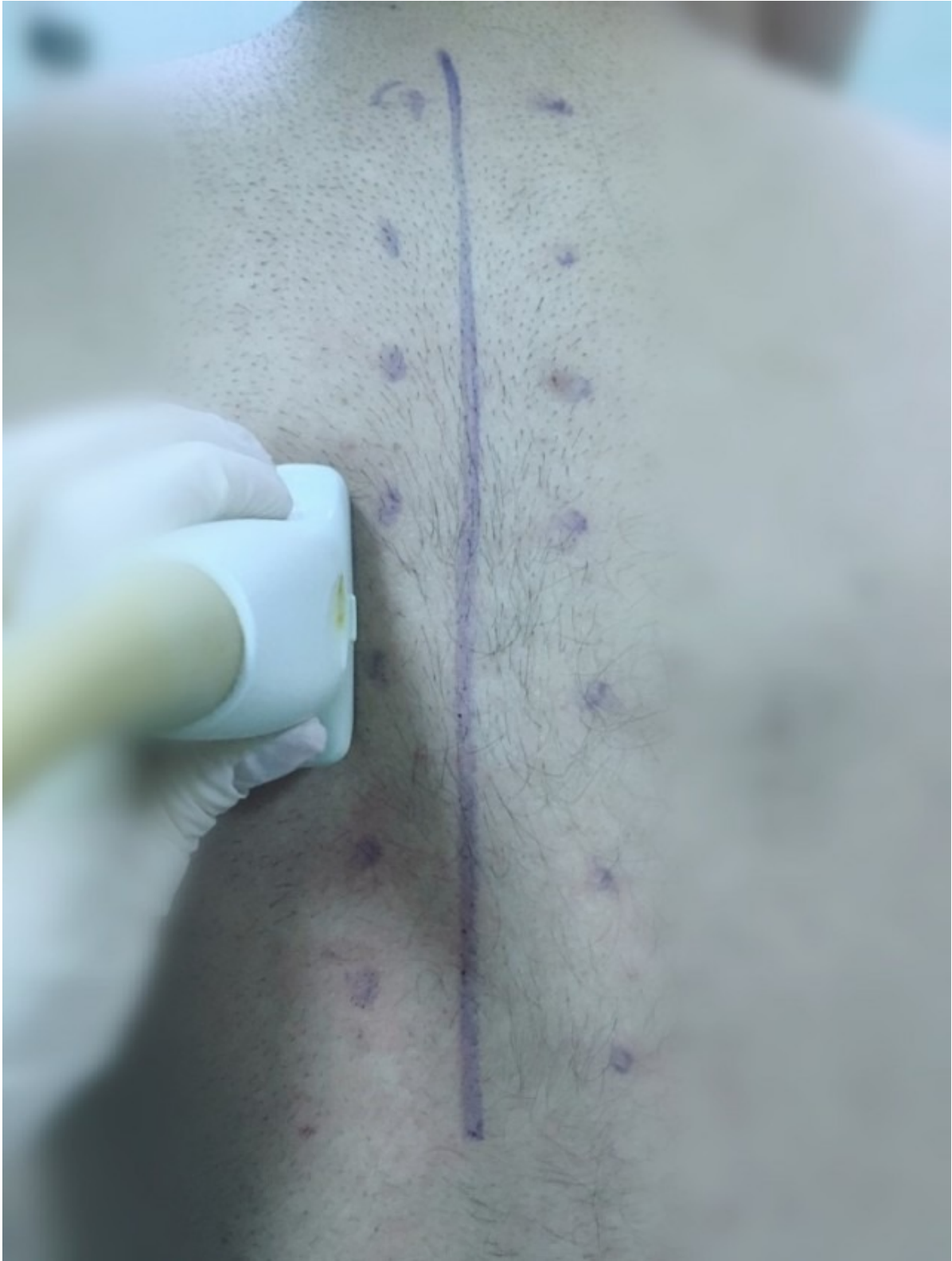Material and methods: A 49 years old male presented with sudden onset severe chest and back pain. CT angiography revealed Type 1 aortic dissection. Patient underwent hemiarcur replacement urgently. The patient was transferred to the ICU at the end of the procedure intubated and sedated on a remifentanyl infusion. Patient met extubation criteria, but struggled with severe incisional pain. He was ultimately extubated 10 hours after ICU admission, after receiving 100 mg IV petidin1 gram IV acetaminophen. He continued to complain of severe sternal incision and chest tube pain. His incision and chest tube insertion sites were exquisitely tender to light palpation. Breathing was shallow and he was unable to clear secretions adequately. His hemodynamic parameters (pulse,blood pressure,saturation) were labil because of his pain. Bilateral erector spinae plane blocks were made at the level of the fourth thoracic vertebra.

Description of Block

The patient was placed in a sitting position and a high-frequency linear ultrasound transducer was placed in a longitudinal orientation 3 cm lateral to the T4 spinous process. An 5-cm 22-gauge block needle was inserted in a cephalad-to-caudad direction until the tip lay in the interfascial plane between rhomboid major and erector spinae muscles, as evidenced by visible linear spread of fluid between the muscles upon injection .Following negative aspiration 15 mL of 0.25% bupivacaine and 5 ml %2 lidocaine were injected here. The procedure was repeated on the contralateral side. 30 minutes after the block, the patient reported numbness over the incision, but still had discomfort with deep palpation. At 60 minutes, he no longer had any pain from the sternotomy or chest tubes The patient able to take deep breath and cough effectively.The patient able to do respiratory physiotherapy and his oxygen saturation increased hourly. The following morning (11 hours post-block), he still exhibited anesthesia to light touch and sternal rub.

Conclusions

Bilateral erector spinae plane block is simple and safe technique and effectively relieves acute post-sternotomy pain.



Oral Presentation

New Surgical Tactics for Challenging Problems

Date: 28.03.2019 Time: 16:30 - 17:30 Hall: 6

ID: 381

Topic: Cardiology » Acute heart failure

Presentation Type: Oral

PRELIMINARY RESULTS OF THE SURGICAL TREATMENT OF ISCHAEMIC SEPTAL WALL RUPTURE.

Sameh Sersar¹, Mohammed Alassal²

¹Mansoura University; Egypt, Mansoura, Egypt

²Benha University, Benha, Egypt

**Corresponding Author (sameh001@yahoo.com)*

sameh001@yahoo.com, sameh001@yahoo.com

Abstract Text

Introduction and aim of the work

Ischaemic Septal Rupture is a lethal condition which mandates aggressive medical and surgical optimization. We reviewed a 14 cases of ischemic septal rupture in our centres in the last 7 years.

Patients and Methods:

We retrospectively collected the data of 14 of ischemic VSD who had surgical repair in 2 centres in Saudi Arabia in the last 7 years.
Results:

Our study included 14 cases including 9 males. There were 6 patients in cardiogenic shock and needed preoperative IABP. The median timing between chest pain and VSD repair was 5 days. VSD were anterior in 8, apical in 4 and inferior in 2 cases. Six cases died in 30 days after surgery. Statistical analysis showed cardiogenic shock preoperatively and preoperative organ failures as the predictors of early mortality.

Conclusion

Aggressive optimization of cardiogenic shock prior to repair of ischaemic VSD may improve the outcome.

ID: 262

Topic: **Cardiology » Acute Heart Failure**

Presentation Type: **Oral**

OUR CLINICAL EXPERIENCE OF TAKOTSUBO CARDIOMYOPATHY

Hamed Moghanchi, Abdi Sağcan, Murat Tümüklü, Mustafa Zungur, Cevat Şeküri

Kent Hospital, İzmir, Turkey

**Corresponding Author (hmoghanchi@yahoo.com)*

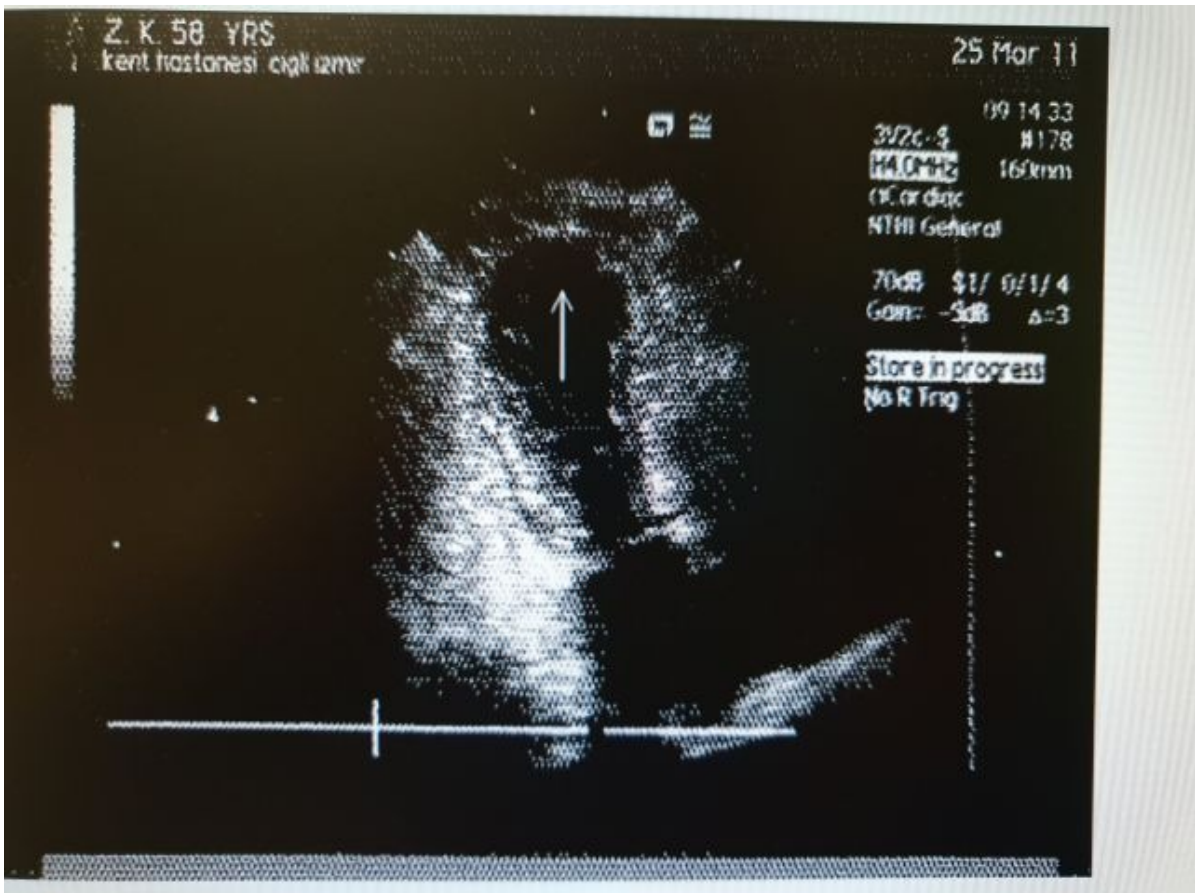
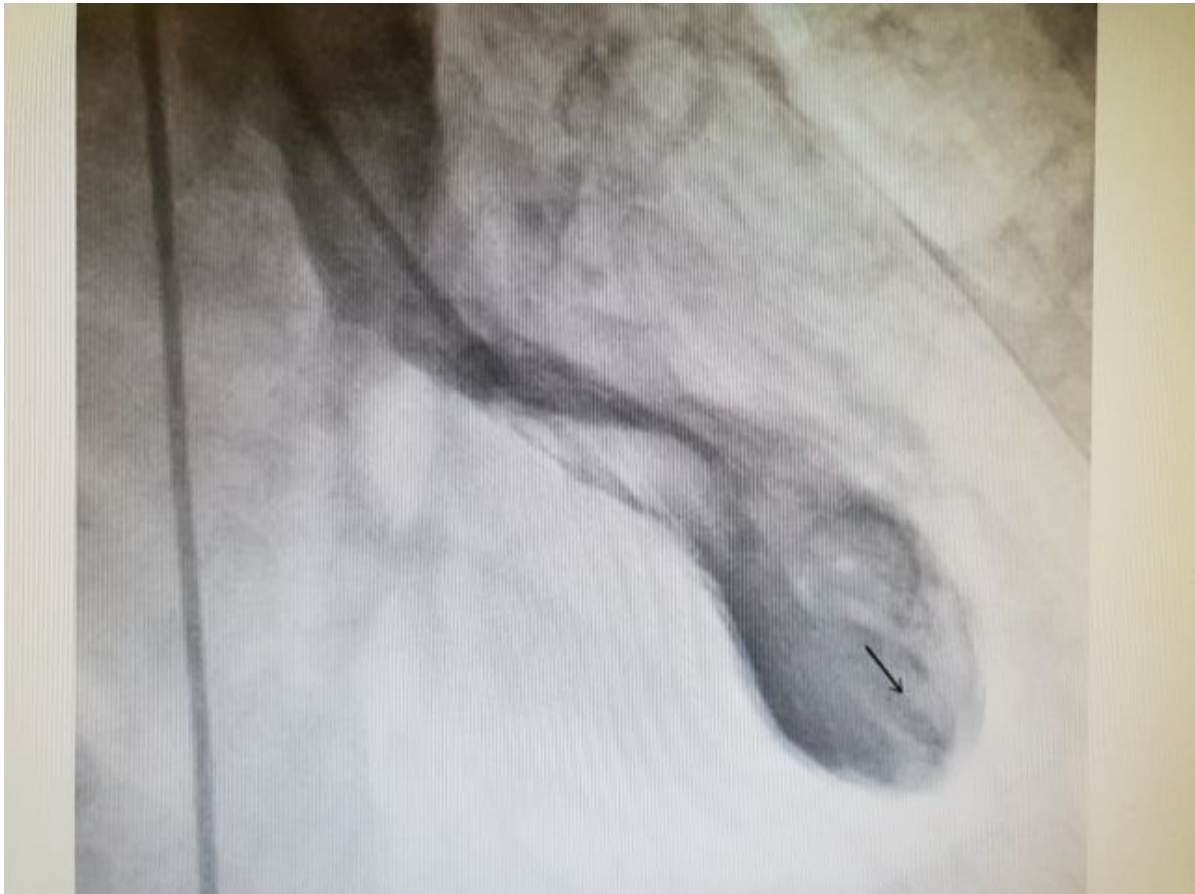*hmoghanchi@yahoo.com, abdi.sagcan@kenthospital.com, murat.tumuklu@kenthospital.com,
drzungur@yahoo.com, csekuri@hotmail.com*

Abstract Text

BACKGROUND AND AIM:This study aimed to research the etiology and prognosis of the patients who diagnosed with takotsubo in our clinic. We included 5 patients who were referred to our center with ST elevation myocardial infarction and diagnosed as takotsubo cardiomyopathy. **METHODS:**In this study, 5 patients who were referred to our clinic with acute ST elevation MI, Three patients were stable and two patients were in acute decompensation clinic. The ages of the patients were between 57-81 years of age and four were female (postmenopausal female). In the pathogenesis emotional stress (4 patients) and physical stress (one patient), hypertension, chronic obstructive pulmonary disease, DM were presented. Troponin positivity in all patients and ST elevation in the anterior leads was observed in all patients.

RESULTS:All patients underwent coronary angiography and non-occlusive coronary artery disease was detected, and echocardiography revealed apical ballooning of the patients. In one patient cerebral ischemic attack because of apical thrombosis with RWMA was occurred, after anticoagulation therapy the neurological symptoms were resolved. In one patient LVOT obstruction was diagnosed due to basal hypercontractility. No significant arrhythmias were observed. In the follow-up four of the patients had normal ejection fraction, one patient died because of non-cardiac reasons.

CONCLUSIONS:In our study we observed that emotional stress is an important triggering factor in takotsubo cardiomyopathy. An evaluation by ventriculography or echocardiography is recommended for acute coronary syndrome patients with non-critical stenosis. LVOT obstruction and apical thrombosis should be evaluated in all patients to modify the treatment.



ID: 535

Topic: **Cardiovascular Surgery » Research**Presentation Type: **Oral**

**PECTOINTERCOSTAL BLOCK MAY BE EFFECTIVE IN
POSTOPERATIVE PAIN MANAGEMENT FOLLOWING CARDIAC
SURGERY; A PILOT STUDY**

Incila Ali, **Seray Türkmen**, Onur Okur, Namigar Turgut, Cihan Yücel, Mete Gürsoy, Nihan Kayalar

Okmeydanı Training and Research Hospital, İstanbul, Turkey

**Corresponding Author (incilali@hotmail.com)*

*incilali@hotmail.com, drserayturkmen@yahoo.com.tr, onurokur@live.com, drnamigar@yahoo.com.tr,
cihanyucel@hotmail.com, metegursoy35@gmail.com, nkayalar@hotmail.com*

Abstract Text

Introduction: Pectointercostal block (PIB) is used for regional analgesia in thoracic diseases and interventions. Cardiac surgery is associated with severe postoperative pain due to sternotomy and internal thoracic artery harvesting. Parenteral narcotic analgesia is preferred approach which may cause various side effects. We reported the results of the first ten patients who had a PIB following cardiac surgery for postoperative pain management.

Material and methods: Ethics committee approval and informed consents were gained. Ten consecutive patients (6 female, 4 male) were included to the study. The same anesthesia team (SK, IA) performed ultrasound guided PIB to the patients at the end of the procedure. Visual pain score (VPS)(postoperative 1st, 3rd, 6th,12th, 18th,24th hours) and analgesia demand (for 24 hours) were recorded and compared with control group who did not have PIB.

Results: Mean age and gender distribution were similar between groups. VPS was insignificant at the 1st , 3rd , 24th hours. But mean VPS was lower in study group at the 6th, 12th, and 18th hours. Analgesia demand was also found decreased.

Conclusion: PIB may be effective in postoperative pain management following cardiac surgery. Repeated administration may be used in demand after 12th hours. A randomised prospective study is continue in our department.

ID: 243

Topic: **Cardiovascular Surgery » Research**Presentation Type: **Oral**

USE OF DEL NIDO CARDIOPLEGIA IN ADULT CARDIAC SURGERY. A PROPENSITY MATCHED STUDY OF 100 CONSECUTIVE UNSELECTED PATIENTS

Claudio Pragliola, Essam Hassan, Huda Ismail, Khaled Al Garni

Prince Sultan Cardiac Centre, Riyadh, Saudi Arabia

**Corresponding Author (claudio.pragliola@libero.it)*

claudio.pragliola@libero.it, ehassan@pscc.med.sa, hismail@pscc.med.sa, kalgarni@pscc.med.sa

Abstract Text

BACKGROUND :Del Nido cardioplegia (DNC) , a 1:4 blood solution largely used in paediatric cardiac surgery, has been successfully tested in selected low risk adult populations. In this study we examined the DNC as the routine solution for cardioplegic arrest and compared the results to those obtained with Intermittent warm blood cardioplegia (IWBC).

METHODS : From April to October 2018, 100 consecutive unselected adult patients (age 54 y ± 12 , 74 M/ 28 F) underwent a variety of surgical procedures on cardiopulmonary bypass and cardioplegic arrest with antegrade del Nido cardioplegia. Primary outcomes assessed myocardial preservation in the whole group (DNC) and in two subgroups with (ESII) Euroscore II > 4 (ESDNC) or an (EF%) ejection fraction < 40% (EFDNC). This groups were compared with similar propensity matched patients selected from a population in whom IWBC was previously used (IWBC, ESWBC,EFWBC). Outcomes were mortality, peak postoperative T troponine , the postoperative EF% and cross clamp time.

RESULTS

Grp	n	M/F n	ESII	CABG n	PAPS mmHg	Creat Umol/L (**)	EF% Preop	Cross Clamp min	Peak Tnl ng/ml	EF% Postop
DNC	100	74/26	4.0±4	38	42±17	105±109	47±11	108±52	1.2±1.3	46±10
IWBC	100	75/25	3.9±5	38	39±12	99±101	47±13	106±64	1.1±1.1	47±11
ESDNC	22	15/7	10.3±5	8	52±19	148±165	44±12	118±83	1.3±0.9	43±12
ESWBC	22	14/8	9.8±	8	48±15	139±95	45±11	109±92	1.2±1.0	47±13
EFDNC	23	20/3	4.7±2	12	43±15	155±156	29±4(*)	95±33	1.8±1.7	38±10(*)
EFWBC	23	20/3	4.6±	12	39±17	124±111	31±7	97±25	1.5±1.0	35±12

(*) p<0.009 to preop

(**) VN 45-84 Umol/L

Overall 4 (3.9%) patients died in both groups. There were no significant differences in three of the outcomes, In the EFDNC the postoperative EF% improved (P<0.009)

CONCLUSIONS

In this initial experience the Del Nido cardioplegia proved to be effective in a variety of pathologies in the adult population.

ID: 277

Topic: **Cardiovascular Surgery » Research**Presentation Type: **Oral****IS COLCHICINE EFFECTIVE IN THE TREATMENT OF PERICARDIAL EFFUSIONS AFTER OPEN HEART SURGERY?**

Bilgehan Erkut, Ümit Arslan, Ferhat Borulu

*Atatürk University Faculty of Medicine, Erzurum, Turkey***Corresponding Author (bilgehanerkut@yahoo.com)**bilgehanerkut@yahoo.com, kvcumit@gmail.com, fborulu@gmail.com***Abstract Text**

Is Colchicine Effective in the Treatment of Pericardial Effusions After Open Heart Surgery?

Bilgehan Erkut, Eyüp Serhat Çalık, Ümit Arslan, Ferhat Borulu.

Atatürk University Faculty of Medicine, Department of Cardiovascular Surgery, Erzurum, Turkey

Objective: Pericardial and pleural effusions are frequently seen after open heart surgery. In mild to moderate effusions, medical treatment modalities may be sufficient, and resistant and higher effusions may require intervention. The aim of our study is to evaluate the efficacy of colchicin in pericardial and pleural effusions which we follow medically using the anti-inflammatory properties of colchicin.

Methods: Of the 168 patients who underwent open heart surgery between November 2017 and November 2018, 48 (28.6%) had no intervention requiring mild and moderate pericardial and / or pleural effusion. Patients were randomly divided into two groups. In the first group, treatment with NSEI and diuretic was started and after the 3rd day oral steroid was added. Treatment with NSEI and diuretic was started for the second group, followed by colchicin at the dose of 1-2 mg / day. The echocardiographic measurements and telegrams of the patients were done every 3 days during the hospitalization period and once a week after discharge. Echocardiographic pericardial fluid measurements were made in millimeters and by the same individuals.

Results: The patients mean age was 62.8 years, 30 were male (60%) and 18 were female (40%). There were 23 patients in the first group and 25 patients in the second group and there was no difference in terms of demographic and clinical characteristics. Patients were followed until their effusions decreased to normal levels. The treatments were continued for 24 days in the steroid group and 16 days in the colchicin group ($p < 0.001$). In pericardial effusions in the group 1, there was decreased according to first day average 24% on the third day, 58% on the sixth day, 72% on the first week after discharge, and 84% on the second week; In the second group, decreased 33% on the third day, 67% on the sixth day, 84% on the first week after the discharge and 92% on the second week. The rate of decrease in the pericardial and pleural effusions was statistically significant in the colchicin group ($p < 0.001$). Significant clinical improvement was observed in both groups. There were no significant complications or side effects associated with drugs.

Conclusions: We think that colchicine is an effective and safe medical treatment in the medical treatment of pericardial and pleural effusions that develops after open heart surgery.

Key words: pericard, pleura, effusion, open heart surgery, therapy.

ID: 283

Topic: **Cardiovascular Surgery » Research**Presentation Type: **Oral**

INTRAOPERATIVELY TAKEN AND TRANSFUSED AUTOLOGOUS BLOOD TRANSFUSION A COST AFFECTIVE AND BENEFICIAL WAY OF BLOOD TRANSFUSION IN CARDIAC SURGERY; A RETROSPECTIVE CLINICAL TRIAL.

Ferda Kartufan, **Kenan Kara***Yeditepe University of Medical Faculty, Istanbul, Turkey***Corresponding Author (ferda.kartufan@yeditepe.edu.tr)**ferda.kartufan@yeditepe.edu.tr, kenan.kara@yeditepe.edu.tr*

Abstract Text

OBJECTIVES: In recent years autologous blood transfusion (ABT) seems to be more beneficial than allograft blood transfusion in coronary artery bypass, major vascular surgery and other surgeries that have increased elective blood transfusion risk. This current retrospective controlled study aimed to show that the intraoperatively taken and transfused ABT (iABT) is practical, beneficial and cost affective.

METHODS: From January 2017 to November 2018, cardiac surgery patients were investigated. According to exclusion criterias of this study; 349 operated from peripheric vascular diseases, 7 operated from emergent cardiac surgery, 3 operated from multiple cardiac operations and 9 using anticoagulant treatment were eliminated from 426 patient who had cardiovascular surgery. 58 patients clinical data were investigated. During the operation; the cross-clamp time and the extracorporeal perfusion time, volume of blood loss, blood transfusions needed were investigated. During the intensive care unit hospitalization extubation, ICU hospitalization time, the volume of blood loss, blood transfusions needed were investigated. Also, total hospitalization time, the total volume of blood loss, total blood transfusions needed, 30 days of mortality and one year of mortality were investigated.

Minimum-maximum, mean and standard deviation values were included in descriptive statistics. The T-test of independent sample to compare volumes of blood loss and transfused blood volumes according to intraoperatively taken ABT usage and Chi-square test for comparing complications related to operation and bleeding according to intraoperatively taken ABT usage were used. SPSS 22.0 programme was used for analysis. A p value less than 0.05 was considered to be statistically significant.

RESULTS: 58 patient's (23 female and 35 male) clinical data were investigated. From 20 of 35 male, ABT was performed in the surgery only one complication occurred in CABG. From 3 of 15 patient not taken ABT, the complication occurred in CABG. From 7 of 23 female, ABT was performed in the surgery. No complication occurred. From 5 of 16 not taken ABT, the complication was occurred in ASD, MVR and AVR operations.

ICU time was significantly shorter than the patient who was not transfused with iABT ($p < 0.05$). Intraoperative, during the ICU stay and the total blood loss was significantly lower than who was not transfused with iABT ($p < 0.05$). Complications related to blood loss and operation was significantly decreased according to ABT usage ($p < 0.05$). The volume of blood transfused as whole blood (WB), and red blood cell (RBC) transfusion was significantly lower ($p < 0.05$) in the patients who used iABT. During the ICU stay volume of blood transfused as WB, and RBC transfusion, fresh frozen plasma (FFP) were significantly lower ($p < 0.05$). The total blood volume transfused related to iABT was significantly lower ($p < 0.05$) according to WB, RBC transfusion, FFP.

CONCLUSIONS: This current study showed that iABT is more beneficial than allograft blood transfusions. iABT is related to less blood loss in operation and during the ICU stay, causing decreased risk for complications. According to less blood loss, fewer blood products transfusion is also a cost-effective benefit.

ID: 394

Topic: **Cardiovascular Surgery » Research**Presentation Type: **Oral**

SHORT TERM PROGNOSTIC EFFECT OF MICROALBUMINURIA IN CARDIAC SURGERY

Emrah Akbay¹, Hakan Öntaş², Zafer Erk¹, Şenol Gülmen³

¹SBÜ Antalya Eğitim Araştırma Hastanesi, Antalya, Turkey

²SB Balıkesir Devlet Hastanesi, Balıkesir, Turkey

³Suleyman Demirel University, Isparta, Turkey

*Corresponding Author (dremrahakbay@yahoo.com)

dremrahakbay@yahoo.com, maestrohakan@hotmail.com, zafererk07@gmail.com, s.gulmen@mynet.com

Abstract Text

Short Term Prognostic Effect of Microalbuminuria in Cardiac Surgery

Emrah Akbay¹, Hakan Öntaş², Zafer Erk¹, Şenol Gülmen³

1 S.B.Ü Antalya Eğitim ve Araştırma Hastanesi Kalp ve Damar Cerrahisi

2 S.B. Balıkesir Devlet Hastanesi Kalp ve Damar Cerrahisi

3 Isparta Süleyman Demirel Üniversitesi Kalp ve Damar Cerrahisi

Objective

Microalbuminuria is independent risk factor of myocardial infarction, cerebrovasculer event, vascular disease and mortality in both diabetic and non-diabetic patients, especially hypertansif patients.

In this study, we aimed to investigate the effects of preoperative microalbuminuria on prognosis in early postoperative period of elective open heart surgery.

Methods

60 patients undergoing elective open heart surgery from 1 January 2012 to 31 December 2012 were included in this study. Preoperative microalbuminuria was scanned in 24-hour urine samples. Preoperative, intraoperative and postoperative data were retrospectively screened.

T test was used to study the differences between the mean values of microalbuminuria and non-microalbuminuria. The chi-square independence test, Pearson correlation, Kendall Tau correlation test, Mann-Whitney U test were used to evaluate the relationship between microalbuminuria and non- microalbuminuria with other parameters.

Results

43 of patients were male and 17 female. Mean age in non-microalbuminuria and microalbuminurea patients was 63.03 ± 2.003 and 64.29 ± 1.774 , respectively. 24 of them had microalbuminuria. EF was similar in both groups and the presence of microalbuminuria was sex-independent in both groups.

The relation of microalbuminuria and NYHA calculated with the chi-square independence test was found 7.944 and it was statistically significant. ($p < 0.05$)

There was a statistically significant difference between microalbuminuria and non- microalbuminuria patients in terms of postoperative drainage ($P < 0.01$) and terms of follow-up time in postoperative intensive care. ($p < 0.05$)

Although there was no increase in frequency of revision in microalbuminuria patients, there was a statistically significant difference between the flow of the wound site. ($p < 0.05$)

Conclusion

In patients with microalbuminuria compared with non-microalbuminuria; there was an increase in the amount of chest tube drainage, duration of intensive care unit stay, frequency of sternal drainage and need for dopamine treatment postoperatively. The results of this study support that the presence of microalbuminuria before cardiac surgery affects the postoperative short-term prognosis. Therefore, we think that more comprehensive prospective clinical studies are needed to determine and reveal the unpredictable results of microalbuminuria. Microalbuminuria is an important parameter that should always be taken into consideration in preoperative evaluation of open heart surgery.

Keywords: Microalbuminuria, cardiopulmonary bypass, postoperative prognosis, wound drainage, drainage, dopamine, intensive care

ID: 422

Topic: Cardiovascular Surgery » Research

Presentation Type: Oral

A RARE CAUSE IN ETIOLOGY: A PATIENT WITH AUTOIMMUNITY AFTER RENAL TRANSPLANTATION AND REPEAT VASCULAR SURGERY

Mehmet Acıpayam, **Erdinç Eroğlu**, Aydemir Koçarlan, Alptekin Yasım

KSU, Kahramanmaraş, Turkey

**Corresponding Author (mehmetacipayam@gmail.com)*

mehmetacipayam@gmail.com, erdinc046@hotmail.com, drakocarlan@gmail.com, alpyasim@hotmail.com

Abstract Text

OBJECTIVES: In this article, it was aimed to consider autoimmune disease in a patient who had kidney transplantation 40 days before and had rejection and multiple vessel repair after transplantation.

Method: In the postoperative 21st day of a 31-day-old woman, 40 days before the transplantation, kidney is removed and the iliac artery and vein are primary repaired. In the follow-up of the patient whose immobile suppressive treatment is stopped, she was taken to the operation because of bleeding for two more times with scars. In the second case, cardiac and vascular surgery consultation is requested and distal iliac artery ligation and left iliofemoral bypass are performed. On her 5th day of operation due to acute bleeding, iliac artery ligation and femoral artery repair with dacron graft on the day of cross femoral bypass and left common femoral artery ligation on the 14th day were performed.

Conclusion: It was decided that the patient may be caused by fungal infection, autoimmune disease or vasculitis in the council, which includes the members of the nephrology, general surgery, rheumatology and cardiovascular surgery because of the operation of the patient due to multiple vascular injuries and frequent recurrence of this condition. It was decided to start IVIG and iv prednol treatment because rheumatologic tests would not result before 1 month and the patient had vascular pathologies that cause life-threatening bleeding. The patient was discharged on the 8th postoperative day.

Conclusion: Autoimmune disease and vasculitis should be kept in mind in patients with multiple vascular repair after rejection.

ID: 268

Topic: **Cardiology » Peripheral Arterial Diseases**Presentation Type: **Oral****PRIMARY HYPERHIDROSIS: IS SURGICAL TREATMENT THE LAST RESORT?****Rukiye Derin Atabey, Yigit Akcali***Erciyes University, Kayseri, Turkey***Corresponding Author (rukiyeatabey@hotmail.com)**rukiyeatabey@hotmail.com, yigitakcali@gmail.com***Abstract Text**

OBJECTIVE. Hyperhidrosis is an uncontrollable excessive sweat that occurs during resting regardless of temperature. Hyperhidrosis symptoms, which vary from social anxiety to phobia, can significantly affect quality of life. Despite different treatment options such as topical and systemic agents, iontophoresis and Botox, surgical sympathectomy is still an outstanding method. We presented our patients who underwent surgery for palmar and palmoplantar primary hyperhidrosis.

METHODS. In the last decade, four patients with hyperhidrosis (median age 21 years, range 17-33) (male=2, female=2) were followed up and treated. Hyperhidrosis and compensatory hyperhidrosis (CH) severity scores (Grade 0-3) of the patients were performed. Each patient was informed about treatment options and complications (CH, etc.), and an informed consent was obtained from them. As surgical therapeutic method, firstly, lumbar sympathectomy (LS) was bilaterally performed in the single session, and then, in the second week, thoracic sympathectomy (TS) was bilaterally performed at 4-day intervals. Thoracic sympathectomies were performed with cosmetic axillary thoracotomy incision while LSs were performed with modified extraperitoneal lateroexternal incision. Muscle-sparing technique was used in both approaches.

RESULTS. The patients had different treatment experiences that lasted a long time and were inconclusive. Except one patient who had treated palliatively with antiperspirant etc. (hyperhidrosis severity score, Grade 0), in the others (Grade 1 = 1 patient and Grade 2=2 patients) bilateral thoracic (n=3) and lumbar (n=2) sympathectomies were performed. Both TS and LS were performed in two of these patients (Figure 1). There was no surgical complication (Horner syndrome etc.). However, in one patient, CH (Grade 2) occurred on the back in the late period (33%).

CONCLUSIONS. Effective treatment modalities in hyperhidrosis vary from patient to patient, as the physician often needs to try several options before finding the most effective choice. Surgical sympathectomy should not be considered a 'last resort', but 'the first place to be sheltered' if medical therapy, iontophoresis and/or botulinum injections are time-consuming, transient, or ineffective.

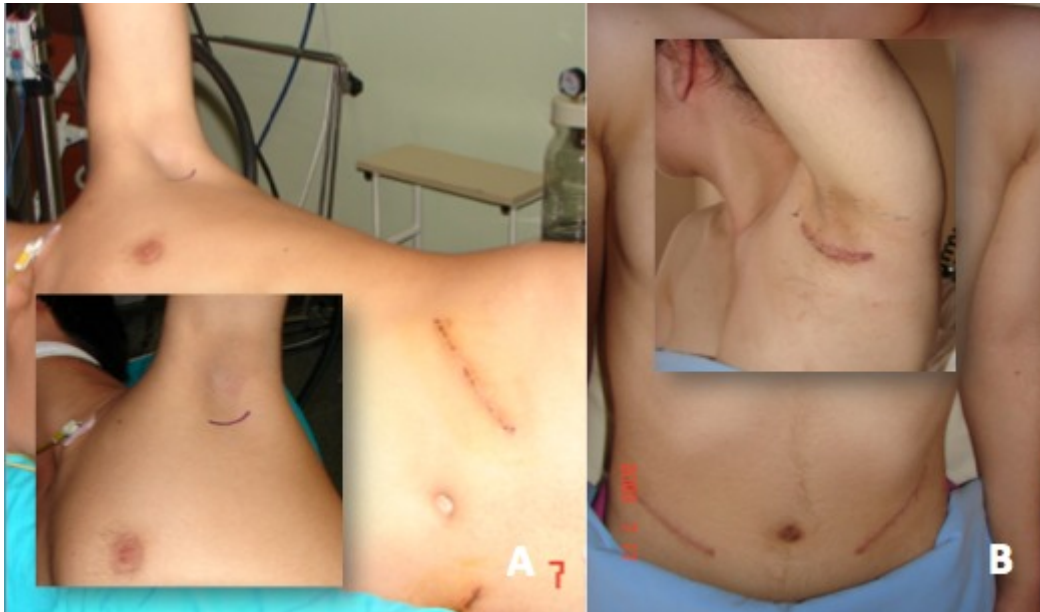


Figure 1. Note a preoperatively marked curvilinear axillary line between pectoralis major and latissimus dorsi muscles under armpit hairline in a 17-year-old male patient who had undergone bilateral lumbar sympathectomy ten days ago (A). An earlier appearance of surgical cicatrices of a 21-year-old female patient who underwent bilateral axillary (small picture) and lumbar sympathectomy (B).

ID: 566

Topic: **Cardiovascular Surgery » Endovascular Surgery**

Presentation Type: **Oral**

NOVEL SINGLE SECTION TECHNIQUE WITH THROMBECTOMY DEVICES IN THE TREATMENT OF SYMPTOMATIC MASSIVE ACUTE PULMONARY EMBOLISM THROUGH JUGULAR ACCESS: DESCRIPTION OF THE TECHNIQUE AND INITIAL SINGLE CENTER EXPERIENCE

Bruno Freitas¹, Elton Alves¹, Wellington Mandinga¹, Achilles Lima¹, Diego Espíndola¹, Mario Amorim¹, Andrej Schmidt², Dierk Scheinert²

¹*Santa Casa de Misericórdia de Maceió, Maceió, Brazil*

²*Universitätsklinikum Leipzig AöR, Leipzig, Germany*

**Corresponding Author (prof.bruno.freitas@icloud.com)*

prof.bruno.freitas@icloud.com, eltoncorreia@gmail.com, wbspomandinga@gmail.com, aclima@uol.com.br, diegoespindola@hotmail.com, marioamorimvascular@gmail.com, dr.andrej.schmidt@gmail.com, dierk.scheinert@gmx.de

Abstract Text**Introduction:**

Acute pulmonary embolism(APE) is one of the leading cause of mortality in the United States, with 58% mortality in the first hour in patients with hemodynamic compromise¹⁻³. Treatment options are often time consuming or less effective. Our aim is to describe the technique and report our preliminary experience with a novel single section mechanical rotational thrombectomy technique for patients with massive APE using Aspirex®.

Methods: A retrospective analysis of patients admitted to our hospital due to massive APE from July/2016 to August/2018. The procedures were performed under general anesthesia. After ultrasound-assisted right jugular access, initial cavography was performed, followed by selective pulmonary trunk catheterization with a 0.035'' hydrophilic guidewire and a 5-French Internal Mamaria(IM) catheter. This catheter was advanced into each pulmonary artery and angiography was performed(Figs 1a and 1b.), with exchange for a 11F Sheath. After distal placement of a 0.018'' guidewire , mechanical thrombectomy was made with 10F Aspirex® ranging from 2 to 5 passages on each side(Figs. 1c., 2a. and 2b.). The procedure was continued until all major primary branches of the pulmonary arteries became recanalized, or the patient showed improvement in haemodynamic stability and blood gas parameters, even if the angiographic result was suboptimal. A 30% residual stenosis after thrombectomy was considered adequate/successful, if there was good flow in to peripheral branches. Likewise, 30–50% stenosis with significant improvement of clinical status (normalisation of heart rate and blood gas parameters) and good flow in to peripheral branches was interpreted as an acceptable result. Residual stenosis (> 50%) or no clinical improvement represented an indication for more ASPIREX passages with adjunctive selective thrombolysis.

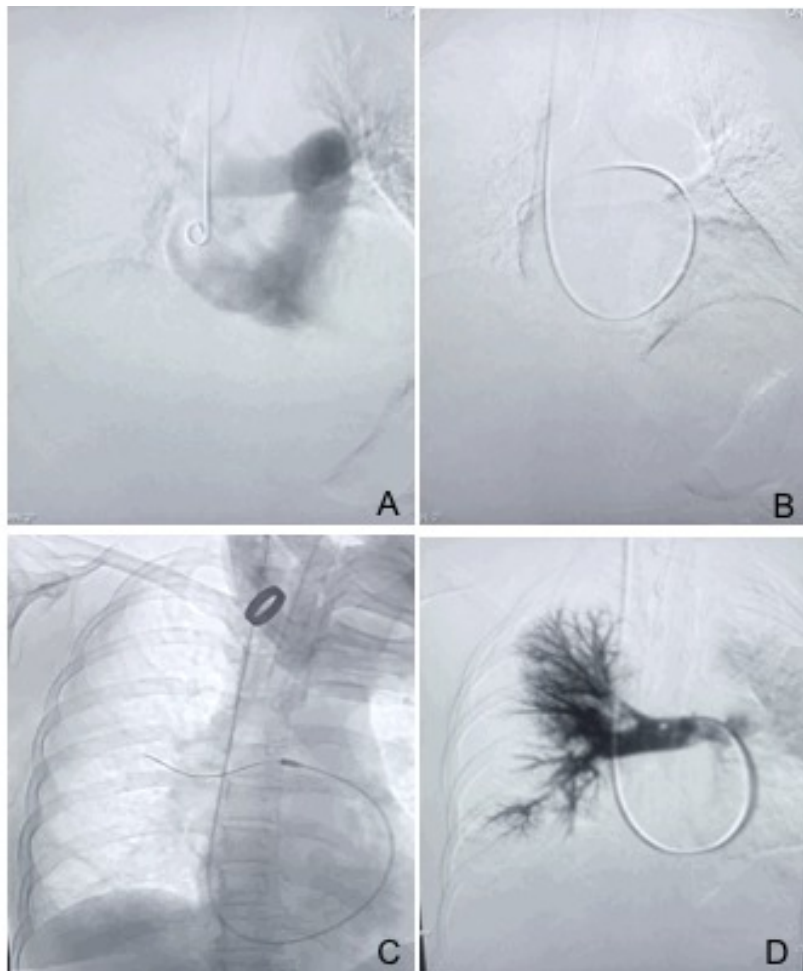


Fig 1. Pulmonary Thrombectomy: 1a. Initial angiogram, 1b. Right Catheterization with IM, 1c. Right Thrombectomy with 10F Aspirex, 1d. Immediate control angiogram

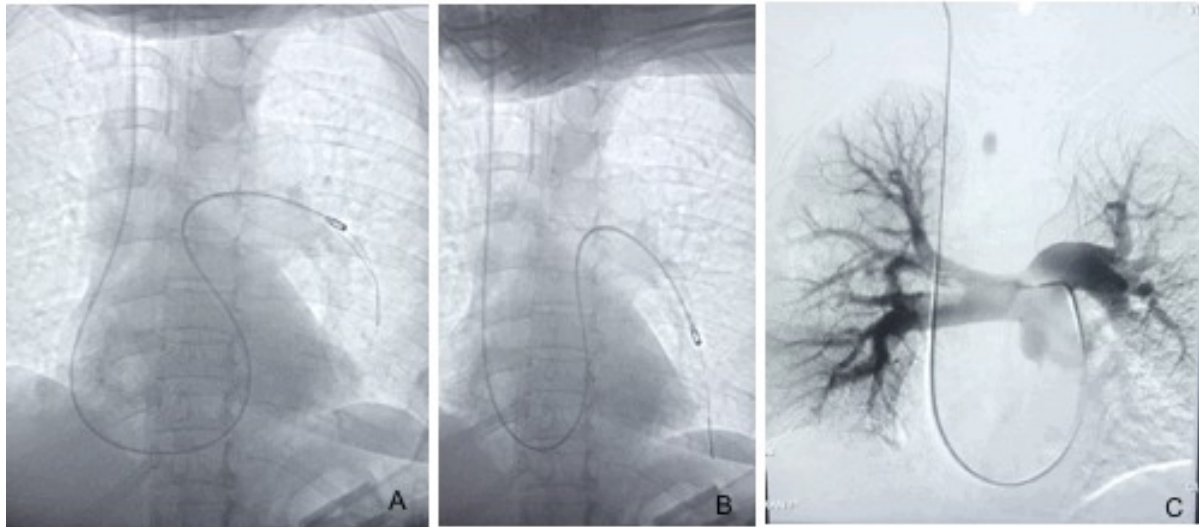


Fig 2. Pulmonary thrombectomy: 2a. Right main trunk thrombectomy, 2b. Right lower interlobar artery, 2c. Final angiogram

Results: 16 patients (mean age 59.6 ± 21.7 years) underwent endovascular revascularization for APE using thrombectomy devices, during the period of the study. Dyspnea was the most common complain on admission (93.75%), with thoracic pain(81.25%) shock(68.75%) and syncope(12.5%) as the main clinical referral presentation at admission. 13 patients had suggestive CT signs of APE on admission. Endovascular revascularization was successfully performed in all patients through the right jugular vein with a mean procedural time of 29 ± 21 minutes. Primary use of thrombectomy devices was performed in all patients, with a technical success rate of 100%. Intraoperative selective thrombolysis (6/16;37.5%) and catheter-assisted aspiration in 12.5%(2/16) of patients. Average time between admission and angio-CT was 3.1 ± 1.6 h and between admission and interventional procedure was 4.2 ± 1.3 h. Complications directly related to the endovascular procedure occurred in two patients, represented by self-limited small access hematomas. Overall 30-day mortality was 12.5% (n=2). Nevertheless, no patient died as a result of complications related to the use of the device.

Conclusions: Endovascular treatment of massive APE with the use of thrombectomy devices proved to be technically feasible and reasonably fast procedure. Early diagnosis and adequate treatment remains the cornerstone of the treatment. Early evaluation and close integration between EP and endovascular specialists are crucial to faster treatment and consequently lower mortality. Further studies are necessary on this field to confirm these findings.

Oral Presentation

Key Opinions From Vascular Surgeons

Date: 28.03.2019 Time: 17:30 - 18:30 Hall: 6

ID: 452

Topic: **Cardiovascular Surgery » Peripheral Artery Disease and Treatment**

Presentation Type: **Oral**

RESULTS OF BYPASS SURGERY IN INFRAPOPLITEAL PERIPHERAL ARTERIAL DISEASE

Dilsad Amanvermez Senarslan, Funda Yıldırım, **Barış Bayram**, Abdülkerim Damar, Adnan Taner Kurdal, Ömer Tetik

Manisa Celal Bayar University, Faculty of Medicine, Manisa, Turkey

**Corresponding Author (damanvermez@yahoo.com)*

damanvermez@yahoo.com, fundanizamoglu@yahoo.com, damanvermez@yahoo.com, damanvermez@yahoo.com, damanvermez@yahoo.com, damanvermez@yahoo.com

Abstract Text

OBJECTIVE

Nowadays, with the prolongation of people's life expectancy, the number of older patients with peripheral arterial disease (PAD) and diabetic patients has increased and the incidence of infrapopliteal lesion also increased in parallel. Infrapopliteal revascularization is usually preferred for limb salvage in patients with critical limb ischemia. Nevertheless it has a limited usage for the patients with intermittent claudication. Endovascular methods or distal bypass with saphenous vein are recommended for the treatment of infrapopliteal lesions. The aim of this study is to investigate the results of infrapopliteal distal bypasses performed in our clinic in the last 3 years

METHODS

In the last 3 years, 46 (8 female, 38 male) patients who underwent distal bypass to infrapopliteal vessels due to critical leg ischemia were reviewed retrospectively.

RESULTS

In 26% of the patients there was a nonhealing wound at the time of admission and others had the critical leg ischemia. Five patients, Rutherford grade 5; 7 patients were in Rutherford class 4 and 36 patients in Rutherford class 3 level. Four (8.6%) patients had minor amputation and 2 patients (4.3%) had a major amputation at a mean follow-up of 10.1 ± 8 months. Two patients who required major amputation in the following period were those who presented with delayed acute arterial occlusion. No postoperative mortality was observed in any patient. No mortality was observed in the long term. However, 6 patients follow-up (%13) was not accomplished. In the first 30 days postoperatively; There were no additional complications except for local healing problems at the wound site in 5 patients (10.6%).

CONCLUSIONS

Endovascular methods or surgical treatment (infrapopliteal bypass) can be used for the treatment of infrapopliteal occlusive peripheral arterial disease. The primary patency rates of endovascular treatments are low, but assisted patency and leg recovery rates are more reasonable. We suggest that surgical treatment with autogenous grafts is preferred primarily for long-term survival, primary patency rates, reasonable morbidity and mortality.

ID: 456

Topic: **Cardiovascular Surgery » Peripheral Artery Disease and Treatment**Presentation Type: **Oral****REVASCULARIZATION OR AMPUTATION? TIME FOR AN UPDATE FOR MESS****Atilla Orhan, Ömer Faruk Çiçek, Hakan Akbayrak, Ahmet Yıldırım, Mustafa Büyükatęs***Selcuk University, Faculty of Medicine, Konya, Turkey***Corresponding Author (atillaorhan@gmail.com)**atillaorhan@gmail.com, farux@hotmail.com, hakanakbayrak@gmail.com, dr1907@gmail.com, mustafabuyukates@yahoo.com***Abstract Text**

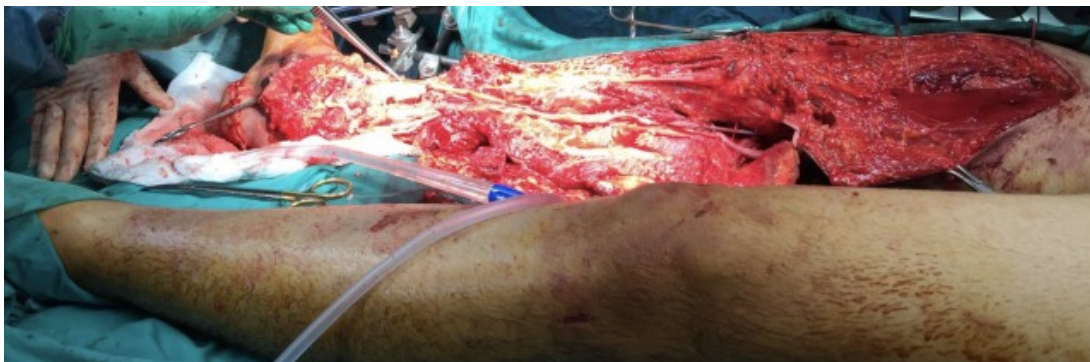Background: Significantly reduced amputation rates in traumatic extremity artery injuries were achieved with improved revascularization and resuscitative techniques. Predictive scores, such as the Mangled Extremity Severity Score (MESS), failed to predict results in patients with arterial limb injury accurately. This retrospective study concluded that MESS score should be updated in the patients with high MESS extremity artery trauma.

Methods: Patients with high MESS extremity artery trauma who applied between March 2017 and June 2018 underwent a single-institution and retrospective study. The data were documented by demographic data, injury mechanism, associated injury, fasciotomy, and the MESS using the institutional registries.

Results: The extremity artery trauma was identified in high MESS patients (N=6) with a mean age of 29.16 (range: 9-42). All patients were male (100%). All were accompanied by severe nerve and vein injury. There were a dislocation and three fractures in the associated orthopedic injuries. The median MESS was 8 (range: 7-11). Arterial and venous revascularization was performed in all cases (100%) (Video Link - 1). The orthopedics team performed fasciotomies, and nerve, muscle, fractures and tissue repairs (Figure 1). Three patients underwent fasciotomy due to the risk of compartment syndrome. Despite the excellent perfusion, the patient who has the highest MESS score required secondary amputation due to the development of disseminated intravascular coagulation in the postoperative period. The extremities of the other patients survived despite the loss of locomotor function of different grades.

Conclusions: Patients with traumatic extremity arterial injury are at high risk for amputation. The blunt trauma is associated with increased amputation rates and the MESS > 7. In our data, although the MESS is the strongest predictor of amputation, we believe that the MESS should be updated with new technological, imaging and surgical developments. There is a need for new methods and the MESS to be updated to determine limb viability and to recover limb in a multiple-injured extremity.

Figure 1:



ID: 405

Topic: **Cardiovascular Surgery » Peripheral Arterial Disease**Presentation Type: **Oral****BELOW-KNEE PERCUTANEOUS TRANSLUMINAL ANGIOPLASTY IN PATIENTS WITH DIABETIC FOOT WOUNDS IN TASC II D GROUP****Mihriban Yalçın***Ordu State Hospital, Ordu, Turkey***Corresponding Author (mihribandemir33@hotmail.com)**mihribandemir33@hotmail.com***Abstract Text**

Objective: The aim of this study was to investigate the effect of percutaneous transluminal angioplasty (PTA) on limb protection in TASC II D group patients with critical leg ischemia and diabetic foot wound.

Methods: In this study, we retrospectively investigated the 18-month limb protection rates and the success of the procedure following PTA. Between January 2015 and December 2017, angiographic images and file information of patients evaluated retrospectively with diabetic foot wound in whom endovascular revascularization therapy was performed. There were 84 patients. The study was completed with 44 patients. 40 patients were excluded from the study (2 of them were treated with only femoropopliteal arteries, 10 patients' follow-up results could not be reached and 28 patients were in TASC A, B or C group).

Results: Of the patients 22.7% (10/44) were female and 77.3% (34/44) were male. The mean age of the patients was 68.72 (\pm 7.49). Technical success was found in 29 patients (67.2%) in the PTA procedure and thirteen patients (29.5%) failed to achieve technical success. In two patients (4.5%) perforation was observed. In the statistical analysis, it was observed that the length of the occlusion affected the success of the procedure ($p = 0.032$).

Limb protection rate was 75.8% (22/29) in 18 months. The use of a drug-eluting balloon or conventional balloon in PTA procedures did not differ significantly on the duration of limb protection and the success of the procedure. Ten of the procedures (22.7%) were done by using drug-eluting balloons.

Among the factors affecting the duration of limb preservation, only the length of the occlusion was found to be significant ($p = 0.021$). During the follow-up period, nine patients died. Of them all patients had at least two vascular diseases and six patients had long segment occlusion. PTA procedure was unsuccessful in six out-of-9 patients. Patients were given 300 mg aspirin (1x1) for lifelong and clopidogrel 75 mg (1x1) for one month after procedure. Foot ulcers of the patients were treated carefully and foot dressings were performed regularly.

Conclusions: We suggest that the patients in TASC II D group that have critical leg ischemia and diabetic foot wound, PTA should be applied for limb salvage if appropriate.

ID: 322

Topic: **Cardiovascular Surgery » Peripheral Artery Disease and Treatment**Presentation Type: **Oral****A RARE TUMOR IN A YOUNG WOMAN ; MYOPERICYTOMA****Mustafa Dağlı***Training and Research Hospital, Konya, Turkey***Corresponding Author (drmustafaaaa@gmail.com)**drmustafaaaa@gmail.com***Abstract Text****OBJECTIVE**

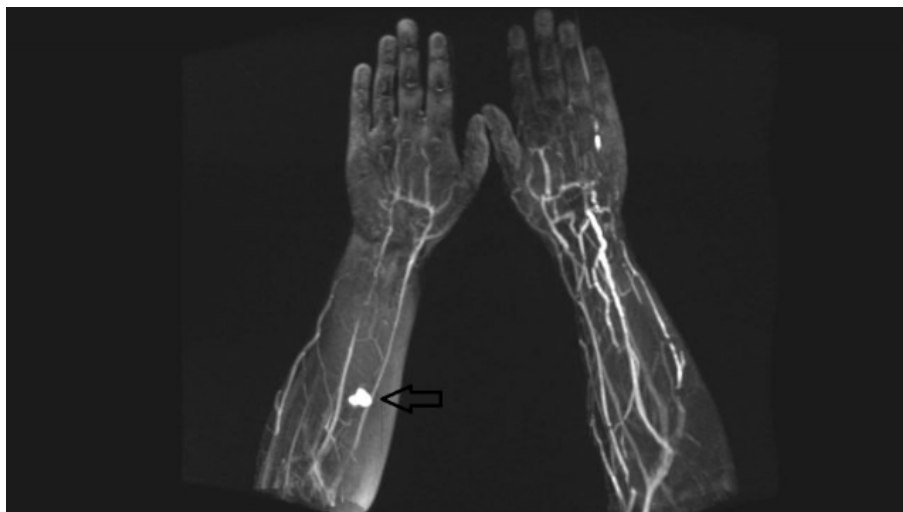
Myopericytoma is a soft tissue tumor arising from perivascular cells called pericytes. It is usually asymptomatic, slow-growing and benign-natured, although malignant variants have been described. The etiology is unknown but it has been associated with local trauma. They are mostly localised in lower extremities in the dermal or subcutaneous location with a middle-aged male predominance. In this paper we aimed to discuss this rare tumor in a young female patient.

CASE REPORT

A 22-year-old woman presented with a mass lesion on the distal left arm, medial side. The mass was painful and had grown progressively over 2 years. MRI demonstrated a lobulated, contrast enhanced mass. The lesion was treated surgically and final diagnosis of the specimen upon pathology was a myopericytoma.

CONCLUSION

Myopericytomas are uncommon, benign perivascular neoplasms. But local recurrences and rarely metastases including visseral organs can result in more unfavourable conditions. Thus, early diagnoses and marginal excision is important in those cases.



ID: 471

Topic: Cardiovascular Surgery » Peripheral Artery Disease and Treatment

Presentation Type: Oral

**SUCCESSFUL REPAIR OF THE ARTERY OF THE SUPERFICIAL
MESENTERIUM DURING ONCOLOGIC SURGERY**

Mehmet Acıpayam, **Erdinç Erođlu**, Aydemir Koçarslan, Alptekin Yasım

KSU, Kahramanmaraş, Turkey

**Corresponding Author (mehmetacipayam@gmail.com)*

mehmetacipayam@gmail.com, erdinc046@hotmail.com, drakocarlan@gmail.com, alpyasim@hotmail.com

Abstract Text

Objective: The aim of this article is to describe the importance of multidisciplinary approach in oncologic surgery.

Method: A 54-year-old male patient was operated because of a renal tumor. Cardiovascular surgery consultation is requested upon detection of superior tumor and ligation of the superior mesenteric artery during exploration due to compression of surrounding tissues. The patient is evaluated by the cardiovascular surgeons at the operating table and after the heparinization, the superior mesenteric artery is clamped to the distal part of the suture. The superior mesenteric artery was anastomosed to the aorta with a 6 mm dacron graft. Postoperative follow-up was uneventful.

Result: During oncologic surgery, both the size of the tumor and the invasion and surrounding of the surrounding tissues may cause difficulties in the exploration of the surrounding tissues and this can lead to unwanted errors. In this case, the superior mesenteric artery was ligated due to the size of the tumor and the compression of the surrounding tissues.

Conclusions: Oncologic surgeries may require a multidisciplinary approach as a result of tumor size and invasion of surrounding tissues. In this case, the better the communication between clinics, the more probable complications will be treated in a shorter time and the possible complications will be prevented

ID: 469

Topic: Cardiovascular Surgery » Peripheral Arterial Disease

Presentation Type: Oral

IATROGENIC LIGATION OF THE ABERRANT RIGHT SUBCLAVIAN ARTERY DURING MEDIASTINAL CYSTIC LYMPHANGIOMA RESECTION SURGERY: A COMPLICATION OR A TREATMENT?

Mustafa Cüneyt Çiçek

*Konya Education Research Hospital, Konya, Turkey***Corresponding Author (drmcuneyt@hotmail.com)**drmcuneyt@hotmail.com*

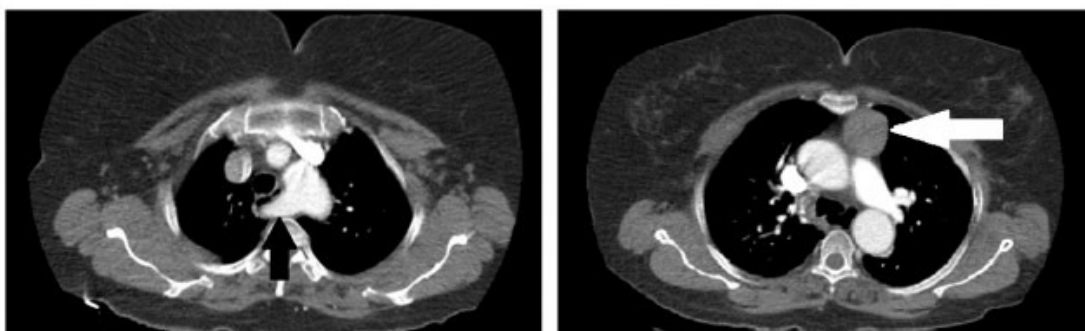
Abstract Text

Introduction: Iatrogenic arterial injuries may result from any invasive diagnostic or therapeutic procedure. Iatrogenic arterial injuries that prompted referral to the vascular surgery resulted largely from angiography, orthopedic procedures, and tumor resections performed by oncologic surgeons. This patient was consulted to us emergently because of intraoperative aberrant right subclavian artery ligation made by thoracic surgeons as a complication of a mediastinal mass resection. We aimed to present our approach to this rare iatrogenic complication.

Case Report: A 67-year-old lady underwent a resection surgery for a mediastinal cystic lymphangioma. Surgery was complicated by the fact that the patient had a mediastinal mass involving most of the anterior mediasten associated with the aberrant right subclavian artery (Figure 1). During mass dissection, the aberrant right subclavian artery was injured 3cm away from aorta which led to significant intraoperative hemorrhage of over 1 liter. In order to gain rapid control, video-assisted thoracoscopic surgery converted to open thoracotomy. The patient was consulted to us emergently and we participated in the operation as soon as possible. Intraoperative view revealed that surgical clip was applied successfully to control hemorrhage by thoracic surgeon. After examination of the patient, right upper extremity peripheral pulses was not palpable, but it was clear that the extremity was not in an ischemic situation. An urgent bedside arterial Doppler was performed by a radiologist. Monophasic waveform was seen at the distal segments. The proximal subclavian artery could not be seen however the distal subclavian artery demonstrated low velocity flow, continuing into the brachial, ulnar and radial arteries. An urgent intraoperative digital subtraction angiography was performed which confirmed complete occlusion of the proximal part of the aberrant right subclavian artery. Conservative management was preferred and an advanced vascular surgery was not planned so. The patient recovered uneventfully after operation and reported no pain and no ischemic symptoms whilst on the ward. The patient was discharged from the thoracic surgery clinic with the decision of probable elective revascularization in the future.

Conclusions: Preoperative imaging tests should be examined very carefully and thus the surgical strategy may be modified in order to prevent potential catastrophic vascular complications especially in cases with unusual origin and/or course of vascular structures.

Figure 1: A computed tomographic angiography shows aberrant right subclavian artery (black arrow) originating from arcus aorta and a mass located in the anterior mediasten (white arrow).



ID: 525

Topic: **Cardiovascular Surgery » Endovascular Surgery**Presentation Type: **Oral****ENDOASCULAR TREATMENT OF BELOW-THE-KNEE ARTERY DISEASE: A SINGLE CENTER EXPERIENCE****Selim Aydin***Acibadem Mehmet Ali Aydinlar University, School of Medicine, İstanbul, Turkey***Corresponding Author (selim.aydin@acibadem.edu.tr)**selim.aydin@acibadem.edu.tr***Abstract Text**

Objective: The importance of endovascular interventions in the treatment of peripheral arterial diseases is increasing day by day. Endovascular treatment of below-the-knee (BTK) artery disease is still controversial.

Methods: Between September 2016 and December 2018, 33 patients underwent peripheral intervention for BTK artery disease in our institution. Mean age was 65.88 ± 13.07 years (min 35 – max 87). Twenty-six patients (78,8%) were male. Twenty-one patients had critical limb ischemia and 12 patients had lifestyle-limiting claudication. As a result of preoperative imaging, 13 patients had 3-vessel BTK disease, 8 patients had 2-vessel BTK disease, and 11 patients had single vessel disease. There was an additional femoropopliteal artery pathology in 29 patients and iliac artery pathology in 6 patients.

Results: Procedural and clinical success were achieved in all cases. Atherectomy was performed in 10 patients. Balloon angioplasty was performed in 48 BTK vessels of 33 patients. Drug-coated balloon was performed in 27 of these vessels. Mean follow-up duration was $12,35 \pm 8,16$ months, range 0,5 – 27,2 months. Two minor amputations were performed to reach complete wound healing. There was no major amputation and no mortality. Re-occlusion was seen in 4 patients (12,1%) and target lesion revascularization (TLR) was performed to these patients. Freedom from TLR rate was 87,8%.

Conclusions: Endovascular treatment of BTK artery disease is safe and effective. It can minimize the risk of amputation with acceptable open rates in patients with critical limb ischemia.

ID: 557

Topic: **Cardiovascular Surgery » Peripheral Artery Disease and Treatment**

Presentation Type: **Oral**

AUTOLOGOUS SAPHENOUS VEIN PANEL GRAFT TREATMENT IN VASCULAR DISORDERS

Kamil Boyacıoğlu

Health Science University Bağcılar Training and Resaearch Hospital, İstanbul, Turkey

**Corresponding Author (kamilboyacioglu@yahoo.com.tr)*

kamilboyacioglu@yahoo.com.tr

Abstract Text

Objective: This study aims to present early and mid-term results of vascular reconstruction with saphenous vein panel graft.

Methods: Between August 2014 and January 2019, 21 saphenous vein panel grafts were used for vascular reconstruction in 19 patients. Patient data including demographic features, etiology of the vascular pathology, concomitant injury, site of injury, surgical procedure, additional surgical procedure, and hemodynamic status were retrospectively collected and analyzed. The Kaplan-Meier method was used to calculate the patency rates.

Results: All patients were male. The most reason for operations was traumatic vascular injuries. Mean duration of follow-up was 18.3±15.3 months (ranged,2-53 months). One patient was required reoperation for bleeding. There was no evidence of arterial claudication or venous insufficiency in all patients. The primary patency rates were 85.7 % at 1 and 3 years; but all saphenous vein panel graft in venous position were patent during follow-up. There was not any mortality, deep venous thrombosis, pulmonary embolism, graft thrombosis, graft infection, anastomotic stenosis, diameter discrepancy and aneurysm formation during late follow-up.

Conclusions: The autologous saphenous panel vein graft enables the surgeon to prepare suitable conduits easily with an appropriate diameter and length for vascular reconstruction. This technique provides high patency rates in mid-term follow-up, resistance to infection and low reintervention rates. In conclusion, autologous saphenous vein panel grafts may well be preferred in various vascular disorders.

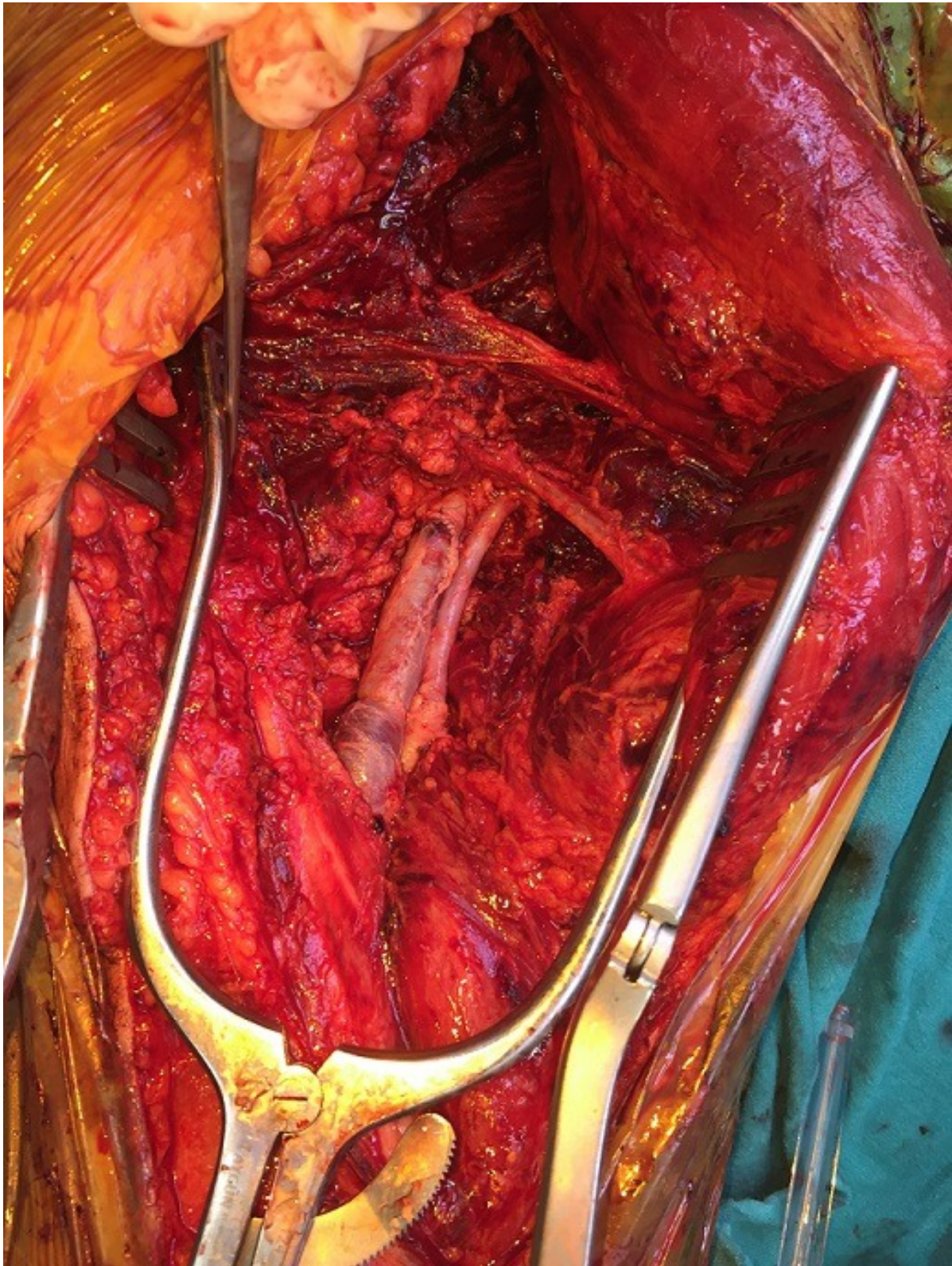


Fig 1: Saphenous vein and saphenous vein panel grafts in popliteal artery and vein position. The diameter discrepancy between the saphenous vein and popliteal vein is eliminated by using autologous saphenous panel vein graft.

Oral Presentations

Percutaneous Intervention in Heart Diseases

Date: 29.03.2019 Time: 11:15 - 12:45 Hall: 4

ID: 26

Topic: Cardiology » Hypertrophic Cardiomyopathy

Presentation Type: Oral

THE MYSTERIOUS CHALLENGE IN THE TREATMENT OF PATIENTS WITH HOCM: ALCOHOL SEPTAL ABLATION OR SURGICAL SEPTAL MYECTOMY ?

Cem Doğan

Kartal Koşuyolu Y.İ.E.A.H, İstanbul, Turkey

**Corresponding Author (cemcardio@hotmail.com)*

cemcardio@hotmail.com

Abstract Text

Objectives:

Alcohol septal ablation may be a preferable alternative to surgical septal myectomy in the treatment of patients with HOCM. This study sought to describe the gradient differences of the left ventricular outflow tract one year after the procedure between the septal myectomy and alcohol septal ablation in patients with hypertrophic cardiomyopathy (HOCM).

Methods:

The echocardiographic parameters were compared in patients with HOCM before and after the septal myectomy and alcohol septal ablation (SAA). The gradient in the left ventricular outflow tract with exercise stress test 1 year after the each procedure were recorded.

Results:

There were 18 patients underwent alcohol septal ablation and 27 patients to septal myectomy. The mean EF for patients performed surgical myectomy was $61 \pm 6.4\%$ and for SAA group it was $59 \pm 6.5\%$, p value: 0.221. The mean gradient of the LVOT in septal myectomy group was 101 ± 38 mmHg and the SAA group 91 ± 38 mmHg with the p value of 0.405 before the procedure. The gradients with exercise stress test were also found similar (54 ± 39 mmHg for surgical myectomy and 73 ± 53 mmHg for SAA, p value: 0.220) at the end of the 1 year.

Conclusions:

SAA is as effective as septal myectomy in the LVOT gradient reduction in an experienced center but the management of the patients with HOCM is still a mysterious challenge.

ID: 29

Topic: **Cardiology » PI for SHD - ASD,VSD,PDA Closure**Presentation Type: **Oral**

EXPERIENCE IN THE USE OF HYBRID TECHNOLOGIES IN VENTRICULAR SEPTAL DEFECTS

Zhenis Koshkinbayev, Rustem Tuleutayev, Timur Ibragimov , Ualikhan Imammyrzayev

National Scientific Center of Surgery Named after A.N. Syzganov, Almaty, Kazakhstan

**Corresponding Author (doctor_zhenis@mail.ru)*

doctor_zhenis@mail.ru, rustemtuleutayev@gmail.com, ibragimovteimyr@mail.ru, ualikhan-88@mail.ru

Abstract Text

Background: Evaluation of early postoperative results of hybrid transventricular closure of the ventricular septal defect (VSD) under the control of transesophageal echocardiography (TEEchoCG).

Materials and methods of research: From April 2017 to February 2018 in the Department of Cardiac Surgery of the National Scientific Center for Surgery named after A.N. Syzganov, 20 patients underwent a surgery for transventricular closure of the VSD. Of these, 9 men (45%), 11 women (55%). The average age was 13.5 years. Echocardiography (EchCG) data before surgery on average: tricuspid valve regurgitation of the 1-2 degrees, the size of the left atrium (LA): 1.75 cm. Left ventricle: the end diastolic size (EDS) -4.1 cm; the end systolic size (ESS) -2.95 cm; The end diastolic volume (EDV) -84.5 ml; the end systolic volume (ESV) -22ml; The stroke volume (SV) - 61.5 ml; Ejection fraction (EF) -65%; The thickness of the ventricular septum (VS) -0.85 cm; The thickness of the posterior wall of the left ventricle (PWL) -0,55 cm; Systolic pressure in the right ventricle (SPRV) is 34 mm Hg.

The method consists of a small incision of 2-4 cm in the lower third of the sternum. Under the control of TEEchoCG through the right ventricle, a conductor is installed, through which the occluder is delivered and installed into the defect of the ventricular septum.

Results: All patients underwent a surgical treatment using TEEchoCG. The average duration of operation was 92min. On the 3rd day after the operation, a control echocardiography was performed: the regurgitation on the tricuspid valve of the 0-1 degree. LA: 1.5cm. LV: EDS-3,8 cm; ESS-2.35 cm; EDV-79.5 ml; ESV-23.5ml; SV-57ml; EF-70.5%; thickness of the VS-0,85cm; thickness of the posterior wall of the LV-0,55cm. Systolic pressure in RV-23 mm Hg. The average time of mechanical ventilation is 169min. All patients were discharged from the hospital with improvement on the 3rd day after the operation.

Conclusion:

The results of the early postoperative period demonstrate a good efficacy of hybrid operations in VSD with a good hemodynamic efficacy.

- 1) The advantage of this technique is a surgical treatment without artificial circulation and cardiac arrest.
- 2) Cosmetic effect (incision (2-4 cm)).
- 3) There is no need for blood transfusion.
- 4) Without the risk of x-ray exposure for the patient and specialists.
- 5) Setting the occluder for aneurysms with a defect and without the upper edge of the interventricular septum.
- 6) If necessary, a conversion to open bypass operation that can not be carried out under the conditions of catheter laboratory theatre.
- 7) Faster postoperative recovery.
- 8) Reduction of hospitalization time.

ID: 310

Topic: **Cardiology » PI for SHD - ASD,VSD,PDA Closure**Presentation Type: **Oral****A PATIENT WITH PULMONARY EMBOLISM DUE TO A THROMBUS STRADDLED TO PATENT FORAMEN OVALE****Muhammet Dural¹, Gurbet Özge Mert²**¹*Eskisehir Osmangazi University, Eskisehir, Turkey*²*Eskisehir Yunus Emre State Hospital, Tepebaşı/eskişehir, Turkey***Corresponding Author (muhammet_dural@hotmail.com)**muhammet_dural@hotmail.com, gozgeyun@gmail.com***Abstract Text****Case**

A female patient presented at our emergency department with chest pain, tachycardia and exertional dyspnea. Plasma D-dimer level was high with 84% of her oxygen saturation. Computed tomography revealed unilateral pulmonary embolism. Transesophageal echocardiography (TEE) revealed a large thrombus in the right atrium which is extending from the right atrium to the left atrium through a patent foramen ovale (PFO) (video-1). In addition, the pulmonary artery pressure was elevated with the enlarged right cardiac chambers which suggested pulmonary embolism. The right atrial thrombus was very mobile and protruded from the mitral valve into the left ventricle. Majority of the thrombus was floating in the right atrium, and a thin-long portion of it was in the left atrium (video-2). Patient referred to the surgical treatment and the thrombus and remnants in left and right atriums were cleared. Also, the PFO was closed concomitantly by direct suture.

Discussion

A right-sided cardiac thrombus can be catastrophic due to paradoxical embolism. If the straddling thrombus (the right and left atrium) presents, the patient should be treated immediately to prevent paradoxical embolism. Moreover, the best treatment option is not clear in this kind of clinical situation. Thrombolytic therapy is simple, rapid and effective, however, it may precipitate a paradoxical systemic embolism due to thrombus dislodgement, or result in haemorrhage because of natural mechanism on hemostasis of this treatment option. Although surgical embolectomy has potential complications, we prefer surgical treatment rather than thrombolytic therapy. We believe that surgery was the best option in our patient and the complete removal of the thrombus, closure of PFO and avoiding thrombus expulsions are crucial for the management of this case.

ID: 253

Topic: **Cardiology » PI for SHD - ASD,VSD,PDA Closure**Presentation Type: **Oral****PERCUTANEOUS CLOSURE OF A LARGE POST-MI VSD WITH AN ASD DEVICE****Mustafa Kürşat Tigen***Marmara University School of Medicine, İstanbul, Turkey***Corresponding Author (mktigen@yahoo.com)**mktigen@yahoo.com***Abstract Text**

50 years of male patient presented with chest pain and ECG findings compatible with anterior MI for two days and occluded LAD artery opened with a 3.0 x 28 mm DES immediately. Despite some clinical improvement cardiogenic shock complicated his clinical status and the patient was intubated. Transthoracic echocardiography revealed a large ventricular septal defect close to the apex as a mechanical complication. Cardiovascular surgeons refused early reparative surgery because of high perioperative mortality risk and percutaneous closure of the defect was the only choice for the management of the patient. An IABP was inserted and the patient was taken to cath-lab in the following day for closure procedure with the guidance of TEE. Defect size was detected 22 mm with TEE which was large for an available VSD device. An ASD device with 26 mm of size was selected for closure procedure after creating an A-V loop and advancing a 9F delivery sheath from the venous route. Delivery sheath was advanced to the aorta and left sided disc was opened. System was pulled back as a unit and left disc was placed to the defect and the procedure was ended-up with opening of right disc and releasing the device. Procedure was finalized with minimal left to right flow detected by TEE. Patient was transferred to coronary intensive care unit and vital parameters were stabilized. Although hemodynamic parameters were favorable renal function was deteriorated and the patient was referred for dialysis because of anuria. During his follow-up in intensive care patient was suffered from sepsis and despite appropriate antibiotic therapy he was died at the 7th day of his initial admission.

ID: 15

Topic: **Cardiology » Diagnosis and Treatment of Valvular Hearth Disease**Presentation Type: **Oral****PREVENTION OF INFECTIVE ENDOCARDITIS, SHOULD DEVELOPING COUNTRY HAVE A CONCERN WITH THE GUIDELINES?****Mona Kholeif¹**, Atif Alzahrani ¹, Abeer Alshukairi², Areej Mufti¹, Abdulhalim Kinsara¹¹*King Saud bin Abdulaziz University for Health Sciences, COM-J King Abdul Aziz Medical City-WR., Jeddah, Saudi Arabia*²*King Faisal specialist hospital & research center, Jeddah, Saudi Arabia***Corresponding Author (omahmed56@yahoo.com)**omahmed56@yahoo.com, atzahrani2008@hotmail.com, abeer_sh@doctor.com, muftiah@ngha.med.sa, akinsara@yahoo.com***Abstract Text****OBJECTIVE:**

The published guidelines of Infective endocarditis (IE) markedly restricting the use of antibiotic prophylaxis for prevention of IE resulted in some controversy. The aim of this study is to attempt to answer the question – Should the developing country have a concern of rising incidence of IE with the current guidelines?

METHODS:

Retrospective analysis of all reported cases of definitive IE based on modified Duke Criteria in tertiary hospital over a 5-year period.

RESULTS:

20 reported cases of IE , 9 males (45%) & 11 females, mean age 36 years (12 days- 72 years);One patient had history of rheumatic heart disease, 4 patients (20%) had congenital heart disease. 14 patients (70%) had history of a prior procedure.

Blood cultures were positive in 16 patients (80%), with culture-negative IE in 4 patients. The most common organisms were Staphylococcus spp. in 9 patients (45%), Enterococcus spp. was isolated in 2 patients (10%), Gram negative bacilli isolated in 2 patients, one Enterobacter & one Acinetobacter bummani. There was one case of streptococcal IE, the usual target for prophylactic antibiotics and he had received prophylactic antibiotics peri-procedurally. Most organisms were acquired nosocomially and/or after procedures which did not require prophylactic antibiotics under any previous or current guidelines.

CONCLUSION:

IE is uncommon disease in our practice representing only 0.017% of total admissions and complicating only one dental procedure out of 101,825. The current guidelines for IE antibiotic prophylaxis did not carry extra risk in developing country, but preferably we may continue to collect relevant data.

ID: 494

Topic: Cardiology » PI for SHD - ASD,VSD,PDA Closure

Presentation Type: Oral

PATENT DUCTUS ARTERIOSUS IN EARLY TERM INFANTS: NEED TREATMENT?

Birol Karabulut*Cigli Regional Training Hospital, Izmir, Turkey***Corresponding Author (dr.biolkarabulut@icloud.com)**dr.biolkarabulut@icloud.com*

Abstract Text

BACKGROUND:

Functional closure of the ductus arteriosus occurs within the first 24 hours in half of the term infants, within the first 48 hours in the other 40% group and the remaining 10% in the first 72 hours. The occurrence of anatomic closure is in 2-3 weeks. However, ductus arteriosus, which remained open between 37-39 weeks of gestation, causes respiratory morbidity, increased ventilation requirement, or not decreased ventilation support. Therefore, closure treatment required of ductus arteriosus is considered in these newborns. In this study, we aimed to investigate closure treatment required of ductus arteriosus in early term infants.

METHODS:

This study was performed with 126 early term infants between 37-39 weeks admitted in the neonatal intensive care unit of Buca Obstetrics and Gynecology Hospital between March 2016 - April 2018. In these patient's echocardiography due to clinical findings related to patent ductus arteriosus, the incidence of hemodynamically significant patent ductus arteriosus and necessity of closure therapy was investigated.

RESULTS:

The mean gestational age was 38.1 ± 0.57 week, mean birth weight was 3229 ± 313 gr, 54 (46.8%) of 126 newborns was male, 72 newborns (57.1%) was female, normal vaginal delivery ratio was 56.3%, C- section was 43.6%, mean ventilation day was 6.7 ± 1.3 (10.3%), 10.3% of surfactant requirement, the number of open patients with ductus arteriosus was 34 (26.9%), the number of patients with hemodynamic significant patent ductus arteriosus who required closure treatment was 14 (11.1%). The mean time of diagnosis and treatment of patients with hemodynamically patent ductus arteriosus was 2.2 ± 0.7 days, mean duct diameter was 3.9 ± 0.88 mm, and the mean left atrium / aortic root ratio was 2.5 ± 1.13 .

CONCLUSIONS:

As a result, patent ductus arteriosus, which affects premature infants born more than 37 weeks, affects newborns between the ages of 37-39 weeks called early term. In early term infants with respiratory distress, increased ventilation requirement, prolonged ventilation support suggest hemodynamically significant patent ductus arteriosus closure treatment required.

ID: 106

Topic: Cardiology » Diagnosis and Treatment of Valvular Hearth Disease

Presentation Type: Oral

UNUSUAL MITRAL BALLOON VALVULOPLASTY COMPLICATION: UNDEFLATED BALLOON

Ferhat Özyurtlu

*Special Grand Medical Hospital, Manisa, Turkey***Corresponding Author (fozyurtlu@yahoo.com)**fozyurtlu@yahoo.com*

Abstract Text

UNUSUAL MITRAL BALLOON VALVULOPLASTY COMPLICATION: UNDEFLATED BALLOON

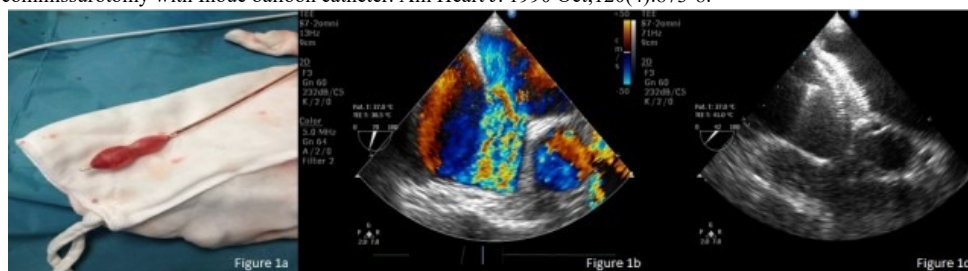
49-year-old female patient with exertional dyspnea complaint and severe mitral stenosis was referred to our clinic with the aim of mitral balloon valvuloplasty (MBV). The patient who doesn't have a significant case in the history, had sinus rhythm in her electrocardiography. In the electrocardiography, the mitral valve was rheumatic, valve area was 1.0 cm², left atrium was dilated, and there was a mild tricuspid insufficiency and mild pulmonary hypertension. Left ventricular ejection fraction was 65%. Thus, MBV was planned for the patient. By performing puncture of right femoral vein, atrial septostomy was applied. Later, with transesophageal echocardiography (TEE), mitral valve was moved through with the mitral balloon catheter (Toray inoue balloon catheter IMS-28) and the balloon was inflated. Right after that, the balloon was tried to be deflated; however, it was observed that its speed of deflation was quite slower than what is expected from normal deflations. At that moment, the patient started to have dizziness, and stasis findings in the image of spontaneous echo contrast in the left atrium in TEE was observed. Therefore, the balloon was withdrawn without waiting for it to deflate. The clinic and TEE findings of the patient were followed until they recovered. Along with this, atrial septal defect in the diameter of 18 mm (ASD) was observed in TEE. Therefore, after the intervention, the defect was occluded with 20mm ASD occluding device (Amplatzer Septal Occluder). After the operation, no residual shunt flow was observed and mitral valve size was measured 2.1 cm². The patient was taken to clinic follow-up. MBV complications are mortality (0-0.5%), cerebrovascular accidents (0.5-2%), cardiac tamponade (0.7-1%), mitral insufficiency requiring operation (0.9-2%), mitral insufficiency (15%), and atrial septal defects which are determined by color doppler (20-23%) (1). In a study, a significant correlation between postoperative residual atrial septal perforation and the duration of operation. However, the majority of these occlude in the process of one year (2). In the literature review, no case which has similar feature with the presented case was found.

Figure 1b,c. ASD after balloon withdrawal, ASD occluder.

Figure 1a. The image of undeinflated balloon after withdrawal

1-Mohamed Eid Fawzy. Mitral balloon valvuloplasty. J Saudi Heart Assoc. 2010 Jul; 22(3): 125–132.

2-Ishikura F, Nagata S, Yasuda S, Yamashita N, Miyatake K. Residual atrial septal perforation after percutaneous transvenous mitral commissurotomy with Inoue balloon catheter. Am Heart J. 1990 Oct;120(4):873-8.



ID: 454

Topic: **Cardiology » Diagnosis and Treatment of Valvular Hearth Disease**Presentation Type: **Oral****TRANSCATHETER CLOSURE OF RUPTURED SINUS OF VALSALVA WITH AN AMPLATZER MUSCULAR VSD OCCLUDER IN A PATIENT WITH AORTIC VALVE REPLACEMENT**

Yusuf Can, Harun Kılıç, Ramazan Akdemir, Ibrahim Kocayigit, Hakan Sacli

*Department of Cardiology, Sakarya Education and Research Hospital, Sakarya University, Sakarya, Turkey***Corresponding Author (dr.ycan@hotmail.com)**dr.ycan@hotmail.com, harunkilic@sakarya.edu.tr, ramazanakdemir@gmail.com, ikocayigit@gmail.com, mdhakans@yahoo.com***Abstract Text**

OBJECTIVE: Sinus of Valsalva rupture is a rare cardiovascular problems which may be acquired or congenital. sinus valsalva rupture occurs in the presence of sinus of Valsalva aneurysms (SoVAs). SoVAs are most commonly congenital in origin and occur in cases of infections, such as syphilis or endocarditis, and degenerative and inflammatory processes such as Marfan's and Behçet's disease. Rarely, iatrogenic causes, such as surgical trauma to aortic wall during aortic valve replacement (AVR). The aneurysms most commonly arise from the right coronary sinus of Valsalva and most frequently rupture into the right ventricle. The traditional treatment for ruptured SoVAs is surgery. However, they are also amenable to percutaneous transcatheter closure.

METHOD and RESULT: A 37-year-old male presented with complaints of dyspnea, palpitation, and atypical chest pain over a period of 3 months. On physical examination, a harsh continuous murmur was noted at the left sternal border without radiation to any regions. A two-dimensional (2D) with color Doppler echocardiography was performed and a ruptured SoV into the right ventricle detected. Then, a transesophageal echocardiography (TEE) was planned to evaluate the ruptured SoV and its relation to cardiac chambers. This TEE verified the signs noted on the 2D echocardiography. We searched for the underlying clinical situation for rupture of SoV without aneurysm formation in the patient. The patient was taken to the catheterization laboratory for evaluation of the ruptured SoV. Then, an aortography was performed to confirm echocardiographic findings, and a ruptured right SoV draining to the right ventricle was detected (Video 1). After taking angiograms, we attempted closure of the ruptured SoV. Firstly, a 6 Fr JR catheter was passed into the right ventricle using a hydrophilic guide wire (Terumo Corp., Tokyo, Japan). In the second step, the hydrophilic guide wire was exchanged for a 0.038 inch x260 cm guide wire for a 9 Fr delivery sheath. This was passed into the right ventricle through the ruptured side of the SoV and the JR catheter pulled back. The floppy segment of guide wire was delivered into the right ventricle. The delivery sheath was passed through the defect region into the right ventricle over the guide wire. The guide wire was pulled back and the sheath crossed the defect. An Amplatzer muscular VSD occluder device with its delivery system was introduced through the sheath. The disc on the right ventricle side was initially released, and after confirming its correct position on both the TTE and fluoroscopy, the aortic end was released by withdrawing the sheath further (Video 2). Prior to final release of the device, the position and residual shunt were reevaluated by TTE and mild shunt was seen. The device was deployed successfully, and following its deployment, aortography were done. Mild shunt was seen on angiograms. The patient was discharged uneventfully one day later on oral treatment of 100 mg of aspirin daily.

CONCLUSION: The retrograde approach for percutaneous closure of a ruptured SoV may be both safer and quicker than the antegrade approach. However, because of a lack of long-term follow-up results such as rate of embolization or residual shunt, we do not have enough data to evaluate its inferiority or superiority over the antegrade approach

ID: 367

Topic: **Cardiology » Percutaneous Coronary Interventions**Presentation Type: **Oral****AN UNUSUAL FATAL COMPLICATION DURING ALCOHOL SEPTAL ABLATION; SEVERE LAD VASOSPASM CAUSING CARDIAC ARREST****Atila İyisoy***Gülhane EAH, Ankara, Turkey***Corresponding Author (aiyisoy@hotmail.com)**aiyisoy@hotmail.com***Abstract Text**

Septal reduction therapy should be performed in hypertrophic obstructive cardiomyopathy patients who have drug-refractory symptoms. This can be applied either surgical myectomy or either alcohol septal ablation(ASA). We present a case report that coronary artery vasospasm occurred in the left anterior descending artery (LAD) during ASA, caused ventricular fibrillation (VF) and severe coronary spasm had been resolved successfully after stent implantation. A 52-old age man presented with exertional severe dyspnea and syncope. He had underwent surgical myectomy 12 years ago. Echocardiography revealed normal left ventricular systolic function; interventricular septum diameter, 25 mm; left ventricular outflow gradient is 75 mmHg at rest and 105 mmHg at provocation with systolic anterior movement of mitral valve. So we decided to perform ASA.

Coronary angiography showed normal LAD and suitable first septal branch for intervention (Fig. 1A). 2 cc 99% ethanol was slowly injected thorough over the wire balloon and 10 minutes later balloon was withdrawn. (Fig 1B,1C). Then the patient felt severe chest pain and fibrillated. We defibrillated the patient but the rhythm was not achieved; and we started the cardiopulmonary resuscitation. Emergent coronary angiography showed that coronary spasm caused severe occlusion in the LAD segment just after the first septal artery and impaired coronary flow nearly totally in the LAD just after septal artery (Fig 1D,1E). At that time, we decided to implant a stent due to the patient's serious condition. A 0,014-inch floppy guidewire was advanced to the distal LAD then a 3,5 x18 mm drug-eluting stent was advanced to the severe spasm segment and inflated at a nominal pressure at 10 atm (Fig. 1F,1G). Then cine angiogram showed us that there was no dissection and LAD flow was TIMI 3 (Fig. 1H) After intervention, we checked coronary balloon for any break because of any probability causing alcohol leakage into the LAD. And again, we controlled cineangiograms for any dissection; there was no coronary dissection image in the angiograms during viewing retrogradely. Subsequently, the patient was monitored in coronary care unit. LVOT gradient decreased to a maximum of 15 mmHg at provocation. Complete atrioventricular block occurred 3 days later ASA and became permanent so we implanted a DDD-R implantable cardioverter-defibrillator(ICD) 5 days later after ASA. The patient was discharged 5 days later procedure. In his 1.month follow-up; he was asymptomatic and LVOT gradient was 15 mmHg at provocation.

LAD occlusion can occur after ASA approximately 1-2% and sometimes it can be fatal. To our knowledge, this is the first case that severe LAD vasospasm occurred during ASA, caused cardiac arrest and a stent was implanted successfully.

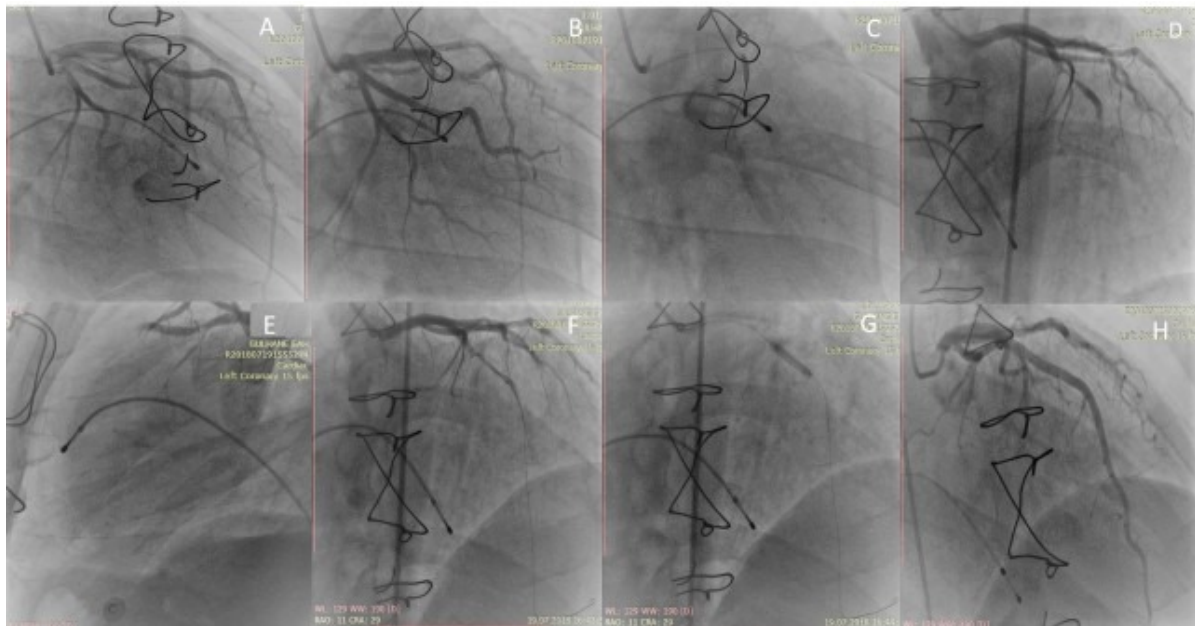


Figure 1. (A) Coronary angiography shows normal LAD and suitable first septal branch for intervention (B) 0,014-inch floppy guidewire and 2,5x20 mm over-the-wire balloon was advanced into septal artery. (C) OTW balloon was inflated. (D) Cine angiogram showed that coronary spasm caused severe occlusion in the LAD segment just after the first septal artery and impaired coronary flow nearly totally in the LAD on AP cranial view. (E) Coronary spasm in the LAD segment on lateral view (F) A 3,5 x18 mm drug-eluting stent was advanced to the severe spasm segment (G) A 3,5 x18 mm drug-eluting stent was inflated at a nominal pressure at 10 atm. (H) After stent there was no dissection and LAD flow was TIMI 3 on AP cranial view.

ID: 475

Topic: **Cardiology » Hypertrophic Cardiomyopathy**

Presentation Type: **Oral**

SUCCESSFULLY SECOND SEPTAL ARTERY OCCLUSION WITH ALCOHOL ABLATION IN A 74-YEAR-OLD HIPERTROPHIC OBSTRUCTIVE CARDIOMYOPATY'S PATIENT

Hakkı Şimşek, Lezgin Dursun, Ali Evsen, Hasan Kaya, Nizamettin Toprak

Dicle university heart hospital, diyarbakır, Turkey

**Corresponding Author (drhsimsek@gmail.com)*

drhsimsek@gmail.com, lezgindursun893@hotmail.com, ali_evsen@hotmail.com, dr_hasankaya@yahoo.com, ntoprak@dicle.edu.tr

Abstract Text

SUCCESSFULLY SECOND SEPTAL ARTERY OCCLUSION WITH ALCOHOL IN A 76-YEAR-OLD HIPERTROPHIC OBSTRUCTIVE CARDIOMYOPATY'S PATIENT

ENTRY

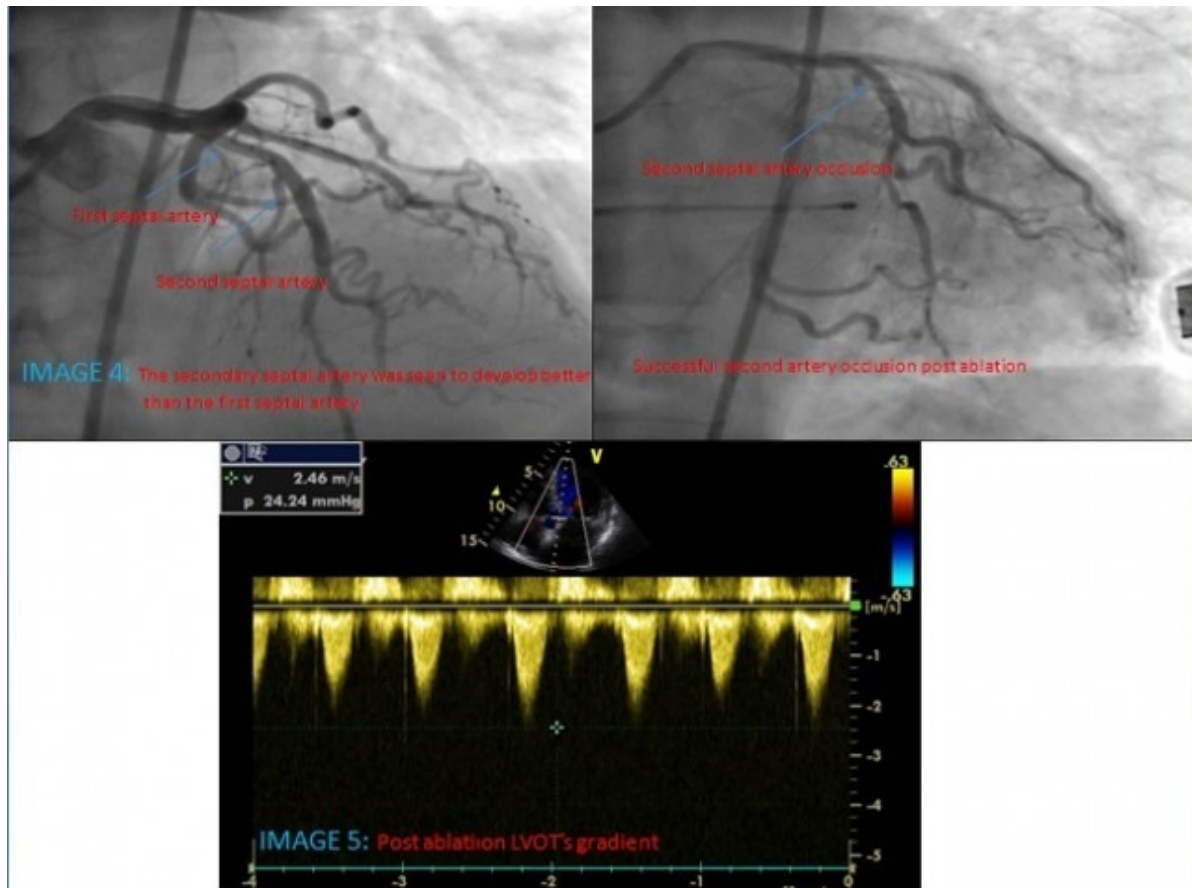
Alcohol septal ablation (ASA) is an alternative to surgical treatment in patients with hypertrophic obstructive cardiomyopathy (HOCM). By alcohol-induced necrosis, ASA increasing left ventricular outflow tract (LVOT) diameter and decreasing LVOT pressure gradient. Our patient is old female and although medical treatment functional capacity was class IV according to the New York Heart Association (NYHA).

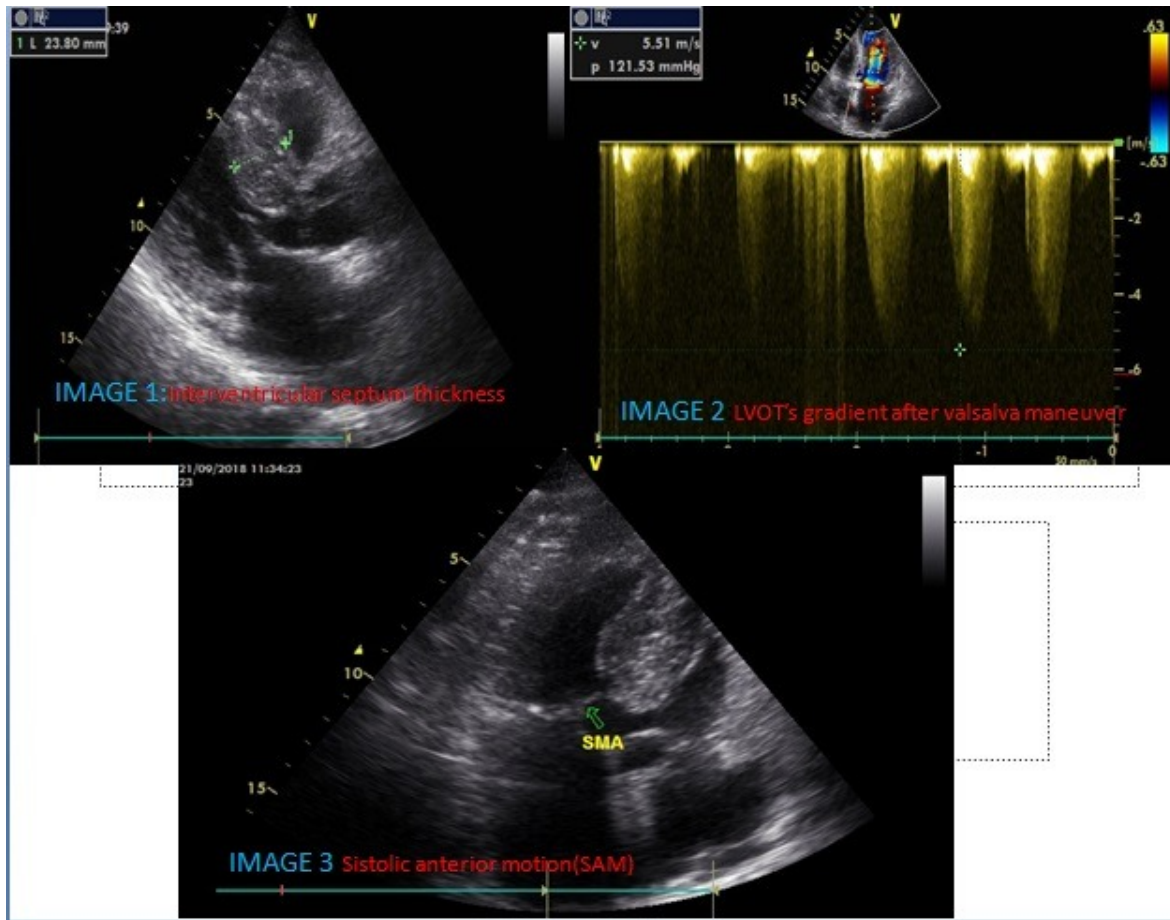
CASE

A 76-year-old female patient with history of known hypertrophic cardiomyopathy, hypertension and diabetes mellitus. She was admitted to our outpatient clinic with complaints of chest pain, shortness of breath and palpitations. The patient did not have a history of syncope and familial sudden cardiac arrest. Her functional capacity was NYHA class IV. Baseline electrocardiography was atrial fibrillation rhythm 105 beats/min. Strain pattern and hypertrophy findings were available. There was 3/6 severity of systolic murmur at the aortic focus. Arterial blood pressure 130/75 mmHg. In the echocardiography (TTE) of the patient, ejection fraction (EF) 60%, enlargement of the left atrium, diastolic interventricular septum thickness of 23 mm(IMAGE 1), LVOT's gradient after valsalva maneuver 121 mmHg(IMAGE 2) and sistolic anterior motion(IMAGE 3) and moderate eccentrically mitral regurgitation were observed at the mitral valve. Septal ablation has been decided.

Procedure: EBU was placed in the left coronary artery ostium with 3.5 and GF. The septal branches were evaluated. The secondary septal artery was seen to develop better than the first septal artery(IMAGE 4).Contrast echocardiography confirmed that second septal supplies the basal of the septum. Alcohol ablation was decided and temporary right ventricular pacemaker was placed. The second septal artery was pulled to 8 atm with over the wire (OTW) 2.0*12 mm balloon. 2 to 3 minutes apart 0.5 cc (total 2.5 cc) alcohol was given by OTW. No complication, operation was succesfully terminated.

Post- operation control echocardiography gradient with valsalva maneuver was 32 mmHg and her functional capacity regressed the NYHA class II and discharged with medical treatment. Two months later, the control was followed by gradient 24 mmHg(IMAGE 5) in echocardiography





ID: 477

Topic: Cardiology » Hypertrophic Cardiomyopathy

Presentation Type: Oral

SUCCESSFULLY ALCOHOL SEPTAL ABLATION IN THE HIPERTROPHIC OBSTRUCTIVE CARDIOMYOPATY ON THE YOUNG PATIENT

Hakkı Şimşek, Lezgin Dursun, Ali Evsen, Nizamettin Toprak

Dicle university heart hospital, Diyarbakır, Turkey

*Corresponding Author (drhsimsek@gmail.com)

drhsimsek@gmail.com, lezgindursun893@hotmail.com, ali_evsen@hotmail.com, ntoprak@dicle.edu.tr

Abstract Text

SUCCESSFULLY ALCOHOL SEPTAL ABLATION IN THE YOUNG PATIENT WITH HIPERTROPHIC OBSTRUCTIVE CARDIOMYOPATY

ENTRY

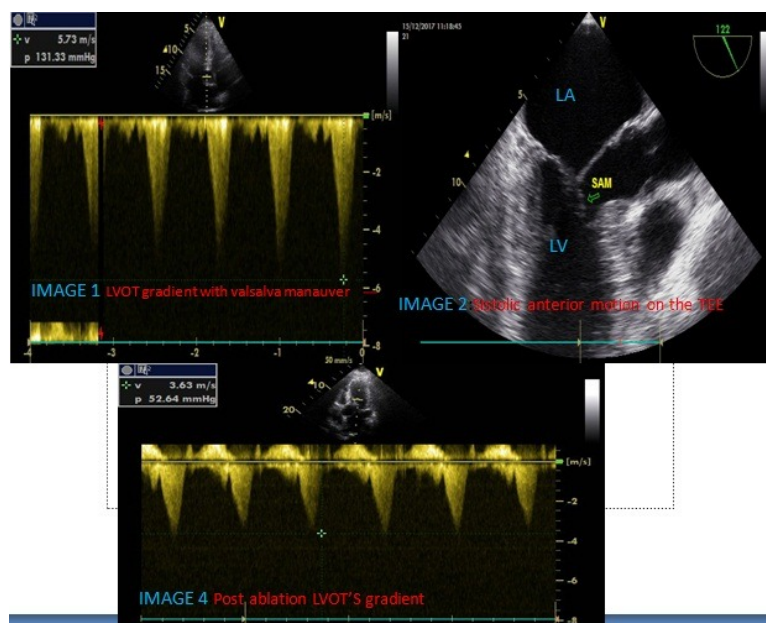
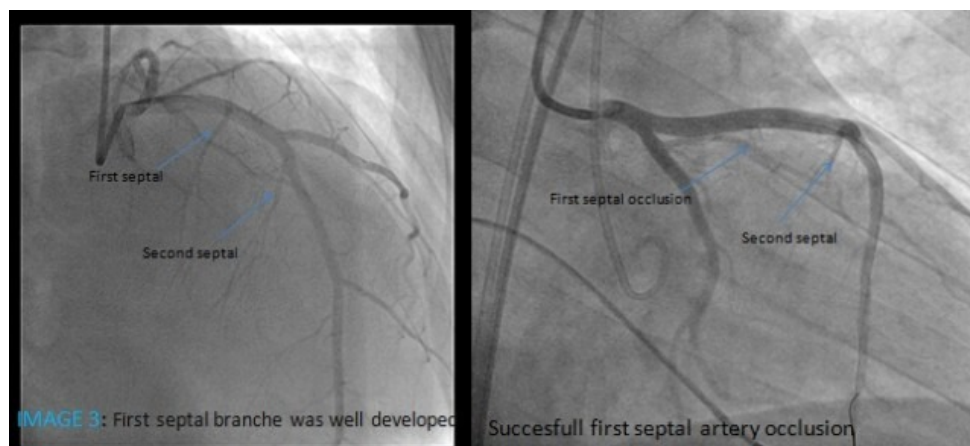
Alcohol septal ablation (ASA) is an alternative to surgical treatment in patients with hypertrophic obstructive cardiomyopathy (HOCM). By alcohol-induced necrosis, ASA increasing left ventricular outflow tract (LVOT) diameter and decreasing LVOT pressure gradient. Our patient is young male and functional capacity was class III according to the New York Heart Association(NYHA)

CASE

A 34-year-old male patient with no history of known systemic disease was admitted to our outpatient clinic with complaints of dispne and palpitations in the last few months. The patient did not have a history of syncope and familial sudden cardiac arrest. His functional capacity was class III according to the NYHA. Baseline electrocardiography was sinus rhythm 74 beats / min. Strain pattern and hypertrophy findings were available. There was 3/6 severity of systolic murmur at the aortic focus. Arterial blood pressure 135/80 mmHg. In the echocardiography of the patient, ejection fraction(EF) 60%, enlargement of the left atrium, diastolic interventricular septum thickness of 16 mm, LVOT's gradient after valsalva maneuver 131 mmHg (IMAGE 1) and systolic anterior motion(SAM)(IMAGE 2) were observed at the mitral valve. Septal ablation has been decided.

Procedure: EBU was placed in the left coronary artery ostium with 3.5 and GF. The septal branches were evaluated. First septal branche was well developed(IMAGE 3). Alcohol ablation was decided and temporary right ventricular pacemaker was placed. The first septal artery was pulled to 8 atm with OTW 2.0*12 mm balon.2 to 3 minutes apart 0.5 cc (total 2.5 cc) alcohol was given by OTW. No complication, operation was succesfully terminated.

Post- operation control echocardiography revealed gradient with valsalva maneuver was 52 mmHg(IMAGE 4) and his functional capacity regressed the class I according to the NYHA. Discharged with medical treatment. after one month control echocardiography detected 32 mmHg gardient.



Oral Presentations

Non-Invasive Electrocardiography: New Applications

Date: 29.03.2019 Time: 08:00 - 09:00 Hall: 5

ID: 357

Topic: Cardiology » Electrocardiography and Non Invasive Electrocardiology

Presentation Type: Oral

P WAVE PEAK TIME IS ASSOCIATED WITH INCREASED LEFT ATRIAL VOLUME INDEX IN HEMODIALYSIS PATIENTS

Ibrahim Yıldız¹, Cengiz Burak², Pınar Özmen Yıldız¹

¹Osmaniye State hospital, Osmaniye, Turkey

²Kafkas University, Kars, Turkey

*Corresponding Author (ibrahimyildiz79@yahoo.com)

ibrahimyildiz79@yahoo.com, cengizburaktyih@yahoo.com.tr, pinarozmen81@yahoo.com

Abstract Text

Objective: Increased left atrial volume index (LAVI) has been found to be related to increased mortality in hemodialysis patients. To date, several p wave parameters derived from 12-lead electrocardiogram including p wave terminal force in lead V1 (PTFV1), p wave dispersion (PWD_{DIS}) and maximum P wave duration (PWD_{MAX}) have been studied for the estimation of increased LAVI in different populations other than hemodialysis patients. In the current study, we evaluated the association of LAVI with p wave peak time (PWPT) which is newly introduced ECG finding, in hemodialysis patients.

Method: 79 hemodialysis patients (mean age: 53 ± 18 years; 55.7% were males) constituted the study population. P wave parameters including PWPT were calculated for each patient from ECG. LAVI was measured by 2- dimensional echocardiography. The study population was categorized as normal LAVI (≤ 28 mL/m²) group (n = 45) or increased LAVI (> 28 mL/m²) group (n = 34). The groups were compared according to demographic, clinical, laboratory, echocardiographic and electrocardiographic features.

Results: There was no statistically significant difference between the groups in terms of demographic, clinical, laboratory characteristics of the patients. Left ventricular ejection fraction, echocardiographic diastolic parameters, p wave morphology in V1, PWD_{MIN}, PWD_{MAX} were similar between the groups. Left ventricular mass index (97 ± 31 vs. 124 ± 30; p < 0.001), PTFV1 (27 (21-28) vs. 40 (27-46); p = 0.024), PWD_{DIS} (45 ± 15 vs. 53 ± 13; p = 0.015), PWPT that were obtained from V1 (PWPTV1) (60 ± 14 vs. 70 ± 14; p = 0.008), PWPT that were obtained from D2 (PWPTD2) (56 ± 14 vs. 71 ± 20; p < 0.001) were significantly higher in patients with increased LAVI. Multivariate logistic regression analyses were performed to identify the independent predictors of increased LAVI using the parameters that showed significant difference between the groups in univariate analyses. PWPTD2 was found to be an independent predictor of increased LAVI (odds ratio: 1.117; 95% confidence interval: 1.052-1.185; p < 0.001).

Conclusions: We showed that prolonged PWPT_{D2} was independently associated with increased LAVI, and it can be a better representative parameter for increased LAVI in hemodialysis patients.

Table Demographic characteristics, echocardiographic and electrocardiographic parameters of the patients

	Left atrial volume index (LAVI)			p value
	All patients n:79	Normal (≤ 28 mL/m ²) n:45	Increased (> 28 mL/m ²) n:34	
Age (years)	53 \pm 18	50 \pm 17	56 \pm 18	0.151
Male gender, n (%)	44 (55.7)	22 (48.9)	22 (64.7)	0.161
Body surface area(m ²)	1.71 \pm 0.22	1.74 \pm 0.20	1.67 \pm 0.23	0.171
Hypertension, n (%)	42 (53.2)	22 (48.9)	20 (58.8)	0.381
Smoking, n (%)	8 (10.1)	3 (6.7)	5 (14.7)	0.241
Diabetes mellitus, n (%)	16 (20.3)	8 (17.8)	8 (23.5)	0.529
Hyperlipidemia, n (%)	5 (6.3)	3 (6.7)	2 (5.9)	0.887
Glucose (mg/dL)	94 \pm 23	94 \pm 22	93 \pm 23	0.826
Blood urea nitrogen (mg/dL)	58 \pm 17	58 \pm 16	57 \pm 19	0.767
Creatinine (mg/dL)	8.3 \pm 2.1	8.4 \pm 1.8	8.1 \pm 2.4	0.424
Sodium (mmol/L)	138 \pm 3	138 \pm 3	138 \pm 3	0.778
Potassium (mmol/L)	5.0 \pm 0.7	5.1 \pm 0.7	4.8 \pm 0.6	0.133
Calcium(mg/dL)	8.4 \pm 0.6	8.5 \pm 0.6	8.3 \pm 0.5	0.330
Phosphorus(mg/dL)	5.9 \pm 13.9	4.1 \pm 1.4	8.3 \pm 21.0	0.187
Hemoglobin (g/dL)	11.2 \pm 1.8	11.3 \pm 1.8	11.2 \pm 2.0	0.824
Ferritin (ng/mL)	436.0-621.0	529.0-654.0	413.0-498.0	0.075
Left ventricular ejection fraction (%)	61 \pm 5	62 \pm 4	60 \pm 7	0.105
LVMI (g/m ²)	109 \pm 33	97 \pm 31	124 \pm 30	<0.001
LAVI(mL/m ²)	29 \pm 10	22 \pm 5	38 \pm 8	<0.001
E (cm/s)	76 \pm 22	73 \pm 21	79 \pm 23	0.204
A (cm/s)	85 \pm 20	86 \pm 20	85 \pm 19	0.832
E/A	0.9 \pm 0.3	0.9 \pm 0.3	1.0 \pm 0.4	0.180
Deceleration time	259 \pm 56	254 \pm 50	264 \pm 62	0.417
E' (cm/s)	8.8 \pm 3.4	9.2 \pm 3.6	8.2 \pm 3.1	0.183
E/E'	9.8 \pm 4.4	9.1 \pm 4.6	10.7 \pm 3.9	0.104
Heart rate (bpm)	79 \pm 13	82 \pm 13	76 \pm 12	0.137
QRS (ms)	100 \pm 17	98 \pm 17	102 \pm 16	0.357
Bundle branch block, n (%)	7 (8.9)	2 (4.4)	5 (14.7)	0.112
QRS fragmentation, n(%)	33 (41.8)	16 (35.6)	17 (50.0)	0.197
PTFV1 (mm \times ms)	34 21-45	27 21-28	40 27-46	0.024
P wave morphology in V1, n(%)				
Negative	3 (3.8)	2 (4.4)	1 (2.9)	0.905
Positive	22 (27.8)	13 (28.9)	9 (26.5)	
Biphasic	54 (68.4)	30 (66.7)	24 (70.6)	
PWD _{MIN} (ms)	75 \pm 16	76 \pm 14	72 \pm 17	0.241
PWD _{MAX} (ms)	123 \pm 19	120 \pm 20	125 \pm 17	0.378
PW _{DIS} (ms)	48 \pm 15	45 \pm 15	53 \pm 13	0.015
PWPT _{D2} (ms)	62 \pm 18	56 \pm 14	71 \pm 20	<0.001
PWPT _{V1} (ms)	64 \pm 15	60 \pm 14	70 \pm 14	0.008

Abbreviations: LVMI; left ventricular mass index, PWD_{MAX}; maximum p wave duration, PWD_{MIN}; minimum p wave duration, PWD_{DIS}; p wave dispersion, PWPT_{D2}; p wave peak time obtained from lead D2, PWPT_{V1}; p wave peak time obtained from lead V1, PTFV1; p wave terminal force in lead V1.

ID: 360

Topic: Cardiology » Electrocardiography and Non invasive electrocardiology

Presentation Type: Oral

ASSOCIATION OF P WAVE PEAK TIME WITH LEFT VENTRICULAR END DIASTOLIC PRESSURE IN PATIENTS WITH HYPERTENSIONCengiz Burak¹, Metin Çağdaş¹, Ibrahim Yıldız²¹Kafkas University Medical Faculty, Kars , Turkey²Osmaniye State Hospital, Osmaniye, Turkey

*Corresponding Author (cengizburakmd@gmail.com)

cengizburakmd@gmail.com, metin-cagdas@hotmail.com, ibrahimyildiz79@yahoo.com

Abstract Text**OBJECTIVE**

Hypertension is the most common disease leading to left ventricular diastolic dysfunction, thereby resulting in left ventricular end diastolic pressure (LVEDP) increment. The aim of this study was to evaluate whether there is any association between the P wave peak time (PWPT) and invasively measured LVEDP in hypertensive patients who underwent a coronary angiography due to a preliminary diagnosis of coronary artery disease.

METHODS

A total of 78 patients were included in this cross-sectional study. The PWPT was defined as the time from the beginning of the P wave to the peak, and it was calculated from the leads D2 and V1. In all patients, LVEDP was measured invasively while performing coronary angiography. The patients with a LVEDP of <16 mmHg formed the normal group (n=32) and those with a LVEDP of ≥16 mmHg formed the increased group (n=46).

RESULTS

The PWPT in the lead D2 were significantly longer in patients with an increased LVEDP, however; there was no significant difference between the groups in terms of PWPT in the lead V1. In multivariable analysis, the PWPT in the lead D2 (odds ratio: 1.257; 95% confidence interval: 1.094–1.445; p = 0.001) was found to be independent predictor of increased LVEDP. In terms of echocardiographic parameters, the left ventricular mass index, tissue Doppler velocities, E/E' ratio, and tricuspid regurgitation jet velocity were similar between the groups (p >0.05, for all), while the left atrial volume index was higher and E/A ratio was lower in patients with an increased LVEDP (p <0.05, for all). The LVEDP was positively correlated with P wave dispersion and PWPT in the lead D2, but not with PWPT in the lead V1.

CONCLUSIONS

In the current study, we found that prolonged PWPT in the lead D2 is an independent predictor of increased LVEDP, which might directly show a left ventricular diastolic dysfunction in hypertensive patients. Our findings may be valuable because this easily obtainable parameter may guide clinicians in detection of left ventricular diastolic dysfunction in hypertensive patients.

	All patients (n:78)	Normal LVEDP group (n:46)	Increased LVEDP group (n:32)	p value

Aortic systolic pressure (mmHg)	151 ±25	142 ±20	164 ±26	<0.001
Aortic diastolic pressure (mmHg)	82 ±14	75 ±9	91 ±14	<0.001
Left ventricular end diastolic pressure (mmHg)	15 ±7	10 ±4	21 ±6	<0.001
Left ventricular ejection fraction (%)	67 ±4	67 ±5	67 ±3	0.87
Left ventricular mass index (g/m ²)	71 ±20	68 ±15	75 ±25	0.272
Left atrial volume index (mL/m ²)	29 ±9	26 ±8	32 ±8	<0.001
Peak E-wave velocity (m/s)	0.67 ±0.22	0.69 ±0.17	0.64 ±0.28	0.127
Peak A-wave velocity (m/s)	0.73 ±0.17	0.70 ±0.18	0.76 ±0.17	0.464
E/A ratio	0.97 ±0.39	1.06 ±0.42	0.83 ±0.28	0.003
Septal e' (m/s)	0.09 ±0.03	0.09 ±0.03	0.09 ±0.03	0.87
Lateral e' (m/s)	0.13 ±0.05	0.13 ±0.04	0.12 ±0.05	0.159
E/e' ratio	6.86 ±2.92	6.74 ±2.39	7.04 ±3.58	0.815
TR systolic jet velocity (m/s)	2.50 ±0.42	2.50 ±0.43	2.49 ±0.42	0.655
Maximum p wave duration (ms)	104 ±17	99 ±13	112 ±20	0.004
P wave dispersion (ms)	26 ±13	21 ±11	33 ±13	0.001
Minimum p wave duration (ms)	78 ±11	78 ±9	79 ±14	0.684
P wave terminal force V1 > 40; n(%)	14 (26.9%)	3 (10.7%)	11 (45.8%)	0.004
P wave peak time D2 (ms)	59 ±18	50 ±12	73 ±16	<0.001
P wave peak time V1 (ms)	56 ±18	52 ±15	60 ±21	0.125

ID: 379

Topic: **Cardiology » Electrocardiography and Non Invasive Electrocardiology**Presentation Type: **Oral****THE RELATIONSHIP BETWEEN VITAMIN D DEFICIENCY AND ECG PARAMETERS ON VENTRICULAR REPOLARIZATION IN OTHERWISE HEALTHY INDIVIDUALS**Seyda Gunay¹, Sabri Seyis²¹*Bahcelievler State Hospital, Istanbul, Turkey*²*Istinye University, Istanbul, Turkey***Corresponding Author (seydagunaymedical@yahoo.com)**seydagunaymedical@yahoo.com, sabriseyis@yahoo.com***Abstract Text**

Background: Electrocardiographic (ECG) measurements such as Tpe (time from the peak of the T wave to the end), QTc dispersion (QTcd), Tpe/QTc are new measurements showing ventricular repolarization.. In this cross-sectional study, we aimed to investigate the relation of vitamin D deficiency with Tpe, QTcd, and Tpe/QTc in patients without known cardiac disease.

Methods: A total of 358 patients without a significant cardiac disease were included in the study. Patients were divided into 3 groups according to vitamin D levels: vitamin D deficiency (<20 ng/ml), vitamin D insufficiency (21-29 ng/ml) and those with normal vitamin D level (> 30 ng/ml). The baseline demographic, cardiologic and ECG features of the groups were compared. Correlation between Vitamin D level and ECG parameters was also explored.

Results: The study groups were comparable in terms of age, gender, cardiovascular risk factors and echocardiographic features. Tpe interval, Tpe/QTc ratio, and QTcd were significantly higher in patients with vitamin D deficiency/insufficiency than those with normal vitamin D level. Serum vitamin D level was negatively correlated with Tpe and QTcd, while it was positively correlated with Tpe/QTc ratio (p <0.001, for all).

Conclusion: According to our results low serum vitamin D level is associated with increased Tpe, QTcd and Tpe / QTc values in otherwise healthy individuals. In addition, serum vitamin D level was negatively correlated with Tpe and QTcd; and positively correlated with Tpe/QTc ratio. These findings indicate that there is a relationship between low vitamin D level and dispersion of ventricular repolarization.

	VitD deficiency (n=120)	VitD insufficiency (n=108)	Control group (n=130)	P
Age, year (mean + SD)	53.0±7.4	53.9±6.7	52.7±6.8	0.41
DM, n (%)	20 (17)	18 (17)	23 (18)	0.97
Systolic BP, mmHg	124.3±7.4	124.7±6.6	124.7±7.0	0.95
EF, %	61.5±3.1	61.4±3.1	61.6±2.7	0.94
LV end-diastolic diameter, cm	50.0±2.9	49.8±2.5	50.2±2.6	0.92
Tp-e interval, msec	86.6±4.8	83.0±4.3	69.2±6.8	<0.001
QTc, msec	417.3±8.8	414.7±7.1	416.8±7.6	0.027
QTc dispersion	56.0±6.0	54.0±5.3	46.4±5.8	<0.001
Tp-e / QTc	0.21±0.01	0.20±0.01	0.17±0.02	<0.001
Serum VitD, ngdL	7.9±3.0	20.1±2.7	30.3±4.2	<0.001
Creatinine, mg/dL	1.02±0.14	1.02±0.17	1.0±0.16	0.89
Hemoglobin, g/dL	12.5±0.9	12.5±0.8	12.6±0.8	0.85
Calcium, mg/dL	9.25±0.39	9.34±0.37	9.37±0.37	0.040
Phosphorus, mg/dL	4.10±0.32	4.10±0.29	4.12±0.30	0.90

ID: 426

Topic: Cardiology » Electrocardiography and Non invasive electrocardiology

Presentation Type: Oral

EFFECT OF HEROIN ON ELECTROCARDIOGRAPHIC PARAMETERS**Murat Selçuk**¹, Ersin Yıldırım², Faysal Şaylık³¹Sancektepe Şehit Prf. Dr. İlhan Varank Education And Research Hospital, Istanbul, Turkey²Umraniye Education And Research Hospital, Istanbul, Turkey³Van Education And Researc Hospital, Van, Turkey

*Corresponding Author (murat-slck@hotmail.com)

murat-slck@hotmail.com, ersinyil44@gmail.com, kardiyologfaysal@me.com

Abstract Text

Variables	Heroin + n=66	Heroin - n=70	P
Heart Rate	77.2±12.8	71.4±11.2	0.02
QT	341.5±25.8	379±45.2	<0.01
QTc	385.1±29.1	411.3±51.7	<0.01
Tpe	65.4±10.8	73.3±10.1	<0.01
Tpe/QT	0.19±0.03	0.2±0.03	NS
Tpe/QTc	0.17±0.03	0.18±0.03	NS

Objective: Addiction to heroin is currently an important health problem. However, despite being such an important health problem, knowledge on the cardiac effects of heroin addiction is limited. The aim of this study was to investigate effects of heroin addiction, on electrocardiographic parameters.

Methods: A total of 136 individuals including 66 patients using heroin via the smoking method as the study group and 70 healthy individuals with no drug addiction as the control group were included in the study. Patients using heroin via the injection method were excluded. Electrocardiographic evaluation of those using heroin was performed and compared with those of the control group. Results: Heart rate (77.2±12.8 vs 71.4±11.2, p=0,02) in the heroin group were found to be higher compared to the control group. QT(341.5±25.8 vs 379±45.2, p<0,01), QTc intervals(385.1±29.1 vs 411.3±51.7, p<0.01) and T peak to end time(Tpe) (65.4±10.8 vs 73.3±10.1, p<0.01) were significantly shorter in the heroin group. No difference was observed between the groups with regard to Tpe/QT and Tpe/QTc ratios.

Conclusion: Heroin addiction significantly affects the QT, QTc and Tpe time intervals. The arrhythmia effects of these parameters are well known and we should be more attention to the electrocardiographic parameters of these patients.

ID: 522

Topic: **Cardiology » Electrocardiography and Non Invasive Electrocardiology**Presentation Type: **Oral**

VITAMIN D INSUFFICIENCY AND DEFICIENCY IS ASSOCIATED WITH VENTRICULAR REPOLARIZATION ABNORMALITIES

Denizhan Bagrul

Rize Recep Tayyip Erdogan University, Rize, Turkey

**Corresponding Author (denizhanbagrul@hotmail.com)*

denizhanbagrul@hotmail.com

Abstract Text

Objective: Several studies have demonstrated associations between vitamin D deficiency and cardiovascular disease-related death, namely sudden arrhythmic death. Prolongation of the peak and the end of T wave (Tp-e) has been recently reported to be associated with ventricular arrhythmias. Also, Tp-e/QTc ratio, JTc duration, and JT dispersion are used as new indexes of ventricular arrhythmogenesis. This study aimed to assess ventricular repolarization in patients with vitamin D deficiency by using new ventricular repolarization indexes.

Methods: The study included 50 adolescent patients with vitamin D deficiency, 50 adolescent patients with vitamin D insufficiency and 50 age-matched controls (vitamin D level >30ng/ml) between March and December 2018 at our institution. QTc duration, QTc dispersion, JTc duration, JT dispersion, Tp-e interval and Tp-e/QTc ratio were determined using electrocardiograms. Also a transthoracic echocardiographic investigation was performed on all patients.

Results: There were no differences in demographic findings, systolic and diastolic blood pressure, and echocardiographic findings between the groups. Tp-e duration was significantly longer in patients with vitamin D deficiency or efficacy ($p < 0.001$). Similarly, Tp-e / Qtc, QTc dispersion and JT dispersion were found to be increased ($p < 0.001$, $p = 0.025$, $p = 0.05$, respectively). QTc and JTc intervals did not differ between the groups.

Conclusions: In our study, vitamin D levels below 30 ng/ml were found to be associated with increased Tp-e, Tp-e / QTc ratio, QTc dispersion, and JT dispersion. These results show the abnormalities in the distribution of ventricular repolarization in patients with vitamin D deficiency and increased risk of malignant arrhythmias. In addition, these results support that the clinical findings of vitamin D deficiency may occur in values less than 30 ng/ml, rather than 20 ng/ml.

Table 1. Comparison of demographic, echocardiographic and electrocardiographic characteristics of groups.

	25(OH)D level of <20 ng/ml (n=50)	25(OH)D level of 21-29 ng/ml (n=50)	25(OH)D level of >30 ng/ml (n=50)	P value
Demographic characteristics				
Age (years)	14.8 ± 3.8	14.7 ± 3.6	14.7 ± 3.8	0.956
Gender				0.975
Boys (n,%)	26(52%)	25(50%)	25(50%)	
Girls (n,%)	24(48%)	25(50%)	25(50%)	
Body mass index (kg/m ²)	20.3 ± 2.3	20.6 ± 2.5	20.6 ± 2.3	0.844
Blood pressure				
Systolic blood pressure	107.2 ± 10.2	105.8 ± 10.5	104.1 ± 9.8	0.188
Diastolic blood pressure	62.6 ± 7.9	62.0 ± 8.2	63 ± 9.2	0.256
Echocardiographic characteristics				
Ejection fraction	68.1 ± 5.7	69.1 ± 5.9	68.4 ± 5.6	
Fractional shortening	38.2 ± 4.1	39.2 ± 4.8	38.0 ± 4.6	0.356
LVEDd	40.7 ± 5.8	41.4 ± 6.0	41.1 ± 6.1	0.4
LVEDS	24.4 ± 3.3	25.3 ± 4.0	24.6 ± 3.8	0.642
LAD	24.2 ± 2.4	25 ± 2.5	24.4 ± 2.4	0.784
LVMPI	0.33 ± 0.04	0.32 ± 0.03	0.34 ± 0.04	0.656
TAPSE (mm)	23.0 ± 3.8	23.6 ± 3.4	23.5 ± 3.6	0.822
Mitral E (m/sn)	1.72 ± 0.38	1.82 ± 0.4	1.77 ± 0.41	0.198
Mitral A (m/sn)	1.05 ± 0.34	1.1 ± 0.41	1.08 ± 0.37	0.112
Mitral E/A (m/sn)	1.51 ± 0.34	1.54 ± 0.32	1.59 ± 0.38	0.184
Electrocardiographic characteristics				
Heart Rate (bpm)	88.13 ± 13.74	90.13 ± 14.56	88.25 ± 13.25	0.344
QRS (ms)	81.1 ± 14.5	82.4 ± 15.4	82.5 ± 15.3	0.54
QT (ms)	372 ± 25.09	377 ± 25.09	378 ± 25.09	0.256
QTc (ms)	398 ± 25.09	396 ± 25.09	392 ± 25.09	0.188
JTc (ms)	315.4 ± 19.2	312 ± 22.1	308.09 ± 25.09	0.105
Tp-e (ms)	82.2 ± 8.8	82.0 ± 8.6	70.4 ± 10.4	<0.001
Tp-ec	90.9 ± 8.6	92.4 ± 8.6	77.2 ± 8.6	<0.001
Tp-e/QTc	0.21 ± 0.02	0.21 ± 0.02	0.17 ± 0.02	<0.001
QTd (ms)	64 ± 5.2	62.4 ± 5.9	56.1 ± 4.4	0.025
JTd	28.72 ± 11.2	29.7 ± 10.2	24.52 ± 9.3	0.05

ID: 578

Topic: **Cardiology » Acute Coronary Syndromes**Presentation Type: **Oral****CAN OUR BLOOD GROUPS DETERMINE OUR LIFE EXPECTANCY?**Gulcin Sahingoz Erdal¹, **Ismail Biyik**²¹*Bakirkoy Dr. Sadi Konuk Education and Research Hospital, Istanbul, Turkey*²*Usak Universty, School of Medicine, Education and Research Hospital, Usak, Turkey***Corresponding Author (gulcinctf@hotmail.com)**gulcinctf@hotmail.com, ismailbiyikmd@yahoo.com***Abstract Text**

Background: Cardiovascular diseases are the leading cause of death worldwide. The relationship between ABO blood group and hemostasis attracted many researchers. Following the studies examining the relationship between deep vein thrombosis and blood groups, the relationship between blood groups and coronary artery disease and survival was also of interest. The relationship between the blood groups without O and the risk of arterial thromboembolic disease including ischemic heart disease and peripheral vascular disease has been supported many studies. Hereditary thrombophilic factors such as factor V Leiden and prothrombin G20210A mutation are also responsible for a moderate increase in thrombotic risk, and some authors also suggest ABO blood group analysis when evaluating the risk profile in thrombophilic individuals.

In this study, we aimed to investigate the relationship between long-term mortality and survival with ABO blood group in patients with acute coronary syndrome.

Methods: 192 patients followed for 72 months due to acute coronary syndrome, showing a balanced distribution for ejection fraction, additional diseases and age, were included in the study. We examined the relationship between blood groups and survival. Hereditary mutation analyzes such as factor V Leiden gene mutation, Factor VIII and von Willebrand factor levels, which were not routinely examined, were not included in the study data. Blood groups of patients were recorded. Of the 192 patients followed, 41 (21.35%) had O blood group, 26 (13.54%) had B blood group, 19 (9.9%) had AB blood group, 106 (55.21%) had A blood group.

Results: In the survival analysis according to individual blood groups; there was no statistically significant difference between the groups. When the patients were divided into two groups as O blood group and those without O blood group, there was 24.39% mortality in those with O blood group and 15.23% mortality in those without O blood group. Although it was not statistically significant, in patients with O blood group, an increasing tendency was observed in 72 month mortality ($p > 0.05$). In the survival-month comparison of both groups; although it was not statistically significant, there was a decreasing tendency in survival in patients with O blood group (62.41 ± 21.47) compared with non-O blood group (65.95 ± 8.17) ($p > 0.05$).

Conclusions: In this study, although it was not able to reach statistical significance limit, a decreasing tendency in long-term survival was observed in patients with O blood group compared to those without O blood group in patients with acute coronary syndrome. Having O blood group may be associated with poor prognosis in patients with acute coronary syndrome, regardless of other etiological factors. The results should be confirmed by larger-scale and well-planned prospective studies.

Key words: acute coronary syndrome, ABO blood groups, mortality, survival

Oral Presentations

Venous Thrombo embolism and Pulmonary Hypertension: New Diagnostic and Therapeutic Approaches

Date: 29.03.2019 Time: 09:00 - 10:00 Hall: 5

ID: 495

Topic: **Cardiovascular Surgery » Pulmonary Hypertension Summit**

Presentation Type: **Oral**

TITLE: ANESTHETIC CONSIDERATIONS FOR A PARTURIENT WITH PULMONARY HYPERTENSION: EXPERIENCE OF 20 CASES

Zerzina Rahman

National Heart Foundation Hospital & Research Institute, Dhaka, Bangladesh

**Corresponding Author (bannya84@gmail.com)*

bannya84@gmail.com

Abstract Text

Background: Women of reproductive age with pulmonary hypertension have a high risk of morbidity and mortality during pregnancy. The failure to increase cardiac output leads to heart failure whereas more risks are presented with hypercoagulability and decrease in systemic vascular resistance. There is no evidence that new advanced treatments for pulmonary hypertension decrease the risk, however some encouraging results have been reported. Nevertheless, pregnancy is still regarded as contraindicated in women with pulmonary hypertension. When pregnancy occurs and termination is declined, pregnancy and delivery should be managed by multidisciplinary services with experience such as cardiology, nephrology along with gynecology & obstetrics and anesthesiology in the management of both pulmonary hypertension and high-risk pregnancies. Requirement of cardiac care unit or Intensive care unit may be pre-emptively counseled.

We have incidentally found 20 cases of pulmonary hypertension with pregnancy. Some developed this associated morbidity beforehand and diagnosed during the antenatal check up at the late phase of pregnancy. Some were diagnosed earlier and advised not to conceive but the counseling was not followed properly.

We followed these cases and tried to give the utmost support with multidisciplinary approach during delivery with caesarean section. This study is a reporting of 20 such cases with their outcome.

Methods: Twenty cases were randomly found during a ten years period when they come for caesarean section. All of them are within 20 to 40 years of age and within their reproductive life. They were divided into two groups, group A- those who were diagnosed early during anti natal checkup and under treatment throughout the period and group B- those who are incidentally diagnosed at the time of delivery and never or irregularly come before for anti natal checkup. Group A and Group B patients are then subdivided into general anesthesia and regional anesthesia subgroup. In all the cases PH is not well controlled or moderately controlled. Results are furnished in the Table and graph below and statistical analysis done.

Result:

Table 1:

	Group A (n=12)		Group B(n=8)	
	GA(n=8)	Regional(n=4)	GA(n=4)	Regional(n=4)
Pulse (Mean)	94±6	90±4	92±5	91±6
BP(Mean)	100/60±15	100/70±10	110/55±10	107±10
SPO2(Mean)	92±5	98±2	95±4	98±2
lungs/creps(Mean)	++	+	+++	+
Inotrope need(Mean)	8	4	4	4

Table 2:

Outcome	Group A(n=12)	Group B(n+8)		
	GA(n=8)	Regional(n=4)	GA(n=4)	Regional(n=4)
Mortality	4	1	2	1
Morbidity	3	1	2	2
Good recovery	1	2	0	1

Conclusion: Pulmonary hypertension is associated with high mortality and morbidity risks for the mother. Although women with severe pulmonary hypertension seem to be at higher risk, pregnancy is therefore contraindicated, but if a woman chooses to continue pregnancy, multidisciplinary care in highly specialized services is mandatory. New targeted anti-pulmonary hypertension therapy may decrease the risk.

ID: 307

Topic: **Cardiology » PI for SHD - Others**Presentation Type: **Oral****THE ROLE OF THE SERUM BILIRUBIN LEVELS IN DETERMINING THE VENOUS THROMBOEMBOLISM**Hakan Duman, Songül Özyurt, Turan Erdoğan, Bilge Yılmaz Kara, **Murtaza Emre Durakoğlugil***Faculty of Medicine, Recep Tayyip Erdoğan University, Rize, Turkey***Corresponding Author (drhakanduman@hotmail.com)**drhakanduman@hotmail.com, drsongul@gmail.com, drturane@yahoo.com, drbilgeyilmaz@hotmail.com, emredur@hotmail.com***Abstract Text**

WBC 1.17 (0.98-1.41) 0.082 Gender 0.68 (0.32-1.43) 0.320 Objective: Venous thromboembolism (VTE) is a disease that includes both deep vein thrombosis (DVT) and pulmonary embolism (PE). Bilirubin is an endogenous anti-inflammatory marker associated with atherothrombosis. The purpose of our study is to investigate the association of serum bilirubin levels with the presence of VTE.

Methods: A total of 103 patients with VTE (distal DVT, n=34; proximal DVT, n=30; PE, n=39) and 50 control subjects were cross-sectionally enrolled. Peripheral venous duplex ultrasonography and computed tomography was used for the diagnosis of VTE. Fasting blood samples were drawn for biochemical analyses.

Results: Baseline characteristics were not different between groups. VTE group had lower bilirubin level (9.0 ± 2.6 vs. 7.3 ± 3 $\mu\text{mol/L}$, $p=0.001$), and higher high-sensitive C-reactive protein concentration (hs-CRP) [0.8 ($0.3-2$) vs 1.1 ($0.2-3$) mg/L , $p=0.008$], and white blood cell (WBC) count (7.4 ± 1.5 vs $8.2 \pm 2.7 \times 10^9/\text{L}$, $p=0.02$) compared with control subjects. In the performed analysis of variance, the levels of total-direct bilirubin and hs-CRP levels were clearly different among the control groups and VTE subgroups (distal and proximal DVT, and PTE). The receiver-operating characteristic curve (ROC) analysis showed a cut-off value of 8.9 $\mu\text{mol/L}$ for total bilirubin (sensitivity: 74%, specificity: 55%) and an area under curve (AUC) of 0.659 ($p < 0.001$).

Conclusions: Bilirubin, hs-CRP, and WBC were independently associated with venous thromboembolism.

Keywords: thromboembolism, bilirubin, pulmonary embolism, antioxidant

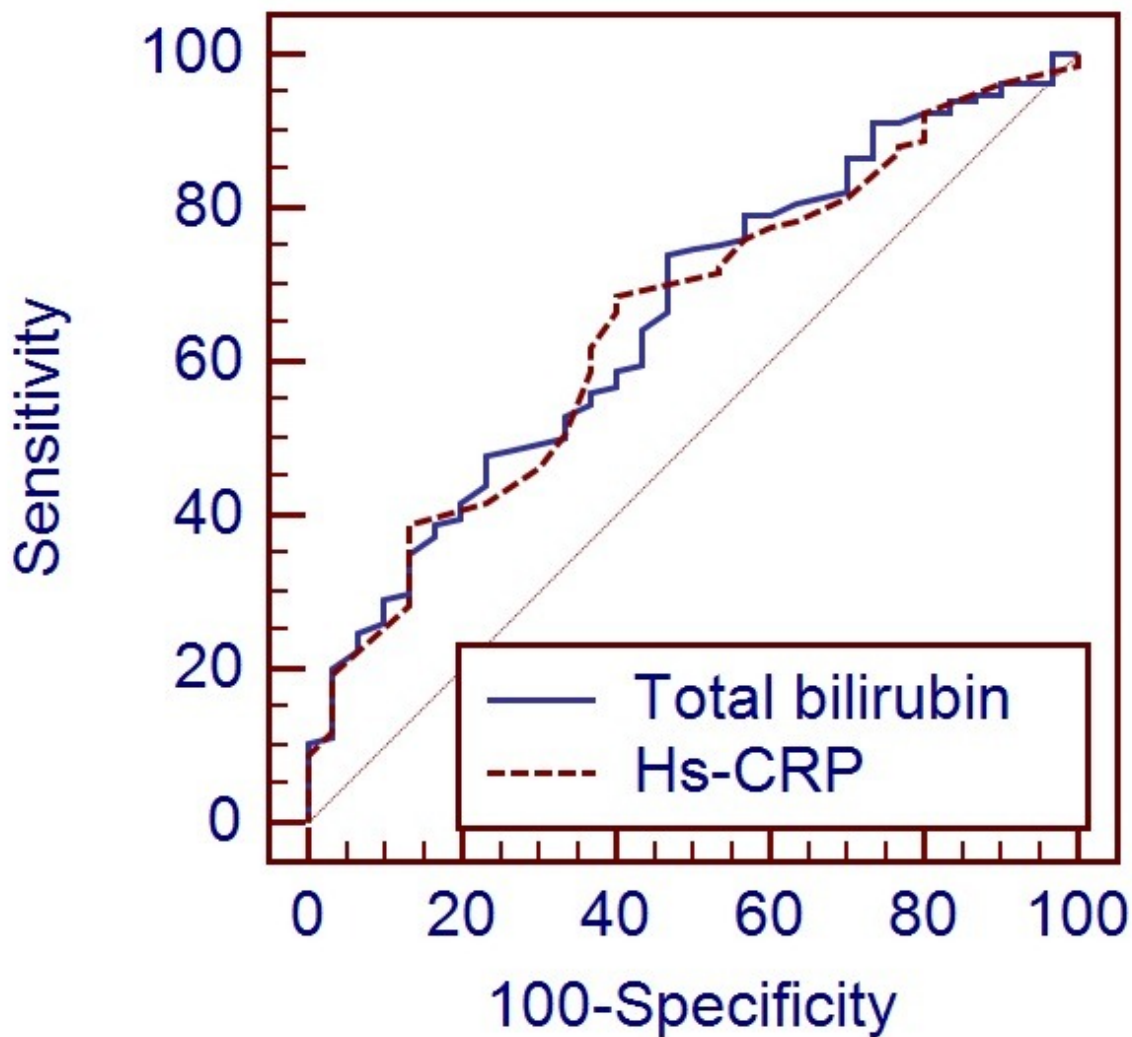


Table. Multivariate Logistic Regression Analyses Demonstrating Association of Variables with the presence of Venous Thromboembolism.

Total Bilirubin	0.82 (0.73-0.94)	0.004
hs-CRP	2.52 (1.24-5.09)	0.010
WBC	1.17 (0.98-1.41)	0.082
Gender	0.68 (0.32-1.43)	0.320

ID: 257

Topic: **Cardiovascular Surgery » Risk Management in Cardiovascular Diseases**Presentation Type: **Oral**

RELATIONSHIP BETWEEN CHA2DS2-VASC, R2CHADS2 SCORE AND ECOCARDIOGRAPHIC PARAMETERS, PESİ, MORTALITY IN PATIENTS WITH ACUTE PULMONARY THROMBOEMBOLISM.

Pelin Aladağ

Health Sciences University, Türkiye Yüksek İhtisas Training and Research Hospital, Ankara, Turkey

**Corresponding Author (aladagpelin@gmail.com)*

aladagpelin@gmail.com

Abstract Text

Variables	Univariate Regression Analysis		Multivariate Regression Analysis	
	p value	Odds ratio (%95 confidence interval)	p value	Odds ratio (%95 confidence interval)
Age	0.001	1.038 (1.015-1.062)		
Creatinine	0.001	2.923 (1.515-5.641)		
Hemoglobin	0.010	0.845 (0.743-0.961)	0.035	0.780 (0.619-0.983)
d-dimer	0.003	1.000 (1.000-1.000)		
R2CHADS2 score	<0.001	1.419 (1.186-1.697)		
PESI	<0.001	1.640 (1.270-2.118)	0.003	2.101 (1.291-3.419)
Troponin	<0.001	15.717 (3.674-67.240)	0.006	27.229 (2.573-288.116)
Right ventricular dilatation	0.031	1.949 (1.063-3.574)		
COPD	0.008	2.648 (1.294-5.416)		

Aim: Acute pulmonary embolism is one of the most common fatal cardiovascular diseases. Therefore, it is important to diagnose and perform a risk stratification of patients with acute PE. In this study, the association between CHA2DS2-VASc scores and mortality was investigated in patients with acute PE. In addition, we investigated the relationship between CHA2DS2-VASc score and the factors which may influence the mortality such as right ventricular dilatation, pulmonary embolism severity index (PESI), subclinical types (massive, submassive and non-massive). Also, the second aim of our study was to investigate the relationship between mortality and other parameters with the R2CHADS2 score in which renal dysfunction was added to the CHADS2 score. *Materials and Methods:* This research is examined retrospectively on the patients who are presented to the emergency department. It involves the patients who are over the age of 18 and whose pulmonary embolism diagnosis is proven by computerized tomography and pulmonary angiography. Finally, 301 appropriate patients were enrolled in to the study. In the study, patients were divided into two groups as exitus and non-exitus. Demographical data of the patients are examined and parameters, especially CHA2DS2-VASc and R2CHADS2 scores, which are thought to be influencing on mortality are compared with each other within those two groups. Regression analysis was performed to determine the relationship between the variables and mortality. *Results:*

157 of 301 patients examined in this study are men. The median age of the patients is determined as 68 (56-76). Analyses demonstrate that 43,5% of the patients have deep vein thrombosis, 10,9% of them have acute coronary syndrome story, 4,6% of them have heart failure, 6,6% of them have stroke story, 13,2% of them have COPD, 40,5% of them hypertension and 23,2 % of them have diabetes mellitus. When patients were grouped according to PESI index; 20.2% was very low-risk, 28.9% was low-risk, 30% was moderate-risk, 15.2% was high-risk, 5.7% was very high-risk. 20.9% of the patients died in one year period. Advanced age, high creatinine, low GFR and hemoglobin levels, high R2CHADS2 score and right ventricular dilatation were found to be statistically significant in the patients who died. The CHA2DS2-VASC score was not significantly different between the two groups. However, high CHA2DS2 -VASC and R2CHADS2 scores were found to be significantly associated with high-risk PESI subgroups, massive PE and right ventricular dilatation. The independent predictors of the mortality were investigated by the univariate and multivariate regression analyses. In multivariate regression analysis, age, creatinine, hemoglobin, PESI, troponin I, R2CHADS2 score, right ventricular dilatation, and COPD were found to be correlated with mortality. In multivariate regression analysis, hemoglobin, PESI, and troponin I were found to be independent predictors of mortality. Conclusion: CHA2DS2-VASC score was found to be correlated with right ventricular dilatation, PESI and PE subclinical types in patients with acute PE and R2CHADS2 score is related to mortality and the other parameters. In addition, hemoglobin value was found to be a predictor of mortality, independent of other factors. These results indicate that CHA2DS2-VASC and R2CHADS2 score and hemoglobin value can be used for additional prognostic information in acute PE patients.

ID: 40

Topic: Cardiology » Diagnosis and Treatment of Pulmonary Hypertension

Presentation Type: Oral

PROGNOSTIC VALUE OF ELEVATED MONOCYTE TO HDL CHOLESTEROL LEVEL FOR PULMONARY THROMBOEMBOLISM

Nizamettin Selçuk Yelgeç

*İstanbul Dr. Siyami Ersek Göğüs Kalp ve Damar Cerrahisi Eğitim ve Araştırma Hastanesi, İstanbul, Turkey***Corresponding Author (yelgec@gmail.com)**yelgec@gmail.com*

Abstract Text

BACKGROUND: Acute pulmonary embolism (PE) is a common and frequently fatal form of venous thromboembolism. Clinical studies have indicated that elevated Monocyte to HDL Cholesterol (M/H) is an independent risk factor for cardiovascular events. The aim of this study was to investigate the prognostic value of M/H in predicting the 30-day pulmonary thromboembolism-related clinical outcome

METHODS: Between January 1, 2014, and February 1, 2018, a total of 412 patient included in this retrospective single-center study. Clinical data, laboratory parameters, The M/H levels were recorded. Mortality rate at 30 days was investigated as the clinical outcome.

RESULTS: In our study population, 40 patients (9.7 %) died within 30-days. In deceased patients, PESI scores, monocytes were higher, LDL and HDL cholesterol levels were lower when compared to the survived patients. In addition, M/H was significantly higher in the deceased group (14.35 ± 1.75 vs 10.40 ± 1.40 , $p < 0.01$). In multivariate regression analysis; PESI scores (OR: 1.08 95% CI: 1.03-1.13, $p < 0.02$), right ventricular diameter (OR: 9.52 95% CI 4.25-46.13, $p < 0.01$), total cholesterol (OR: 1.10 95% CI: 1.03-1.23, $p < 0.01$), LDL-C (OR: 1.05 95% CI: 1.02-1.11, $p = 0.02$), HDL-C (OR: 1.19 95% CI: 1.03-1.44, $p < 0.01$) and M/H levels (OR: 3.22 95 % CI 2.45- 4.84, $P < 0.001$) were independently correlated with mortality.

CONCLUSIONS: Our results suggested that the M/H is a simple and useful indicator in predicting 30-day mortality in patients with PE. However, this conclusion should be confirmed by prospective studies with larger samples.

ID: 186

Topic: **Cardiology » Diagnosis and Treatment of Pulmonary Hypertension**Presentation Type: **Oral**

FASCILITATED CATHETER DIRECTED THROMBECTOMY OF ACUTE PULMONARY EMBOLI A NEW FASCILITATED REGIMEN; PRELIMINARY RESULTS OF AN ONGOING STUDY

Elton Soydan, Mustafa Akin

Ege University, Izmir, Turkey

**Corresponding Author (eltonsoydan@hotmail.com)*

eltonsoydan@hotmail.com, drmustafaakin35@gmail.com

Abstract Text

Objective: Acute pulmonary embolism is a life threatening disease that immediate diagnosis and treatment are the main stones for saving the patient's life. There is no specific sign or symptom that refers to pulmonary embolism that is why so many patients deteriorate without having an immediate proper diagnosis. Alertness about this disease should not only be for pulmonologists but for us cardiologists as well. Multiple comorbidities, immobilization, orthopedics surgery are all risk factors that are involved in patients hospitalized, so that we should be aware about any sudden shortness of breath without any other precipitating cardiac factors. In addition most of patients referred to the emergency unit have shortness of breath and chest pain, the symptoms that should alert us for pulmonary embolism besides other cardiac diseases. Fascilitated catheter directed thrombolysis and thrombectomy are promising and effective strategies in the acute management of this disease perhaps more appropriate in patients with high bleeding risk. We aimed to investigate the effectiveness of a new fascilitated regimen of low dose thrombolytics (t-Pa) infusion contemplated with AngioJet (Solent Omni) mechanical thrombectomy catheter system in patients with acute massive and submassive pulmonary embolism.

Methods: These are the preliminary results of a prospective ongoing study. So far we have three patients involved, of

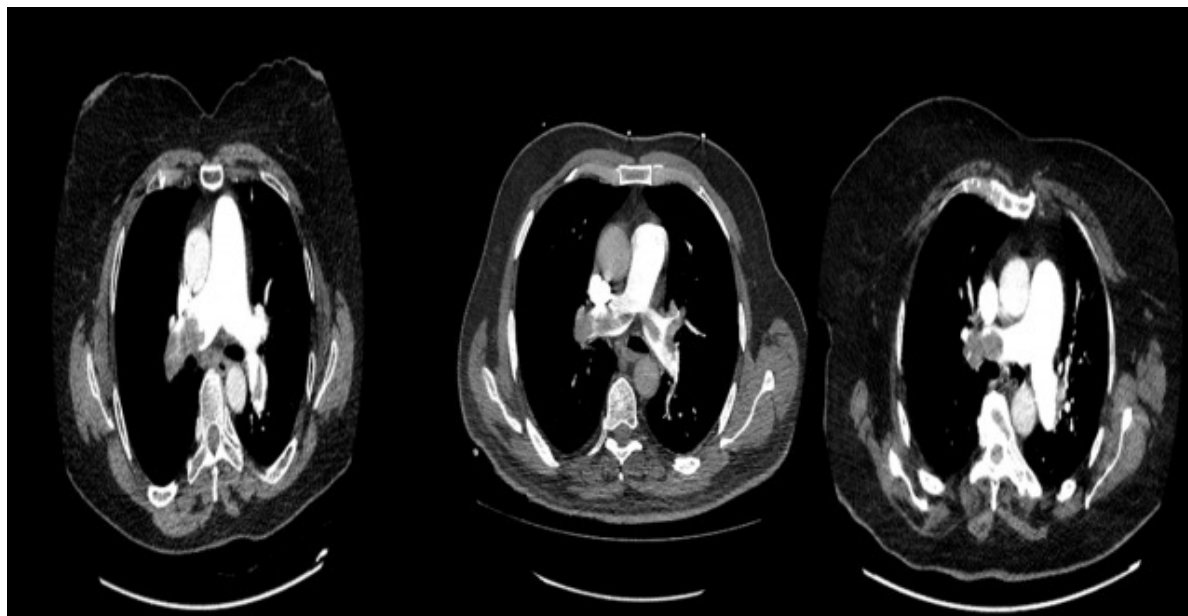
which two were male and one female patient. Demographic features are depicted in table 1. All of them were in the submassive intermediate-high risk of Pulmonary Emboli. They all underwent local t-Pa infusion by the EV3 infusion catheter into the right pulmonary artery for 15 hours. residual thrombus was resolved by introducing the AngioJet catheter system.

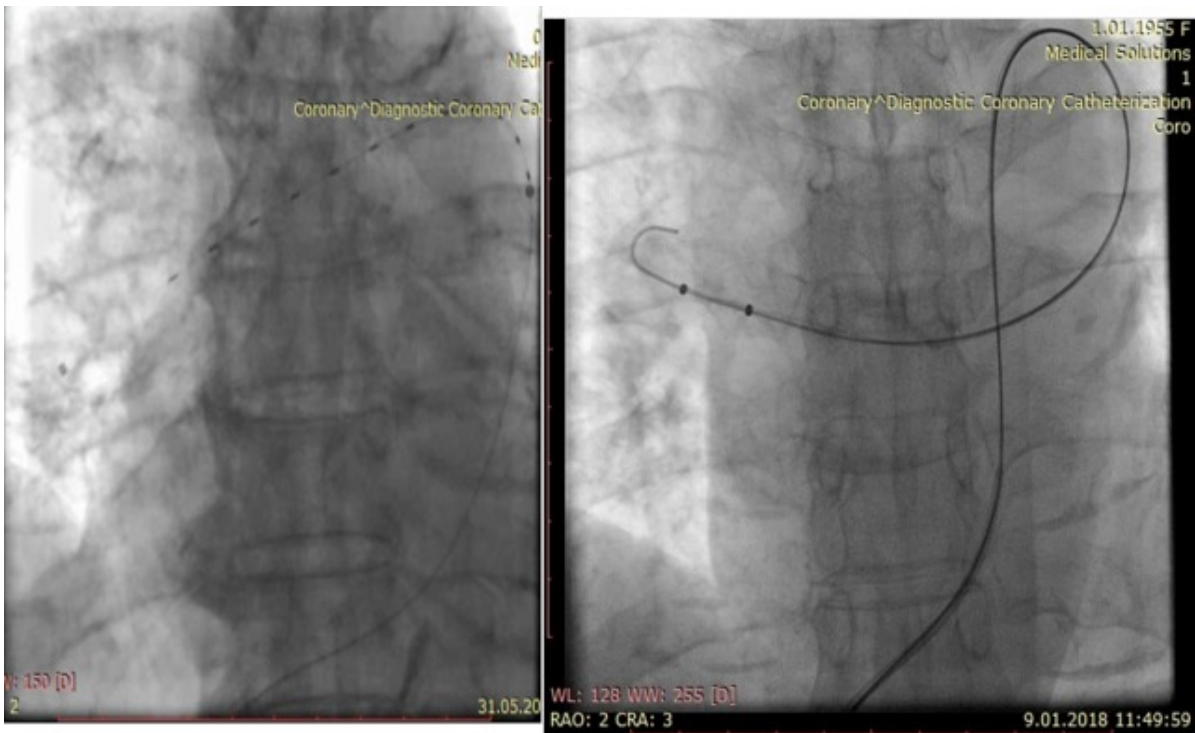
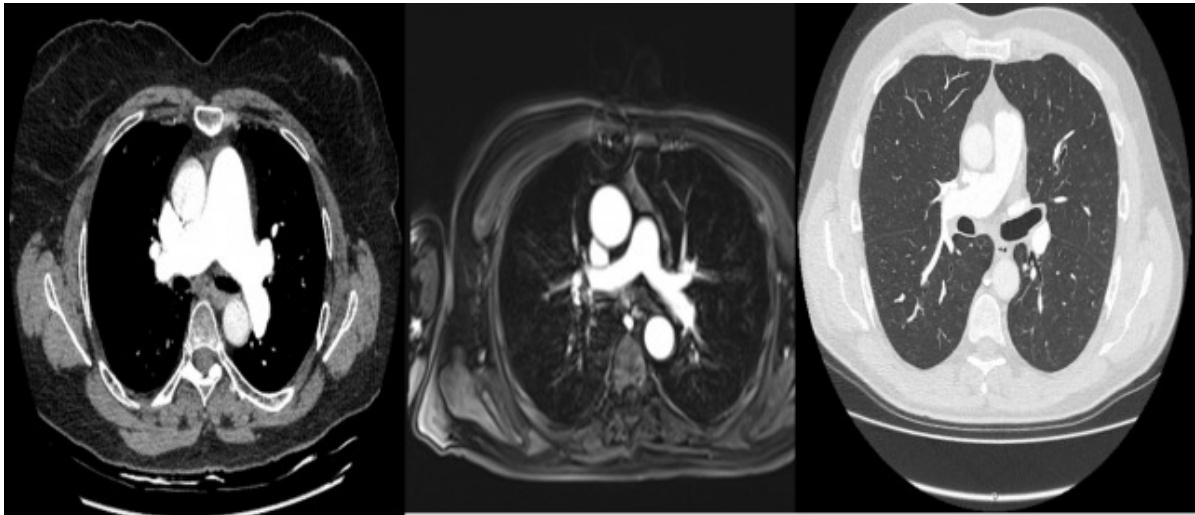
Demographic Features	Patient 1	Patient 2	Patient 3
Age	72	67	53
Gender	Female	Male	Male
Symptom	Dyspnea	Dyspnea	Dyspnea
Comorbidity	HT	COPD	HT
Smoking	No	Yes	Yes
Recent surgery	No	Hip prosthesis	No
DVT	Yes (Popliteal vein)	Yes (Popliteal vein)	Yes (Popliteal vein)
Blood Pressure	90/60 mmHg	60/40 mmHg	90/50 mmHg
Breath rate	20	25	20
Heart rate	110	120	110
Malignancy	No	No	No
sPESI	3	4	2

Right ventricle function (RVEF)	Moderately depressed (40%)	Mildly depressed (35%)	Preserved (60%)
RVEDD (diameter)	3,4 cm	3,6 cm	3,2 cm
Cardiac Troponin	Normal	775 ng/L	475 ng/L
Pulmonary emboli Location	Right Main Pulmonary Artery; left Lobar Pulmonary Artery	Main Pulmonary Artery Bilateral	Right Main Pulmonary Artery
15 hours t-Pa infusion catheter; dose	Right pulmonary artery: 10 mg	Right pulmonary artery: 20 mg	Right pulmonary artery: 10 mg
AngioJet mechanical thrombectomy catheter	Residual right pulmonary artery	Residual right pulmonary artery	Residual right pulmonary artery
Systolic pulmonary artery pressure before; after	80 mmHg/25 mmHg	45 mmHg/20 mmHg	35 mmhg/20 mmHg
Presentation	NYHA Class III	Cardiogenic shock	NYHA Class III
3 month follow up	NYHA Class I	NYHA Class I	NYHA Class I

Results: Patient two had a respiratory arrest during t-Pa infusion that was stabilized by intubation and mechanical ventilator administration. All patients showed effective response towards AngioJet catheter thrombectomy procedure. At follow up functional capacity was normally restored and heart systolic functions normalized.

Conclusions: The new facilitated catheter directed thrombectomy with low dose t-Pa infusion seems safe and effective. More patients are needed to accurately estimate this regimen.





ID: 274

Topic: **Cardiology » Diagnosis and Treatment of Pulmonary Hypertension**Presentation Type: **Oral****CRP/ALBUMIN RATIO IS AN INDEPENDENT ASSOCIATE OF MASSIVE PULMONARY THROMBOEMBOLISM.****Zafer Buyukterzi¹, Kadri Murat Gurses²**¹*Health Sciences University Konya Training and Research Hospital, Konya, Turkey*²*Adnan Menderes University Faculty of Medicine, Aydin, Turkey***Corresponding Author (buyukterzizafer@hotmail.com)**buyukterzizafer@hotmail.com, buyukterzizafer@hotmail.com***Abstract Text****Objective:**

Several studies have suggested that increased C-reactive protein/albumin ratio (CAR) may serve as a predictor of poor prognosis and mortality in certain patient groups. Herein, we aimed to investigate the association between CAR and pulmonary thromboembolism (PTE).

Methods:

In this retrospective analysis, subjects diagnosed with PTE between May 2017 and May 2018 were assessed. Detailed medical history, laboratory and transthoracic echocardiography findings were obtained from medical records.

Results:

81 subjects (median age 76 years, 50.6% male) were included. Subjects who had pulmonary emboli at the main artery had higher systolic pulmonary artery pressure (sPAP) (52.57±17.69 vs. 41.36±14.54 mmHg, p=0.040), troponin-I (0.15 [0.25] vs. 0.03 [0.31] ng/mL, p=0.005) and CAR (20.33 [36.83] vs. 10.63 [13.11], p=0.005) compared to those with segmentary PTE. Age (80 [14] vs. 72.50 [36.75] years, p=0.068) and D-dimer (3.80 [1.00] vs. 3.50 [2.60] mg/L, p=0.184) were similar in both groups. Subjects with massive PTE had higher troponin-I (0.11 [0.15] vs. 0.03 [0.25] ng/mL, p=0.029), D-dimer (5.30 [3.40] vs. 3.70 [1.30] mg/L, p=0.015) and CAR (28.29 [27.03] vs. 10.63 [19.46], p=0.010). Age (77.50 [22.25] vs. 77.50 [22.25] years, p=0.846) and sPAP (65.00±35.36 vs. 42.85±12.76 mmHg, p=0.201) were similar in both groups. Only CAR was independently associated with massive PTE (OR: 1.034, 95% CI: 1.001-1.069, p=0.044). A CAR value ≥22.27 was predicted the presence of massive PTE with a sensitivity of 80% and specificity of 64.8%.

Conclusions:

CAR was independently associated with the presence of massive PTE and predicted the presence of massive PTE with a high sensitivity.

ID: 275

Topic: **Cardiology » Diagnosis and Treatment of Pulmonary Hypertension**Presentation Type: **Oral****ROUTINE HEMATOLOGICAL PARAMETERS ARE NOT ASSOCIATED WITH SEVERITY OF PULMONARY THROMBOEMBOLISM.****Zafer Buyukterzi***Health Sciences University Konya Training and Research Hospital, Konya, Turkey***Corresponding Author (buyukterzizafer@hotmail.com)**buyukterzizafer@hotmail.com***Abstract Text**

Objectives: Pulmonary thromboembolism (PTE) is among the leading cardiovascular cause of hospitalization and mortality. Studies on developing risk models for PTE are ongoing. Herein, we aimed to investigate the association between routine hematological parameters and pulmonary thromboembolism (PTE).

Methods: In this retrospective analysis, subjects diagnosed with PTE between May 2017 and May 2018 were assessed. Detailed medical history, laboratory and transthoracic echocardiography findings were obtained from medical records.

Results: 100 subjects (medianage: 73.50,48% male) diagnosed with pulmonary embolism were included. Subjects with PTE at the main artery level were older (80 [14] vs. 72.50 [36.75] years, $p=0.017$) had higher systolic pulmonary artery pressure (sPAP) (52.57 ± 17.69 vs. 41.36 ± 14.54 mmHg, $p=0.022$) and troponin-I (0.15 [0.25] vs. 0.03 [0.31] ng/mL, $p=0.001$) compared to those with segmentary PTE. D-dimer (3.80 [1.00] vs. 3.50 [2.60] mg/L, $p=0.152$), MPV (9.90 [1.60] vs. 11.00 [1.43] fL, $p=0.867$), NLR (5.60 [4.33] vs. 6.41 [8.65], $p=0.428$) and RDW (15 [1] vs. 14 [2.50] %, $p=0.572$) were similar between groups. Subjects with massive PTE had higher troponin-I (0.11 [0.15] vs. 0.04 [0.18] ng/mL, $p=0.012$) and D-dimer (5.30 [3.40] vs. 3.60 [1.03] mg/L, $p=0.012$) levels compared to subjects without. Age (77.50 [22.25] vs. 72.50 [31.00] years, $p=0.977$), sPAP (65.00 ± 35.36 vs. 41.71 ± 13.26 mmHg, $p=0.147$), RDW (13 [2.5] vs. 14 [2] %, $p=0.431$), MPV (10.25 [1.70] vs. 10.45 [1.25] fL, $p=0.840$) and NLR (5.49 [6.34] vs. 5.33 [6.08], $p=0.774$) were similar between groups. In the multivariate regression model including age, sPAP and hemoglobin, the only independent associate of PTE severity (main pulmonary artery vs. segmentary) was found to be age (OR: 1.062, 95% CI: 1.009-1.119, $p=0.022$).

Conclusion: None of the routine hematological parameters were found to be associated with PTE severity.

Oral Presentations

Percutaneous Solutions in Valvular Heart Problems

Date: 29.03.2019 Time: 10:15 - 11:30 Hall: 5

ID: 323

Topic: **Cardiology » PI for SHD - Transcatheter Aortic Valve Replacement**

Presentation Type: **Oral**

IS IT FEASIBLE TO PERFORM TAVR WITHOUT PREPROCEDURAL CT-SCAN IN CRITICALLY ILL PATIENTS WITH CRITICAL AORTIC STENOSIS

Ertugrul Okuyan

Health Sciences University Bağcilar Trainin and Research Hospital, Istanbul, Turkey

**Corresponding Author (dreokuyan@hotmail.com)*

dreokuyan@hotmail.com

Abstract Text

Background:

Before transcatheter aortic valve replacement (TAVR) procedure, computed tomography (CT) is required for heart valve selection, sizing the annulus, assessment of the peripheral access; ascending aorta and aortic root. However, CT brings with it certain risks such as fluid-volume loading and contrast nephropathy. In some patients such as hemodynamically unstable, non-cooperative or who cannot rest on their back, CT imaging may be difficult or impossible. Data is limited in the current literature about safety of TAVR without CT assessment. We wanted to share our experience in critically ill aortic stenosis patients who we had to proceed TAVR without CT imaging.

Methods

We evaluated retrospectively patient's medical records who undergone TAVI procedure between 2014-2018 in our centre. The patients who we performed TAVI without CT imaging were selected and their demographic findings, mortality rates and the reasons to proceed without CT imaging were noted. All of the procedures were conducted by same operators. Aortic valve, aortic annulus and ascending aorta were assessed by using transthoracic echocardiography. A peripheral angiogram was done at the beginning of the procedure to assess access sites. Aortic annulus also evaluated with aortography and sizing of heart valve was done by using both echocardiographic and angiographic findings. When a decision couldnot be made, we benefited from balloon sizing and TEE.

Results

We identified 13 TAVR patients (6 male, age 79 +/- 9,5) without preprocedural CT images. Periprocedural mortality was occurred in one patient. The other patients postprocedural followings were uneventfull. Predilatation was performed in five patients. Four patients required post dilatation due to moderate aortic regurgitation. Peripheral vascular complications did not occur in any patient. Contrast nephropathy has occurred in four patients, none of them required hemodialysis. The reasons to preclude CT imaging were renal failure in four, hemodynamic instability in five and lack of cooperation for remainders.

Conclusion

TAVI is safe without CT by using alternative imaging methods in such challenging patients.

ID: 555

Topic: Cardiology » PI for SHD - Others

Presentation Type: Oral

MITRACLIP FOR THE TREATMENT OF SEVERE MITRAL REGURGITATION IN PATIENTS WITH HEART FAILURE

Begum Yetis Sayin, Hakan Aksoy, Sercan Okutucu, Ebru Ercan Akgul, Ali Oto

Memorial Ankara Hospital, Ankara, Turkey

**Corresponding Author (begumyts@yahoo.com)*

begumyts@yahoo.com, haksoy63@yahoo.com, sercanokutucu@yahoo.com, akgul37ebru@hotmail.com, alioto@tksv.org

Abstract Text

Objective: Patients with heart failure and secondary mitral regurgitation (MR) who remained symptomatic despite maximally medical therapy showed reduced rates of hospitalizations and death after the treatment with transcatheter MitraClip device. Percutaneous edge-to-edge mitral valve repair was shown to be safe and feasible alternative for high risk surgical candidates. Approximately half of patients with heart failure (HF) develop significant mitral regurgitation (MR). As the severity of MR increases, symptoms and prognosis worsen with a high mortality rate. The treatment options for patients with degenerative mitral valve disease also include a MitraClip if the patient is high risk for surgical repair. We present case series of percutaneous intervention for severe MR in symptomatic patients with HF.

Methods: Symptomatic patients with significant MR with high operative risk were consecutively enrolled if they fulfilled anatomical criteria assessed by 2-dimensional TEE for MitraClip (Abbott Vascular) implantation. We also assessed mitral valve anatomic regurgitant orifice (ARO) using 3-dimensional TEE and its association with reduced regurgitation following MitraClip implantation. The decrease in left ventricular end diastolic volume calculated. Also the improvement in patients' functional capacity in three months follow up was noted. Device success was defined as reduction of MR to <2.

Results: Our series consisted of 8 patients with median age 66,6 years (5 males,3 females). Patients' median logistic EuroSCORE was 21 and median left ventricular ejection fraction was 37,7 %. Six patients had severe functional MR and one patient had mitral valve prolapse. Also one patient who was over 82 with high surgical risk had degenerative mitral valve disease. MitraClip was used in mitral valve prolapse in a patient with sickle cell anemia who was younger than other patients. Comorbidities were common including coronary artery disease (62.5%) and functional capacity of Class III/IV according to the New York Heart Association (NYHA) Classification. Cardiac resynchronization therapy defibrillator (CRT-D) and implantable cardioverter defibrillator were present in 5 patients adjunctive to MitraClip. Two patients had undergone previous coronary artery bypass grafting before. The MitraClip procedures were successful in all patients; 2 devices were implanted in 3 patients. There were no pericardial effusions, no complications due to device dislodgement or other complications due to device delivery system. The mean left ventricular end diastolic volume improved from 223 ml to 186 ml. The patients' symptoms improved to NYHA Class II/III in three months follow up. Mitral regurgitation was significantly reduced throughout the series ($p<0.05$) when assessed using both the reduction in MR grade and the reduction in effective regurgitant orifice. The maximum gradient in mitral valve was not more than 5.0 mmHg and in only two patients the maximum gradient in mitral valve was approximately 5.6 mmHg

Conclusions: Percutaneous MitraClip implantation can be used safely to reduce the severity of MR even in patients with advanced HF and is associated with improved functional capacity. MitraClip was shown to be effective treatment with functional and degenerative MR. A dedicated multidisciplinary team is necessary, as well as suitable patient selection, familiarity with the technical aspects of the procedure including transesophageal echocardiography and post-procedure monitoring

Keywords: Heart failure, MitraClip, Mitral regurgitation

ID: 119

Topic: Cardiology » PI for SHD - Transcatheter Aortic Valve Replacement

Presentation Type: Oral

THE ASSOCIATION BETWEEN SERUM VISFATIN LEVELS AND LEFT VENTRICULAR REVERSE REMODELLING, ALL-CAUSE MORTALITY AND STROKE INCIDENCE IN AORTIC STENOSIS PATIENT AFTER TRANS-AORTIC VALVE IMPLANTATION

Aydin Rodi Tosu

Health Science University, Mehmet Akif Ersoy Thoracic and Cardiovascular Surgery Training Research Hospital, Istanbul, Turkey

**Corresponding Author (aydinroditosu@gmail.com)*

aydinroditosu@gmail.com

Abstract Text

The association between serum visfatin levels and left ventricular reverse remodelling, all-cause mortality and stroke incidence in aortic stenosis patient after trans-aortic valve implantation

Objective:

In patients with aortic stenosis (AS), left ventricular hypertrophy develops due to pressure overloading, which may regress after trans-aortic valve implantation (TAVI). Serum visfatin may play a part in left ventricular reverse remodelling. We addressed this issue in patients with AS and examined whether serum visfatin levels are related to left ventricular reverse remodelling, all-cause mortality, and stroke incidence following TAVI.

Material and methods:

From January 2012 and January 2016, a total of 110 symptomatic severe AS patients and 70 healthy patients were enrolled in this study. In all patients, serum visfatin levels were measured before the procedure and at 12th month follow-up period. Results: Serum visfatin levels were significantly higher in healthy subjects compared to patients with AS [14.2 ng/dl (IQ: 8-20 ng/dl) vs. 8.4 ng/dl (IQ: 1.8-22.4 ng/dl), $p<0.05$]. Twelve months after TAVI, serum visfatin levels significantly increased compared to preoperative values [8.4 ng/dl (IQ: 1.8-22.4 ng/dl) vs. 8.35 ng/dl (IQ: 1.7-20.0 ng/dl), $p<0.05$]. We observed that serum visfatin levels were significantly lower in patients who developed stroke following TAVI [1.8 ng/dl (IQ: 1.7-2.8 ng/dl) vs. 8.5 ng/dl (IQ: 1.7-20.0 ng/dl), $p<0.05$]. A total of six patients died during follow-up period. We noted that serum visfatin levels were significantly lower in patients who died following TAVI [1.8 ng/dl (IQ: 1.7-2.8 ng/dl) vs. 8.5 ng/dl (IQ: 1.7-20.0 ng/dl), $p<0.05$].

Conclusion:

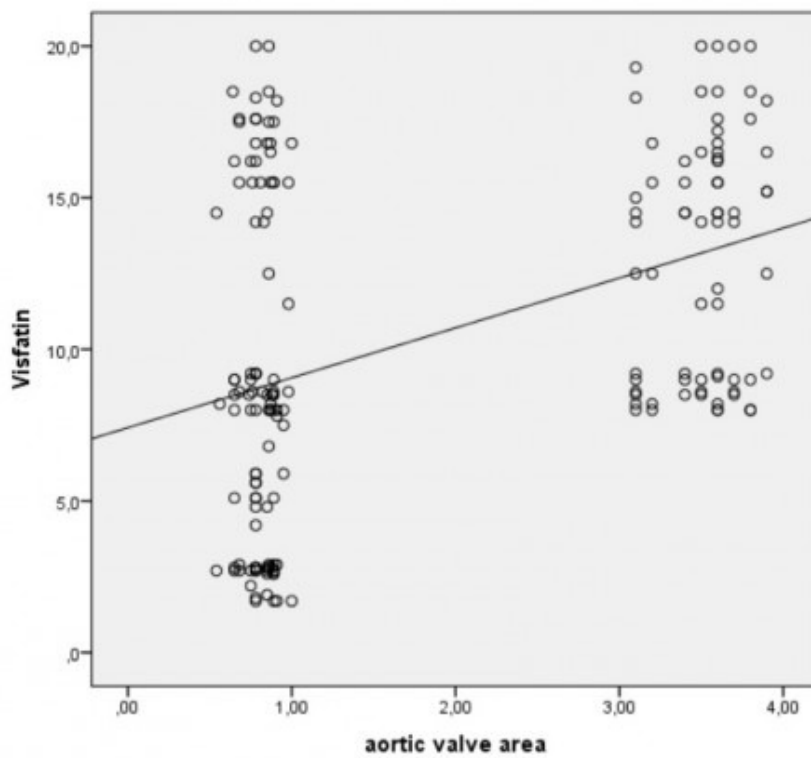
Serum visfatin levels are reduced by cardiac pressure overload. Serum visfatin levels increase after correction of pressure overload and may play a part in postoperative left ventricular reverse remodelling. Our findings provide evidence that serum visfatin cardioprotective and neuroprotective effects may play an important role in patients with AS following TAVI.

Key words: serum visfatin, aortic stenosis, trans-aortic valve implantation

Table 1: Clinical and laboratory parameters before and after TAVI

	Pre-TAVI	Post-TAVI	P value
Creatinine	0.8 (0.4-2.5)	0.9 (0.4-2.3)	0.159
Hemoglobin	14.5 (9.8-16.9)	14.1 (9.8-16.8)	<0.001*
C-reactive protein	1.6 (0.8-4.5)	1.5 (0.8-4.5)	0.810
Mean gradient	47.68±4.09	7.58±1.82	<0.001*
EF	60 (25-60)	60 (35-60)	<0.001*
Serum visfatin	8.35 (1.7-20.0)	8.4 (1.8-22.4)	<0.001*

*p<0.05, EF: ejection fraction

**Figure 1:** Pre- and post-TAVI serum visfatin values of aortic stenosis patients

ID: 24

Topic: Cardiology » PI for SHD - Transcatheter Aortic Valve Replacement

Presentation Type: Oral

THE ASSOCIATION OF HOSPITAL SURGICAL AORTIC VALVE REPLACEMENT QUALITY WITH SHORT- AND LONG-TERM MORTALITY AFTER TRANSCATHETER AORTIC VALVE REPLACEMENT

Harun Kundi

*BIDMC, Brookline, Chestnut Hill, United States***Corresponding Author (hkundi@bidmc.harvard.edu)**hkundi@bidmc.harvard.edu*

Abstract Text

Objectives:

To assess whether those hospitals with better patient outcomes for surgical aortic valve replacement (SAVR) subsequently achieved better transcatheter aortic valve replacement (TAVR) outcomes after launching TAVR programs.

Methods:

Patients aged 65 and older in the United States using the Centers for Medicare & Medicaid Services (CMS) Medicare Provider and Review (MedPAR) database between January 1, 2010 and September 29, 2015. Only hospitals performing at least one SAVR prior to September 1, 2011 and performing at least one TAVR after this date (post-TAVR period) were included in the analysis.

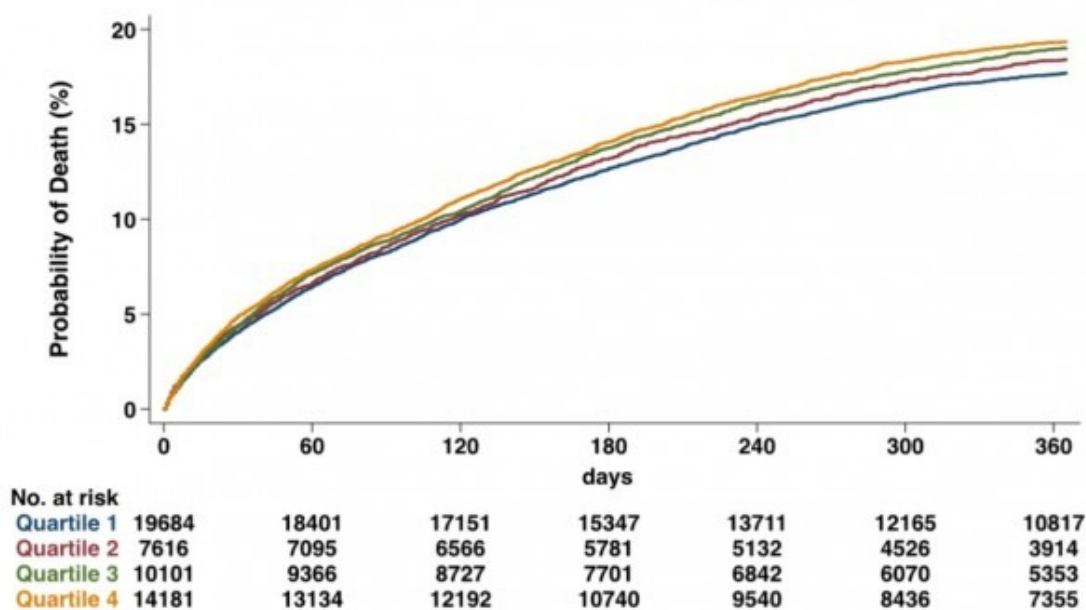
Results:

A total of 51,924 TAVR procedures were performed in 519 hospitals, of which 19,798 were performed at hospitals in Quartile 1 (lowest risk-adjusted SAVR mortality rate), 7,663 were performed in Quartile 2, 10,180 were performed in Quartile 3, and 14,283 were performed in Quartile 4 (highest risk-adjusted SAVR mortality rate). Observed mortality rates at 30-days (Quartile 1: 4.6%, Quartile 2: 5.0%, Quartile 3: 5.1%, Quartile 4: 5.6%; $p < 0.001$) and 1-year (Quartile 1: 17.0%, Quartile 2: 17.5%, Quartile 3: 18.2%, Quartile 4: 18.6%; $p < 0.001$) consistently increased with increasing baseline hospital SAVR risk-adjusted mortality. After multivariable analysis, compared with the lowest quartile of SAVR mortality, undergoing TAVR at a hospital with higher baseline SAVR mortality continued to be associated with higher 30-day mortality (Quartile 2: odds ratio [OR] 1.023 [95% CI 0.867-1.207], Quartile 3: OR 1.130 [95% CI 1.017-1.256], Quartile 4: OR 1.225 [95% CI 1.070-1.402], $p = 0.024$) and 1-year mortality (Quartile 2: hazard ratio [HR] 1.040 [95% CI 0.924-1.167], Quartile 3: HR 1.140 [95% CI 1.020-1.275], Quartile 4: HR 1.160 [95% CI 1.050-1.284], $p = 0.020$).

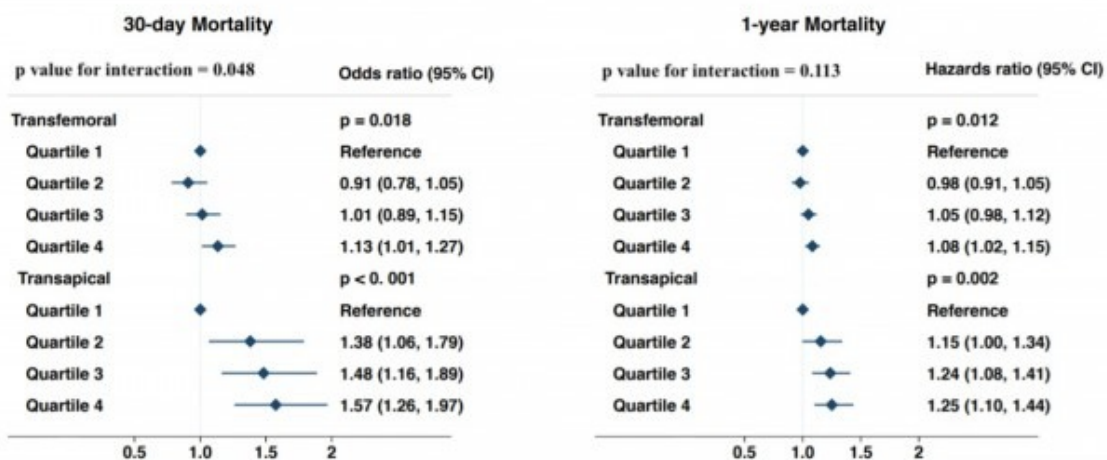
Conclusions:

Hospitals with higher SAVR mortality rates also had higher short- and long-term TAVR mortality after initiating TAVR programs. Quality of cardiac surgical care may predict a hospital's performance with new structural heart disease programs.

Unadjusted Kaplan-Meier TAVR mortality curves stratified by hospital quartile of SAVR mortality



Results of subgroup analyses of TAVR access site (transfemoral vs. transapical) by hospital quartile of SAVR mortality



ID: 207

Topic: Cardiology » PI for SHD - Transcatheter Aortic Valve Replacement

Presentation Type: Oral

THE EFFECT OF PRIOR BETA BLOCKER USAGE TO CLINICAL OUTCOME IN AORTIC STENOSIS PATIENTS AFTER TRANSCATHETER AORTIC VALVE REPLACEMENT

Kamil Gulsen

*Health and Science University Bagcilar Training and Research Hospital , Istanbul, Turkey***Corresponding Author (kamilgulsen2000@yahoo.com)**kamilgulsen2000@yahoo.com*

Abstract Text

Objectives: There is insufficient data in the literature regarding the impact of prior usage of beta-blocker (BB) therapy in patients undergoing transcatheter aortic valve replacement (TAVR). Chronically use of BB agents before TAVR could potentially cause bradycardia and atrioventricular (AV) block, while could also protect new-onset atrial fibrillation and other tachycardias. In this study, our aim is demonstrate the relationship between prior BB usage and clinical outcomes in aortic stenosis patients after TAVR.

Methods: We investigated totally 129 consecutive patients who undergone TAVR procedure in our hospital between 2013 and 2018. Patient's demographic characteristics, prior medication and data including mortality (in hospital, 30 days and long term) periprocedural new-onset atrial fibrillation, left bundle branch block, need of temporary and permanent pacemaker were collected retrospectively. Patients were divided in two groups as being chronically received BB agents or not (BB + and BB -). These two groups were compared in terms of demographic characteristics and clinical outcomes.

Results: Study population consisted of 129 consecutive patients (69 female [% 51.2] mean age 78.4 [± 7.4]). Totally 65 of 129 patients (% 50.4) were being chronically use a kind of BB agent before the procedure. Patients continued their own BB therapy before and after the procedure if hemodynamic instability, bradycardia or AV block did not occur. Patients in BB + group were younger (76.5±6.9 vs. 80.3±7.1 respectively p= 0.03). In hospital and long term mortality was similar in BB+ and BB- groups (28 % and % 21 respectively p=0,3). There were no statistically significant differences regarding post procedural early new onset atrial fibrillation and left bundle branch block (atrial fibrillation in BB+ group 10.7%, in BB- group 10.9 % p= 0,9 ; left bundle branch block in BB+ group 38 %, in BB- group 33 % p=0,3). Temporary pacemaker need early after the procedure was 32.8 % in BB +, 11.9 % in BB- group p= 0.02; while need of permanent pacemaker was 14.2 % in BB+ group and 6.2% in BB- group p= 0,11)

Conclusion: Prior use of BB agents in patients undergone TAVR procedure did not effect mortality, new onset atrial fibrillation and left bundle brunch block nor need of permanent pacemaker in our study population. However, there was a significant relation between prior BB usage and need of temporary pace maker. In the light of this findings, it seems plausible to continue BB therapy in patients receive that therapy before the procedure, cause of withdrawal of medication may potentially lead clinically deterioration.

ID: 549

Topic: Cardiology » PI for SHD - Transcatheter Aortic Valve Replacement

Presentation Type: Oral

A RARE COMPLICATION AFTER TAVR: ACUTE LEFT MAIN CORONARY ARTERY OCCLUSION AND SUCCESSFUL PERCUTANEOUS TREATMENT

Atila Iyisoy

*Gülhane Training and Research Hospital, Ankara, Turkey***Corresponding Author (aiyisoy@hotmail.com)**aiyisoy@hotmail.com*

Abstract Text

An 83-year-old man admitted to our clinic with decompensated heart failure. He had hypertension, diabetes, and chronic obstructive lung disease. Echocardiogram showed severe aortic stenosis (PgMax/Mean: 110/60 mmHg) and normal LV ejection fraction. After stabilization the patient TAVR procedure was performed.

The super-stiff wire was inserted into the left ventricle through the left Amplatz-2 catheter via left femoral artery (Fig. 1A). The delivery system was advanced and predilatation was performed by creating hypotension at the level of the aortic valve under high-speed pacemaker (Figure 1B). Then, 29 mm Edwards Sapien XT aortic valve level was adjusted and valve was implanted using balloon under high-speed pacemaker (Figure 1C, 1D). Valve placement was performed without any complications. No complication was detected in the patient's aortography and the procedure was stopped. While the femoral closure was going on, the patient's hemodynamics was impaired, the patient had arrest and immediately intubated. Echocardiography showed no pericardial effusion. At fluoroscopy, bioprosthetic valve was in place. Coronary angiography was performed in the contralateral groin. There was no flow from the proximal left main coronary artery (Fig. 2A). Then, under the CPR, a 0.014-inch guidewire was advanced LAD distal and multiple balloon angioplasty was performed with a 2.5x15 and 3.0x20 mm balloon (Fig. 2B). A 3.5x25 mm Commander BMS was implanted from LMCA to LAD, provided TIMI 2 flow both LAD and CFX then the patient's rhythm was achieved. (Figure 2C, 2D). The patient was taken to the intensive care unit. The patient was arrested again after 2 hours and the rhythm could not be achieved despite the CPR for 45 minutes and the patient was exitus.

The risk of coronary obstruction after TAVR is increased in patients with coronary ostium less than 10 mm in aortic annulus small sinus Valsalva and in those with asymmetric bulky calcification. In our patient, the reason caused coronary obstruction was thought that aortic annulus- coronary ostium distance was 8.07 mm, and bulky calcification embolism after valve implantation (Figure 2E). Coronary obstruction is an important cause of hypotension and mortality after TAVR.

Figure 1

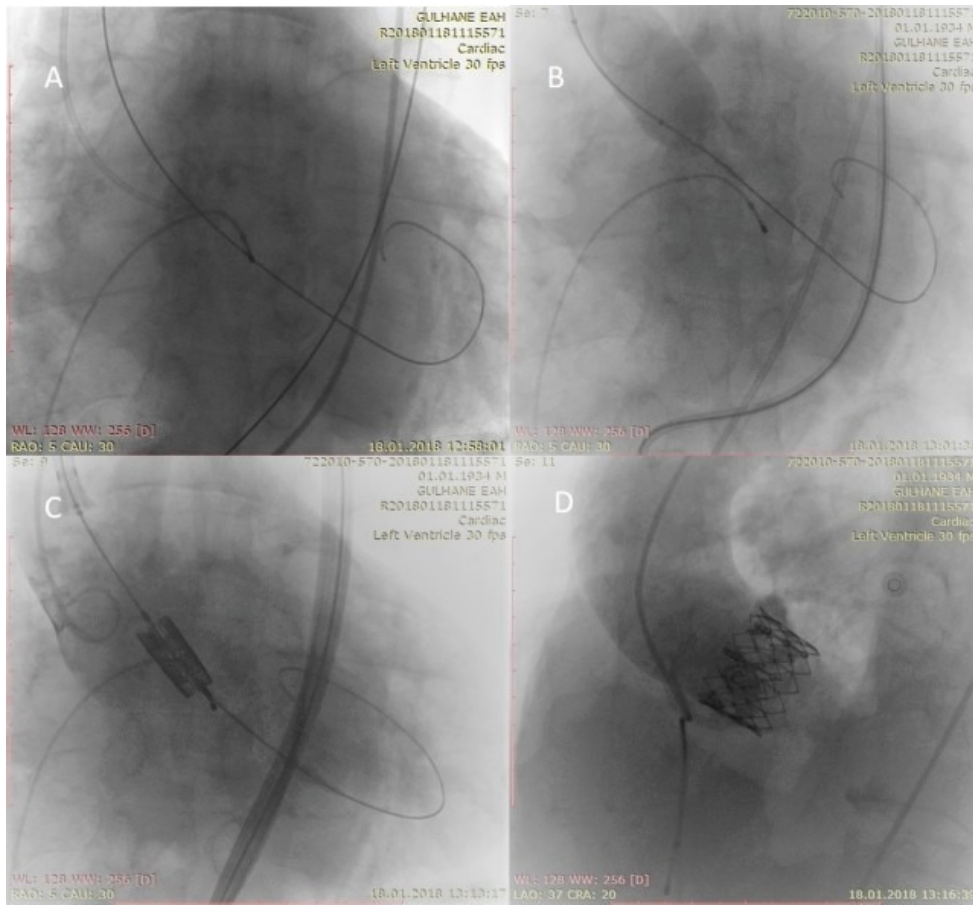
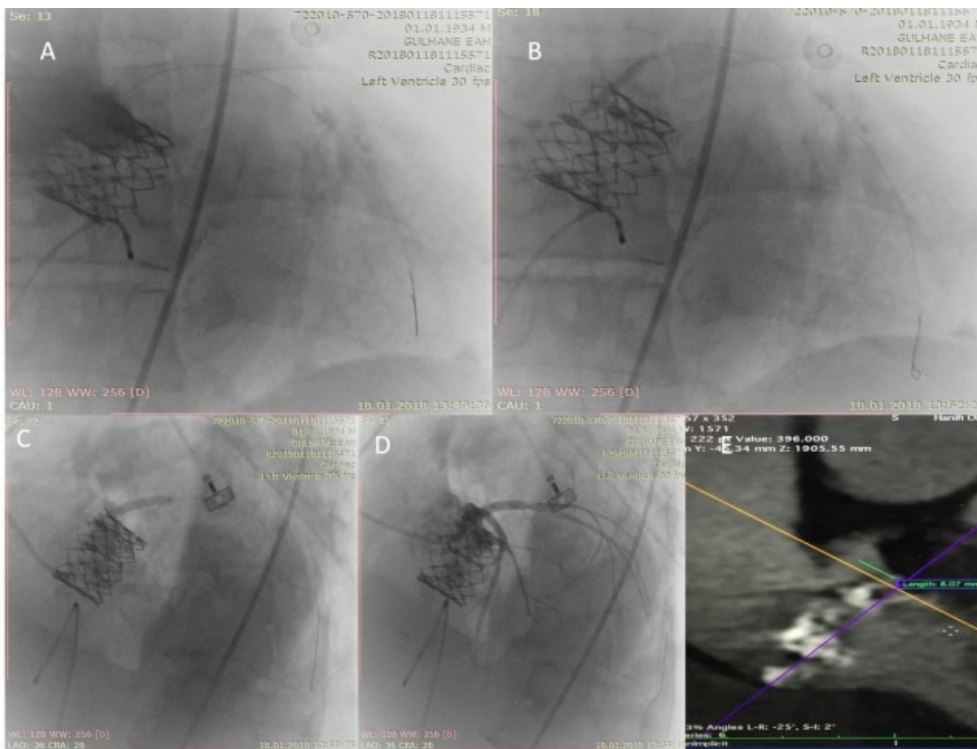

Figure 2



Oral Presentations

Acute Coronary Syndrome: Bench to Bedside

Date: 29.03.2019 Time: 11:30 - 12:45 Hall: 5

ID: 228

Topic: **Cardiology** » **Acute Coronary Syndromes**

Presentation Type: **Oral**

CORONARY AND INTRACARDIAC THROMBOSIS AT A 38 YEAR OLD PATIENT WITH MTHFR A 1298C, PAI4G/5G AND PROTHROMBIN G2021GA MUTATION

Irfan Veysel Duzen¹, Doğan Kahraman²

¹Gaziantep University Faculty of Medicine Department of Cardiology, Gaziantep, Turkey

¹Gaziantep University Faculty of Medicine Department of Cardiovascular Surgery, Gaziantep, Turkey

**Corresponding Author (vduzen79@yahoo.com.tr)*

vduzen79@yahoo.com.tr, drdogankahraman@gmail.com

Abstract Text

Objective: Cardiovascular diseases are multifactorial diseases leading cause of death in the world.

Coronary artery disease is very common in young patients at the present time but some genetic predisposition tests to thrombosis and cardiovascular disease must be performed to suspected patients.

Methods:

A 38 year old woman was admitted to the emergency room with chest pain and nausea. There was ST elevation in inferior leads at the electrocardiogram and she was taken to the catheter laboratory in the first hour. Circumflex artery was totally occluded in the angiogram(movie1) Primary PTCA was performed. In echocardiography there was mitral stenosis and mitral valve area was 1.2 cm². Mitral balloon valvuloplasty was planned and after one month transesophageal echocardiogram was performed. In transesophageal echocardiography interatrial septum was covered with an appearance compatible with thrombus . (figure1) Warfarine was prescribed to the patient and genetic predisposition to cardiovascular disease mutation scan test was made. After 3 months control echocardiogram and transesophageal echocardiogram was repeated and it was seen that thrombus formation is persistent.

Results: The genetic predisposition to cardiovascular disease mutation scan test revealed that there's heterozygote PA-1 4G/5G, MTHFR A1298 C and prothrombin G20210A mutation in PCR analysis. The thrombus formation was persistent in transesophageal ecocardiography. The patient was referred to cardiovascular surgery.

Conclusion: Genetic predisposition to thrombosis and cardiovascular disease must be suspected especially in young patients with multiple thrombotic presentations.

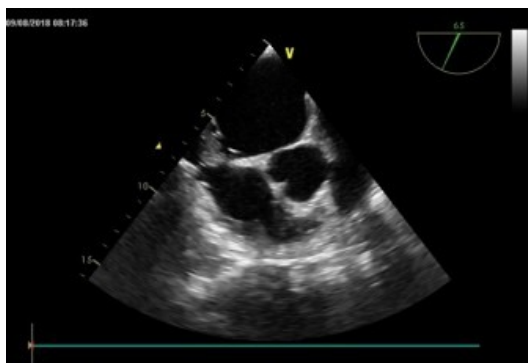


Figure 1: Transesophageal echocardiogram shows thrombus formation at interatrial septum

ID: 269

Topic: **Cardiology** » **Acute Coronary Syndromes**

Presentation Type: **Oral**

RDW/PDW RATIO; A NOVEL PREDICTOR OF APICAL THROMBUS FORMATION IN POST MYOCARDIAL INFARCTION PATIENTS

Firdevs Aysenur Ekizler¹, Burak Acar²

¹*Yuksekt Ihtisas Education and Research Hospital Turkey, ANKARA, Turkey*

²*Kocaeli University Education and Research Hospital Turkey, Kocaeli, Turkey*

**Corresponding Author (firdevs_bsk@hotmail.com)*

firdevs_bsk@hotmail.com, burakacarm@yahoo.com

Abstract Text

Objective: The development of left ventricular (LV) apical thrombus formation is an important complication of myocardial infarction and is associated with systemic thromboembolism. The usual substrate for LV thrombus is a recent anterior myocardial infarction (MI) with an akinetic apex that provides the suitable milieu for thrombus formation. RDW and PDW have been implicated in the pathogenesis of cardiovascular disorders, including atherosclerosis and its complications. We sought to investigate RDW/PDW as a new variable that resulted from a combination of both markers and the predictive value of this marker regarding formation of LV apical thrombus in post-MI patients.

Material and Method: A total of 137 patients (81 male, mean age 54.1±4.7 years) diagnosed with acute anterior MI enrolled in this study (sixty seven patients with LV apical thrombus and 70 patients without LV apical thrombus). We evaluated post-myocardial infarction echocardiographic parameters of all patients as well as admission RDW/PDW ratio

Results: There were no significant differences in terms of clinical, demographic features and echocardiographic parameters between two groups. There was a significant difference in terms of RDW/PDW ratio between patients with and without apical thrombus formation ($p=0.002$). In multivariate logistic regression analysis, RDW/PDW ratio was found to be a strong and independent predictor of the formation of apical thrombus.

Conclusion: Admission RDW/PDW ratio, as a simple and easily accessible parameter, can be useful in prediction of left ventricular apical thrombus formation after post-MI patients

ID: 293

Topic: **Cardiology » Acute Coronary Syndromes**

Presentation Type: **Oral**

WHOLE BLOOD VISCOSITY AS A NEGLECTED PARAMETER MAY PREDICT HIGHER CORONARY ATHEROSCLEROTIC BURDEN IN PATIENTS WITH FIRST DIAGNOSIS OF ACUTE CORONARY SYNDROME.

Mevlüt Serdar Kuyumcu¹, Mustafa Bilal Özbay²

¹Suleyman Demirel University: School of Medicine, Isparta, Turkey

²Türkiye Yüksek İhtisas Training and Research Hospital, Ankara, Turkey

**Corresponding Author (kuyumcuserdar@hotmail.com)*

kuyumcuserdar@hotmail.com, mbozbaymd@gmail.com

Abstract Text

Objective

Blood viscosity is associated with the risk of cardiovascular events and plays a role in the pathophysiology of atherosclerosis. Endothelial shear stress have been proposed as novel risk markers for acute coronary syndrome. SYNTAX score, an angiographic scoring system, defines the grade and complexity of coronary artery disease. We aimed to evaluate the relationship between whole blood viscosity and severity of coronary artery disease according to the SYNTAX score in patients with first diagnosis of acute coronary syndrome.

Methods

A total of 356 subjects were included into the study, of whom 236 underwent coronary angiography with the first diagnosis of acute coronary syndrome and 120 had normal coronary arteries detected in coronary angiography. Patients with acute coronary syndrome were divided into 2 groups: low SYNTAX score (< 23) (129 patients) and high SYNTAX score (≥ 23) (107 patients). All data and whole blood viscosity values compared between 3 groups.

Results

The acute coronary syndrome patients with a high SYNTAX score had a higher white blood cell values for both low shear rate and high shear rate (58 ± 17.1 and 17.2 ± 1.2 , respectively) compared to the acute coronary syndrome patients with a low SYNTAX score (48.2 ± 15.5 and 16.7 ± 1.1 , respectively) and the control group (35.2 ± 13.7 and 16.0 ± 1.1 , respectively). There was also a positive correlation between SYNTAX score and whole blood viscosity for both low shear rate ($\beta=0.333$, $p<0.001$) and high shear rate ($\beta=0.347$, $p<0.001$). Higher values of whole blood viscosity for both low shear rate and high shear rate (OR = 1.003; 95% CI: 0.997-1.017; $p < 0.001$ and OR = 1.517; 95% CI: 1.431-1.923; $p < 0.001$, respectively) were independent predictor for a high SYNTAX score in the acute coronary syndrome patients after multiple linear regression analysis.

Conclusions

Whole blood viscosity values for both low shear rate and high shear rate were higher in the high SYNTAX group than in the low SYNTAX group in patients with acute coronary syndrome. A higher whole blood viscosity indicating increased endothelial shear stress could have a role in the pathogenesis of atherosclerotic burden in patients with first diagnosis of acute coronary syndrome.

Table 1. Baseline characteristics and laboratory parameters of the study groups (n=356).

Variables	ACS SYNTAX score ≥23 (n=107)	ACS SYNTAX score <23 (n=129)	NCA (n=120)	P value*	P value ^a	P value ^b	P value ^c
Age, years	61.6 ± 11.7	57.9 ± 12.0	56.2 ± 11.7	<0.001	0.020	<0.001	0.246
BMI, kg/m ²	27.7 ± 3.5	27.4 ± 3.6	25.4 ± 2.3	<0.001	0.588	<0.001	<0.001
Male, n(%)	79 (73.8)	64 (72.9)	75 (62.5)	0.110	-	-	-
Hyperlipidemia, n(%)	24 (22.4)	23(17.8)	19 (15.8)	0.389			
Diabetes Mellitus, n(%)	39 (36.4)	39 (30.5)	23 (19.2)	0.013	0.332	0.004	0.040
Hypertension, n(%)	44 (41.1)	57 (44.2)	40 (33.3)	0.201	0.637	0.227	0.080
Smoking, n(%)	41 (38.3)	59 (45.7)	41 (34.2)	0.167	-	-	-
Multi-vessel disease, n (%)	41 (52.6)	16 (14)	0 (0)	-	<0.001	-	-
ACS subtype					-		
NSTEMI (%)	57 (47.2)	49 (45.8)	0 (0)	-	0.805		
STEMI (%)	58 (54.2)	72 (55.8)	0 (0)	-	0.805	-	-
Stent implantation, n (%)	68 (63.6)	114 (88.4)	0 (0)	-	<0.001	-	-
Decision for CABG, n (%)	38(35.5)	12 (9.3)	0 (0)	-	<0.001	-	-
Glucose, mg/dL	155.21 ± 84.9	144.8 ± 67.4	98.8 ± 33.3	<0.001	0.319	<0.001	<0.001
Creatinine, mg/dL	1.97 ± 8.3	1.0 ± 0.34	0.99 ± 0.12	0.213	-	-	-
Total cholesterol, mg/dL	203 ± 42.0	189.5 ± 50	165.8 ± 43.1	<0.001	0.030	<0.001	<0.001
LDL-C, mg/dL	131.7 ± 35.4	123.5 ± 35.0	100.2 ± 30.1	<0.001	0.120	<0.001	<0.001
HDL-C, mg/dL	45.1 ± 10.7	43.4 ± 10.1	45 ± 13.7	0.306	-	-	-
Hemoglobin, g/dL	15.2 ± 1.8	14.8 ± 1.6	14.4 ± 1.3	0.71			
Hematocrit (%)	45.7 ± 5.5	44.4 ± 4.7	41.5 ± 4.9	<0.001	0.06	<0.001	0.030
WBC, 10 ⁹ /mm ³	11.2 ± 2.7	11.1 ± 2.9	10.3 ± 2.5	0.117	-	-	-
Platelet, 10 ⁹ /mm ³	236.7 ± 70.9	238.1 ± 61.4	238.2 ± 66.5	0.982	-	-	-
Neutrophil, 10 ⁹ /mm ³	8.27 ± 3.5	8.45 ± 5.5	7.8 ± 6.6	0.690	-	-	-
Lymphocyte, 10 ⁹ /mm ³	2.1 ± 1.2	2.5 ± 1.3	2.4 ± 1.1	0.035	0.017	0.043	0.528
CRP, mg/L	19.1 (44)	11 (21)	4 (9)	<0.001	0.089	<0.001	0.001
LVEF, %	44.6 ± 10.1	48.9 ± 8.2	60.6 ± 6.2	-	0.001	-	-
Total protein (g/l)	70.8 ± 7	68.9 ± 5.0	66.9 ± 5.1	<0.001	0.014	<0.001	0.002
Peak troponin-T, ng/mL	5.3 (14.5)	4.6 (12.3)	-	0.744	-	-	-
SYNTAX score	29.1 ± 5.3	15.1 ± 5.1	0 ± 0	-	<0.001		
WBV at LSR	58 ± 17.1	48.2 ± 15.5	35.2 ± 13.7	<0.001	0.004	<0.001	<0.001
WBV at HSR	17.2 ± 1.2	16.7 ± 1.1	16.0 ± 1.1	<0.001	0.003	<0.001	<0.001

Data are given as mean ± SD, n (%) or median (lower-upper limit). BMI, body mass index; CABG, coronary artery bypass grafting; CRP, C-reactive protein; HDL, high-density lipoprotein; LDL, low-density lipoprotein; LVEF, left ventricular ejection fraction; NCA, normal coronary artery; NSTEMI, Non ST-segment elevation myocardial infarction; MI, myocardial infarction; STEMI, ST-segment elevation myocardial infarction; SYNTAX, The anatomical synergy between percutaneous coronary intervention (PCI) with taxus and cardiac surgery; WBC, white blood cell; WBV at HSR: Whole blood viscosity at high shear rate; WBV at LSR: Whole blood viscosity at low shear rate.

Table 2. Multivariate linear regression analysis showing the predictors for the SYNTAX score

Variables	Univariable Beta (95% CI)	P value	Multivariable Beta (95% CI)	P value
Age	1.032 (1.012-1.052)	0.001	1.028 (1.001-1.056)	0.043
BMI	1.114 (1.041-1.191)	0.050	0.979 (0.896-1.069)	0.631
Diabetes Mellitus	1.721 (1.057-2.801)	0.029	1.055 (0.516-2.157)	0.434
Glucose	1.007 (1.004-1.011)	0.043	1.002 (0.997-1.006)	0.428
Total cholesterol	1.002 (0.997-1.007)	0.420	-	-
LDL-C	1.004 (0.999-1.010)	0.141	-	-
Hematocrit	1.107 (1.056-1.160)	0.031	1.080 (1.016-1.148)	0.078
Lymphocyte	0.758 (0.608-0.944)	0.160	-	-
CRP	1.014 (1.004-1.024)	0.049	1.001 (0.991 - 1.011)	0.858
Total protein	1.794 (1.162-2.271)	0.020	1.889 (1.117 - 2.011)	0.057
WBV at LSR	1.025 (1.015-1.035)	<0.001	1.003 (0.997-1.017)	<0.001
WBV at HSR	1.693 (1.388-2.066)	<0.001	1.517 (1.431-1.923)	<0.001

BMI, body mass index; CRP, C-reactive protein; HDL, high-density lipoprotein; LDL, low-density lipoprotein; WBV at HSR: Whole blood viscosity at high shear rate; WBV at LSR: Whole blood viscosity at low shear rate.

Table 3. Pearson analysis of SYNTAX score with hemorheological parameters.

Variables	r value	p value
WBV at LSR	0.333	<0.001
WBV at HSR	0.347	<0.001

WBV at HSR: Whole blood viscosity at high shear rate; WBV at LSR: Whole blood viscosity at low shear rate.

ID: 298

Topic: **Cardiology » Acute Coronary Syndromes**Presentation Type: **Oral****RELATION BETWEEN SERUM THYROID HORMONE LEVELS,
SUBCLINICAL HYPOTHYROIDISM AND CORONARY COLLATERAL
CIRCULATION IN PATIENTS WITH NON-ST ELEVATION MYOCARDIAL
INFARCTION****Bahar Tekin Tak**, Firdevs Ayşenur Ekizler, Habibe Kafes, Serkan Çay, Özcan Özeke, Dursun Aras*Turkiye Yuksek Ihtisas Training and Research Hospital , Ankara, Turkey***Corresponding Author (tekinbahar@yahoo.com)**tekinbahar@yahoo.com, firdevs_bsk@hotmail.com, drhabibekafes@hotmail.com, cayserkan@yahoo.com, ozcanozeke@gmail.com, drdaras@gmail.com***Abstract Text****Background:**

Thyroid disease is a prevalent endocrine disease with crucial effects on the cardiovascular system. Coronary collateral circulation (CCC) conduits an alternative blood flow to the ischemic myocardium in the setting of coronary artery occlusion which can limit the infarction area to expanse more widely. Many factors that may change CCC development have been assessed thus far. In spite of increased awareness regarding the development of CCC, thyroid hormone levels and subclinical thyroid disease have not been clearly investigated. We aimed to demonstrate whether the presence of Subclinical hypothyroidism (SH) is associated with coronary collateral circulation (CCC) in patients with non-ST elevation myocardial infarction (NSTEMI).

Methods:

In total, 366 consecutive patients with non-ST elevation myocardial infarction (NSTEMI) who underwent coronary angiography procedure and had documented total occlusion in at least 1 major coronary artery were investigated retrospectively. Degree of CCC was classified according to Cohen-Rentrop method. The patients were classified into impaired CCC (group 1, Rentrop grades 0-1) or good CCC (group 2, Rentrop grades 2-3). Serum free triiodothyronine (FT3), free thyroxine (FT4) and thyroid-stimulating hormone (TSH) were assessed by the chemiluminescence immunoassay technique. Subclinical hypothyroidism was diagnosed from an elevated TSH value ($>4.2\text{mU/L}$) and FT4 values within the normal range.

Results:

The presence of subclinical hypothyroidism was significantly different in two groups ($p=0.012$). The TSH values were significantly higher in patients with impaired CCC than in those with good CCC (5.24 ± 1.2 vs. 2.26 ± 1.2 , $p<0.001$). According to univariate and multivariate analysis SH was found an independent predictor of impaired CCC.

Conclusion:

Our study demonstrated that, SH were found to be independent predictors of impaired CCC in patients with non-ST elevation myocardial infarction (NSTEMI).

ID: 312

Topic: **Cardiology » Acute Coronary Syndromes**Presentation Type: **Oral****THE PREDICTIVE ROLE OF ADMISSION LACTATE LEVEL IN PATIENTS WITH ST-SEGMENT ELEVATION MYOCARDIAL INFARCTION COMPLICATED WITH CARDIOGENIC SHOCK****Mert Ilker Hayiroğlu¹, Emrah Bozbeyoğlu¹, Özlem Yıldırım Türk¹, Seçkin Pehlivanoglu²**¹*Istanbul Dr. Siyami Ersek Göğüs Kalp ve Damar Cerrahisi Eğitim ve Araştırma Hastanesi, İstanbul, Turkey*²*Başkent University Faculty of Medicine, istanbul, Turkey***Corresponding Author (mertilkerh@yahoo.com)**mertilkerh@yahoo.com, emrahbozbeyy@gmail.com, ozlemyt@gmail.com, seckinph@gmail.com***Abstract Text****Objective**

Deterioration of renal functions after ST-segment elevation myocardial infarction (STEMI) complicated with cardiogenic shock (CS) remains as a serious condition causing high morbidity and mortality despite advances in medical treatment and coronary intervention procedures. Hemodynamic deterioration, occurrence of multi-organ dysfunction and development of systemic inflammatory response play a major role in mortality of CS patients. Accordingly, not only hemodynamic derangements but also inflammatory, neurohumoral and metabolic parameters should be taken into consideration since they could be precursors for new therapeutic strategies. Regarding metabolic parameters, serum lactate level is considered to be a reliable indicator of tissue hypoperfusion. In the current study, we evaluated the importance of admission serum lactate level in patients of STEMI complicated with CS.

Methods

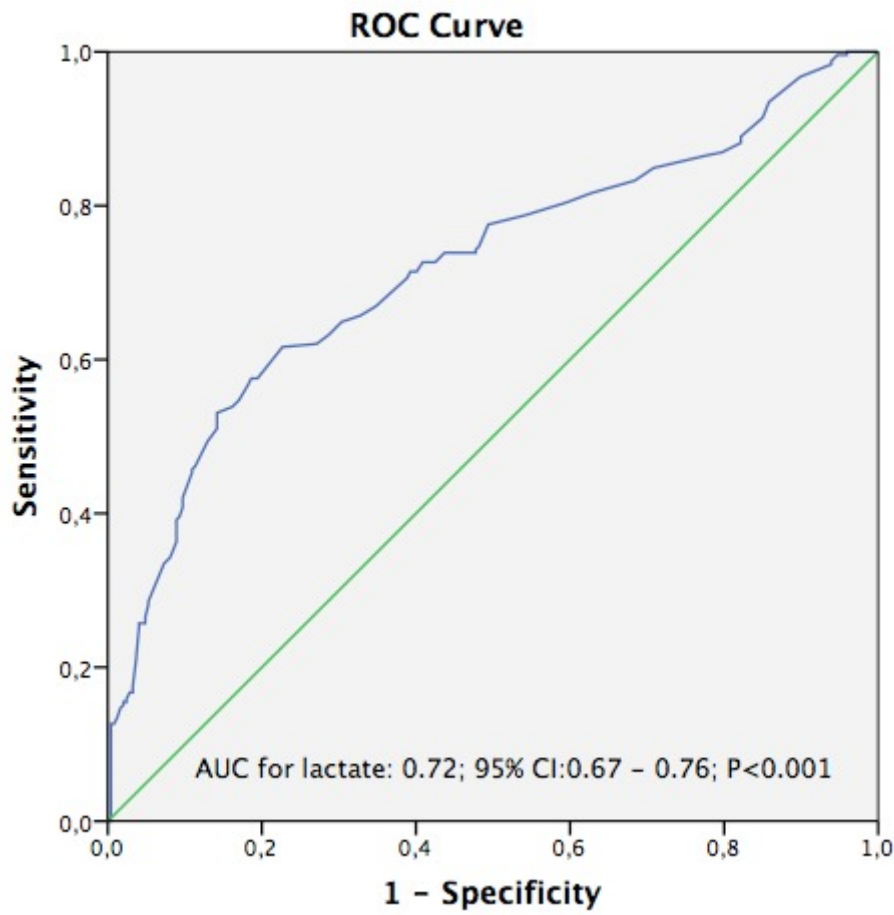
In this retrospective study, we evaluated the predictive value of baseline characteristics, echocardiographic and laboratory parameters on acute kidney injury of 492 patients with STEMI complicated with CS who were treated with primary percutaneous coronary intervention. The predictive value for acute kidney injury of admission lactate level was assessed by mean of the area under receiver operating characteristic (ROC) curve calculation.

Results

The acute kidney injury rate was found to be 49.8% in the study population. At multivariate analysis after adjustment for the parameters detected in univariate analysis; chronic renal failure, plasma lactate and blood urea nitrogen levels were independent predictors of acute kidney injury. ROC analysis showed that the best cut-off value of the lactate to predict acute kidney injury was 4.95 with 71% sensitivity and 72% specificity (AUC: 0.72; 95% CI: 0.67–0.76; $p < 0.001$)

Conclusion

Hyperlactatemia is an independent predictor for acute kidney injury in patients with STEMI complicated with CS. Patients with higher lactate levels should be followed more closely in regard to their renal functions during the cardiogenic shock process.



Multivariate analysis	p value	OR (95% CI)
Chronic renal failure	0.007	
BUN at admission	<0.001	
Lactate at admission	0.001	

ID: 443

Topic: **Cardiology » Acute Coronary Syndromes**Presentation Type: **Oral****RELATION BETWEEN ANGIOTENSIN-II TYPE 1 RECEPTOR GENE POLYMORPHISMS AND MUSEKNA INDEX (MODIFIED PROGNOSTIC INDEX) IN PATIENTS WITH A FIRST ANTERIOR ACUTE MYOCARDIAL INFARCTION****Onder Ozturk, Unal Ozturk***Diyarbakir Gazi Yasargil Education and Research Hospital, Diyarbakir, Turkey***Corresponding Author (droozturk21@hotmail.com)**droozturk21@hotmail.com, drunalozturk@gmail.com***Abstract Text**

Objective: Angiotensin-II Type-1 Receptor (AGTR1) gene C allele was associated with augmented neurohumoral activation and cardiac dilatation, as well as poor prognosis after an acute myocardial infarction. Patients with acute anterior myocardial infarction who have AGTR1 C allele is high risk of heart failure and death. Prediction tools are particularly helpful in this context in guiding medical decision-making. Antonini L et al found that prognostic index was predictor of death and heart failure in patients with ischemic cardiomyopathy implanted with an ICD. The prognostic index (PI) was built according to the formula: $120 - \text{age} + \text{mean 24 h systolic blood pressure} - (\text{creatinine} * 10)$. However, mean 24 h systolic blood pressure calculation is not clinically easy. Therefore, we propose a new modified prognostic index (Musekna Index). Musekna Index was calculated as $120 - \text{age} + \text{mean arterial pressure} - (\text{creatinine} * 10)$. We aimed to investigate relation between Angiotensin-II Type-1 Receptor (AGTR1) gene polymorphisms and Musekna Index in patients with a first acute anterior myocardial infarction.

Methods: Overall 132 patients with a first anterior AMI were included in this cross-sectional study. The AC status was determined by polymerase chain reaction (Figure 1). Based on the polymorphism of the AGTR1 gene, they were classified into 2 groups: AA genotype (Group 1, n=91), AC / CC genotype (Group 2, n=41). Musekna Index (Modified Prognostic Index) was calculated as $120 - \text{age} + \text{mean arterial pressure} - (\text{creatinine} * 10)$. Echocardiographic examinations were performed using the parasternal longitudinal axis and apical 4-chamber windows in accordance with the recommendations of the American Echocardiography Committee. OMann-Whitney U test and Chi-square analyses were used to compare differences among subjects with different genotypes. The study was approved by the local Ethics Committee, and each patient gave a written consent.

Results: There were no significant differences among clinical parameters of patients (Table 1). LVEF was significantly lower in patients who have AGTR1 AC/CC genotypes than in patients who have AGTR1 AA genotype ($37.5 \pm 5.9\%$ and $42.7 \pm 6.8\%$, $p=0.036$). Musekna Index was significantly lower in patients who have AGTR1 AC/CC genotypes than in patients who have AGTR1 AA genotype (137.3 ± 18.9 and 145.1 ± 17.5 , $p=0.002$).

Conclusions: Our results suggested that, AGTR1 Gene A/C polymorphism C allele may affect Musekna Index in patients with a first anterior AMI.

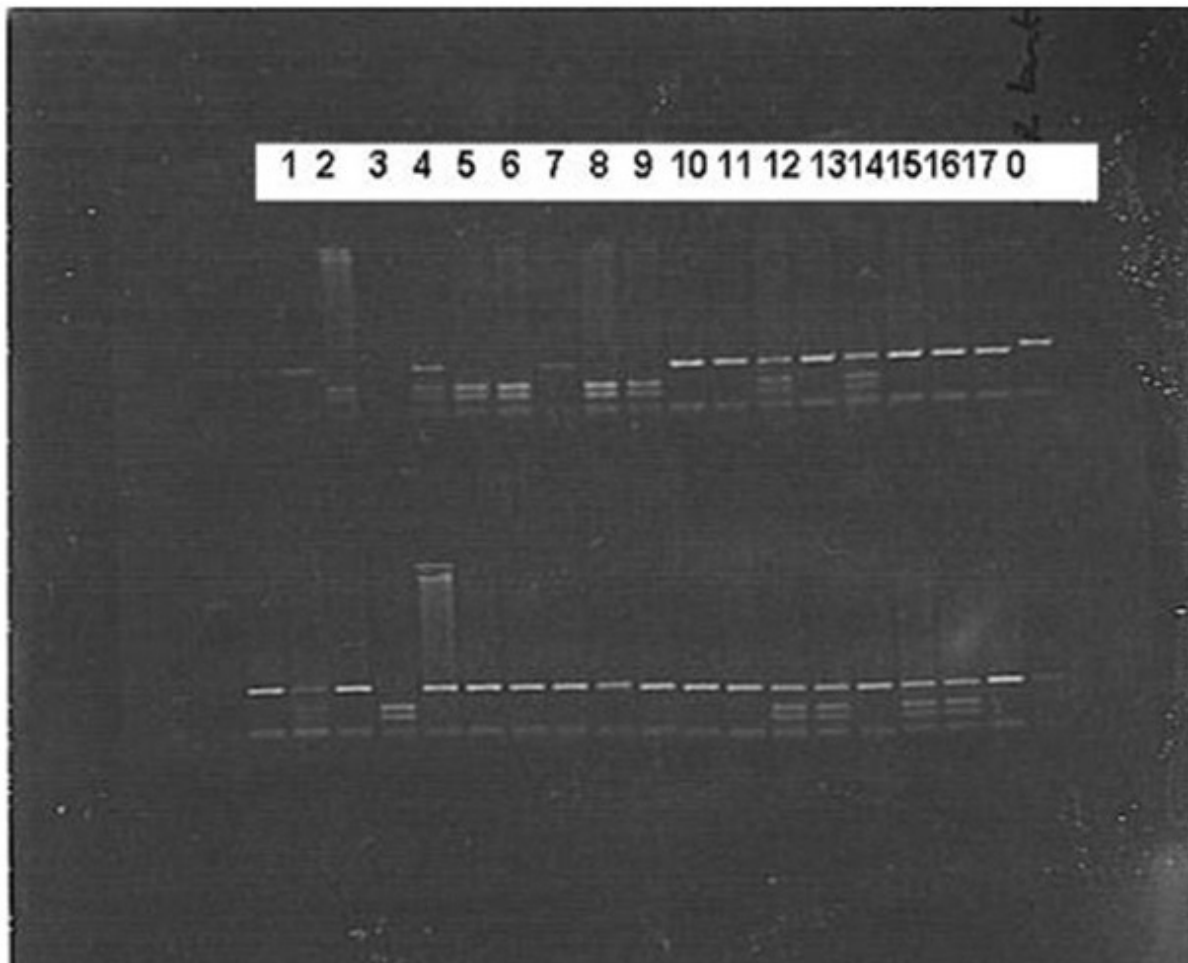


Table 1: Clinical Characteristics of the Patient Groups According to AGTR1 Genotypes.

Variables	AGTR1 AA Genotype (n=91)	AGTR1 AC/CC Genotype (n=41)	p value
Age (years)	57±13	59.4±15	0.545
Sex (F/M)	16/75	10/31	0.478
Heart rate (beats/min)	87.6±13.7	86.9±15.1	0.644
Hypertension	34 (38%)	10 (24%)	0.032
Diabetes	18 (20%)	10 (24%)	0.728
Smoking	57 (63%)	24 (58)	0.338
BMI (kg/m ²)	23.9±3.4	25±2.9	0.779
Hypercholesterolemia	29 (32%)	12(29%)	0.714
Troponin I (ng/mL)	16.1±5.9	18.3±4.7	0.760
MI Localisation, n(%)			
-Anteroseptal	15 (17%)	7 (16%)	0.473
-Anterior	25 (28%)	10 (26%)	0.519
-Large Anterior	43 (47%)	21 (51%)	0.348
-Anterolateral	7 (8%)	3 (7%)	0.613

ID: 375

Topic: **Cardiology » Acute Coronary Syndromes**Presentation Type: **Oral**

**EPIDEMIOLOGICAL ANALYSIS AND DISEASE SPECTRUM
CHARACTERISTICS OF EMERGENCY PATIENTS WITH CRITICAL
ILLNESS: 3 176 EMERGENCY CASES IN 201 IN A HOSPITAL IN
AVELLINO WERE ANALYZED**

Pierpaolo Maietta

Aorn Moscati, Avellino, Italy

**Corresponding Author (pier.ma@virgilio.it)*

pier.ma@virgilio.it

Abstract Text**OBJECTIVE:**

To investigate the epidemiological characteristics of emergency critical illness and disease spectrum in emergency department of a hospital in avellino.

METHODS:

A retrospective study was conducted. The data of 3 176 critically ill patients aged ≥ 14 years old admitted to the emergency room of avellino Capital Medical hospital from January 1st to December 31st in 2017 were analyzed, including gender, age, clinical time, discharge diagnosis, outcomes, etc. To analyze the epidemiological characteristics and disease spectrum distribution of emergency critically ill patients, annual and daily 24-hour emergency visits in 2017 were analyzed.

RESULTS:

Among the 3 176 cases of acute critical illness, there were more males than females (1 824 vs. 1 352, 1.35:1); the age ranged from 14 to 100 years old, with an average of (66.52 ± 17.18) years old; the highest incidence age was 75-89 years old (35.2%, 516 males and 603 females), followed by 60-70 years old (30.0%, 572 males and 381 females). The top four prevalence diseases in the emergency critical disease spectrum were cardiovascular diseases [41.8%, 716 males and 610 females, age (70.25 ± 15.08) years old], nervous system diseases [26.7%, 502 males and 346 females, age (60.28 ± 17.57) years old], respiratory disease [12.3%, 226 males and 166 females, age (72.96 ± 16.23) years old] and digestive system diseases [5.6%, 119 males and 60 females, age (65.40 ± 17.96) years old], accounting for 86.4% of the total. There were more males than females (all $P < 0.05$), and the age difference was statistically significant ($F = 84.094$, $P < 0.001$). Arrhythmia was the most common cardiovascular disease (16.7%), followed by acute coronary syndrome (12.0%) and heart failure (9.1%); the main nervous system diseases were stroke (20.9%); respiratory diseases mainly included severe pneumonia (8.3%); digestive system diseases were mainly with digestive tract bleeding (4.4%). The high incidence of acute critical illness in the emergency department occurred in winter (287 cases in December and 277 cases in January) and the early stage of spring (282 cases in March). The daily peak period was midday and at night, especially from 18:00 to 23:00 (163 cases at 18:00, 173 cases at 19:00, 172 cases at 20:00, 186 cases at 21:00, 167 cases at 22:00, 169 cases at 23:00). The average treatment time of critically ill patients in emergency room was 1.5 days (the longest was 23.0 days, the shortest was 6 minutes), among them, 85.6% of the patients could be discharged from the emergency within 3 days, and 1.9% of the patients stayed in the emergency for more than 7 days. There were 305 deaths (9.6%), mainly among the elderly, with an average age of (71.10 ± 16.08) years old.

CONCLUSIONS:

Cardiovascular and cerebrovascular diseases, respiratory and digestive diseases are the main causes of acute critical diseases in department of emergency of aorn moscati Medical hospital in 2017. Male and elderly patients are more common; different types of acute and severe patients tend to attack at different ages.

ID: 577

Topic: **Cardiology » Percutaneous Coronary Interventions**Presentation Type: **Oral**

A RETROSPECTIVE EVALUATION OF PERIPROCEDURAL MYOCARDIAL INFARCTION

Nurcemal Şentürk, Mustafa Gökçe

Karadeniz Teknik Üniversitesi Tıp Fakültesi, Trabzon, Turkey

**Corresponding Author (nurcemal61@hotmail.com)*

nurcemal61@hotmail.com, drmustafagokce@gmail.com

Abstract Text

Objective:

To assess retrospectively the prevalence, predictor factors and prognosis of periprocedural myocardial infarction (PMI) at stable angina pectoris patients who undergone elective percutaneous coronary intervention (PCI) and stent implantation in our clinic between 2015 to 2017.

Materials and Methods:

A total of 581 stable coronary artery disease patients who had available medical data at institutional record system were enrolled. Patients with normal Tn levels before PCI or with high Tn levels at baseline but unchanged or decreasing consecutive Tn measurements were included to the study according to Third Universal Definition of Myocardial Infarction (MI) guideline. As basal characteristics, presence of DM, HT, previous MI, coronary artery bypass graft surgery and stent history, age, gender, previous medications and smoking status were evaluated. Data was acquired by evaluating epicrisis, outpatient examination notes, angiography records and routine biochemical tests of patients. PMI prevalence after PCI, related risk factors and long-term mortality were statistically evaluated by using high sensitive troponin-T as cardiac biomarker.

Results:

PMI rate was identified as 26% in our study. All patients followed 23.7±11.2 months after index procedures. PMI was not related with total mortality within two years of period but have a trend toward increased relation ($p=0,089$). Moreover overall group of patient's survival rate were found to be 94.7% in this time period. Low density lipoprotein (LDL) cholesterol level, age of 75 or more, intervention to multiple coronary arteries, presence of 2 or more implanted stent, elevated creatinine level and stent length were identified as independent risk factors when causes increasing PMI rate according to univariate analysis result were evaluated in multivariate logistic regression analysis. A statistically insignificant relation was identified between elevated basal troponin level and long-term mortality rates.

Conclusion:

Risk factors identified in our study were consistent with previous studies. Only different finding from previous studies is lower LDL cholesterol level in PMI group than group without PMI. Although mortality was relatively seen higher rate in PMI group, this was statistically not significant. Multi-centered, prospective, randomized future studies with larger patient samples will be beneficial for better evaluation of these findings.

Keywords: Coronary Artery Disease, Periprocedural Myocardial Infarction, Percutaneous Coronary Intervention

Table 1. Baseline characteristics and procedural datas of the study population

	Total (n=581)	periprocedural myocardial infarction		<i>p</i> -value
		Var (n=151)	Yok (n=430)	
Age	63.5 ± 10.3	64.4 ± 10.7	63.2 ± 10.26	0,209
≥75 years old	88 (15.1)	28 (18.5)	60 (14)	0,176
Diabetes	158 (27.2)	54 (35.8)	104 (24.2)	0,006
Creatinine (mg/dL)	0.97±0.23	0.96±0.30	0.88±0.19	0,011
LDL-cholesterol (mg/dL)	116.28±45.23	108.82±43.35	118.90±45.63	0,021
Multi vessel	171 (29.4)	72 (47.7)	99 (23.0)	<0,0001
Number of Stents ≥2	197 (33.9)	76 (50.3)	121 (28.1)	<0,0001
Stent length	28.24±18.38	37.95±22.38	24.84±15.38	<0,0001

Table 6. The relationship between periprocedural MI and death

	Total(n=581)	periprocedural myocardial infarction		<i>p</i> -value
		Var (n=151)	Yok (n=430)	
Death				
Yes	13 (2.2)	6 (4)	7 (1.6)	0,089
No	568 (97.8)	145 (96)	423 (98.4)	

Table 5. Multivariable logistic analysis of independent predictive factors in periprocedural myocardial infarction

Variables	OR	95% C.I.	Z	P değeri
CX lesion	1,335	0,789-2,258	0,289	0,281
Stents history (yes)	0,626	0,369-1,063	-0,468	0,083
CABG history (yes)	1,637	0,825-3,248	0,493	0,159
LVEF \leq 40(%)	0,696	0,340-1,424	-0,363	0,320
LDL-cholesterol	0,991	0,985-0,997	-0,09	0,003
\geq 75 years old	0,501	0,267-0,938	-0,692	0,031
Multi-vessel (yes)	2,791	1,206-6,457	1,026	0,016
Bifurcation lesion (yes)	1,347	0,470-3,862	0,298	0,579
CTO (yes)	1,856	0,680-5,070	0,619	0,228
DES (yes)	3,401	0,568-20,373	1,224	0,180
BMS (yes)	1,033	0,409-2,610	0,032	0,945
Overlapping (yes)	2,280	0,649-8,015	0,824	0,199
Predilation (yes)	1,011	0,575-1,777	0,011	0,970
Postdilation (yes)	1,750	0,928-3,298	,559	0,084
Diabetes (yes)	1,148	0,674-1,953	0,138	0,612
Stent length	1,032	1,011-1,053	0,031	0,002
Number of Stents \geq 2	0,390	0,155-0,978	-0,942	0,045
Creatinine	3,349	1,120-10,015	1,209	0,031
CRP	1,174	0,993-1,387	0,160	0,060

Oral Presentations
Different Perspectives in Acute Coronary Syndromes
Date: 29.03.2019 Time: 13:30 - 14:45 Hall: 5

ID: 192

Topic: Cardiology » Acute Coronary Syndromes

Presentation Type: Oral

**SPECIAL FEATURES OF ACUTE CORONARY SYNDROME IN RAMADAN:
PROSPECTIVE STUDY OF A NORTH-AFRICAN POPULATION.**

Maryam Mouadili, Mariame Chakir, Cyriaque Mbauchy

Centre Hospitalier Universitaire Mohammed VI Marrakech, Marrakech, Morocco

**Corresponding Author (maryam.mouadili@gmail.com)*

maryam.mouadili@gmail.com, mariamechakir@hotmail.com, cyrmbauchy@hotmail.com

Abstract Text

Abstract:

Data on the effect of Ramadan on coronary heart disease are rare and controversial. The purpose of our survey is to determine the impact of Ramadan on the prevalence of acute coronary syndrome (ACS) in a population of patients followed in our cardiology department.

Methods: This is a prospective study, carried out at the Department of Cardiology and Vascular Diseases in our setting during 2 successive Ramadan periods (2017-2018), including three months period ranging from a month before, during and one month after Ramadan. We included all patients admitted for ACS during the study period. The data were collected on a standardized form. We performed a mono and multivariate analysis of the results.

Results: During the six months period of the study, we included 153 patients admitted for ACS with (43%) and without (57%) ST segment elevation. The prevalence of ACS among hospitalized patients over this period was 15% one month before Ramadan, 19% during Ramadan, and 27% one month after Ramadan. According to the results of the multivariate analysis, the risk of ACS is not increased in Ramadan month, and is greater during the following month. In a subgroup analysis of the population of patients with ACS occurring during the month of Ramadan, we found an increased risk of ACS in men over 60 years of age, and those with hypertension or diabetes. The period including Ramadan and the month following it is not associated with an increased risk among subjects with no more than one cardiovascular risk factor (other than age, hypertension and type 2 diabetes).

Conclusion: The prevalence of ACS is not increased in the month of Ramadan except in elderly hypertensive and diabetic patients; the increased risk of ACS the following month can be explained by the inadequate lifting of the dietary restriction. More studies need to be done to better explain this difference in prevalence.

ID: 308

Topic: Cardiology » Percutaneous Coronary Interventions in Acute Coronary SyndromesPresentation Type: **Oral****SEVERE CORONARY SPASM: UNCOMMON REASON OF SUDDEN CARDIAC ARREST****Belma Yaman, Ümit Yüksek, Levent Cerit, Hatice Kemal Günsel, Songül Usalp, Hamza Duygu***Near East University Faculty of Medicine, Nicosia, Cyprus***Corresponding Author (belmayaman@yahoo.com)**belmayaman@yahoo.com, uyuksekk@yahoo.com, drcerit@hotmail.com, drhaticekemal@gmail.com, dr.songulusalp@hotmail.com, hamzakard@yahoo.com***Abstract Text****Introduction**

Coronary vasospasm is one of the important causes of myocardial ischemia, unfortunately it is not an uncommon event. Generally coronary vasospasm occurs with exercise and causes exercise related angina. In a few cases coronary vasospasm may cause serious arrhythmias such as ventricular fibrillation or heart block and cardiac arrest in which cases there is an anomalous coronary artery. In our case we present coronary vasospasm in right coronary artery which progressed to cardiac arrest at rest.

Case presentation

A 63-year-old male patient was admitted to our hospital with sustained epigastric pain. ECG had normal sinus rhythm without any ischemic changes. The troponin-I (4,673 pg/mL), ck-mb (11,6 pg/mL) levels were increased. We performed primary percutaneous coronary intervention (PCI) with the diagnosis of non-ST elevation myocardial infarction. Coronary angiography revealed total occlusion (100%) in the mid left anterior descending artery (LAD), 90% stenosis in the first diagonal artery, and 30% stenosis in the proximal right coronary artery (figure 1). We performed PCI for LAD lesion and two sequential drug-eluting stents (DES) with 2.75x33 mm size were implanted. Three days after the procedure, patient complained of epigastric pain followed by bradycardia and cardiac arrest. After intubation and successful CPR the patient underwent coronary angiography again. The proximal LAD stent was patent, but there was a severe stenosis in proximal RCA (figure 2). After giving intracoronary nitroglycerin angiography showed regression of the RCA lesion. We stopped beta-blocker and added calcium channel blocker to his treatment. At one month follow up, the patient was asymptomatic and left ventricular systolic function was normal.

Discussion

Coronary vasospasm is the leading cause of exercise related ischemia. Calcium channel blockers are the main treatment modalities for preventing angina related ischemia. Patients present with angina during exercise, hemodynamic instability, arrhythmia, cardiac arrest. ST segment changes might occur on ECG. In recent studies, it is shown that coronary vasospasm is one of the most important causes of out-of-hospital cardiac arrest. In few cases coronary vasospasm can lead to cardiogenic shock and intraaortic balloon pump (IABP) can be needed to support patients' hemodynamics. Severe arrhythmia and cardiac arrest are mostly seen in patients with coronary artery anomalous or multivessel vasospasm. In our case, following heart block cardiac arrest developed at rest. Due to the history of stent implantation to LAD we suspect acute stent thrombosis however, coronary angiography showed severe vasospasm in right coronary artery which resolved after coronary nitroglycerin. After switching beta-blockers to calcium channel blockers there was no sign of coronary ischemia. Coronary artery vasospasm should be mentioned in in-hospital or out-hospital cardiac arrests. Treatment modality with calcium channel blockers, implantable cardioverter defibrillators or IABP to support hemodynamic instability in special patient groups must be evaluated.

ID: 382

Topic: Cardiology » Percutaneous Coronary Interventions in Acute Coronary SyndromesPresentation Type: **Oral****A CARDIAC CYST PRESENTED WITH NON ST ELEVATION MYOKARDIAL INFARCTION****Yusuf Çekici, Isa Sincer, Gökalp Güzel***Dr Ersin Arslan Education and Research Hospital Gaziantep Turkey, Gaziantep, Turkey***Corresponding Author (coroner1796@hotmail.com)**coroner1796@hotmail.com, isasincer@yahoo.com, drgokalpguzel@gmail.com***Abstract Text**

ABSTRACT

Cardiac involvement in hydatid disease is uncommon, representing only 0.5-2 % of all echinococcosis cases. Our case is striking as there is the Cardiac hydatid cyst which causes myocardial ischemia by external compression of the coronary artery.

Introduction:

Cardiac hydatid cyst (CHC) is mostly asymptomatic for years, but sometimes it can lead to life-threatening clinical conditions. In this study, we report CHC that lead to non ST segment elevation myocardial infarction.

Case report:

A 15-year-old female patient with typical chest pain was admitted to the cardiology department of our hospital. He had occasional chest pain, which had been aggravated for 3 days. Non ST elevasyon myokardial infarction (NSTEMI) (DII,DII,aVF, V4, V5, and V6 ST Depression and T wave inversion) . An 87*65mm sized cystic lesion that lies to inferior in heart apex level was determined in the thorasic computed tomography (CT) and Echocardiography investigation which was performed (Figure1). Coronary angiography (CAG) was planned to the patient because of positive troponin. CAG was performed in the patient and it was seen that pressure findings that causes 90% narrowness were observed in first obtus marginal artery (OM1) (Figure 2).CAG was performed postop two month later. It was determined pressure finding on coroner artery was totally lost in the CAG performed, and that coroner arteries are normal. (Figure2).

Discussion:

The size, location, and integrity of the cyst are significant for manifestations. Transmission change or myocardial ischemia can be seen in the ones which stay in septum. Cysts which make pressure on coronary arteries can cause myocardia infarctus. In our case, our patient has consulted us with myocardia infarctus as result of pressure on coronary artery. The most effective method to diagnose cardiac cyst hydatid is with ECHO. CT and magnetic resonance imaging (MRI) should be used to evaluate extra cardiac hold. We diagnosed our case with ECHO and CT. The treatment of cardiac cyst hydatid is surgery, and it must not be delayed. As the cyst has serious complications such as rupture to heart cavities or pericard or sudden deaths, generally accepted treatment is urgent operation.

Conclusions:

Cardiac hydatid cysts are an important disease in endemic regions such as our country. This disease, which is generally asymptomatic, can lead to serious complications that might even result in death. During the evaluation of patients in emergency services, hydatid cyst should be considered for pathologies observed in the heart, and any complications should be treated accordingly.

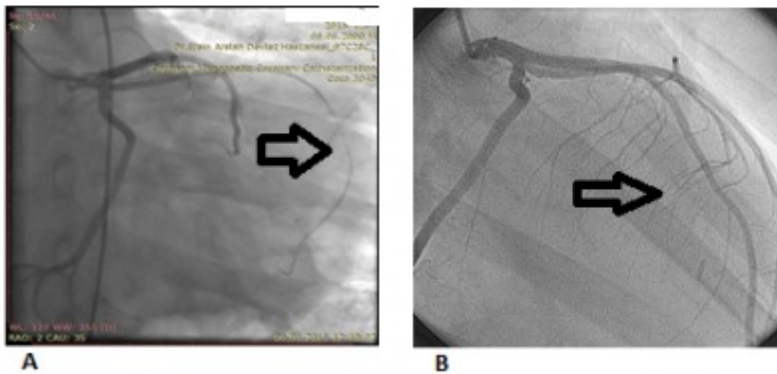


FIGURE 2: Coronary Angiogram Shows Stenosis in Mid First Obtus Marginal Artery (A), Postop Coronary Angiogram (B) Images

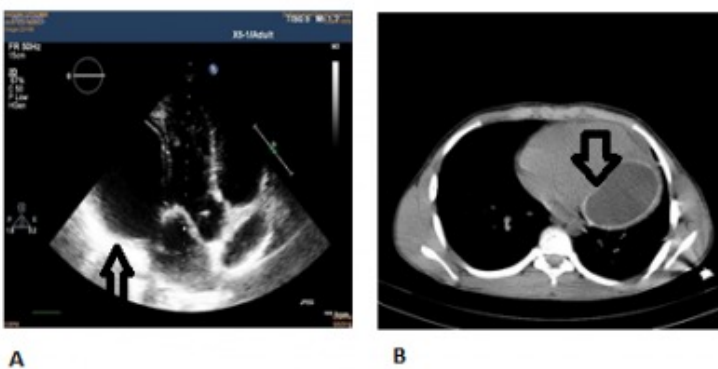


Figure 1. Transthoracic Echocardiography (A) and Thoracic Computed Tomography Images

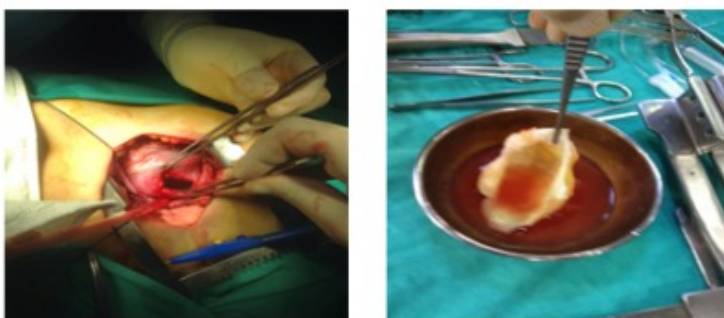


FIGURE 3 : Intraoperative Images

ID: 334

Topic: **Cardiology » Percutaneous Coronary Interventions**Presentation Type: **Oral****FASTING VS NON FASTING PRIOR TO ELECTIVE CARDIAC CATHETERIZATION****Syed Mohammad Haleem***Aintree University Hospital , Liverpool , United Kingdom***Corresponding Author (haleem.d@yahoo.com)**haleem.d@yahoo.com***Abstract Text**

Fasting Versus Non-fasting prior to elective Cardiac catheterisation: A Pilot Study

Hesham K Abdelaziz Ph.D1,2; Syed Haleem MRCP1

; Mohamed Mostafa

Ph.D2

; Charlotte Waterhouse1

, Jonas Eichhofer Ph.D1

1Lancashire cardiac centre- Blackpool Victoria Hospital-UK

2Ain Shams University- Cairo-Egypt

Abstract

Background: There is little evidence available about the benefits of pre-procedural fasting and prospective randomized trials are lacking with no clear guidelines recommendations that advocate the benefit of fasting prior to cardiac catheterization. **Objective:** To investigate the safety and feasibility of non-fasting prior to elective coronary catheterization.

Method: Single centre, open label randomised control trial involving 50 patients presented for elective coronary catheterization, randomised in 1 :1 fashion to either standard hospital fasting policy that allow clear fluids up to the time of the procedure and no food for at least 2 hours before the procedure (control arm) or allowed to drink and eat freely up to the point of transfer to the catheter laboratory (intervention arm). Primary endpoint consisted of a composite of nausea, vomiting, peri-procedural abdominal pain, emergency intubation and aspiration. Other secondary end points included patient satisfaction score, incidence of hypoglycemia and hypotension, and 30-day chest infection rate.

Results: Our pilot study included 50 patients who were randomized to fasting group (n=25) and non-fasting group (n=25). There was no difference in the primary composite endpoint for safety between fasting and non-fasting group (4% vs 0, p=0.31). Compared to fasting group, the non-fasting group had more diabetic patients (4% vs 24%, p=0.009), higher admission blood sugar (7±3 mmol/L vs 5±1 mmol/L, p=0.01), shorter duration between last meal and the procedure (110±85 min vs 433±158, p=0.009). There was no statistically significant difference between the 2 groups in terms of the patient questionnaire results or patient satisfaction score.

Conclusion: Non-fasting prior to cardiac catheterization is a safe and feasible approach which carries no additional risk compared to the standard practice of fasting. Limited number precluded any definite conclusion with regards to the secondary endpoints. A further large scale trial is warranted to confirm the safety of this approach and to investigate other endpoints.

ID: 359

Topic: **Cardiology » Acute Coronary Syndromes**

Presentation Type: **Oral**

**A PATIENT WITH DOUBLE RIGHT CORONARY ARTERY WITH
CRITICAL LESION IN ONE OF THEM AND ACUTE ANTERIOR
MYOCARDIAL INFARCTION: A RARE CORONARY ARTERY ANOMALY**

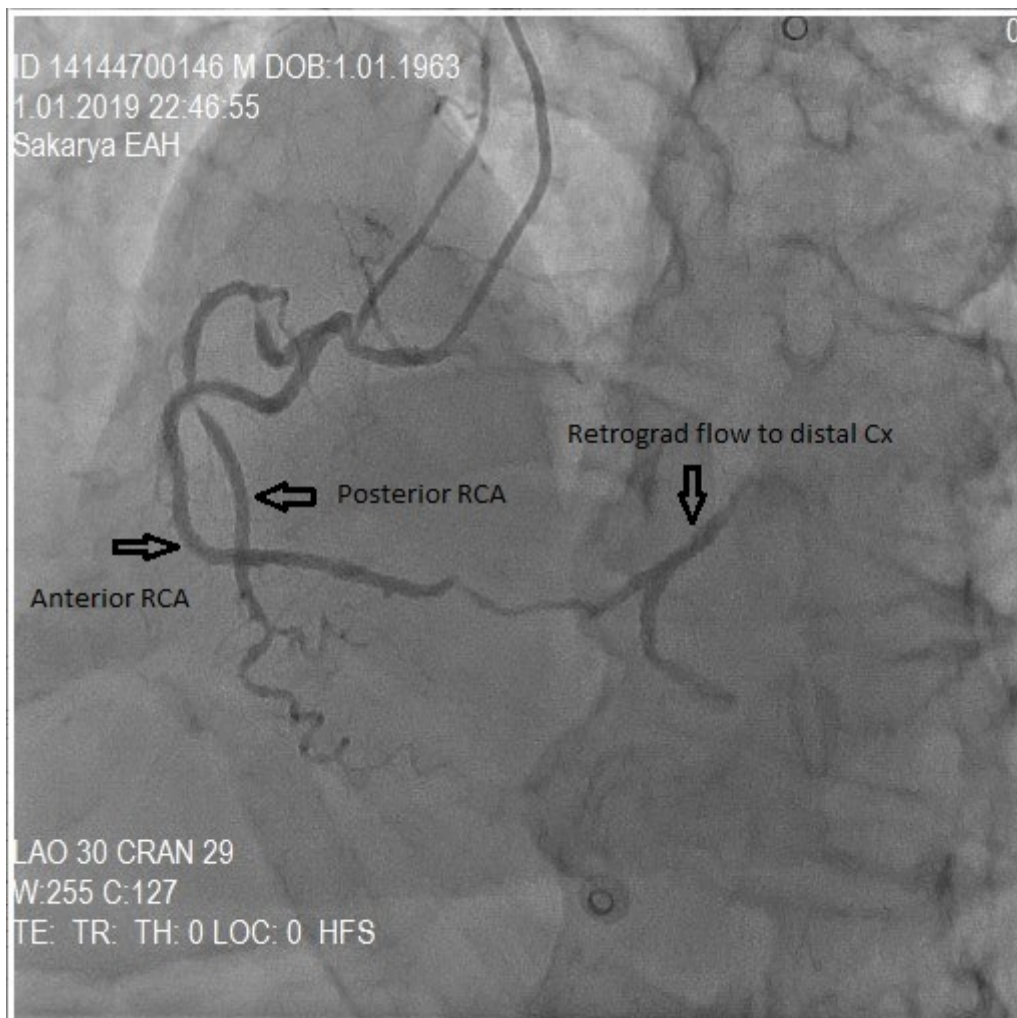
Kahraman Cosansu

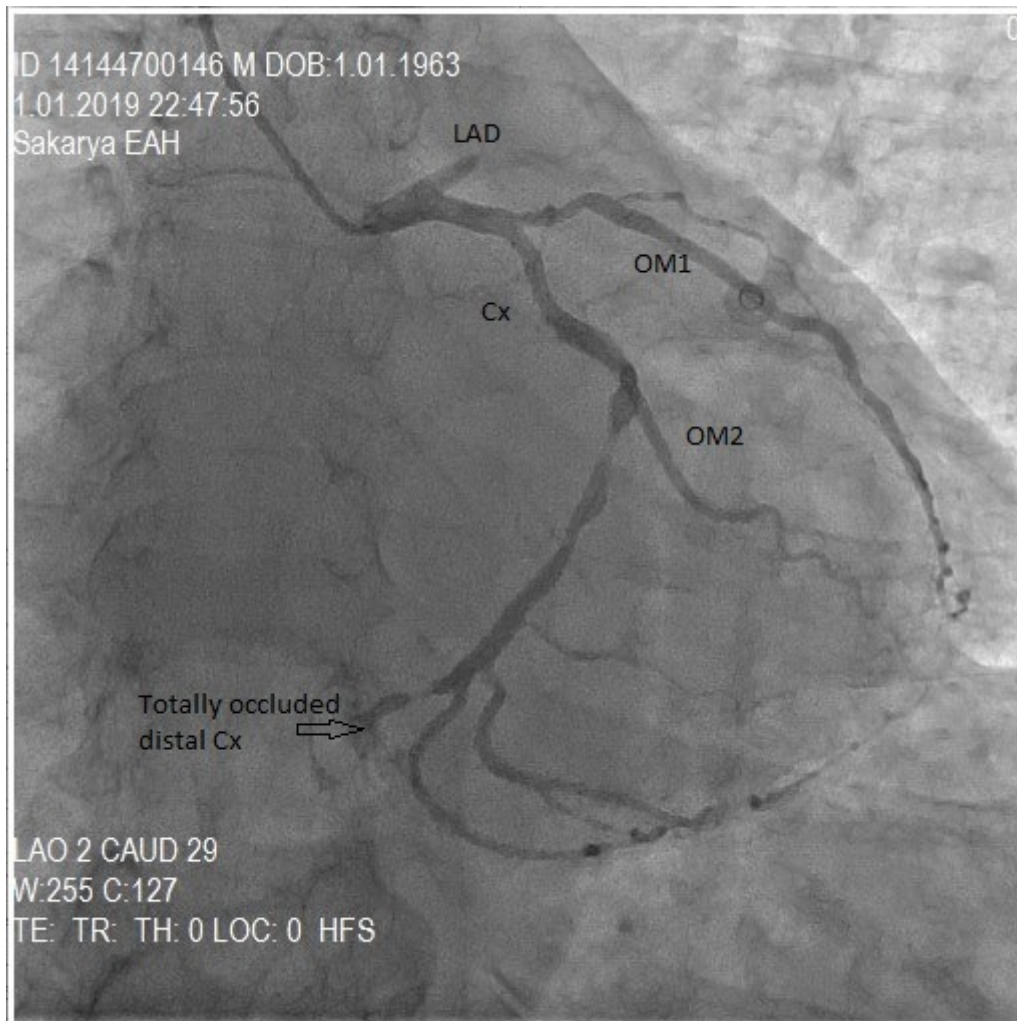Sakarya University, Education and Research Hospital, Sakarya, Turkey

**Corresponding Author (kahraman141@gmail.com)*

kahraman141@gmail.com

Abstract Text





Background: Double right coronary artery(RCA) is an extremely rare coronary artery anomaly. The true incidence of this anomaly is unknown. Although it can be regarded as a benign condition in the most of cases, it has been associated with acute and life-threatening situations. We here report double RCA which detected after primary percutaneous intervention performed to treat a 56-year-old male presenting with acute anterior myocardial infarction.

Case Report: 56-year-old male was admitted to emergency department with retrosternal chest pain at rest for 1 hour. Electrocardiogram showed ST segment elevations in anterior leads and reciprocal ST segment depressions in II, III, and aVF. Coronary angiography showed two separate RCAs originating from single ostium. The anterior RCA was free of any angiographically identifiable atherosclerotic lesion and give retrograd flow to totally occluded distal circumflex artery(Cx). In the posterior RCA, two consecutive significant stenoses in the proximal region was observed. The left coronary arteries were of normal origin and distribution; there was critical lesion in mid Cx and totally occluded distal Cx and total occlusion of the left anterior descending artery(LAD) from proximal region as a culprit lesion. The patient's symptoms were relieved after the successful intervention on the LAD. An elective PCI procedure is planned for the Cx lesion.

Conclusion: Invasive cardiologists should be kept in mind this possibility, because existence of such anomaly may change management strategies. Failure to recognize such an anomaly with atherosclerotic involvement could be disappointing and can lead to inadequate revascularization.

ID: 38

Topic: **Cardiology » Acute Coronary Syndromes**Presentation Type: **Oral****A VERY RARE COINCIDENCE OF FIRST SEPTAL AND DIAGONAL ARTERIES ORIGINATING ANOMALOUSLY FROM THE LEFT MAIN CORONARY ARTERY: A CASE REPORT****Erdoğan Sökmen***Kirsehir Ahi Evran Education and Research Hospital, Kirsehir, Turkey***Corresponding Author (erdoganmen@gmail.com)**erdoganmen@gmail.com***Abstract Text**

A 47-year-old male patient was admitted to our hospital's emergency department with the complaint of ongoing chest pain which had been lasting for 4 days. Admission ECG revealed deep Q waves along with slight ST segment elevations in the inferior derivations, and T wave inversions in the anterior derivations. Upon interrogating his past medical history, we learnt that he had been given a diagnosis of type 2 diabetes mellitus 8 years ago and undergone a coronary angiography 6 years ago. An emergency echocardiography revealed global left ventricular ejection fraction of 32% with thinning and akinesia in the posterior left ventricular wall and severe hypokinesia in the apical portion of the anterior left ventricular wall and the apex, together with mild-to-moderate mitral regurgitation and mild tricuspid regurgitation. The patient was transferred to the cardiac catheterization laboratory with the diagnosis of acute coronary syndrome.

During the coronary angiographic procedure, a true spider view in the left anterior oblique (LOA) caudal view, which included the first septal artery, the left anterior descending artery (LAD), the first diagonal artery, the intermediate artery and the left circumflex artery all originating from the left main coronary artery (LMCA), was observed (Video 1). There was a 99% stenosis in the proximal LAD. Selective right coronary angiography revealed a total occlusion in the mid-portion of the right coronary artery (RCA). Trials for passing through and re-canalize the RCA failed. Hence, we thought it was a chronic total occlusion. In the RAO cranial and LAO cranial views of the left coronary system, FSA appeared to give collateral branches to posterior descending artery (PDA), which was originating from the RCA (Video 2). At this point, we only implanted a drug-eluting stent in the severe LAD lesion.

Most of the coronary origination anomalies are clinically silent and are encountered incidentally either in coronary angiography or a computerized tomographic scan. However, they can prove very crucial when it comes to providing collateral circulating to the other main arteries which were not able to supply adequate blood flow to their pertinent territories.

15% of the blood supply of the myocardium is achieved through the first septal artery (FSA). Moreover, an anomalous FSA may play a pivotal role in providing collateral blood flow in severe coronary arterial diseases.

Despite rare presence of respective anomalous FSA and first diagonal artery reported to be originating from LMCA, there is no case report in the literature describing concomitant presence of the both arteries anomalously originating from the LMCA. To the best of our knowledge, therefore, this is the first case report describing the co-existence of the first septal and the first diagonal arteries originating anomalously from the left main coronary artery.

ID: 143

Topic: Cardiology » Acute Coronary Syndromes

Presentation Type: Oral

THE ALLERGIC MYOCARDIAL INFARCTION: KOUNIS SYNDROME

Adnan Kaya¹, Muhammed Keskin²

¹Duzce University School of Medicine, Duzce, Turkey

²Sultan Abdulhamid Han Hospital, Düzce, Turkey

**Corresponding Author (adnankaya@ymail.com)*

adnankaya@ymail.com, drmuhammedkeskin@gmail.com

Abstract Text

Objective: Kounis syndrome, allergic myocardial infarction, is a hypersensitivity reaction compromising coronary blood flow either by coronary vasospasm (type I), native plaque destabilization (type II) or stent thrombosis (type III). The main pathophysiology is a burst of systemic inflammation induced by mast cell degranulation. We would like to draw attention to this clinical issue since it can be mortal if the prejudice of physician's fails to make the diagnosis.

Methods: Here we have 3 cases of Kounis syndrome; one presented with type II, the other two with type I.

Results: The first case was a 47 year-old male patients presented with 2 hour ongoing chest pain and anterolateral ST segment elevation myocardial infarction (MI) after ingestion of amoxicillin and clavulanic acid. Coronary angiography showed an unstable plaque in mid left anterior descending artery with 50% compromise of blood flow. The case was medically treated with decreased ejection fraction to 45%. The second one was a 42 year-old lady presented with 90 minutes of ongoing chest pain and ST elevation in inferior leads after contrast media injection. CAG showed normal coronary vasculature. The third one was 35 year-old lady presenting with chest pain and widespread ST depression after diclofenac ingestion. CAG showed normal coronary vasculature.

Conclusion: Kounis syndrome diagnosis is difficult to make since the anamnesis and patients characteristics may not coincide with the atherosclerotic coronary disease. It is very important to keep it in mind not to harm the patients.

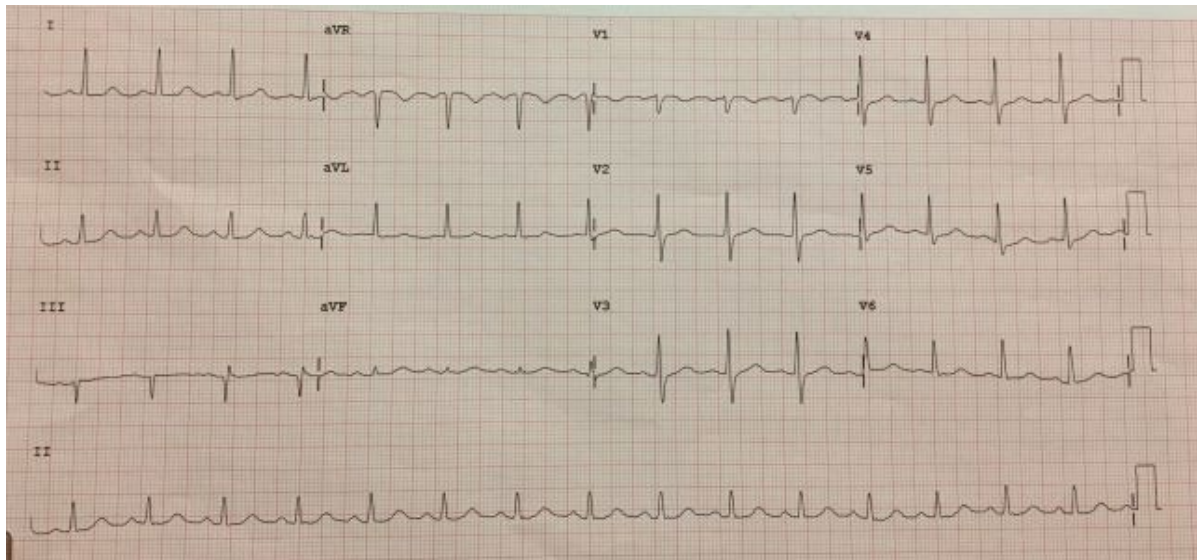
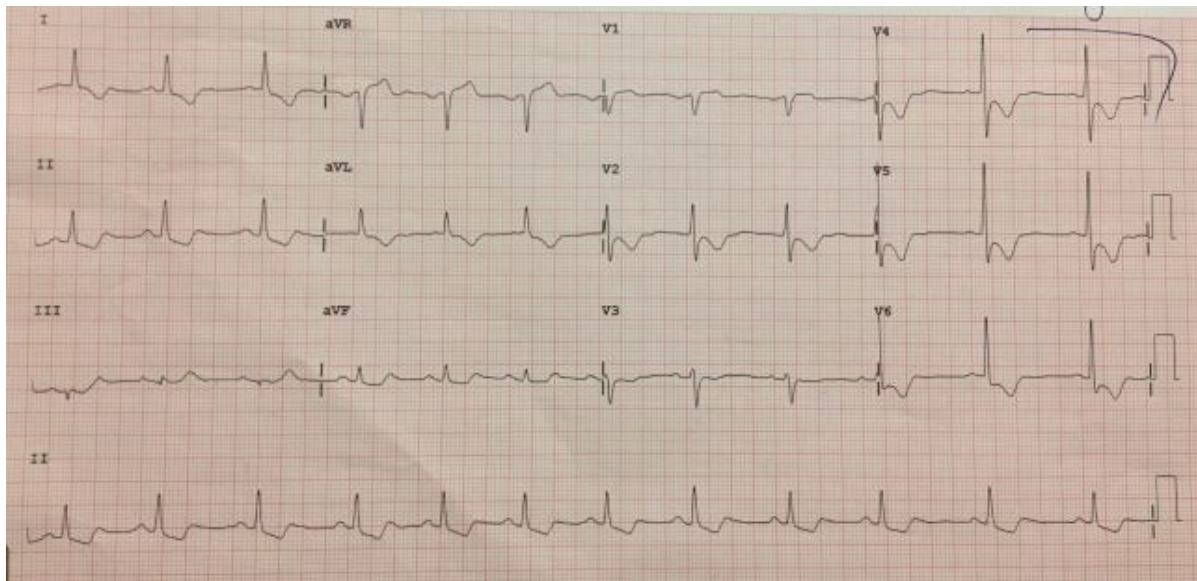
ID: 497

Topic: **Cardiology » Acute Coronary Syndromes**Presentation Type: **Oral****ACUTE CORONARY SYNDROME ASSOCIATED WITH CARFILZOMIB TREATMENT****Umüt Kocabaş**, Figen Atalay, Hakan Altay, Armağan Altun, Seçkin Pehlivanoglu*Baskent University School of Medicine, Istanbul, Turkey***Corresponding Author (umutkocabas@hotmail.com)**umutkocabas@hotmail.com, figen.atalay@baskent.edu.tr, sakaltay@yahoo.com, armagan.altun@tkd.org.tr, seckinph@gmail.com***Abstract Text**

Introduction: Carfilzomib is a selective and second generation proteasome inhibitor that is approved for the treatment of relapsed and/or refractory multiple myeloma (RRMM). Frequency of cardiotoxicity with carfilzomib is higher than with bortezomib due to its irreversible proteasome inhibition and higher potency. We describe the case of a 72-year-old man with RRMM who presented with acute coronary syndrome (ACS) after receiving carfilzomib treatment.

Case: A 72-year-old man with a history of coronary artery disease, diabetes mellitus, hypertension, hyperlipidemia, bone marrow transplantation and RRMM presented with chest pain and shortness of breath approximately 24 hours after the beginning of carfilzomib treatment (56 mg/m²/day carfilzomib). He had diagnostic coronary angiography (CAG) in 2012 and it showed chronic total occlusion (CTO) of the right coronary artery (RCA) with retrograde filling via collaterals from left anterior descending coronary artery (LAD), non-obstructive coronary lesions of LAD, critical coronary artery stenosis of left circumflex (LCx) coronary artery and obtuse marginal-1 (OM-1) coronary artery. Drug-eluting stents placed into his LCx and OM-1 artery. His second CAG after non-ST-segment elevation myocardial infarction in 2017 revealed patent LCx and OM-1 coronary stents. His medical therapy included aspirin 100 mg, clopidogrel 75 mg, atorvastatin 40 mg, valsartan 80 mg and metoprolol 25 mg twice daily. On admission, physical examination was unremarkable and electrocardiography (ECG) showed normal sinus rhythm with ST-segment depression and T-wave inversion in inferior and anterior precordial leads during anginal episode (**Figure 1**). Baseline and follow-up cardiac troponin-I levels were within normal range. His chest pain and shortness of breath resolved after treatment with intravenous nitroglycerin and nifedipine and ECG showed normal sinus rhythm without ST-segment depression or T-wave inversion (**Figure 2**). Echocardiography showed normal left ventricular systolic function. We performed CAG due to dynamic ECG changes and it revealed similar findings with previous CAG as patent LCx and OM stents with non-obstructive coronary lesions of LAD and CTO of RCA with retrograde filling via collaterals from LAD. After CAG, we speculated that the possible causes of dynamic ECG changes and chest pain were prolonged coronary vasospasm and/or endothelial dysfunction induced by carfilzomib. After ACS, treatment dose of carfilzomib for RRMM reduced with the decision of cardio-oncology council and patient discharged from hospital with dual antiplatelet, atorvastatin, valsartan, metoprolol, nifedipine and isosorbide mononitrate therapy.

Conclusion: Here, we reported a case of vasospastic ischemia after use of carfilzomib in a patient with past history of coronary artery disease. Vasospastic ischemia is one of the multiple cardiovascular toxicities associated with different antineoplastic drugs in patients with cancer. Patients with coronary artery disease were particularly vulnerable to this kind of cardiotoxicity. Carfilzomib use in patients with preexisting coronary artery disease must be extremely cautious, justified by the benefit to cancer outcomes and absence of alternative oncological treatments, and with close surveillance and cardiac monitoring.



ID: 465

Topic: **Cardiology » Acute Coronary Syndromes**

Presentation Type: **Oral**

TRAUMATIC CORONARY ARTERY DISSECTION IN A YOUNG MAN AFTER A ROAD ACCIDENT

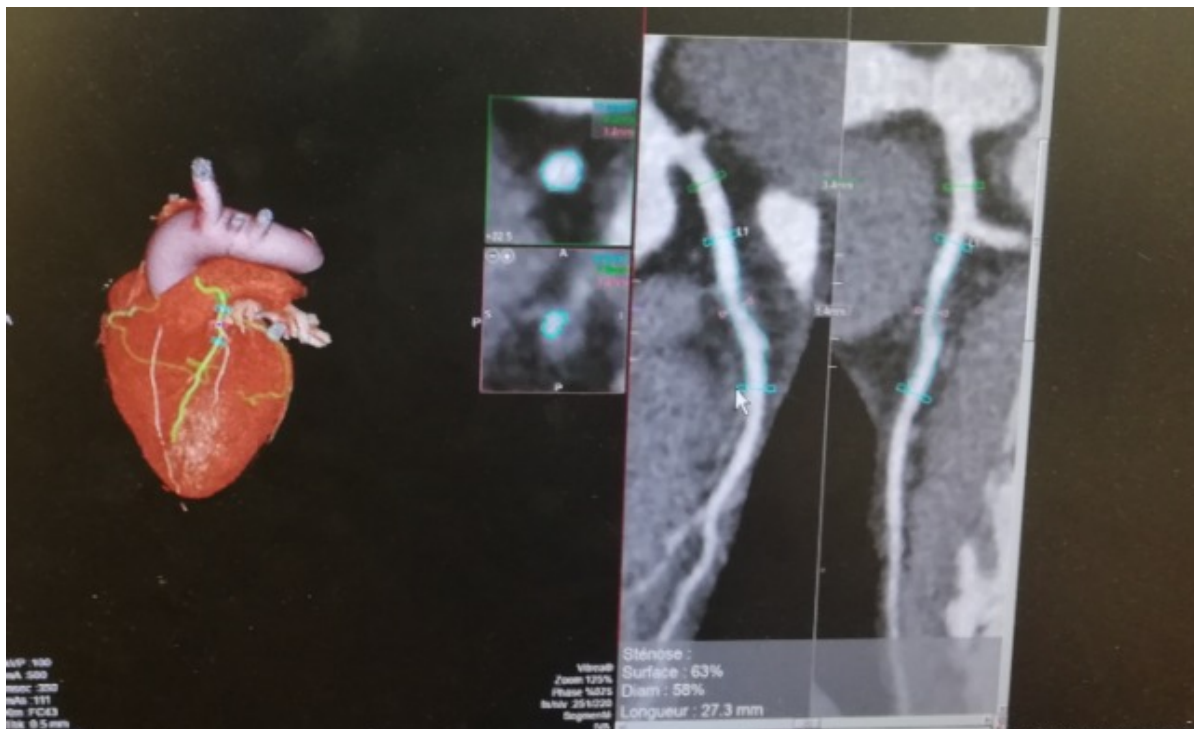
Zakaria Raiss, Badre El Boussaadani, Amine Qat Amine

Centre Hospitalier Sud Francilien, Evry, France

**Corresponding Author (raisszakaria@gmail.com)*

raisszakaria@gmail.com, badreelboussaadani1989@gmail.com, badreelboussaadani1989@gmail.com

Abstract Text



Introduction: artery dissection after blunt chest trauma is a rare, life-threatening condition.

Objectives: To present a case of coronary artery dissection after blunt chest trauma and to outline the appropriate management of this condition based on a literature review.

Case Report: We report the case of a 42-year-old man , a road accident victim initially admitted in the emergency department , an injury assessment has shown a non-displaced fracture of the second cervical spine, a cerebellar ischemic stroke with haemorrhagic transformation without sensory motor deficits and pulmonary contusion. the biological assessment showed a significant increase in troponin and CPK without any notion of chest pain or hemodynamic instability. A 12-lead electrocardiogram on arrival demonstrated just a sinus tachycardia . The assessment was completed by a trans-thoracic echocardiography which showed hypokinesia of the anterolateral septum with conserved left ventricular function (55% LVEF). it was decided to perform a non-invasive imaging such as CT Coronary Angiogram , which demonstrated dissection with hematoma of the left anterior descending artery in its proximal part associated with an estimated intermediate stenosis of 50 to 70% on about 6 mm fusiform aspect, the rest of the coronary network was non-calcified. Moreover, there was no dissection of the thoracic aorta.

The patient has received a medical treatment (beta-blocker and vasodilator) without antiplatelet agent, especially since there was a haemorrhagic transformation of his stroke. The patient remained hemodynamically stable. A control CT is performed one month after the accident, which showed a permeability of the proximal interventricular artery and disappearance of the hematoma.

Conclusion: Early recognition of this clinical entity with a screening electrocardiogram, and aggressive management, may result in a favorable outcome. A literature review reveals that coronary artery bypass grafting, angiography with stent placement, and conservative management may all be considered viable treatment options for this condition

ID: 574

Topic: **Cardiology » Preventive Cardiology**Presentation Type: **Poster****THE EFFECT OF ANTHRACYCLINE CHEMOTHERAPY ON ARTERIAL STIFFNESS****Oguzhan Ekrem Turan***Karadeniz Technical University, Trabzon, Turkey***Corresponding Author (oguzhanekrem@gmail.com)**oguzhanekrem@gmail.com***Abstract Text**

OBJECTIVE: Anthracycline chemotherapy can cause early and late term cardiovascular disease. Patients, who is diagnosed Non-Hodgkin's lymphoma (NHL) disease and planning to receive anthracycline chemotherapy, investigate the changes in arterial stiffness between anthracycline chemotherapy cycle.

METHODS: We included ten patients in our study who is diagnosed Non-Hodgkin's lymphoma (NHL) disease and recieved anthracyclin chemothreaphy. Patients arterial stiffness parameters were measured by SpygmoCor applanation tonometer device (Artcore, Sydney, Australia) before , for the first match and after six cycle chemotherapy within 24 hours. Arterial stiffness parameters evaluated with aortic pulse wave velocity (PWV), augmentation index (Alx@75) and subendocardial viability ratio (SEVR). Echocardiography was performed all patients at baseline and after six cycle of chemotherapy.

RESULTS: At the end of anthracycline chemotherapy left ventricular end systolic diameter (LVESD) (26.9 ± 3.3 ve 29 ± 2.5 , $p=0.01$) significantly increased and left ventricular ejection fraction (LVEF) (65.5 ± 4.8 ve 62.8 ± 3.9 , $p=0.01$) significantly decreased. Compared to baseline anthracycline chemotherapy had an increased effect of PWV value. ($p = 0.053$) Alx@75 values changing were not significant ($p=0.76$). Also Anthracycline chemotherapy effected SEVR values but had a trend toward significance ($p = 0.058$)

CONCLUSION: Our results revealed that anthracycline chemotherapy increased the PWV values slightly. Increased PWV may be responsible for early and late term developing cardiovascular events.

Not measured

	At Baseline	After 1 cycle Chemotherapy	After 6 cycle Chemotherapy
LVESD (mm)	26.9±3.3	29±2.5*	
LVEF %	65.5±4.8	62.8±3.9*	
PWV (m/s)	9.08±1.9	10.31±2.9*	9.64±2.1+
Alx@75 (%)	18.8±11.9	22.7±13.9	17.5±13.4
SEVR (%)	151.6±33.1	130.6±32.5	124.3±31.9†
Heart rate (bpm)	69.3±11.5	72.8±12.9	77.7±9.4

*,† A p value less than 0.05 accepted significance for previous box

Oral Presentations

Emidemiology, Risks and Prevention of Cardiovascular Diseases

Date: 29.03.2019 Time: 14:45 - 16:15 Hall: 5

ID: 543

Topic: Cardiology » Preventive Cardiology

Presentation Type: Oral

ASSOCIATION OF MEAN PLATELET VOLUME AND MONOCYTE / HDL RATIO WITH MYOCARDIAL BRIDGING

Ekrem Aksu, Akif Serhat Balcıoğlu, Abdullah Sökmen, Gülizar Sökmen, **Mehmet Kirişçi**

Kahramanmaras Sutcuimam University Faculty Of Medicine, Kahramanmaras, Turkey

**Corresponding Author (drekrema^{ksu}4676@gmail.com)*

drekrema^{ksu}4676@gmail.com, serhatbalcioglu@gmail.com, abduallah27@yahoo.com, guliz58@yahoo.com, drkirisci@yahoo.com

Abstract Text

Background: Increased mean platelet volume (MPV) and monocyte/HDL ratio (MHR) has been reported to be the markers of inflammation which plays a major role in the development of atherosclerosis. Although myocardial bridging is a congenital benign disease, previous studies have shown that the risk of atherosclerosis increases in segments proximal to myocardial bridging. In this study, we aimed to investigate MPV and MHR in patients with myocardial bridging.

Method: Patients undergoing coronary angiography between January 2014 and December 2017 were evaluated retrospectively. Study group included the patients diagnosed as myocardial bridging without any evidence of coronary atherosclerosis and control group included the patients with normal coronary arteries. MPV and MHR were calculated from biochemical and hematological parameters based on the results of pre-angiographic blood analysis, and obtained values were compared between two groups.

Results: Study group was composed of 54 patients (mean age 56.8 ± 11.4 years, 74.1% male) with myocardial bridging and control group was composed of 62 patients (mean age: 55.5 ± 12.8 years, 58.1% male) with normal coronary vascularity. Baseline characteristics of both groups were similar. Median (interquartile range 25/75) MPV was significantly lower [9.7 (8.5/10.5) vs. 10.7 (10/11.2), $p < 0.001$] and median (interquartile range 25/75) MHR was significantly higher [16.7 (11.5/23.7) vs. 12.1 (10.2/17.3), $p = 0.011$] in the study group as compared to the control group (Table 1).

Conclusion: Previous studies demonstrated significant relationship between elevated MPV and MHR that might partly explain increased cardiovascular events in patients with myocardial bridging. In this study, myocardial bridging was found to be associated with increased MHR, but not MPV. These conflicting results require clarification. Further studies are needed to claim the relationship between these markers and cardiovascular events in this group of patients.

Table 1: Baseline Characteristics and Laboratory Findings of the Study Population

	Myocardial bridge (+)n=54	Myocardial bridge (-) n=62	P value
Age, years	56.8 ±11.4	55.5±12.8	0.572
Male gender, numbers (%)	40(74.1)	36(58.1)	0.070
Total cholesterol, mg/dL*	169.5 (150.5/203.75)	180.5 (148.5/204)	0.528
HDL-cholesterol, mg/dL*	37 (32.75/42)	41 (35/52.25)	0.006
LDL-cholesterol, mg/dL*	108.5 (84.5/141.75)	114 (90.75/134.5)	0.644
Triglycerides, mg/dL*	169.5 (103/240)	128 (106/175.25)	0.044
WBC, x1000/mL*	7.8 (7/9)	7.4 (6.6/9.3)	0.475
Neutrophils, x1000/mL*	4.3 (3.8/5.6)	4.5 (3.8/5.9)	0.748
Monocytes, x1000/mL*	0.58 (0.49/0.8)	0.56 (0.45/0.74)	0.314
Lymphocytes, x1000/mL*	2.2 (1.7/2.4)	2.2 (1.8/2.6)	0.498
Platelets, x1000/mL	230±52.2	238.8±63	0.417
Mean platelet volume, fL*	9.7 (8.5/10.5)	10.7 (10/11.2)	<0.001
Monocyte/HDL-cholesterol ratio*	16.7 (11.5/23.7)	12.1 (10.2/17.3)	0.011

*Data presented as median (interquartile range 25/75). HDL= High-density lipoprotein, LDL=Low-density lipoprotein, WBC=White blood cells

ID: 90

Topic: **Cardiovascular Surgery » Risk Management in Cardiovascular Diseases**

Presentation Type: **Oral**

RRELATION BETWEEN CORONARY ARTERY CALCIUM SCORE AND SERUM TENASCIN-C LEVEL IN PATIENTS WITHOUT KNOWN CORONARY ARTERY DISEASE

Pınar Ozmen Yildiz¹, Ibrahim Yildiz¹, **Caglar Ozmen**², Mustafa Karabacak³, Oben Doven⁴

¹*Osmaniye State Hospital, Osmaniye, Turkey*

²*Cukurova University, Adana, Turkey*

³*Suleyman Demirel University, Isparta, Turkey*

⁴*Mersin University, Mersin, Turkey*

*Corresponding Author (pinarozm@hotmail.com)

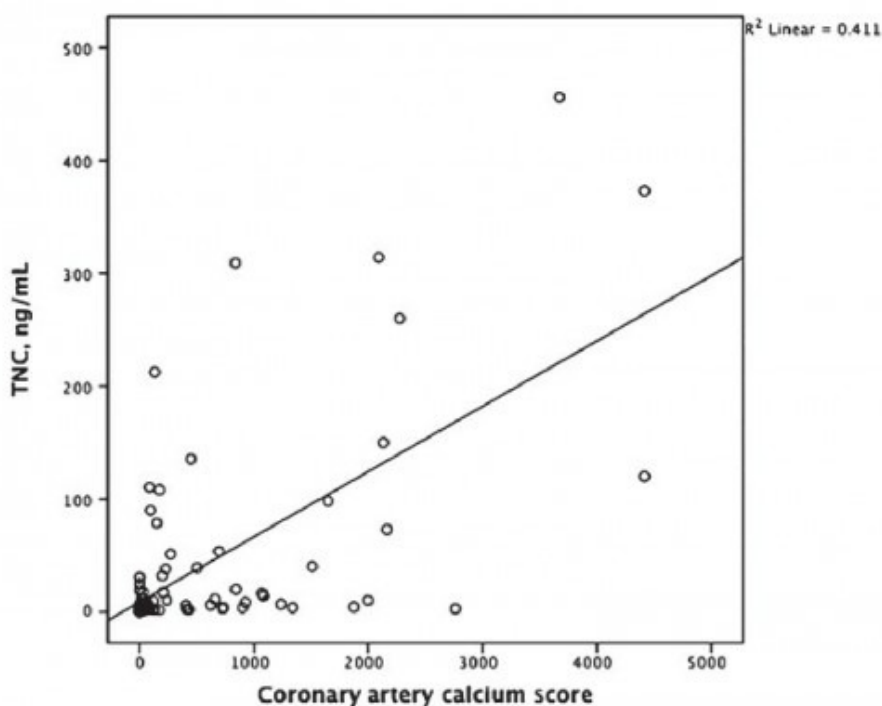
pinarozm@hotmail.com, ibrahimyildiz79@yahoo.com, caglarozm@hotmail.com,
mustafakarabacak@sdu.edu.tr, obendoven@mersin.edu.tr

Abstract Text

Objective: Presence of coronary artery disease (CAD) also in subjects without traditional risk factors leads to a search for new risk factors. Tenascin-C (TNC), an extracellular matrix glycoprotein is normally found in very low concentrations in tissues and serum of adults, whereas its expression is enhanced in case of pathological conditions accompanied by inflammation. This study aimed to investigate the relation between coronary artery calcium score (CACS) and serum TNC level.

Methods: Ninety patients (age range, 18-75 years) presenting with chest pain but without known CAD were divided according to their CACSs as control (CACS = 0, n = 30), low CACS (CACS between 0 and 400, n = 30), and high CACS (CACS \geq 400, n = 30) groups. The patients were questioned about risk factors and underwent laboratory analyses for biochemical parameters including TNC.

Results: The mean TNC level was significantly higher in the high CACS group as compared to both the low CACS group and the control group [4.7 (0.03-30.7), 28 (0.7-212) and 84 (2-456) ng/mL, respectively; $P < 0.01$]. A positive correlation was determined between serum TNC level and CACS ($r = 0.641$, $P < 0.001$). In the ROC curve analysis, when the cut-off value for TNC was accepted as 8.09 ng/mL, the sensitivity and specificity in detecting patients with CACS > 100 (moderate or significant calcification) were 72% and 82%, respectively. **Conclusion** A significant relationship was found between CACS and serum TNC level. Thus, measurement of TNC level can be used in determining elevated CACS and thereby the risk for CAD.



ID: 74

Topic: **Cardiology » Preventive Cardiology**Presentation Type: **Oral****RELATIONSHIP BETWEEN ATHEROSCLEROTIC RISK FACTORS AND INTERNAL CAROTID ARTERY STENOSIS SEVERITY IN PATIENTS WITH NON-ARYTHMIC AND NON-VALVULER ISCHEMIC STROKE**Ruhan Karahan Özcan, **Tahir Bezgin***Gebze Fatih State Hospital, Kocaeli, Turkey***Corresponding Author (karahanruhan@yahoo.com)**karahanruhan@yahoo.com, bezgintahir3@yahoo.com***Abstract Text**

Aim: To investigate the relationship between common atherosclerotic risk factors and the severity of internal carotid artery stenosis in an ischemic stroke patient cohort.

Methods: A total of 215 patients diagnosed with ischemic stroke and admitted to the Neurology Clinic of Taksim Training and Research Hospital were included in this retrospective study. Patients were investigated via Doppler ultrasonography, and divided into 3 groups by the grade of the stenosis in extracranial internal carotid arteries. Patients with a carotid artery stenosis between 0% and 29%, 30% and 69%, and $\geq 70\%$ were considered as group A, B and C, respectively. Hypertension, presence of diabetes mellitus, hyperlipidemia, smoking, ischemic cardiac disease, age and gender were assessed.

Results: Serum LDL level was higher in the Group B relative to the Group A, and in the Group C relative to Groups A and B with statistical significance (105.24 ± 33.27 ; 139.61 ± 25.22 ; 167.41 ± 24.9 , respectively, $p < 0.01$). Carotid artery stenosis was less common among women compared to men in the Group B and Group C, relative to the Group A; and there was a statistically significant correlation between the grade of stenosis and gender ($p < 0.02$). No statistically significant difference was observed in age, hypertension, diabetes, smoking and the presence of ischemic cardiac disease between the groups.

Conclusion: Male patients with increased LDL levels were found to have a greater degree of internal carotid artery stenosis. These findings indicate that male subjects with higher LDL levels need a more aggressive risk factor modification.

ID: 105

Topic: Cardiology » Preventive Cardiology

Presentation Type: Oral

NEUTROPHIL GELATINASE-ASSOCIATED LIPOCALIN AS EARLY PREDICTIVE BIOMARKERS IN CONTRAST-INDUCED NEPHROPATHY AFTER CORONARY ANGIOGRAPHY

Alparslan Kılıç

Koç Üniveristesi, İstanbul, Turkey

**Corresponding Author (alkilic@kuh.ku.edu.tr)*

alkilic@kuh.ku.edu.tr

Abstract Text

Neutrophil gelatinase-associated Lipocalin As Early Predictive Biomarkers In Contrast-induced Nephropathy After Coronary Angiography

Objective: Coronary artery disease (CAD) is the most common form of heart disease and is a leading cause of death worldwide. Coronary angiography (CAG) is the gold standard in the diagnosis of CAD. Contrast induced nephropaty (CIN) is a severe and important health problem. Neutrophil gelatinase-associated lipocalin (NGAL) is an early biomarker for renal impairment. The value of ischemia modified albumin (IMA) was highlighted as a biomarker for the detection of acute ischemia. We tested the hypothesis whether NGAL and IMA could serve as early biomarkers of CIN in patients with normal serum creatinine values who undergo CAG.

Methods: This study was conducted in 78 patients undergoing elective CAG. Urinary NGAL and serum IMA values measured before and 6th hours after CAG, and creatinine values measured prior to and 48th hours after CAG were compared. Urinary NGAL was assessed by the Abbott Architect i2000 (Abbott INC., USA) device with chemiluminescent microparticle immunoassay tests. Serum IMA level was assessed spectrophotometrically by the Humalayz 2000 (HUMAN INC, Germany). Data analysis was performed in PASW statistics program version 18.

Results: IMA and NGAL values obtained 6 hours after CAG differed significantly from those obtained at baseline. According to Wilcoxon test, statistically significant differences were found between the baseline and 6th hour values of urinary NGAL and serum IMA values ($p < 0.001$). There was no significant difference between baseline and 48th hours serum creatinine levels ($p = 0.081$). In addition, a statistically significant positive correlation was found between pre-processing and 6 th hours NGAL and IMA levels, ($r = 0.277$, $p = 0.014$; $r = 0.407$ and $p < 0.001$, respectively). Forty-eighth-hour serum creatinine values and volume of contrast material revealed a statistically significant positive correlation ($r = 0.264$, $p = 0.019$). Due to lack of CIN cases in our study, we could not evaluate this issue further.

Conclusions: An increase in urinary NGAL and serum IMA levels were detected without an increase in serum creatinine values which is routinely used in determining the CIN. When compared to serum creatinine, urinary NGAL and serum IMA may be an early and sensitive biomarker for predicting CIN. Large scale prospective studies are needed to obtain further information about this issue.

Evaluation of Nephrotoxicity Markers with Wilcoxon Test	P
6.hours İMA -0.hours İMA	<0.001
6.hours NGAL -0.hours NGAL	<0.001
48. hours creatinine mg/dl - 0. hours creatinine mg/dl	0.081
6. hours Urine creatinine mg/dl - 0. hours Urine creatinine mg/dl	<0.001
48. hours Urine creatinine mg/dl – 0. hours Urine creatinine mg/dl	<0.001
48.saat Bun mg/dl – 0.saat Bun mg/dl	<0.001

ID: 130

Topic: **Cardiology » Preventive Cardiology**Presentation Type: **Oral****WHOLE BLOOD VISCOSITY IN MICROVASCULAR ANGINA AND CORONARY ARTERY DISEASE: SIGNIFICANCE AND FEASIBILITY****Elif Ijlal Cekirdekci***Dr. Suat Gonsel University of Kyrenia Hospital, Kyrenia, Turkish Republic of Northern Cyprus***Corresponding Author (elifcekirdekci@hotmail.com)**elifcekirdekci@hotmail.com***Abstract Text**

Objectives: The aim of this study is to compare Whole blood viscosity (WBV) levels in patients with microvascular angina (MVA), coronary artery disease (CAD) and normal population and to identify the relationship between WBV and inflammation markers in patients.

Methods: 573 patients were enrolled into the current study. The MVA group consisted of 189 subjects, the CAD group consisted of 203 subjects, and the control group consisted of 181 age and sex-matched individuals. WBV was calculated from hematocrit and plasma protein concentration at low shear rate (LSR) (0.5 s⁻¹) and high shear rate (HSR) (208 s⁻¹) by a validated equation.

Results: CAD and MVA patients had significantly higher WBV for LSR and HSR when compared to control group. Correlation analysis revealed a significant relationship between the hsCRP and WBV for LSR ($r = 0.556$; $p < 0.001$) and HSR ($r = 0.562$) in CAD group and LSR ($r = 0.475$) and HSR ($r = 0.493$) in MVA group.

Conclusions: Overall, the key strengths of this study to demonstrate a significant and independent association between simple evaluation of blood viscosity and the existence of endothelial inflammation and atherosclerotic process.

Keywords: Coronary Artery Disease, Microvascular angina, Whole blood viscosity

Table 1. Comparison of WBV parameters of the study groups

Variables	Control Group	MVA	CAD	P value
WBV at HSR, 208 s ⁻¹	15.1 ± 1.6	18.3 ± 2.8	21 ± 4.5	<0.001
WBV at LSR, 0,5 s ⁻¹	37.4 ± 14	62.4 ± 18	72.1 ± 27	<0.001

CAD = Coronary artery disease; HSR = High shear rate; LSR = Low shear rate; MVA = Microvascular angina; WBV = Whole blood viscosity.

ID: 155

Topic: **Cardiology » Preventive Cardiology**Presentation Type: **Oral****ASSOCIATION BETWEEN SUBCLINICAL HYPOTHYROIDISM AND
CORONARY ARTERY DISEASE****Belma Yaman¹**, Levent Cerit¹, Aziz Günsel¹, Songül Usalp¹, Ümit Yüksek¹, Ilker Gül², Ilker Etikan¹, Hamza Duygu¹¹Near East Faculty of Medicine, Nicosia, Cyprus²Torbali State Hospital, izmir, Turkey^{*}Corresponding Author (belmayaman@yahoo.com)*belmayaman@yahoo.com, drcerit@hotmail.com, aziz.gunsel@med.neu.edu.tr, dr.songulusalp@hotmail.com, uyuksekk@yahoo.com, drilkerkul@gmail.com, ilker.etikan@neu.edu.tr, hamzakard@yahoo.com***Abstract Text**

Objective: Coronary artery disease (CAD) is a common health problem with high morbidity and mortality. In recent years overt hypothyroidism is shown as an independent risk factor of CAD. Also subclinical hypothyroidism (SCH) is associated with endothelial dysfunction, coronary atherosclerosis, and cerebrovascular disease with the similar mechanism of overt hypothyroidism. In this study we aim to evaluate the association between SCH and coronary artery disease severity with Syntax score.

Methods: This study is a retrospective cohort of participants who undergo coronary angiography and resulted in coronary artery bypass graft surgery. Participants divided into two group according to their Syntax score as high Syntax score (Syntax \geq 23) and low Syntax score (Syntax < 23). Thyroid stimulating hormone (TSH), free thyroxine (fT4), free triiodothyronine (fT3) were assayed in blood samples after 12h overnight fasting. We defined SCH as elevated serum TSH level (TSH \geq 4 IU/L) with normal levels of fT3 and fT4. Patients were divided into two group according to their TSH levels as SCH (fT3 and fT4 normal, TSH \geq 3) or not.

Results: There is no statistically significant difference between two Syntax groups regarding age, male, height, weight, smoking, hypertension, diabetes mellitus, hyperlipidemia, peripheral artery disease, total cholesterol, HDL-C, LDL-C, TG, fT4, fT3, TSH, vitamin B12, vitamin D, and uric acid. Serum LDL, total cholesterol levels are significantly higher in the SCH group than non-SCH group (respectively; $p=0.029$, $p=0.024$). There is a positive correlation between SCH and age, SCH prevalence increase with older age ($p=0.017$).

Conclusion: We aimed to evaluate the association between SCH and coronary artery disease severity with Syntax score however, there is no significant correlation. Further studies are needed to evaluate the association between SCH and CAD.

ID: 178

Topic: **Cardiology » Preventive Cardiology**Presentation Type: **Oral****EVALUATION OF THE KNOWLEDGE OF PATIENTS ABOUT THE MANAGEMENT OF THEIR TREATMENT WITH VITAMIN K ANTAGONIST DRUGS: PROSPECTIVE STUDY ABOUT 100 PATIENTS.****Maryam Mouadili**, Cyriaque Mbauchy, Mariame Chakir*Centre Hospitalier Universitaire Mohammed VI, Marrakech, Marrakech, Morocco***Corresponding Author (maryam.mouadili@gmail.com)**maryam.mouadili@gmail.com, cyrmbauchy@hotmail.com, mariamechakir@hotmail.com***Abstract Text**

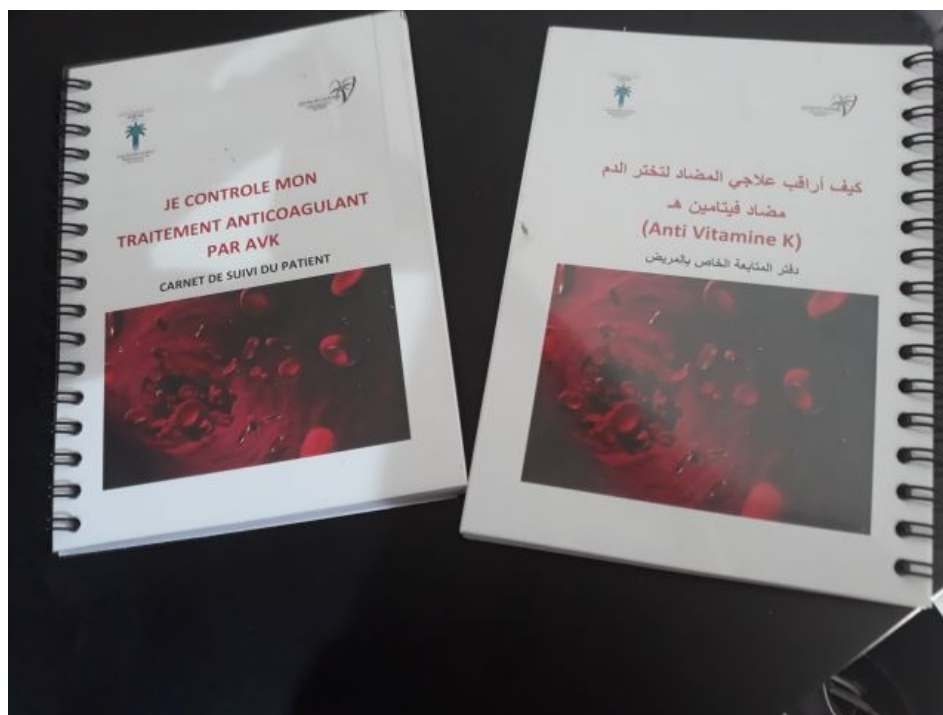Introduction: vitamin K Antagonists (VKA), the most widely prescribed oral anticoagulant treatment, has a significant iatrogenic risk, often secondary to insufficient information from patients regarding the management of their treatment

Methods: this was a descriptive cross-sectional survey conducted at our Medical Center. A questionnaire (19 items) was administered to patients who had recently been on VKA (for at least one week) on three short assessment visits at approximately one month interval between each.

We evaluated their initial level of knowledge then we followed the evolution of their knowledge through three assessment sessions (during this period all patients received their care normally from their attending physician).

Duration of the study was 29 months (recruitment and monitoring of patients) - from January 2015 to May 2017.

Results: One hundred patients were included in the study (47 men/53 women). The average age was 38 ± 16 years old. Valvular diseases and venous thromboembolism justifying the institution of VKA treatment were found in 35% and 27% of cases, respectively. Thirty-nine percent of patients reported that they did not received information about their treatment. The names of the VKA and the exact reason for the treatment were known in 25% and 30% of cases respectively at the first consultation. Thirty-six patients cited INR as a laboratory-based monitoring of treatment and only 28 patients were aware of the target values. The majority of patients were unaware of the risks of overdose (60%) and underdosing (52%). Nonsteroidal anti-inflammatory drug self-medication was reported by 26 patients. A positive evolution of knowledge at the end of the study was noted in only 58 patients, but with an average score not exceeding $09 (+/- 2) / 19$ items. **Conclusion:** Patients' knowledge of VKA management was fragmentary and insufficient to ensure safe and effective treatment. At the end of this study we created a booklet of information and monitoring of patients under VKA in two languages (French and Arabic).



ID: 122

Topic: **Cardiology » Preventive Cardiology**Presentation Type: **Oral**

THE IMPACT OF HOSPITAL-BASED CARDIAC REHABILITATION ON INFLAMMATORY MARKERS AFTER CORONARY ARTERY BYPASS GRAFTING SURGERY

Hicaz Zencirkiran Agus

Istanbul Sağlık Bilimleri Üni. Mehmet Akif Ersoy Kalp ve Damar Cerrahisi Hastanesi, Istanbul, Turkey

**Corresponding Author (hicazincir@yahoo.com)*

hicazincir@yahoo.com

Abstract Text

OBJECTIVE: The main aim of this study was to investigate the inflammatory markers like platelet to lymphocyte (PLR), monocyte to high density lipoprotein (MHR) and neutrophil to lymphocyte ratio (NLR) before and after cardiac rehabilitation (CR) programme after coronary artery bypass grafting (CABG) surgery. Inflammatory markers are known as a predictor of major adverse cardiovascular outcomes.

METHODS: We evaluated records of 75 patients who underwent CABG operation and attended CR between January 2016 and December 2017 retrospectively. Exclusion criteria included: hematological proliferative diseases, active or chronic inflammatory or autoimmune diseases, steroid therapy, concomitant valve surgery. Twenty one patients were excluded from the study: 12 patients with concomitant valve surgery, 9 patients with inflammatory disease. PLR, NLR, MHR, RDW (red cell distribution width), MPV (mean platelet volume) were calculated, obtained from the blood samples that were taken 2 months after CABG surgery, before CR and compared with the blood samples taken after CR programme. CR lasted for 24±4 days.

RESULTS: Patients' mean age was $60,7 \pm 8,7$ years and %25.9 were women. After the onset of cardiac rehabilitation, there was a significant decrease in NLR ($2,85 \pm 1,15$ to $2,38 \pm 1,39$ $p=0,004$) and PLR ($152,95$ ($44,42-394,25$) to $105,36$ ($48,37-258,44$) $p<0,001$). Bazal LDL level was 98 ($39-195$) mg/dl. The median EF was %60. RDW and MPV didn't change significantly after CR.

CONCLUSION: This study showed decreased inflammatory markers in coronary artery disease patients participated CR after CABG. Due to reducing inflammatory process; CR decrease morbidity and mortality.

	Before	After	p
Neutrophil/Lymphocyte	$2,85 \pm 1,15$	$2,38 \pm 1,39$	0,004*
Platelet/Lymphocyte	$152,95$ ($44,42-394,25$)	$105,36$ ($48,37-258,44$)	<0,001*
Monocyte/HDL	$0,0177$ ($0-0,04$)	$0,0163$ ($0,01-0,04$)	$0,396$
RDW	$13,54 \pm 1,41$	$13,7 \pm 1,60$	$0,471$
Lymphocyte/Monocyte	$3,40 \pm 1,49$	$3,75 \pm 1,42$	$0,082$
MPV	$9,91 \pm 1,26$	$10,17 \pm 1,50$	$0,172$

ID: 451

Topic: Cardiovascular Surgery » Various Veins

Presentation Type: Oral

THE PAINKILLER NEEDS AFTER PROCEDURE IN PATIENS WITH VENOUS FAILURE TREATED WITH RADIOFREKANS AND CYANOACRYLATE GLUE

Mehmet Kirişci

Kahramanmaraş Sutcu Imam University, Kahramanmaraş, Turkey

**Corresponding Author (drkirisci@yahoo.com)*

drkirisci@yahoo.com

Abstract Text

Objectives: The aim of this retrospective study was to compare the pain relief needs of patients treated with radiofrequency and n-butyl-2 cyanoacrylate glue (Venablock) with venous insufficiency.

Methods: Frequency of painkiller usage of fifty patients who underwent radiofrequency between 2016 and 2018 and fifty patients who underwent n-butyl-2 cyanoacrylate glue (Venablock) within first 5 days after intervention. Paracetamol 500 mg was given as the painkiller. At the end of 5 days, they were asked how much pain medication he was using.

Results: Radiofrequency patients were consisted of 32 females and 18 males. Glue applied patients were 35 females and 15 males. Radiofrequency patients, 40 people need to take painkillers on the day treatment, he said. In the first 5 days, 22 patients had painkiller on the first day and 7 patients had painkillers on the fifth day. Glue applied 16 patients needed painkiller on the first day and 4 patients needed painkillers in the first five days.

Conclusions: In the treatment of venous insufficiency, radiofrequency and glue treatment is a more comfortable treatment compared to open surgery for patients. saphenous vein ablation is done in both methods. In our study, it was observed that patients who had radiofrequency had more painkiller during the first five days after the procedure.

Oral Presentations

The Pearls for the Management of Acute Coronary Syndrome

Date: 29.03.2019 Time: 16:30 - 18:00 Hall: 5

ID: 436

Topic: **Cardiology » Preventive Cardiology**

Presentation Type: **Oral**

THE CLINICAL EVALUATION OF MORNING-NIGHT VARIATION IN THE PATIENTS WITH ACUTE ST ELEVATION MYOCARDIAL INFARCTION

Ersin Saricam

Medicana Ankara Hospital, Ankara, Turkey

**Corresponding Author (saricamersin@yahoo.com)*

saricamersin@yahoo.com

Abstract Text

Objective: A number of factors may interference with circadian rhythm and trigger acute myocardial infarction. In the morning, while sympathetic activity and platelet aggregability increase, plasma fibrinolytic activity decreases. These changes lead to mismatches between myocardial oxygen supply and demand in the morning. However, at present, accepted these theories has not enough in the young patients with acute myocardial infarction. Because the lifestyles have recently significantly changed, including the rise in obesity, more sedentary life. Therefore, we have evaluated day-night acute myocardial infarction cases according to the onset time of chest pain.

Methods: From March 2017 to December 2018, we prospectively randomized examined 115 patients admitted for acute ST-elevation acute myocardial infarction in the intensive care unit (ICU). The patients divided into two groups according to the onset time of chest pain. The group 1 (60 patients) was daytime group (between 06.00 AM-21.00PM), while the group 2 (55 patients) was night group (21.00PM-06.00 AM). The demographic data, clinical histories, smoking, atherosclerosis risk factors, and laboratory and angiographic findings of all the patients were collected. In addition these, the evidence of obstructive sleep apnea evidence, anxiety examination, and physical activity score were examined.

Results: Compare to night group and daytime group, sleep apnea evidence, anxiety evidence were important statistically in night group ($p<0.001$). This condition was prominently in young persons. Both groups physically inactive were similar according to IPAQ (Table). **Conclusion:** In addition to classically the factors disrupting circadian rhythm, obstructive sleep apnea, anxiety evidence are associated with especially night acute myocardial infarction.

	Daytime Acute myocardial infarction	Night Acute myocardial infarction	P	
Sleep apnea evidence	5.6%	94.4%	0.0001	
Activity score	55.7%	44.3%	0.82	
Anxiety score	3.57%	10.93%	0.0001	

ID: 342

Topic: Cardiology » Percutaneous Coronary Interventions in Acute Coronary SyndromesPresentation Type: **Oral****THE EFFECT OF SMOKING ON CLINICAL ENDPOINTS AFTER ACUTE ST ELEVATION MYOCARDIAL INFARCTION IN SMALL VESSEL CORONARY LESIONS****Kahraman Cosansu, Harun Kilic***Sakarya University, Education and Research Hospital, Sakarya, Turkey***Corresponding Author (kahraman141@gmail.com)**kahraman141@gmail.com, harunkilic@sakarya.edu.tr***Abstract Text****Background**

Cigarette smoking is one of the major classical risk factor for atherosclerosis and cardiovascular disease including acute myocardial infarction. The aim of this study was to clarify how prior smoking status may affect long-term clinical outcomes following angioplasty with the Everolimus Eluting Stent(EES) in the treatment of lesions in STEMI patients with small vessel coronary artery disease.

Methods

We included 286 patients who underwent primary angioplasty for treating coronary lesions with EESs in small vessels (reference diameter ≤ 2.5 mm). The patients were divided into two groups based on their cigarette smoking status (non-smokers, n: 146 and current or previous smokers, n: 140). The primary endpoint was the MACE rate at 24-month: a composite of target vessel revascularization(TVR), myocardial infarction(MI), stent thrombosis(ST) and target lesion revascularization(TLR). The secondary endpoint was the in-hospital death rates.

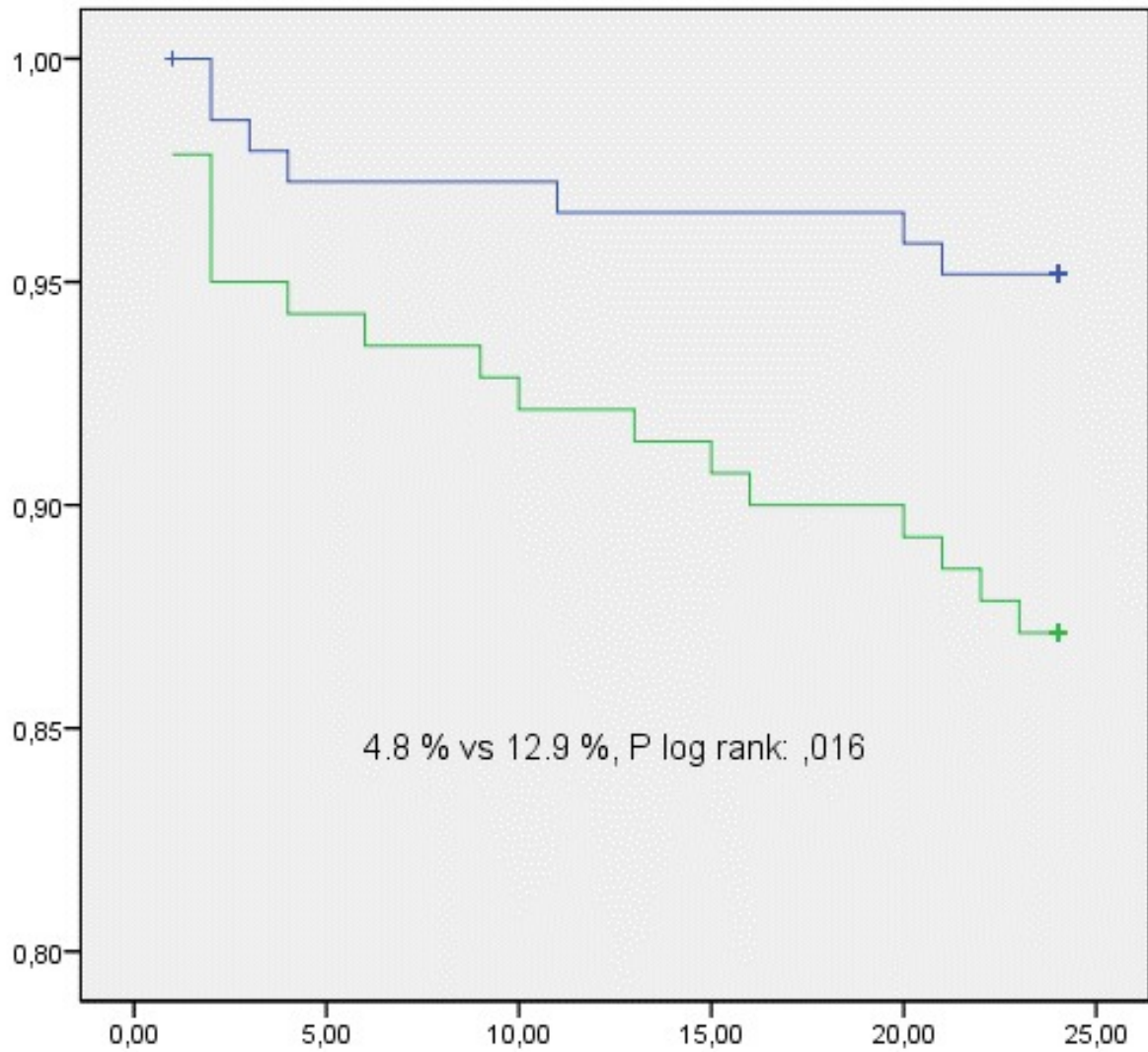
Results

At 2 years, MACEs occurred in 4.8% in the non-smokers group and 12.9% in the smokers group ($p=.01$). The rates of TVR(2.1% vs 7.1%, $p=.03$), TLR(2.1% vs 7.1%, $p=.03$) and MI(4.1% vs 11.4%, $p=.02$) in the non-smokers group was significantly lower than that in the smokers group. The rates of ST was not significantly different((2.1% vs 4.3%) , $p>.05$). The time-to-event curves reflected a higher incidence of MACE (P log rank = .016) rates in the smoker patients group (Figure 1). In a Cox analysis, the adjusted hazard ratios (HRs) for MACEs (HR: 0.51, 95% confidence interval [CI] 0.15-0.86; $p=0.01$) was significantly lower in the non-smoker group than in the smoker group. The in-hospital death rate was 8.8 % in the smokers group and 2.8 % in the non-smokers group ($p=.03$).

Discussion

We report for the first time that cigarette smoking increases the risk for MACEs after primary percutaneous coronary intervention for STEMI in small vessel coronary artery disease treated with EESs.

Freedom from MACE at 24 months



ID: 301

Topic: **Cardiology » Percutaneous Coronary Interventions in Acute Coronary Syndromes**

Presentation Type: **Oral**

THE RELATIONSHIP BETWEEN ADMISSION HBA1C LEVEL AND INFARCT-RELATED ARTERY PATENCY IN ST ELEVATION MYOCARDIAL INFARCTION PATIENTS

Muhammet Cihat Çelik, **Abdullah Nabi Aslan***Atatürk Education and Research Hospital, Ankara, Turkey***Corresponding Author (drcihat81@hotmail.com)**drcihat81@hotmail.com, drnabiaslan@hotmail.com***Abstract Text**

Objectives: Patency of infarct-related artery (IRA) in patients with ST segment elevation myocardial infarction (STEMI) before primary percutaneous coronary intervention (pPCI) is associated with lower mortality and better clinical outcome. In this study, the relationship between admission haemoglobin A1c (HbA1c) and IRA patency before mechanical reperfusion in patients with STEMI was investigated.

Methods: A total of 140 consecutive patients with STEMI undergoing pPCI within 12 hours from symptom onset were retrospectively evaluated. IRA patency was assessed by the thrombolysis in myocardial infarction (TIMI) flow grade and patients initially were divided into 2 groups based on the TIMI flow grade. Impaired flow was defined as TIMI grades 0 and 1 and normal flow or patency was defined as TIMI 2 and 3. Patients were divided into three groups based on admission HbA1c levels as group I (HbA1c \leq 5.6%), group II (HbA1c 5.6–6.5%), and group III (HbA1c \geq 6.5%).

Results: Among 140 patients, 46 (32.8 %) revealed pre-pPCI TIMI 2 and 3 flow in IRA. The IRA patency was found to be similar in all 3 HbA1c groups ($p=0.269$). Admission HbA1c levels were similar in both IRA groups ($p=0.314$). In multivariate regression analysis, only MPV (OR: 0.589, 95% CI: 0.365-0.951, $p=0.030$) was significantly and independently associated with IRA patency.

Conclusions: HbA1c is not an independent predictor of the IRA patency in STEMI patients treated with pPCI. However, MPV is a simple, low-cost and available parameter, might be used as an indicator of IRA patency.

Table 5. Multivariate regression analysis of variables related with the patency of infarct - related artery

Variables	Possibility rate	95.0 % confidence interval	P value
Smoking	1.276	0.783 - 2.092	0.324
Mean platelet volume	0.589	0.365 - 0.951	0.030
Lymphocyte count	0.582	0.335 - 1.012	0.055
Total cholesterol	1.008	0.986 - 1.030	0.482
LDL cholesterol	0.978	0.952 - 1.004	0.101
Amylase	0.991	0.972 - 1.011	0.379
Pain duration	1.001	0.998 - 1.003	0.603

LDL, low density lipoprotein

ID: 126

Topic: **Cardiology » Percutaneous Coronary Interventions in Acute Coronary Syndromes**

Presentation Type: **Oral**

RELATIONSHIP BETWEEN ALBUMIN AND CORONARY COLLATERAL CIRCULATION IN PATIENTS WITH ST-ELEVATED MYOCARDIAL INFARCTION

Ash Vural

Giresun University, Giresun, Turkey

**Corresponding Author (drtalu@gmail.com)*

drtalu@gmail.com

Abstract Text

OBJECTIVE: In patients with acute ST-elevated MI, coronary collateral circulation (CCC) is an adaptive responds to myocardial ischemia and protecting from tissue damage and infarction. Recently, the albumin is an acute phase reactane and readily available marker of inflammation. This study aimed to investigate the relationship between albumin levels and development of CCC in patients with STEMI.

METHODS: A total of 160 patients with acute STEMI who had no history of cardiac disease, undergoing coronary arteriography were enrolled and divided on the basis of the development of CCC into two groups: group with poor CCC (Rentrop grades 0-1) (n = 125) and group with well-developed CCC (Rentrop grades 2-3) (n = 35). Routine complete blood count parameters and albumin levels were measured during admission.

RESULTS: The mean age of patients was 59.4± 11.5. The male/female ratio of the study group was 7.4/1. There was no significant difference between the patient groups interms of age, arterial hypertension, diabetes mellitus and hyperlipidemia. Patients with poorly developed CCC had significantly higher albumin and total protein levels compared with those with well-developed CCC. (4.1±0.36 vs. 3.9±0.33, p=0.003) (6.7±0.53 vs 6.3±0.43, p= 0.003).

CONCLUSIONS: Our findings suggest that measurement of albumin and total protein levels may predict the development of CCC in patients with acute STEMI. An increased albumin and total protein levels are associated independently with impaired CCC in these patients.

ID: 123

Topic: Cardiology » Percutaneous Coronary Interventions in Acute Coronary SyndromesPresentation Type: **Oral****IS THERE AN ASSOCIATION OF SERUM SODIUM LEVEL WITH IN-HOSPITAL AND LONG-TERM OUTCOMES IN PATIENTS WITH STEMI****Muhammed Keskin¹, Adnan Kaya²***¹Sultan Abdülhamid Han Training and Research Hospital, Istanbul, Turkey**²Duzce University Medical School, Duzce, Turkey***Corresponding Author (drmuhammedkeskin@gmail.com)**drmuhammedkeskin@gmail.com, adnankaya@ymail.com***Abstract Text****Background**

There are some conflicting results in the association of serum sodium level with clinical outcomes in patients with acute myocardial infarction. The aim of this study was to investigate the effect of serum sodium levels on in-hospital and long-term outcomes in patients with ST-segment elevation myocardial infarction (STEMI).

Methods

A total of 1840 patients with STEMI (mean age 57,3±11.8; men 79.7%) who underwent primary percutaneous coronary intervention were included to the study. Baseline characteristics and outcomes were compared among the patients by admission serum sodium level and categorized accordingly; Q1, Q2, Q3 and Q4.

Results

There was not a significant difference regarding in-hospital mortality, cardiogenic shock, ventricular arrhythmia, acute kidney injury and major adverse cardiac events. Furthermore, after a follow-up period of 3-years; there was not a significant difference regarding long-term mortality and major adverse cardiac events.

Conclusion

In this large-scale study, we did not observe a significant association of serum sodium level with in-hospital and long-term clinical outcomes in patients with STEMI.

Table 1. Outcomes of patients classified by serum sodium level.

Outcomes	I(n=460)	II (n=460)	III(n= 460)	IV (n=460)	P
In-hospital course Cardiogenic shock	30 (6.5)	29 (6.3)	23 (5.0)	25 (5.4)	0.729
Acute respiratory failure	20 (4.3)	23 (5.0)	19 (4.1)	21 (4.6)	0.932
Acute kidney injury	56 (12.2)	68 (14.8)	51 (11.1)	44 (9.6)	0.095
Ventricular arrhythmia	23 (5.0)	24 (5.2)	32 (7.0)	43 (9.3)	0.029
Stent thrombosis	5 (1.1)	9 (2.0)	15 (3.3)	13 (2.8)	0.124
Recurrent MI	5 (1.1)	10 (2.2)	13 (2.8)	14 (3.0)	0.189
Revascularization	11 (2.4)	31 (6.7)	31 (6.7)	30 (6.5)	0.008
Major adverse cardiac events	29 (6.3)	45 (9.8)	38 (8.3)	49 (10.7)	0.099
Mortality	24 (5.2)	29 (5.3)	24 (5.2)	26 (5.7)	0.876
Out-hospital course Stent thrombosis	18 (3.9)	21 (4.6)	28 (6.1)	22 (4.8)	0.477
Recurrent MI	29 (6.3)	32 (7.0)	32 (7.0)	32 (7.0)	0.972
Revascularization	33 (7.2)	54 (11.7)	49 (10.7)	47 (10.2)	0.117
Major adverse cardiac events	58 (12.6)	65 (14.1)	56 (12.2)	63 (13.7)	0.799
All-cause mortality	36 (7.8)	33 (7.2)	36 (7.8)	40 (8.7)	0.863

ID: 118

Topic: **Cardiology** » **Acute Coronary Syndromes**Presentation Type: **Oral**

**ST SEGMENT ELEVATION MYOCARDIAL INFARCTION AND TOTAL
ATRIOVENTRICULAR BLOCK IN THE ABSENCE OF OBSTRUCTIVE
CORONARY ARTERY DISEASE**

Mehmet Eyuboglu

Bergama State Hospital, Izmir, Turkey

**Corresponding Author (mhmtymbgl@gmail.com)*

mhmtymbgl@gmail.com

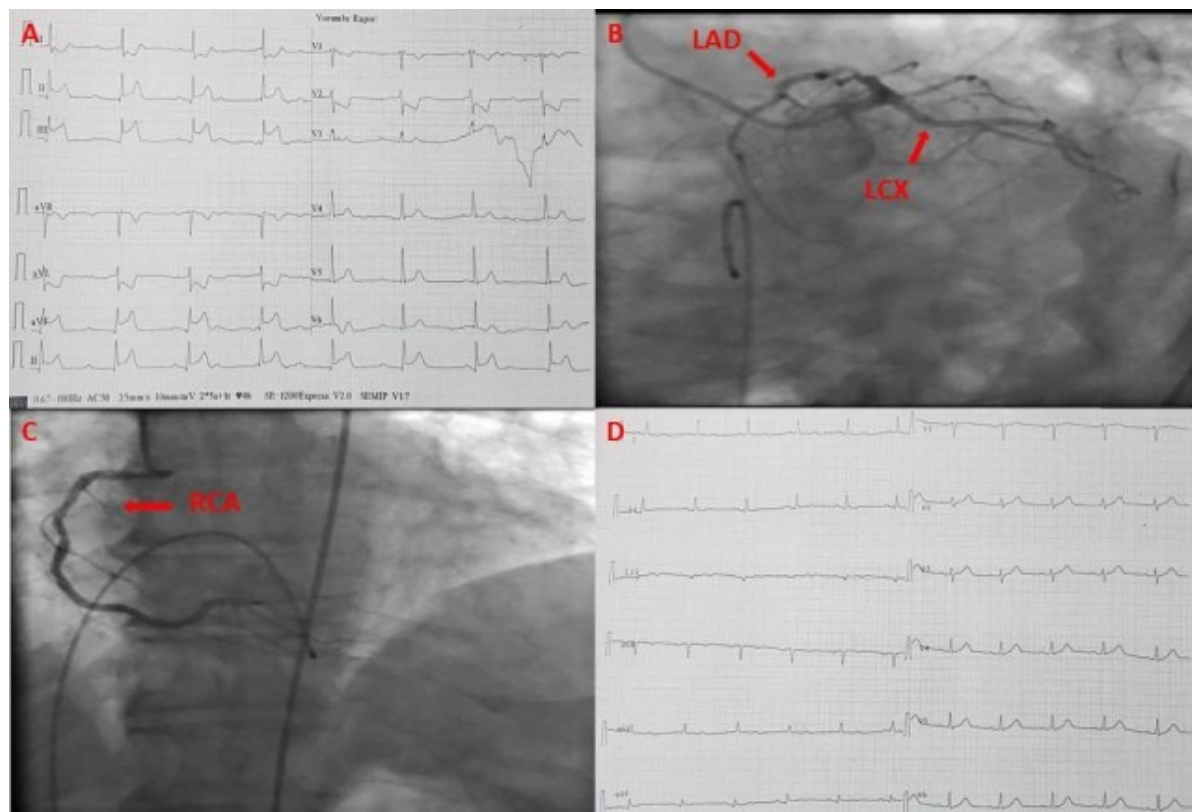Abstract Text

Background: Patients presenting with ST-segment elevation myocardial infarction (STEMI) rarely have non-obstructive (<50%) coronary artery disease in infarct-related artery (IRA), and this type of myocardial infarction is known as 'Myocardial infarction with non-obstructive coronary arteries' (MINOCA). However, MINOCA as STEMI and total atrioventricular block (TAVB) is extremely rare and treatment options for these cases are limited. This presentation would reveal that MINOCA can be complicated by life threatening arrhythmias. Also, discussion of treatment options for this challenging clinical condition is intended.

Methods: A 63 years old male patient without history of prior coronary artery disease admitted to emergency department with acute onset chest pain, sweating and dizziness. The patient was hypotensive (70/30 mmHg) and bradycardic (40 beats/min.). Admission electrocardiography (ECG) demonstrated ST segment elevation in leads D2, D3 and aVF and ST segment depression in leads V1-3 suggesting acute inferior myocardial infarction. Moreover, the ECG revealed that patient had severe bradycardia due to TAVB (Figure 1). Hence, the patient was underwent emergent coronary angiography for primary percutaneous coronary intervention of IRA.

Results: Coronary angiography was performed under transient transvenous pacing. Coronary angiography revealed that there was not critical stenosis in the left anterior descending and in the left circumflex arteries. Interestingly, right coronary artery which is considered as IRA, had no any obstructive lesion (Figure 1). This finding indicated that there was no obstructive (>50%) lesion to treat in IRA. However, the patient was still suffering from chest pain, STEMI was ongoing, and he had bradycardia due to TAVB. Emergent echocardiography demonstrated near-normal left ventricular ejection fraction (55%), hypokinesia in mid and basal segments of inferior wall, and no mechanical complications. The patient was transferred to intensive care unit. After three hours of supportive treatment with intravenous fluid administration, inotrope treatment and transvenous pacing, the patient showed complete recovery of symptoms. Blood pressure returned to normal values and ECG showed normal sinus rhythm and complete resolution of ST-segment elevation (Figure 1).

Conclusions: STEMI complicated by TAVB is an extremely rare clinical condition in the presence of open coronary arteries. Aetiology of this type of MINOCA is unclear and there is no consensus on how to treat it. Hemodynamic support, temporary pacing and effective treatment of hypotension may be helpful in the acute phase, in addition to standard STEMI care. Additionally, further investigation may be necessary in some cases for differential diagnosis.



A) Admission Electrocardiography shows inferior myocardial infarction and total atrioventricular block B) Coronary angiography shows open LAD and LCX arteries C) Right coronary angiography shows no obstructive lesion in infarct-related artery (RCA) D) After 3 hours of admission, electrocardiography shows complete resolution of ST segment elevation and normal sinus rhythm

ID: 196

Topic: **Cardiology » Acute Coronary Syndromes**Presentation Type: **Oral****ASSESSMENT OF QUALITY OF CARE IN PATIENTS PRESENTING WITH ST-SEGMENT ELEVATION MYOCARDIAL INFARCTION (STEMI): EXPERIENCES FROM AN UNIVERSITY HOSPITAL**

Veysel Oktay, Ebru Serin

*Istanbul University-Cerrahpasa Institute of Cardiology, Istanbul, Turkey***Corresponding Author (drvoktay@gmail.com)**drvoktay@gmail.com, serin.ebru@hotmail.com***Abstract Text**

Objective: There is a strong relationship between the patient outcomes and the quality of care in patients with STEMI. Currently, there is wide gap between optimal and actual care in patients diagnosed with STEMI around the world. In this study, we aimed to investigate the assessment of quality of care in patients with STEMI regarding the recommendations of 2017 ESC Guidelines for the management of patients with STEMI.

Methods: Between the time period November 2017 and November 2018, 202 patients diagnosed with STEMI in our hospital were assessed in terms of quality of care regarding the recommendations of 2017 European Society of Cardiology (ESC) STEMI Guidelines. Performance measures including reperfusion therapy, hospital risk assessment, antithrombotic treatment, discharge medication, mortality outcomes and composite quality indicators were identified.

Results: The percentage of STEMI patients arriving in the first 12 hours receiving reperfusion therapy was 87%. No patients received thrombolytic therapy in the pre-hospital settings. The mean door-to-balloon time was 40±21 minutes. The percentage of STEMI patients underwent primary percutaneous coronary intervention (PCI) in 60 minutes was 86%. The proportion of patients having left ventricular ejection fraction (LVEF) assessed before discharge was 89%. The proportion of patients discharged on dual antiplatelet therapy (DAPT) was 93%. The ratio of patients prescribed high-dose statins at discharge was %78. The proportion of patients with LVEF< 40% with a beta blocker and angiotensin-converting enzyme inhibitor (ACEI) prescribed at discharge was 91% and 83% respectively. 30-day adjusted mortality rate was 1%. 30-day adjusted rehospitalization rate was 9%. The composite quality indicators as the proportion of patients with LVEF > 40% receiving at discharge low-dose aspirin, P2Y12 inhibitor and high-dose statin was 63%. Finally, the proportion of patients with LVEF <40% receiving at discharge low-dose aspirin, P2Y12 inhibitors, high-dose statin, ACEI and beta blocker was 44%.

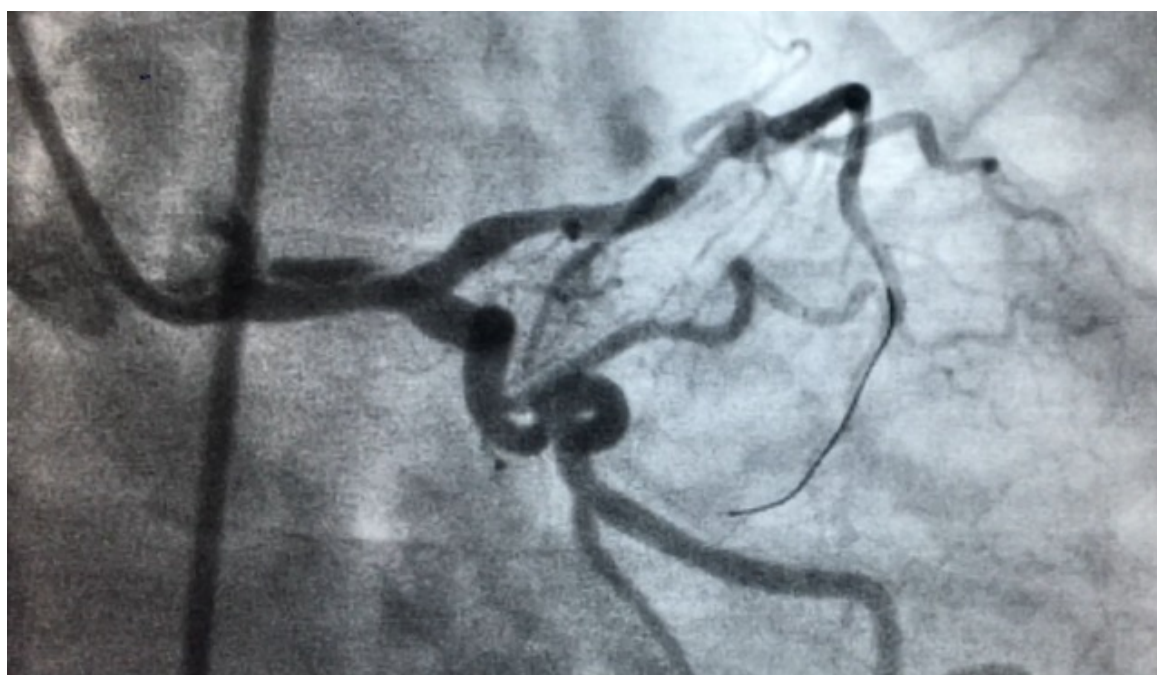
Conclusions: In patients with STEMI, although the time intervals for reperfusion and the percentage of antithrombotic therapy were acceptable relatively, the prescription of drugs having a positive impact on mortality such as beta blocker and ACEI were not satisfactory. It is important to perform and update the quality of care programmes institutionally to improve the patient outcomes.

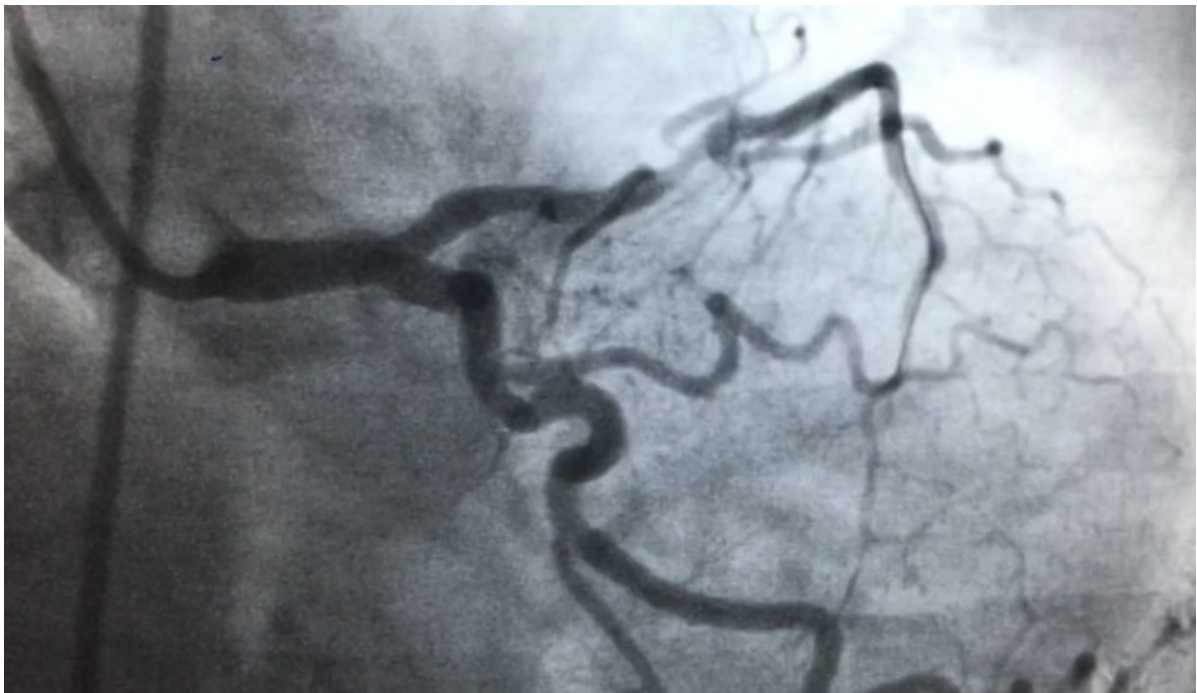
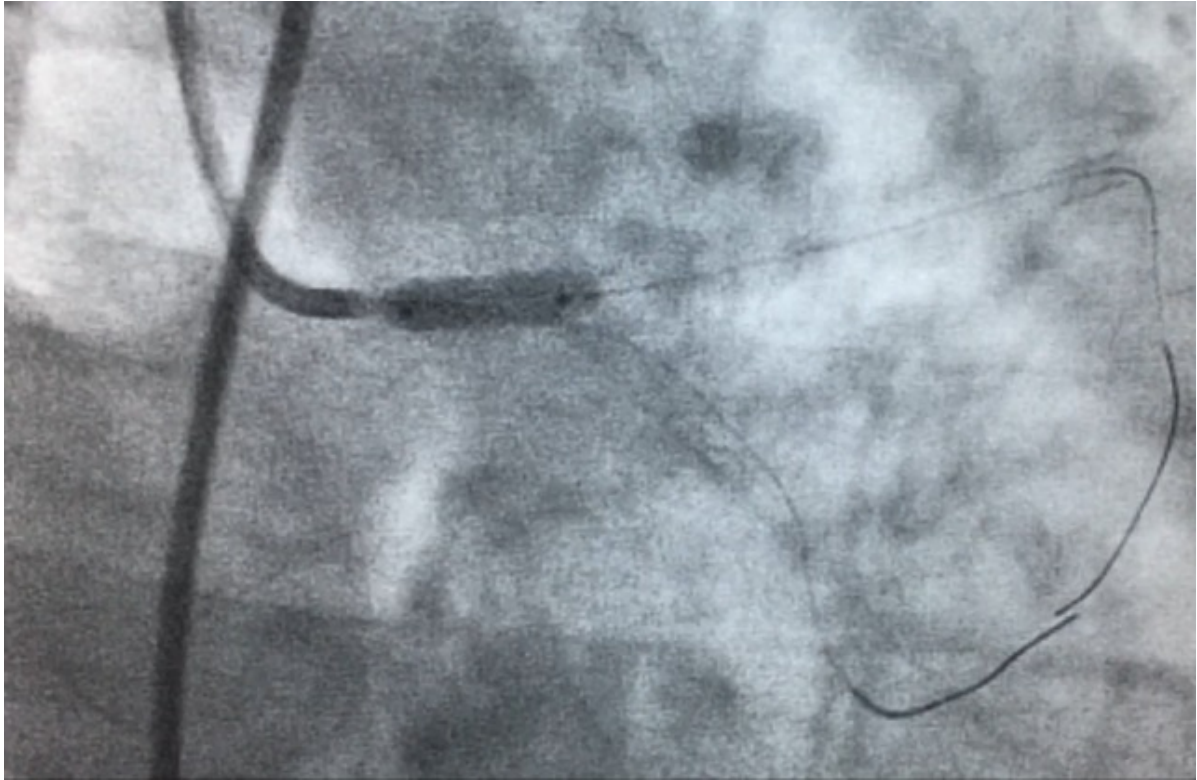
ID: 133

Topic: **Cardiology » Percutaneous Coronary Interventions**Presentation Type: **Oral****SUCCESSFUL STENTING OF LEFT MAIN CORONARY ARTERY
DISSECTION DEVELOPED DURING LAD PCI****Huseyin Bozbas, Ezgi Polat Ocakli, Tuğba Kayhan Altuner, Mehmet Emin Korkmaz***Güven Hospital, Ankara, Turkey***Corresponding Author (hbozbas@gmail.com)**hbozbas@gmail.com, ezgiocakli@gmail.com, drtugba_kayhan@yahoo.com, meminkorkmaz@gmail.com***Abstract Text**

One of the most feared and catastrophic complications of percutaneous coronary intervention (PCI) is left main coronary artery (LMCA) dissection.

We performed coronary angiography to an 58 years of female patient because of angina and positive treadmill exercise test. Upon significant stenosis in LAD and RCA we decided to perform PCI. After stenting LAD lesion we noticed a dissection in LMCA (Picture 1). The patient was hemodynamically stable. We kept the guidewire in position in LAD and immediately placed another guidewire into the Cx artery. As the dissection was confined to LMCA only, we implanted a 4.0-12mm drug eluting stent in LMCA (Picture 2). Then we performed post-dilatation using a 4.5-12mm non-compliant balloon. We saw that the dissection was covered well with TIMI3 flow (Picture 3). We stented the second lesion in LAD. The patient was transferred to intensive care unit. In addition to ticagrelor + aspirin we administered intravenous heparin infusion. She stayed in the ICU for 2 days and did not have chest pain during post-PCI course. We performed control coronary angiography 1 month later. The stent in LMCA was well patent with good blood flow. We stented the lesions in RCA and discharged the patient in good clinical condition. During the post procedure follow up of 18 months she is doing well. Our case is a good example of successful stenting of the iatrogenic LMCA dissection during a PCI/angiography procedure. In such cases the operator should be calm and keep the guidewire in position. We think that stenting is the more appropriate therapy in such cases, especially when the dissection is confined to LMCA only.





Oral Presentations

New Horizons in Diagnosis, Treatment and Outcomes in Acute Coronary Syndrome

Date: 29.03.2019 Time: 18:00 - 19:30 Hall: 5

ID: 434

Topic: **Cardiology » Percutaneous Coronary Interventions in Acute Coronary Syndromes**

Presentation Type: **Oral**

THE VALIDATION OF THE PROGNOSTIC VALUE OF TIMI RISK SCORE IN PATIENTS WITH ST-SEGMENT ELEVATION MYOCARDIAL INFARCTION COMPLICATED WITH CARADIOGENIC SHOCK

Ceyhan Türkkan

SBÜ Dr. Siyami Ersek GKDCEAH, İstanbul, Turkey

**Corresponding Author (jtkan@yahoo.com)*

jtkan@yahoo.com

Abstract Text

Background

Cardiogenic shock is defined as a severe myocardial contractile dysfunction causing failure of the left ventricle to provide sufficient cardiac output despite a normal or elevated pre-load. The Thrombolysis in Myocardial Infarction (TIMI) risk score for ST segment elevation myocardial infarction (STEMI) estimates 30-day mortality in patients with STEMI. There is lack of evidence in regard to the prognostic value of TIMI risk score in in-hospital mortality in patients with STEMI complicated with cardiogenic shock. The aim of the study was to evaluate the prognostic value of the TIMI risk score for STEMI applied to patients complicated with cardiogenic shock and underwent primary percutaneous coronary intervention (PPCI).

Methods

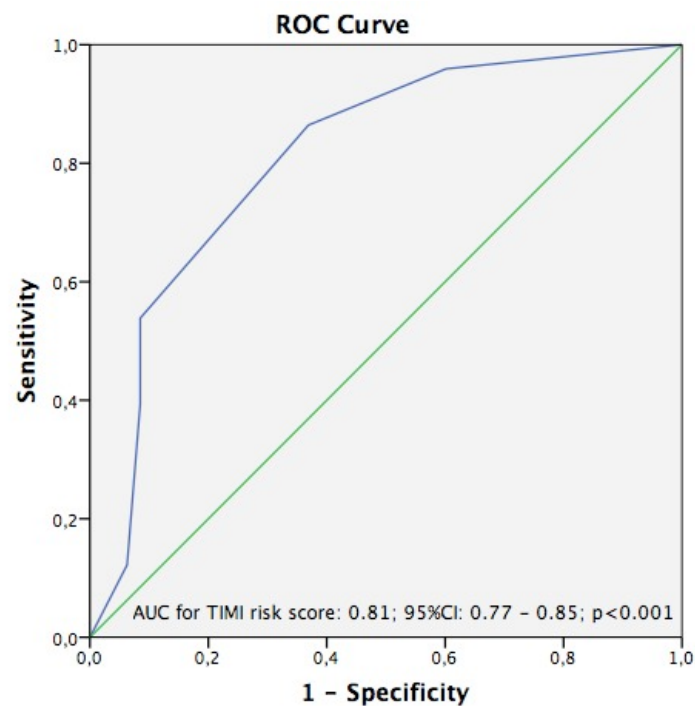
In this retrospective analysis, we evaluated the in-hospital prognostic impact of TIMI risk score on 492 patients with STEMI complicated with cardiogenic shock treated with PPCI. Univariable and multivariable predictors of in-hospital mortality were presented and the value of TIMI risk score was tested with the help of a receiver operating characteristic curve (ROC) analysis.

Results

Ejection fraction (odds ratio [OR]: 0.924; 95 % confidence interval [CI]: 0.898 – 0.951; $p < 0.001$), TIMI risk score (OR: 1.864; 95 % CI: 1.603 – 2.168; $p < 0.001$), glucose (OR: 1.012; 95 % CI: 1.006 – 1.017; $p < 0.01$), lactate (OR: 1.330; 95 % CI: 1.205 – 1.468; $p < 0.001$) were defined as multivariate predictors of in-hospital mortality. ROC analysis showed that the best cut-off value of TIMI risk score to predict in-hospital mortality was 10.5 with 86% sensitivity and 65% specificity (AUC: 0.81; 95% CI: 0.77–0.85; $p < 0.001$)

Conclusion

Our study indicated that TIMI risk score is an independent prognostic factor for in-hospital mortality of patients with STEMI complicated with cardiogenic shock treated with PPCI.



	Unadjusted OR	95% CI	P value	Adjusted OR	95% CI	P value
Age	1.033	1.018 – 1.049	<0.001			
Ejection fraction	0.895	0.872 – 0.918	<0.001	0.924	0.898 – 0.951	<0.001
Diabetes Mellitus	1.730	1.186 – 2.523	0.004			
Chronic renal failure	1.656	1.035 – 2.651	0.036			
Female gender	0.659	0.457 – 0.952	0.026			
TIMI risk score	2.070	1.799 – 2.381	<0.001	1.864	1.603 – 2.168	<0.001
Culprit lesion LAD	2.012	1.393 – 2.907	<0.001			
Glucose	1.009	1.005 – 1.013	<0.001	1.012	1.006 – 1.017	<0.001
Lactate	1.396	1.280 – 1.522	<0.001	1.330	1.205 – 1.468	<0.001
Creatinine	1.462	1.021 – 2.093	0.038			

Univariate and multivariate logistic regression analysis for prediction of in-hospital mortality in patients with STEMI complicated with cardiogenic shock

ID: 134

Topic: Cardiology » Percutaneous Coronary Interventions in Acute Coronary SyndromesPresentation Type: **Oral****EVALUATION OF CORONARY ANGIOGRAPHY TIMING IN PATIENTS WITH NON-ST SEGMENT ELEVATION MYOCARDIAL INFARCTION****Samet Yılmaz, Oguz Kılıç***Pamukkale University, Pamukkale/Denizli, Turkey***Corresponding Author (sametyilmazmd@gmail.com)**sametyilmazmd@gmail.com, dr.kilicoguz@gmail.com***Abstract Text****Objective**

An invasive approach is recommended to prevent mortality and morbidity in non-ST-segment elevation acute coronary syndromes (NSTE-ACS). However, the timing of angiography and the subsequent intervention, when required, remains controversial. In this study, our aim was to evaluate the timing of coronary angiography on long term mortality and major adverse cardiovascular events (MACE) in patients with (NSTE-ACS).

Methods

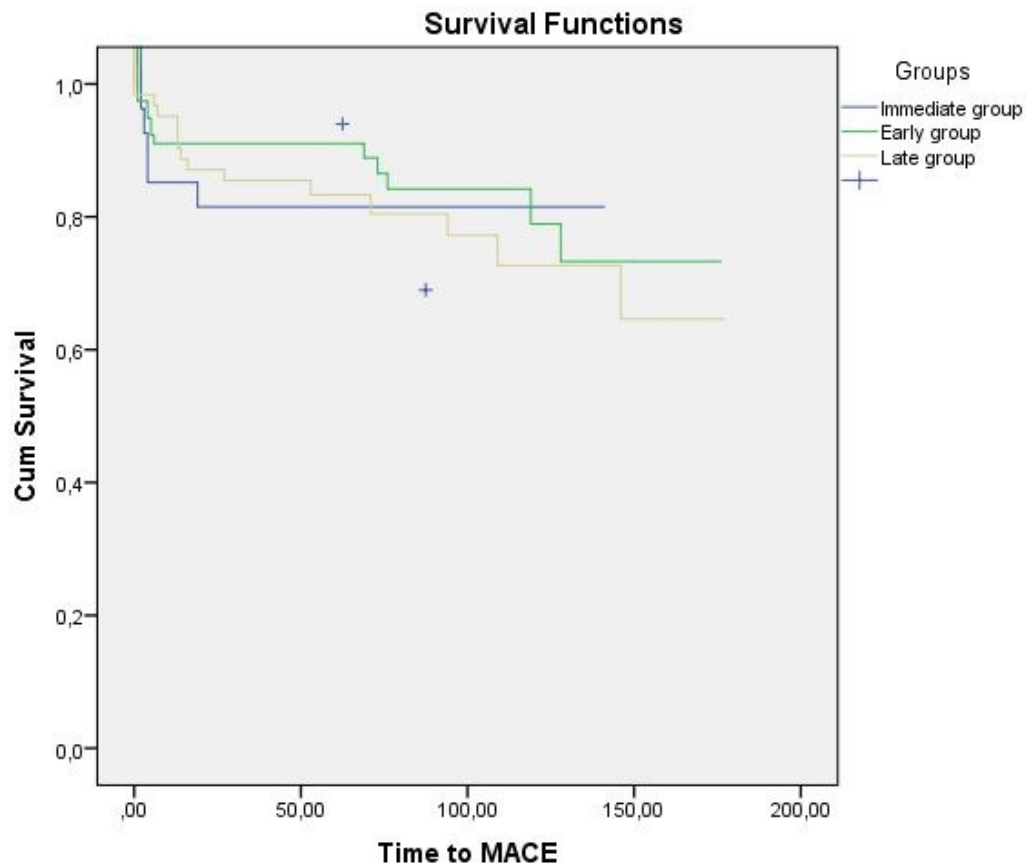
Patients who were hospitalized with a diagnosis of NSTE-ACS between January 2016 and January 2018 were enrolled in this study. Time duration between hospital admission to coronary angiography was calculated from hospital records. Patients who died during index event were excluded from the study. Follow-up data was gathered from hospital records and patient phone calls. MACE was defined as a composite of all-cause mortality, myocardial infarction and re-hospitalization due to cardiovascular causes.

Results

A total of 167 patients were divided into 3 groups [immediate group (<2 h), early group (2<, <24 h) and late group (24< h)] according to coronary angiography timing. The mean follow up duration of the total study group was 75±16 weeks. A number of MACE occurred in each group was not statistically different (18.5% vs. 15.3% vs. 22.5%, p=0.553). During follow up period, 24 patients (14.3%) died. Although rate of all-cause mortality is higher in the late angiography group, it was not reach the statistically significance (17.7% vs 11.5% vs 14.8%, p=0.581). The mean time duration up to coronary angiography was significantly higher in the patients who died (41±43 h vs. 25±24 h, p=0.011). According to Cox regression analysis only GRACE risk score was found related to MACE [HR:1.039, 95% CI (1.04-1.055), p<0.001].

Conclusions

In patients with NSTE-ACS, timing of coronary angiography was not found related to long term mortality or MACE.



|

ID: 80

Topic: **Cardiology** » **Electrocardiography and Non Invasive Electrocardiology**Presentation Type: **Oral**

INCREASED GALECTIN-3 LEVELS FOLLOWING ST-ELEVATION MYOCARDIAL INFARCTION INDICATE VENTRICULAR ARRHYTHMIC EVENTS

Mustafa Umut Somuncu¹, Ali Riza Demir²¹Bulent Ecevit University, Kozlu, Turkey²Mehmet Akif Ersoy Thoracic and Cardiovascular Surgery Center, Training and Research Hospital, Istanbul, Turkey*Corresponding Author (usomuncu@gmail.com)usomuncu@gmail.com, alirdemir1986@gmail.com

Abstract Text

Objective: Galectin-3 (Gal-3), a biomarker of inflammation, tissue repair, and fibrogenesis, is associated with left ventricular remodeling and myocardial fibrosis following ST-elevated myocardial infarction (STEMI). Ventricular remodeling and myocardial fibrosis are reported to be associated with ventricular arrhythmic events. The aim of this study is to determine if Gal-3 levels are associated with microvolt T-wave alternans (MTWA) and frequent premature ventricular complexes (PVCs), known to predict arrhythmic events/ventricular arrhythmia.

Methods: A total of 81 ST-elevated myocardial infarction patients with preserved cardiac function treated with single vessel primary percutaneous coronary intervention were included in the study. Blood samples for Gal-3 levels were obtained from all patients at the time of admission. The patients were separated into low- and high-Gal-3 groups using the median value. Echocardiography and 24-hour Holter monitoring for MTWA, PVCs, and arrhythmia were performed. TWA greater than or equal to 65 microvolts was considered positive in light of previous studies. Detection of more than 10 PVCs per hour during a 24-hour rhythm Holter examination in ischemic heart patients was considered positive since it was reported to be associated with increased arrhythmic events. Low-Gal-3 and high-Gal-3 groups were compared with respect to both MTWA and PVC positivity and their association with Gal-3 levels were examined. Furthermore, multivariate logistic regression analysis was performed to determine independent predictors of MTWA and PVC positivity.

Results: When compared to the low-Gal-3 group, left atrial volume (LAV) was higher in the high-Gal-3 patients (55.7±18.0 vs 40.6±13.7 ml, p<0.001). Multiple logistic regression analyses revealed that age (OR: 1.083 CI 95% 1.023-1.140, p=0.005) and LAV (OR: 1.042 CI 95% 1.002-1.083, p=0.040) were significant independent predictors of PVC positivity. Besides, being in the high Gal-3 group was associated with 10.5 times increased odds for PVC positivity and 6.7 times increased odds for MTWA positivity than being in the low Gal-3 group independent other risk factors. Furthermore, a Gal-3 cut off 3.4 ng/dl had AUC 0.867 with an 81.8% sensitivity, 83.0% specificity for distinguishing coexistence of MTWA and PVC positivity showed in ROC analysis (p<0.001)

Conclusions: Gal-3 levels were associated with PVC and MTWA positivity, and predictor of arrhythmic events, among single-vessel STEMI patients underwent pPCI with preserved cardiac function.

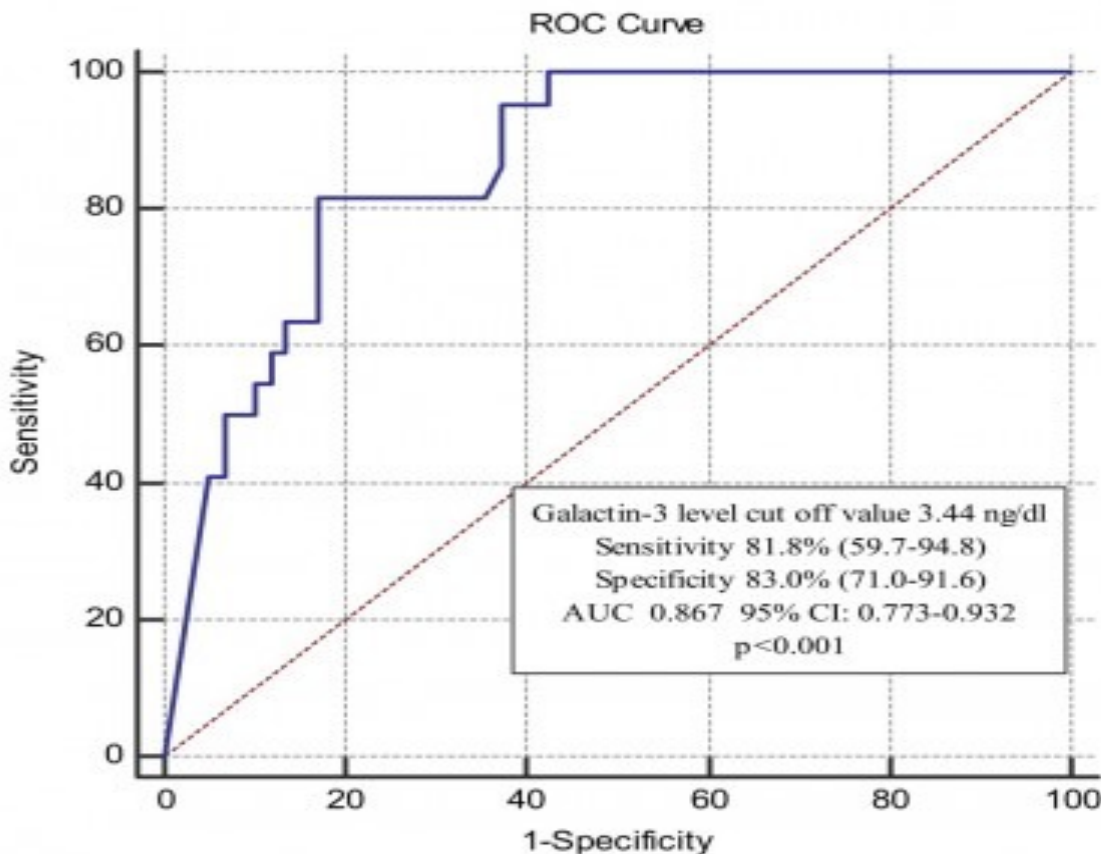


Table 2:Multivariable	Logistic Regression	Analysis for	T-wave	Alternans	and PVC Positivity
------------------------------	----------------------------	---------------------	--------	-----------	---------------------------

-	Univariable analysis CI 95%	P Value	Multivariable analysis OR (CI 95%)*	P Value
First Model	-	-	-	-
Age, years	1.006- 1.100	0.026	1.083(1.023-1.140)	0.005
Male, yes	0.410-10.457	0.384		
HL, yes	0.087-14.437	0.929		
DM, yes	0.021-3.065	0.283		
HT, yes	0.249-4.807	0.906		
Anterior MI	0.113-1.923	0.291		
LVEF, %	0.912-1.045	0.492		
Peak troponin, mg/dl	0.902-1.039	0.373		
LA volum	1.017-1.085	0.003	1.042 (1.002-1.083)	0.040
Galactin Class	2.825-40.156	<0.001	10.576 (2.295-48.726)	0.002
Second Model†				
Age, years	0.937- 1.019	0.282		
Male, yes	0.914-1.010	0.118		
HL, yes	0.063-3.153	0.419		
DM, yes	0.466-22.745	0.234		
HT, yes	0.128-1.944	0.316		
LVEF, %	1.000-1.150	0.051	1.071 (0.995-1.153)	0.066
Anterior MI	0.430-4.441	0.587		
Peak troponin, mg/dl	0.965-1.087	0.435		
LA volum	0.971-1.045	0.689		
Galactin Class	2.177-20.420	0.001	6.734 (2.149-21.101)	0.002

ID: 172

Topic: **Cardiology » Acute Coronary Syndromes**Presentation Type: **Oral**

RELATIONSHIP BETWEEN URIC ACID AND ANGIOGRAPHIC CORONARY SEVERITY IN PATIENTS WITH ACUTE CORONARY SYNDROME

Khanh Pham¹, Vien Truong¹, Sang Tran¹, Quynh Dinh¹, Hoang Duong¹, Tam Ngo¹, Quoc Bui¹, An Ho¹, Chau Dang¹, Anh Nguyen¹, Hoai Nguyen², Duong Huynh¹, Trang Le³, Thien Thai³, Tuy Nguyen¹, Nguyen Nguyen⁴, Duy Chung⁵, Luan Ngo¹, Hoang Phan¹, Vinh Pham¹, Thach Nguyen⁶

¹Pham Ngoc Thach University of Medicine, Ho Chi Minh, Vietnam

²Ho Chi Minh University of Medicine, Ho Chi Minh, Vietnam

³Tam Duc Heart Hospital, Ho Chi Minh, Vietnam

⁴Ho Chi Minh University of Medicine, Ho Chi Minh, Vietnam

⁵Pham Ngoc Thach University of Medicine, Indiana, United States

⁶Methodist Hospital, Indiana, United States

*Corresponding Author (drphikhanh@gmail.com)

drphikhanh@gmail.com, thanhvientruong1988@gmail.com, nghiencuutimmach@gmail.com,
nghiencuutimmach@gmail.com, nghiencuutimmach@gmail.com, nghiencuutimmach@gmail.com,
nghiencuutimmach@gmail.com, nghiencuutimmach@gmail.com, nghiencuutimmach@gmail.com,
nghiencuutimmach@gmail.com, nghiencuutimmach@gmail.com, nghiencuutimmach@gmail.com,
nghiencuutimmach@gmail.com, nghiencuutimmach@gmail.com, nghiencuutimmach@gmail.com,
nghiencuutimmach@gmail.com, nghiencuutimmach@gmail.com, nghiencuutimmach@gmail.com,
nghiencuutimmach@gmail.com, nghiencuutimmach@gmail.com, nghiencuutimmach@gmail.com,
thachnguyen2000@yahoo.com

Abstract Text

PURPOSE

We examined whether there is an association between the level of uric acid and angiographic severity in the patients presenting with acute coronary syndrome (ACS).

METHODS

A total of 381 patients (mean age 65.7 ± 12.2 years) with ACS who underwent coronary angiography from January 2015 to June 2017 at Tam Duc Heart Hospital, Vietnam were included in this study. Serum uric acid level and basic laboratory tests were measured among patients before the procedure. Those with end-stage renal disease, cirrhosis, NYHA III-IV chronic heart failure were excluded from our analyses. The patients were categorised into two groups: normouricemia and hyperuricemia based on their serum uric acid level. Hyperuricemia was defined as serum uric acid level ≥ 420 $\mu\text{mol/L}$ for men or ≥ 360 $\mu\text{mol/L}$ for women. The severity of coronary artery disease was determined by the Gensini score.

RESULTS

In this series of patients, 170/381 (44.6%) were diagnosed with hyperuricemia. We identified 1-, 2-, and 3-diseased vessels among 122 (32%), 114 (29.9%), and 145 (38.1%) patients, respectively. Compared to those with normouricemia, hyperuricemic patients had significantly greater levels of high-sensitive cardiac troponin T ($p=0.03$), N-terminal pro-brain natriuretic peptide ($p<0.001$), creatinine level ($p<0.001$), and a higher Killip classification ($p<0.001$). Regarding to coronary angiographic findings, Gensini score and number of diseased vessels were greater in hyperuricemic patients compared to normouricemia group ($p=0.007$, $p=0.015$, respectively) (Table). Higher level of uric acid was positively correlated with the Gensini score ($r=0.19$, $p<0.001$), and the number of diseased vessel ($r=0.15$, $p=0.003$).

CONCLUSION High level of uric acid was associated with the angiographic severity of coronary artery disease in patients with ACS.

Normouricemia (n=221)	Hyperuricemia (n=170)	P	
Age (year)	65 ± 12	67 ± 12	0.2
Systolic BP (mmHg)	133 ± 23	133 ± 25	0.9
Diastolic BP (mmHg)	76 ± 13	75 ± 14	0.8
BMI (kg/m ²)	24.2 ± 4.7	23.5 ± 3	0.1
Hypertension	152 (72%)	134 (78.8%)	0.13
Smoking	83 (39.3%)	62 (36.5%)	0.6
Diabetes	74 (35.1%)	48 (28.2%)	0.16
Dyslipidemia	114 (54%)	90 (53.3%)	0.88
Killip classification	1.3 ± 0.7	1.6 ± 0.9	<0.0001
Uric acid (umol/L)	318.3 ± 64.2	499.4 ± 102.7	<0.001
NT-proBNP (pg/mL)	360.5 (116.3 – 1300)	798.5 (198 – 3991)	<0.0001
hs-TnT (pg/mL)	84 (14.5 – 752.3)	219.1 (32.8 – 904.3)	0.03
Gensini score	32 (16 – 62)	45 (24 – 72)	0.007
Number of diseased vessels	1.9 ± 0.8	2.2 ± 0.8	0.015
Continuous variable are expressed as mean ± standard deviation with normal distribution and median and interquartile range with non-normal distribution. Categorical variables are presented as n (%). Hs-TnT, high-sensitive cardiac troponin T; NT-proBNP, N-terminal pro-brain natriuretic peptide.			

ID: 31

Topic: **Cardiology » Acute Coronary Syndromes**Presentation Type: **Oral****MEAN PLATELET VOLUME-TO-LYMPHOCYTE RATIO AS A NOVEL
MARKER OF SEVERITY AND COMPLEXITY OF CORONARY
ATHEROSCLEROSIS IN ACUTE CORONARY SYNDROME PATIENTS****Alparslan Kılıç***Koç Üniveristesi, İstanbul, Turkey***Corresponding Author (alkilic@kuh.ku.edu.tr)**alkilic@kuh.ku.edu.tr***Abstract Text**

Abstract

OBJECTIVE Thrombo inflammatory process plays an important role in the pathophysiological mechanism of acute coronary syndrome (ACS). Recently, mean platelet volume-to-lymphocyte ratio (MPVLR) has been suggested as a prognostic marker in ACS patients. We aimed to research the association of MPVLR with the severity and complexity of coronary atherosclerosis in patients with ACS.

METHODS A total of 1782 patients undergoing urgent coronary angiography were enrolled in the study. The SYNTAX score (SXscore) was calculated for each patient. Patients were divided into two groups: low SXscore (<23) and intermediate-to-high SXscore (≥23).

RESULTS MPVLR levels were higher in the intermediate-to-high SXscore group than the low SXscore group ($p<0.001$). Furthermore, in-hospital mortality was significantly higher in patients with high MPVLR (≥ 4.31) and intermediate-to-high SXscore (≥ 23). In multivariate analysis, independent predictors of intermediate-to-high SXscore were MPVLR (odds ratio [OR] 1.737, $p<0.001$), age (OR 1.030, $p=0.009$), ejection fraction (OR 0.943, $p<0.001$), and Killip ≥ 2 class (OR 3.937, $p=0.006$).

CONCLUSIONS MPVLR levels at admission were associated with the severity and complexity of coronary atherosclerosis and in-hospital mortality in ACS patients. MPVLR was an independent predictor of higher SXscore in these patients.

Key Words: Mean platelet volume-to-lymphocyte ratio, SYNTAX score, acute coronary syndrome

ID: 333

Topic: **Cardiology » Chronic Stable Angina Pectoris**Presentation Type: **Oral****THE ASSOCIATION BETWEEN LYMPHOCYTE-TO-MONOCYTE RATIO AND CORONARY ARTERY DISEASE SEVERITY IN PATIENTS WITH STABLE CORONARY ARTERY DISEASE**Nuri Kose¹, Fatih Akin², Tarik Yildirim², Gokhan Ergun², İbrahim Altun²¹Private Yucelen Hospital, Mugla, Turkey²Mugla Sitki Kocman University, Mugla, Turkey^{*}Corresponding Author (drnurikose@hotmail.com)

drnurikose@hotmail.com, fatih._akin@hotmail.com, kdrtarik@gmail.com, dr_ergun2006@yahoo.com, ibrahim_altun@yahoo.com

Abstract Text

BACKGROUND AND AIM: Inflammation plays an important role in the pathogenesis of atherosclerosis. Lymphocyte-to-monocyte ratio (LMR) may reflect systemic inflammatory status. We investigated the association between LMR and coronary artery disease in patients with stable angina pectoris.

METHODS: A total of 221 consecutive patients who were routinely referred to coronary angiography for stable angina pectoris and 72 patients with normal coronary artery were included in the present study. We analyzed the relation between LMR and angiographic severity of CAD. The SYNTAX score was used for assessing the severity of coronary atherosclerosis.

RESULTS: The neutrophil-to-lymphocyte ratio (N/L ratio), platelet size distribution width (PDW), neutrophil and uric acid levels were significantly higher in the stable angina pectoris group than in the control group. The LMR was significantly lower in the stable angina pectoris group than in the control group (4.5 ± 3.2 vs. 6 ± 2.9 , $p < 0.001$). MpvI_r was similar in both group. Patients with elevated SYNTAX score (>32) had lower LMR values (3.2 ± 1.5 vs 4.6 ± 3 , $p = 0.002$). MHR was significantly higher in patients with stable CAD group than in the control group (0.015 ± 0.008 vs. 0.009 ± 0.004 , $p < 0.001$), however it was similar in higher SYNTAX score (>32) and lower group. (0.018 ± 0.007 vs. 0.014 ± 0.008 , $p = 0.056$). Using multivariate logistic regression analysis, we found that only LMR was independent predictor of the high SYNTAX score in patients with stable angina pectoris.

CONCLUSIONS: Lymphocyte-to-monocyte ratio, an inexpensive and easily measurable laboratory variable, is significantly associated with the presence of coronary artery disease and high SYNTAX score in patients with stable angina pectoris.

Keywords: coronary artery disease, lymphocyte-to-monocyte ratio, stable angina pectoris, SYNTAX score

ID: 261

Topic: Cardiology » Chronic Stable Angina Pectoris

Presentation Type: Oral

LYMPHOCYTE / MONOCYTE RATIO PREDICTS THE OCCURENCE OF CORONARY ARTERY DISEASE IN YOUNG ADULTS

Firdevs Aysenur Ekizler, Serkan Cay, Habibe Kafes, Bahar Tekin Tak, Ozcan Ozeke, Dursun Aras

Yuksekt Ihtisas Education and Research Hospital Turkey, Ankara, Turkey

**Corresponding Author (firdevs_bsk@hotmail.com)*

firdevs_bsk@hotmail.com, cayserkan@yahoo.com, drhabibekafes@hotmail.com, tekinbahar@yahool.com, ozcanozeke@gmail.com, drdaras@gmail.com

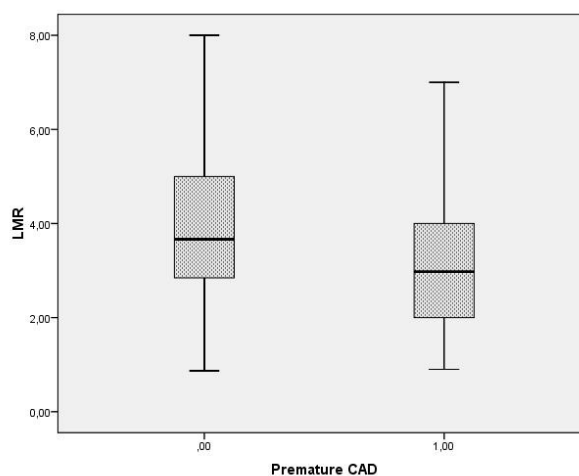
Abstract Text

Objective: Onset of coronary artery disease (CAD) before 45 years of age for men and <55 years of age for women is considered as premature coronary artery disease (CAD). Coronary artery disease in young adults is relatively rare, but it is in an increasing trend. Few data on CAD in young adults are available in the literature. However the risk factors are largely unknown. The lymphocyte / monocyte ratio (LMR) obtained by dividing the number of lymphocytes by monocyte number is considered a novel marker of inflammation. In the current study, LMR was evaluated in patients with newly diagnosed premature coronary artery disease.

Method: In this retrospective study, we consecutively included young adults undergoing coronary angiography in our institution. Patients with coronary angiography showed that luminal diameter stenosis > %50 in any of the major epicardial coronary arteries were considered as CAD. A total of 553 patients (392 male) were included and 230 cases with newly diagnosed premature coronary heart disease (age <45 years for men and <55 years for women) formed the study group. Remaining 323 cases were well-matched controls with normal coronary angiography results. Blood parameters including LMR were compared between two groups.

Results: While monocyte count, CRP and uric acid was higher in the premature CAD group; lymphocyte count, High-density lipoprotein cholesterol(HDL) and LMR levels (Fig.1) were lower than control group. Multivariate logistic regression analysis showed that uric acid, and LMR are independent variables for the occurrence of premature CAD.

Conclusions: Based on our results, In young adults (age <45 years for men and <55 years for women), it can be concluded that LMR levels are significantly associated with the presence of CAD.



ID: 2

Topic: **Cardiology » Chronic Stable Angina Pectoris**

Presentation Type: **Oral**

EVALUATION OF FUNCTIONAL EFFICIENCY OF CORONARY FLOW IN PATIENTS WITH STABLE CORONARY ARTERIES DISEASE WITH CONSERVATIVE AND INTERVENTIONAL TREATMENT

Volha Sujayeva

Republican Scientific and Practical Centre , Minsk, Belarus

**Corresponding Author (sujayeva@bk.ru)*

sujayeva@bk.ru

Abstract Text

Objective - to study functional efficiency of coronary flow in patients with stable coronary arteries disease with conservative and interventional treatment

Methods: The research included 104 patients with stable coronary arteries disease (CAD), in 64 (62 %) percutaneous coronary intervention (PCI) has been performed before. The age included in a research was 48-70 years (on average 63,5±4,8). The myocardial had 101 patients. At 64 patients 91 stents were implanted. Stable angina I-III functional class had 73 % pts without revascularization and 69 % pts after PCI was exposed. Myocardial ischemia was revealed by daily ECG monitoring at 14 % pts without revascularization and at 8 % pts after PCI. A myocardium ischemia by spirobicycle ergometry test was found at 30 % and 22 % patients, correspondingly. Quality of visualization of coronary stenosis in native coronary arteries was good in 93 % patients. Sensitivity and specificity of coronary stenosis and coronary stents was high enough.

Non-invasive method for assessing coronary anatomy – computed tomography of coronary arteries is highly informative in assessing the patency of both native coronary arteries and coronary stents of ≥ 2.5 mm in size long after the PCI. Performing of ECG methods of myocardial ischemia visualization (both ECG daily monitoring and spiro BET) and computed tomographic angiography of coronary arteries promotes rising of myocardial ischemia objectification at patients with stable CAD both with and without PCI.

ID: 171

Topic: **Cardiology** » **Acute Coronary Syndromes**Presentation Type: **Oral****ASSOCIATION OF N-TERMINAL PRO-BRAIN NATRIURETIC PEPTIDE WITH CONTRAST-INDUCED NEPHROPATHY IN PATIENTS WITH ACUTE CORONARY SYNDROME UNDERGOING PERCUTANEOUS CORONARY INTERVENTION**

Vien Truong¹, Khanh Pham², Sang Tran², Van Truong², Hoang Duong², Tam Ngo², An Ho², Quan Tran², Huy Phan², Thi Nguyen², Tam Nguyen², Giang Ngo², Quoc Bui², Khoi Che², Thu Nguyen², Boa Truong², Tu Nguyen², Minh Vo², Dinh Quynh², Hoang Phan², Vinh Pham³, Thach Nguyen⁴

¹Tan Tao School of Medicine, Long An, Vietnam

²Pham Ngoc Thach University of Medicine, Ho Chi Minh, Vietnam

³Methodist HosPham Ngoc Thach University of Medicinepital, Ho Chi Minh, Vietnam

⁴Methodist Hospital, indiana, United States

*Corresponding Author (thanhvientruong1988@gmail.com)

thanhvientruong1988@gmail.com, drphikhanh@gmail.com, nghiencuutimmach@gmail.com, nghiencuutimmach@gmail.com, nghiencuutimmach@gmail.com, nghiencuutimmach@gmail.com, nghiencuutimmach@gmail.com, nghiencuutimmach@gmail.com, nghiencuutimmach@gmail.com, nghiencuutimmach@gmail.com, nghiencuutimmach@gmail.com, nghiencuutimmach@gmail.com, nghiencuutimmach@gmail.com, nghiencuutimmach@gmail.com, nghiencuutimmach@gmail.com, nghiencuutimmach@gmail.com, nghiencuutimmach@gmail.com, nghiencuutimmach@gmail.com, nghiencuutimmach@gmail.com, nghiencuutimmach@gmail.com

Abstract Text

Background

It is evident that N-terminal pro-brain natriuretic peptide (NT-proBNP) is associated with important risk factors for contrast-induced nephropathy (CIN). We investigated whether there is an association between the level of NT-proBNP and CIN among the patients presenting with acute coronary syndrome (ACS) who underwent coronary intervention.

METHODS

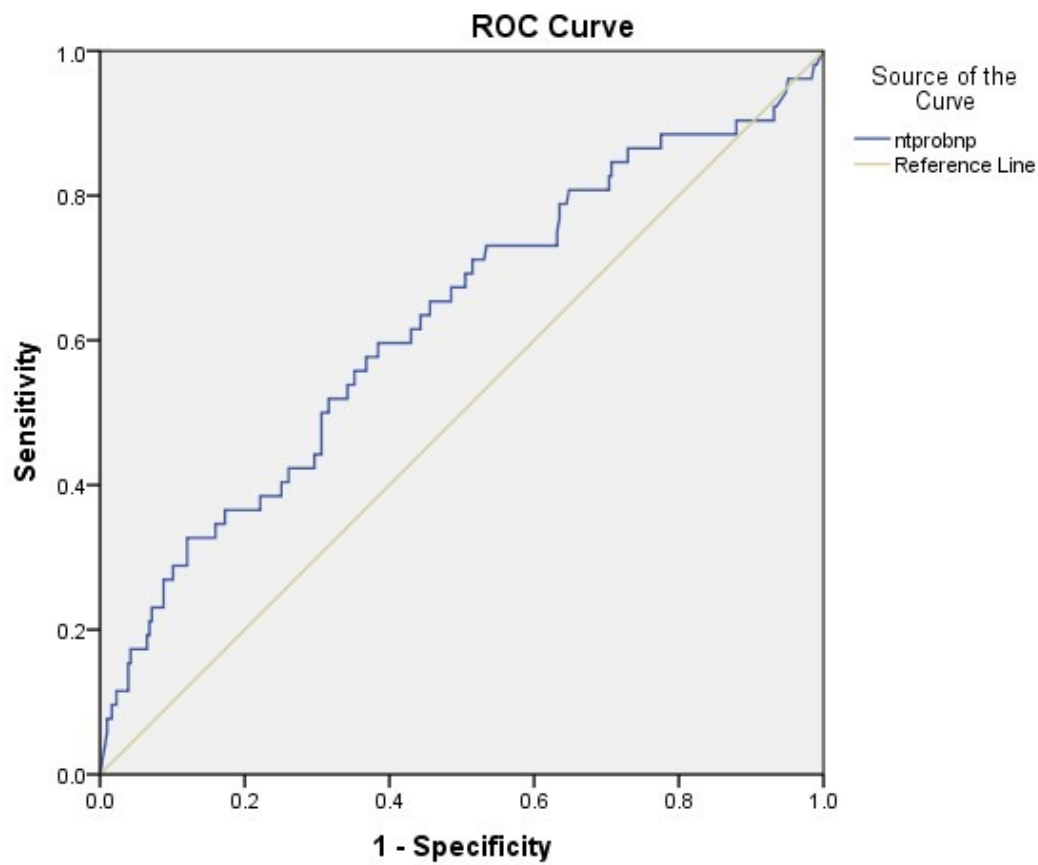
We included a total of 381 patients (mean age 65.7 ± 12.2 years) with ACS who received coronary angiography from January 2015 to June 2017 at Tam Duc Heart Hospital, Vietnam. The predictive value of preprocedural NT-proBNP for CIN was assessed by receiver operating characteristic (ROC curve) and multivariable logistic regression analysis.

RESULTS

Fifty-two (52) out of 381 (14%) patients developed CIN. Those with CIN had higher preprocedural levels of NT-proBNP compared to those without CIN (mean: 5381 ± 9350 versus 2088 ± 4684 pg/mL, $p < 0.001$). An NT-proBNP cut-off value of 815 pg/mL predicted CIN with 60% sensitivity and 61% specificity. Multivariable regression analysis suggested that, after adjustment for other risk factors (age, baseline creatinine, history of diabetes mellitus, contrast volume), NT-proBNP was significantly associated with CIN (odds ratio (OR) = 1.2; $p = 0.026$).

CONCLUSION

Increased NT-proBNP level was associated with the presence of CIN among patients with ACS.



Diagonal segments are produced by ties.

ID: 260

Topic: **Cardiology » Coronary Artery Disease - CABG Surgery**Presentation Type: **Oral****DOES LAD DEPRESSION SIGN IN CORONARY ANGIOGRAPHY
CORRELATE WITH INTRAMYOCARDIAL LEFT ANTERIOR
DESCENDING CORONARY ARTERY?**Kivanc Atilgan¹, **Zafer Cengiz Er**², Ertan Demirdas³, Ferit Cicekcioglu², Haci Alper Uzun²¹*TOBB ETU Hospital, Ankara, Turkey*²*Bozok University, Yozgat, Turkey*³*Gulhane Egitim ve Arastirma Hastanesi, Ankara, Turkey***Corresponding Author (kivancatilgan@gmail.com)**kivancatilgan@gmail.com, erzafer2008@gmail.com, dr.ertandemirdas@gmail.com, drferitcicek@gmail.com, alpuzun2003@yahoo.com***Abstract Text**

Objective: The aim of this study is to define the correlation between intramyocardial left anterior descending (IMLAD) artery and coronary artery angiography (CAG); our clinical intraoperative experiences.

Methods: Between January 2014 and May 2018, 179 patients underwent coronary artery bypass grafting (CABG) surgery in Bozok University Medicine Faculty Hospital. The correlation between the typical “wide-U” image of left anterior descending artery (LAD) depression on CAG and our intraoperative surgical observations of the patients were studied. (Figure 1)

Results: Of the 179 patients, 5 were excluded due to the total occlusion of proximal LAD. 25 had a typical “wide-U” image on CAG and 14 were observed to have an IMLAD. Of the 25 patients having IMLAD image on CAG, 3 were observed to have an epicardial LAD. Of the 17 patients being observed to have IMLAD intraoperatively, 3 had a normal preoperative CAG imaging. The prevalence of the intramyocardial LAD was 9.7%. Sensitivity of CAG was measured as 82.3% and specificity of CAG was 92.9%.

Conclusion: In some of the CAG procedures, LAD is seen diving into the myocardium at an acute angle and coming back to the epicardial layer following a variable length of course composing a “wide-U” imaging, which is seen more clearly on the left anterior oblique position. This LAD depression sign was observed to have a correlation with the intraoperative detection of IMLAD. According to this strategy, we may define positive and negative predicting values for CAG imaging in terms of intramyocardial LAD.

Oral Presentations

A Success Story of Vascular Surgeons: Salvage for Vascular Injuries

Date: 29.03.2019 Time: 08:00 - 09:00 Hall: 6

ID: 267

Topic: **Cardiovascular Surgery » Peripheral Artery Disease and Treatment**

Presentation Type: **Oral**

OUR CLINICAL EXPERIENCE IN LOWER EXTREMITY VASCULAR INJURIES

Ferhat Borulu, Bilgehan Erkut, Yasin Kılıç, Yahya Ünlü

Atatürk University Faculty Of Medicine, Erzurum, Turkey

**Corresponding Author (fborulu@gmail.com)*

fborulu@gmail.com, bilgehanerkut@yahoo.com, k.yasin_ssb@hotmail.com, yahyaunlu@hotmail.com

Abstract Text

Abstract

Objectives

In patients with trauma patients, subcutaneous injuries are quite common. In these injuries, vascular injuries are seen at a significant rate and cause dysfunction and loss of extremity. The aim of this study is to retrospectively analyze the treatment modalities of the patients who applied to our clinic and intervened.

Method

A total of 201 patients were operated for lower extremity trauma in our clinic between March 1990 and November 2018. These patients were examined retrospectively with all follow-up parameters.

Results

168 (83.5%) of the patients were male and 33 (16.5%) were female and the mean age was 33.4 years. In etiology, cutter penetrating tool traumas were in the forefront in males and 50.5% (85 patients) of the patients and the etiology of 57.5% (19 patients) were blunt traumas in females. Among the other etiological factors, gunshot injury was detected in 34.5% of males (21 patients) and 21.2% (7 patients) in males. In total, 91 patients (45.2%) were the first patients with stab wounds. Gunshot injuries were seen in 65 patients (32.3%) and in 36 patients (17.9%). 3 of our patients had iatrogenic injury while surgery was performed by another clinic. As the localization of the injury, the most frequently injured femoral artery was 43.2%. This was followed by popliteal artery (27.3%) and posterior anterior peroneal artery (23.8%). In addition, the injuries in the iliac vessels with 5.4% were rarely seen. Revascularization was the most preferred method by using saphenous vein in 107 (53.2%) cases. In 73 patients (36.3%), primary (end-to-end) anastomosis and 15 patients (7.4%) were used. In 6 patients, ligation had to be applied. Patients underwent fasciotomy due to compartment syndrome. Amputation was performed in 6 cases. Fifteen of the patients had mortality (7.4%) because they were associated with major systemic trauma.

Conclusions

In particular, lower extremity vascular injuries are associated with vascular hemorrhage and other organ injuries, which may lead to greater mortality and loss of extremity than vascular injuries in the upper extremity. Mortality and morbidity can be reduced by early and appropriate intervention to replace serious volume loss of the patients.

ID: 259

Topic: **Cardiovascular Surgery » Peripheral Artery Disease and Treatment**Presentation Type: **Oral****UPPER EXTREMITY VASCULAR INJURIES AND TREATMENT APPROACHES****Ferhat Borulu, Yahya Ünlü , Hatice Işıl Dayı, Azman Ateş***Atatürk University Faculty Of Medicine, Erzurum, Turkey***Corresponding Author (fborulu@gmail.com)**fborulu@gmail.com, yahyaunlu@hotmail.com, isilcucen@hotmail.com, azmanates@atauni.edu.tr***Abstract Text****Objectives:**

Although upper extremity vascular injuries do not pose a life-threatening injury, they may cause high morbidity in the long term if there is nerve and tendon damage. These injuries result in serious loss of function and loss of extremities. The aim of our study is to examine the patients who have applied upper extremity vascular injury and to examine and share their treatment methods.

Method:

Between January 1983 and November 2018, 196 patients treated for upper extremity vascular injuries in our clinic were examined retrospectively.

Results:

43 (21.9%) of the patients were female and 153 (72.1%) were male. The mean age of the patients was 38.4 years. Of the causes of injury, 71.4% were injured by stab wounds (140 patients), 17.3% by blunt trauma (34 patients), 7.1% by gunshot injury (14 patients) and 4.2% by injury. work accident (8 patients). The time interval between the occurrence of admission and admission to our hospital ranged from 2 hours to 72 hours (mean 6.1 hours). The most frequent localization of the brachial artery in 90 patients (45.9%), the radial and ulnar artery in 68 patients (34.6%), subclavian artery in 15 patients (7.6%), axillary artery in 16 patients (8.1%) Axillary vein injury was present in 7 patients (3.5%). The most common surgical interventions were primary repair in 98 patients (43.8%), saphenous vein revascularization in 88 patients, anastomosis with synthetic grafts in 7 patients (32%) and ligation in 3 patients (5.4%). Two patients who had a gunshot wound were forced to undergo amputation. Fasciotomy was performed in 4 patients due to compartment syndrome. The limb salvage rate was 98.9%.

Conclusions:

Early and appropriate surgical intervention in the upper extremity peripheral vascular injuries, closure of the blood and volume gap, peroperative and postoperative debridement of necrotic tissues, appropriate medical interventions will reduce serious morbidity and mortality, especially the loss of limb.

ID: 254

Topic: **Cardiovascular Surgery » Peripheral Artery Disease and Treatment**Presentation Type: **Oral****ARTERIAL COMPRESSION SYNDROMES: A DIAGNOSTIC AND THERAPEUTIC DILEMMA****Yigit Akcali, Rukiye Derin Atabey, Aydin Tuncay, Halis Yılmaz, Cihat Atabaş***Erciyes University, Kayseri, Turkey***Corresponding Author (yigitakcali@gmail.com)**yigitakcali@gmail.com, rukiyeatabey@hotmail.com, atuncay@erciyes.edu.tr, halisy38@hotmail.com, h.c.atabas@gmail.com***Abstract Text****OBJECTIVE**

Arterial compression syndromes (ACSs) are caused by compression of the arteries in a limited anatomical area of the thoracic outlet, abdomen or extremities in otherwise healthy young patients and may lead to arterial ischemia and embolism. Most arterial compression is associated with the underlying anatomical abnormality. Treatment is surgical and medical. We presented a versatile analysis of our patients with ACS in diagnosis and treatment.

METHODS

In the last decade, 45 patients (28 females, 17 males) with median age of 32.2 years (age range, 4 months-63 years) were reviewed (Table I). The rate of ACS was lower among the other vascular compression syndromes (29.0%). Scher classification was used for arterial thoracic outlet syndrome (ATOS). Adson, Wright, Roos, Spurling, Allen tests were performed and capillary re-filling time (CRT) was measured; and radiography, ultrasonography, magnetic resonance angiography, computed tomographic angiography and contrast arteriography were used (Figure 1, 2). The patients were treated conservatively and surgically.

RESULTS

ATOS had the highest rate among ACS (57.8%). The female-to-male ratio was 5.5 / 1. The median age was 33.5 years (range, 12 to 63). All patients were congenital TOS. ATOS and neurogenic TOS were associated in three patients. The ratio of ATOS to all TOS patients was 27.6%. In Scher's classification, about half of patients with ATOS were stage 0. The patients with stage I ATOS and II presented with ischemic findings in the arm due to brachial embolism. Two of the nine patients with popliteal artery entrapment syndrome were treated surgically. Allen test was positive in all four male patients with hypothenar hammer syndrome (HHS) and their CRT > 2 sec. One patient with HHS underwent aneurysmal excision and reconstruction. The other ACSs that were followed conservatively were uneventful.

CONCLUSIONS

Arterial compression syndromes occur due to external compression causing thrombus, embolism and ischemia. When the correct diagnosis and treatment is performed, its long-term negative consequences can be avoided.

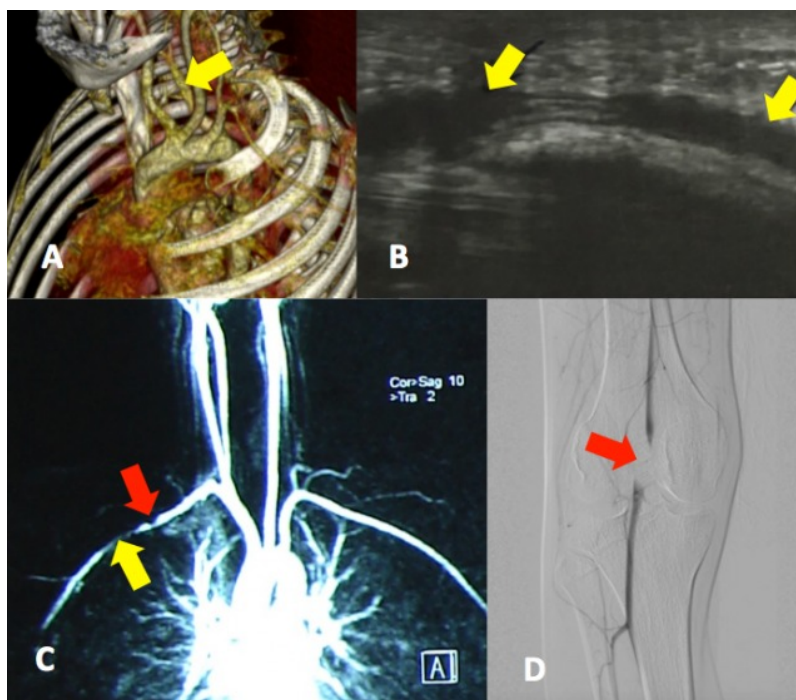


Figure 1. Diagnostic modalities in patients with arterial compression syndrome. A CT scan (VRCT) showing retrotracheoesophageal abnormal right subclavian artery in a 2-year-old patient with a dysphagia lusoria (A). Ultrasonography showing thrombosed ulnar arteries in a patient with hypothernar hammer syndrome (B). MR angiography demonstrates irregularity and narrowing in the right subclavian artery of a 31-year-old patient with arterial thoracic outlet syndrome (C). A DSA shows occlusion of the right popliteal artery in a 17-year-old patient with popliteal artery entrapment syndrome (D).

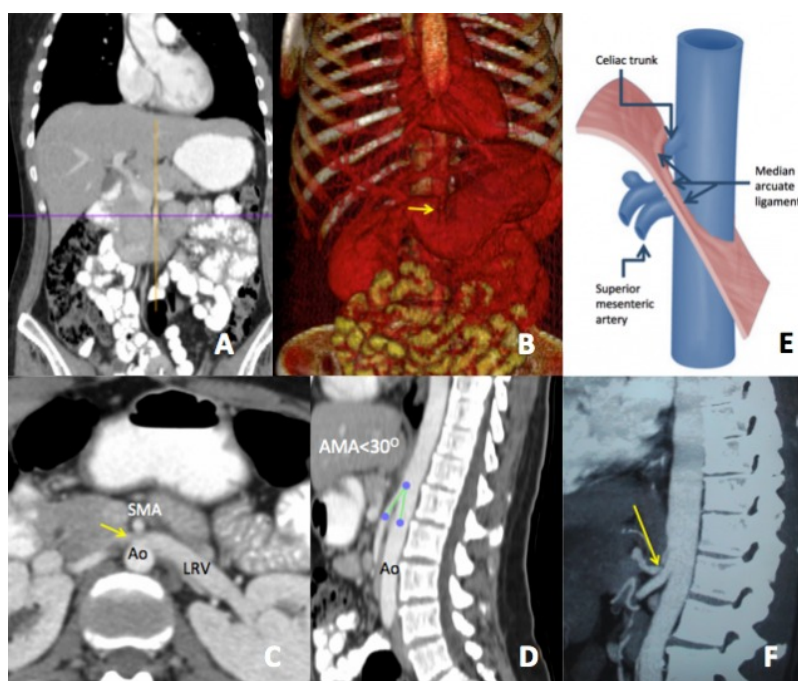


Figure 2. CT angiography (3D MPR and 3D VR) showing the compression of the third part of the duodenum between the SMA and the aorta in a 33-year-old woman with superior mesenteric artery syndrome (A, B). The same patient also had a concomitant nutcracker syndrome. Note that the LRV is compressed in the highly narrowed AMA (here 28o) and the dilated left ascending lumbar vein (C, D). Note that the origin of the celiac artery shows a characteristic “hooked appearance” due to the indentation of the celiac trunk on its superior surface in a 45-year-old male patient with median arcuate ligament syndrome (E, F). SMA = superior mesenteric artery, Ao = aorta, LRV = left renal vein; AMA = aorto-mesenteric angle.

ID: 150

Topic: **Cardiovascular Surgery » Peripheral Artery Disease and Treatment**Presentation Type: **Oral****OUR EXPERIENCE IN VASCULAR TRAUMA****Berke Özkan, Gökçen Özkan***Mardin Devlet Hastanesi, Mardin, Turkey***Corresponding Author (ozkanberke@gmail.com)**ozkanberke@gmail.com, ozserimgokcen@gmail.com***Abstract Text**

Vascular trauma involves acute force injuries to usually normal and healthy vessels, with typically very short time intervals for diagnosis and intervention. Exposure, and management principles are similar to those of elective vascular surgery, there is often not enough time to make a complete evaluation for patient. Surgeon must act quickly and definitively often having little or incomplete information, and therefore, a tough knowledge of the natural History of vascular wounds is critical to success or failure of treatment.

Major vascular trauma is commonly associated with hemorrhage, and first foundations of medical and surgical practice evolved around the control of bleeding. The mainstay for therapy of visible vascular injuries from the earliest medical history was the application of topical treatments, including bandages, styptics, and cauterly.

The experiences reported from the major modern conflicts starting with World War I provide a highlight of the evolution in vascular trauma management. Although vascular repair and techniques for anastomoses or interposition grafts had been well described by the turn of the century, the lack of adequate equipment and training and the high incidence of complications prevented widespread acceptance. An additional factor in determining candidacy for repair and particularly limb salvage is the time from injury to treatment which is strongly related with amputation rates. In Mardin State Hospital between January 2016 and January 2018 we treated 69 vascular trauma patients. 29 of them were arterial firearm/combat-battlefield injury which includes shotgun injuries and 32 of 20 were lower extremity arterial injury which we made 5 of them femoro-popliteal bypass with autologus graft and 6 were upper extremity arterial injury which we primary repaired and none of them gone to amputation. 32 of 3 were proximal groin/axillary artery injury that we made subclavian-axillary artery bypass with autologus vein graft and 1 of them iliac artery injury and 2 of them were throcal injury implicates aortic injury whom were resusitated in emergency room because of massive noncompressible hemorrhage whom also gone postoperative exitus. 69 of 27 were penetrating type of vascular injury which suffer of cuts from glass or sharp debris, and puncture by fractured bone fragments whom we applied primary arterial repair. 69 of 13 were major vascular injury related with motor vehicle collision, and injury to the vessel typically results from stretching and shearing forces or from vascular avulsion. 13 of 5 of them were upper extremity trauma and 5 of 3 of them were total upper extremity amputation in emergency room application. We revascularized 1 of them and gone amputation 1 day later. 13 of 8 were lower extremity injuries and all of them had a high MESS score (>7) and we revascularized all of 8 and 6 of them were gone to amputation in the follow up.

ID: 533

Topic: **Cardiovascular Surgery » Risk Management in Cardiovascular Diseases**Presentation Type: **Oral****BALLISTIC GEL BASED LOWER EXTREMITY SURROGATE AND NEXT GENERATION TOURNIQUET (HAYAT) DEVELOPMENT FOR EXTREMITY VASCULAR INJURIES: NULLIFYING AN UNACCEPTABLE, PREVENTABLE CAUSE OF DEATH**Aytekin Unlu, Sahin Kaymak, **Gokhan Arslan**, Nazif Zeybek, Bilgehan Savas Oz*University of Health Sciences /Gulhane school of medicine , Ankara, Turkey**aytekim@gmail.com, sahin kaymak@hotmail.com, drgokhanarslan@gmail.com, nzeybek@hotmail.com, bilgehansavas.oz@sbu.edu.tr***Abstract Text**

OBJECTIVE:

Turkish military trauma data show that extremities continue to be the most common sites of injury (%64). Potentially survivable hemorrhage related cause of death has been reported to occur in 13.3% of extremity injuries (third most common) and Turkish data show that 16.6% of casualties had associated extremity vascular injuries that required tourniquet application.


METHODS:

Having encountered extremity hemorrhage related mortalities in the prehospital period, a military tourniquet project has been started at the Gulhane War Surgery Department. The project involved studying the global and Turkish military tourniquet types. The study showed the most prevalent tourniquet in Turkish military was Combat Application Tourniquets (CAT). The project also involved prospective randomized tourniquet trials to establish training goals, developing ballistic gel based extremity surrogates for tourniquet studies, and also start a novel Smart Tourniquet System (HAYAT- TUBITAK, Gulhane Harp Cerrahi BD, TOBB Biyomedikal Mühendisliği AD, ASELSAN) development for Turkish security forces.

RESULTS:

Initially, a prospective, randomized study involving 102 trainees from a tank battalion was performed in pre-training, after-training and eyes-closed phases. The overall tourniquet success rates were 69.6%, 82.4% and 91.2%, respectively. The application times improved significantly. However, a negative significant relationship was found between the extremity circumference (lower extremity) and tourniquet success. Another prospective randomized study was performed to define an ideal range of wind-lass turn degrees for attaining a 100% tourniquet success rate. A 11700 turn degree was required for 100% success rate, which depended on how tight the soldiers applied their tourniquets. Our next generation tourniquet system (HAYAT) is pressure controlled and it transmits data upon activation. Before testing HAYAT a 250-Bloom gelatin-based lower extremity surrogate was created with bony and vascular structures. Tests proved that our gelatin sample possessed similar values to human muscle tissue, X-ray features were also comparable to humans. Vascular structures were also tested for blood circulation, which resembled human limbs. (Picture 1) The prototype HAYAT tourniquet was successfully tested on the phantom. Clinical trials are currently being planned.

CONCLUSION: Weapons systems are getting smarter and more powerful. In such an environment, HAYAT aims to nullify the extremity hemorrhage mortalities, which potentially will increase the vascular repair procedures in Turkish trauma hospitals.



ID: 534

Topic: Cardiovascular Surgery » Risk Management in Cardiovascular Diseases

Presentation Type: Oral

OUR ABDOMINAL VASCULAR INJURY EXPERIENCES INFLICTED BY HIGH ENERGY PENETRATING MECHANISMS

Sahin Kaymak, Aytekin Unlu, Gokhan Arslan, Bilgehan Savas Oz

University of Health Sciences Gulhane School of Medicine, Ankara, Turkey

**Corresponding Author (sahinkaymak@hotmail.com)*

sahinkaymak@hotmail.com, aytekim@gmail.com, drgokhanarslan@gmail.com, bilgehansavas.oz@sbu.edu.tr

Abstract Text

OBJECTIVE: Abdominal vascular injuries are uncommon, potentially lethal and primarily occur due to penetrating mechanisms. Improved trauma system organization, recognition and resuscitation of hemorrhagic shock in the prehospital period have increased the number abdominal vascular surgery procedures in our hospital. We retrospectively analyzed gunshot wounds to the abdomen with vascular injuries.

METHOD: We retrospectively reviewed 210 abdominal gunshot injury cases between 2008 and 2018. The collected data comprised age, sex, type of weapon used, injured organs and vascular structures and associated injuries, and surgical procedures performed.

RESULTS: Male patients comprised 95.2% of casualties, mean age was 28 (min-max, 28-68). Data revealed that 45 patients (21.4%) inflicted associated abdominal vascular (AAV) injuries. Hemodynamic instability (systolic blood pressure < 90 mmHg at presentation) was present in 90% of these AAV casualties at the time of presentation and were performed emergency laparotomies. In 21 (47%) casualties, stable retroperitoneal hematoma was present. Eight (18%) patients presented with inferior v. Cava, 3 (7%) common iliac artery, 5 (18%) common iliac vein, 4 (9%) splenic artery, 2 (4%) splenic vein, 3 (7%) middle colic artery, 3 (7%) renal vein, and 3 (7%) abdominal aorta injuries were present. Associated intra abdominal organs were; 19 cases with small bowel, 14 cases with colon, 7 cases with liver, 9 cases with spleen, 5 cases with pancreatic, and 7 cases with gastric injuries. In eight patients with inferior caval vein injuries, one with patchplasty and 7 were treated by primary repair. All abdominal aorta injuries expired during the surgery. Common iliac veins were repaired primarily, 2 common iliac artery injuries were treated by graft interposition and 1 was repaired primarily. Cases with splenic artery and vein injuries were treated with splenectomy, 3 patients with renal vein injuries were treated nephrectomy and 3 patients with middle colic artery injuries were treated with ligation (Table 1).

CONCLUSION: Early recognition of shock, fast transport, better prehospital volumere suscitation decreases the mortality and morbidity rates of vascular injuries. Addition of endovascular repair capabilities in the operating theater and recent addition REBOA to our armamentarium will further add to our success rates.

Table 1. Number of gunshot wounds and treatments.

Vascular injuries	Number of vascular injuries in 45 patients.	Treatment
Retroperitoneal hematoma	21	Non surgery repair (21)
Inferior v. cava	8	Primary repair (7) / Patch-plasty(1)
Common iliac vein	5	Graft interpos.(2) / Primary repair(1)
Renal vein	3	Primary repair (5)
Abdominal aorta	3	Nephrectomy (3)
Middle colic artery	3	Primary repair (3)
Splenic artery	4	Splenectomy (4)
Splenic vein	2	Splenectomy (2)
Total vascular injuries	52	

Oral Presentations

Alternative Strategies in Cardiovascular Surgery

Date: 29.03.2019 Time: 09:00 - 10:00 Hall: 6

ID: 515

Topic: **Cardiovascular Surgery » Coronary Bypass Surgery**

Presentation Type: **Oral**

ALTERNATIVE VEIN GRAFT IN CABG: NATURAL Y SAFEN VEIN?

Murat Ercişli¹, Ayda Aybars Pala¹, Serkan Ketenciler², Birol Yamak³

¹*Adiyaman University, Adiyaman, Turkey*

²*SBU Okmeydanı EAH, İstanbul, Turkey*

³*Gaziantep Medical Park Hospital, Gaziantep, Turkey*

**Corresponding Author (mercisli@gmail.com)*

mercisli@gmail.com, aydaaybars@gmail.com, ketencilers@hotmail.com, birolyamak@gmail.com

Abstract Text

OBJECTIVE: Post-operative cardiac event-free survival is a valuable indicator in the clinical evaluation of graft patency in coronary artery bypass surgery. In this study, we aimed to evaluate the graft patency of multi-vessel CABG patients who underwent sequential anastomoses and natural Y saphenous vein graft anastomoses.

METHODS: A total of 80 patients who underwent isolated coronary artery bypass graft surgery were included in the study. The patients were divided into two groups as the sequential vein anastomoses group Group 1 (n = 40) and the natural Y saphenous vein graft Group 2 (n = 40). Off-pump CABG patients were excluded from the study. The groups were compared in terms of preoperative, intraoperative and postoperative data, postoperative cardiac symptoms, interference and event free survival. Symptomatic patients underwent emergency / elective coronary angiography. In terms of these results, the patency of saphenous vein grafts which are anastomosed with different configurations was investigated.

RESULTS: No statistically significant difference was found between the groups when the patients were evaluated for the first 30-day mortality, cardiac symptoms after discharge, post-operative cardiac intervention, and post-operative cardiac event-free survival (p> 0.05).

CONCLUSION: The data obtained from our study showed that in addition to sequential anastomosis technique, natural Y saphenous vein graft can also be used safely in cases where venous graft is limited for various reasons.

ID: 292

Topic: **Cardiovascular Surgery » Research**Presentation Type: **Oral****AMINOACID ENRICHED CARDIOPLEGIA DECREASED THE AMOUNT OF INTRAMYOCARDIAL LEUCOCYTES IN CORONARY ARTERY BYPASS GRAFTING SURGERY.****Ömer Faruk Doğan, Kevser Tural***Kars Kafkas University School of Medicine, Kars, Turkey***Corresponding Author (ofdogan@hacettepe.edu.tr)**ofdogan@hacettepe.edu.tr, ktr12011@hotmail.com***Abstract Text**

Background: In this prospective placebo controlled study, we investigated the potential effects of amino acids (L-glutamate and L-aspartate) enriched tepid blood cardioplegia (GAETBC) administration on myocardial PMNL accumulation using a radionuclid method. We also researched the relationship between PMNL accumulation and myocardial performance in isolated coronary artery bypass grafting (CABG) patients who have low ejection fraction.

Patients and Methods: One-Hundred CABG patients were included into this study. The patients divided into two groups. Amino acids (L-aspartate and L-glutamate, at a dose of 13 milimol/l) enriched tepid blood cardioplegia was used in fifty patients (Study group, G1). In the remaining patients, we used a standart cold blood cardioplegia (Control group, G2). Myocardial Tru-Cut biopsy from the right ventricle was taken before the institution of CPB. The second myocardial biopsy was taken after weaning from CPB. Cardiac troponin-I (cTn-I), tumor necrosis factor alpha (TNF-Alpha), Pro-Brain Natriuretic Peptide (Pro-BNP), and lactate levels were measured pre- and postoperative periods. We compared myocardial PMNL levels (pre- and post-CPB), ventricular contractile functions including cardiac indices (CI), Pulmonary capillary wedge pressure (PCWP), and Systemic vascular resistance index (SVRI), pulmonary and left ventricular stroke work index (LVSWI) were compared.

Results: Myocardial biopsy results showed that PMNL accumulation was significantly high in G2 ($p=0.001$). The requirement of inotropic agent was also significantly high in G2. Cardiac Troponin-I levels were significantly high in G2 than the study group (0.66 ± 0.32 vs. 0.34 ± 0.19) ($p = 0.01$). Two hours later weaning from ECC, LVSWI, CI, and the heart rate were significantly high in G1. Blood gas analyses showed that myocardial acidosis was more severe in G2 [pH (0.10 ± 0.09 vs 0.054 ± 0.001 ; $p = 0.34$)]. Lactate levels were also more higher in G2 patients (1.01 ± 0.007 vs 1.92 ± 0.35) ($p = 0.22$).

Conclusion: Our study findings show that glutamate-aspartate enriched tepid blood cardioplegia significantly decrease in myocardial white blood cell accumulation. Therefore, aminoacid riched cardioplegia may be use to increase LVSWI and CI in patients who have poor left ventricle, and to inhibite myocardial infarction peroperatively

ID: 473

Topic: **Cardiovascular Surgery » Coronary Bypass Surgery**Presentation Type: **Oral****SIMULTANEOUS CAROTID ENDOARTERECTOMY AND CORONARY ARTERY BYPASS GRAFTING: OUR CLINICAL EXPERIENCE WITH 153 PATIENTS**Gökhan Erol¹, **Celal Selçuk Ünal**, Hüseyin Sicim¹, Ufuk Mungan³, Furkan Burak Akyol¹, Kaan Yurtseven¹, Ertan Demirdaş¹¹*Gulhane Training and Research Hospital , Ankara, Turkey*²*Karabük Training and Research Hospital , Karabük, Turkey*³*Akay Hospital , Ankara, Turkey***Corresponding Author (drgokhanerol@gmail.com)**drgokhanerol@gmail.com, drselcukunal@yahoo.com, drhuseyinsicim@gmail.com, drumungan@gmail.com, akyolburak19@gmail.com, kaanyurtseven.md@gmail.com, dr.ertandemirdas@gmail.com***Abstract Text****Introduction:**

The optimal surgical strategy for the patients who have both coronary artery disease and carotid artery disease is controversial. The aim of this study was to review our experience on simultaneous carotid endarterectomy patchangioplasty and coronary artery bypass grafting (CABG) with cardiopulmonary bypass.

Methods:

This study included 153 patients whom underwent simultaneous carotid endarterectomy patchangioplasty and CABG surgery at Cardiovascular Surgery Clinic of Akay Hospital between May 2009 - June 2014. 117 of these 153 patients had 3-vessel disease. Carotid endarterectomy was indicated for patients who are symptomatic or asymptomatic with a decrease more than 70% in lumen diameter of the vessel and/or ulcerated/unstable plaque. At first carotid endarterectomy with shunt and patch angioplasty was performed, then CABG was performed with cardiopulmonary bypass with moderate hypothermia under heparinization, hemodilution and pulsatile perfusion for additional cerebral protection.

Results:

The mean age of the patients was 68.6±8.3. 117 of patients were male while 36 of them were female. 45 (29.4%) of the patients had stenosis on the right, 38 (24.8%) of the patients had on the left carotid artery while 70 (45.8%) of the patients had bilateral carotid arteries. 11 (7.1%) of the patients had previous history of carotid endarterectomy and 21 (13.7%) of them had their contralateral carotid artery fully blocked. 27 (17.6%) of the patients had a history of stroke while 92 (60.1%) of the patients were asymptomatic. 5 (3.2%) of the patients had developed neurological complication perioperatively but only 1 of them was permanent. 30-day postoperative mortality rate was 2.6% (4 patients).

Conclusion:

In conclusion, simultaneous carotid endarterectomy patch angioplasty and myocardial revascularization could be an appropriate treatment of the severe lesions of the both arterial systems. In this study we've concluded that carotid endarterectomy patch angioplasty and CABG surgeries could be applied simultaneously with acceptable morbidity and mortality rates.

ID: 290

Topic: **Cardiovascular Surgery » Coronary Bypass Surgery**Presentation Type: **Oral****SIMULTANEOUS CORONARY ARTERY BYPASS GRAFTING AND ABDOMINAL SURGERY****Ömer Faruk Doğan¹, Ümit Duman², Kevser Tural¹, Atif Akçevin⁴**¹*Kars Kafkas University School of Medicine, Kars, Turkey*²*Koç Vakfı Amerikan Hastanesi, İstanbul, Turkey*⁴*Koc University School of Medicine, İstanbul, Turkey*^{*}*Corresponding Author (ofdogan@hacettepe.edu.tr)**ofdogan@hacettepe.edu.tr, umit_duman@hotmail.com, ktr12011@hotmail.com, atif.akcevin@koc.edu.tr***Abstract Text**

Background: There have been only a limited number of reports of simultaneous coronary artery bypass grafting (CABG) and cholecystectomy in patients with cholelithiasis. To our knowledge, there is no report in the early after percutaneous coronary intervention (PCI) and cholecystectomy. We present clinical outcomes of coronary artery disease (CAD) patients who underwent synchronous laparoscopic cholecystectomy (LC) and revascularization procedures using CABG or PCI.

Patients and Methods: We performed simultaneous LC in selected 19 CAD patients (male/female: 12/7) who requiring coronary artery revascularization between January 2008 and June 2016. Cholelithiasis has been detected using an ultrasonographic examination in all patients. Thirteen patients have previously been hospitalised due to acute cholecystitis in another hospital. The mean age of patients was 53±11.6 year (49-72 year). Synchronous CABG and LC was performed in 10 patients (Group I) (the mean age was 56±7.8 year) (55- 72 year). PCI (Group II) was performed using a paclitaxel-coated balloon (PCB) or plain old balloon angioplasty (POBA) in 6 patients. Drug eluting stent (DES) was used in the remaining three patients (the mean age was 49±9.8 year) (41-69 year). Immediately after CABG, LC was performed at the same time in the operating room. In PCI group, LC was performed under general anaesthesia two or three days later PCI.

Results: No mortality or morbidity was seen after revascularization in CABG and PCI group. The mean number of by-pass grafts was 3.4±1.9 in CABG group. The mean number of stent use was 2.1±0.7 in PCI group. The mean left ventricular ejection fraction (LVEF) was 54±5.9 %. In CABG group, the mean extracorporeal circulation and total operation time were 95±13.5 min., and 259±18.9 min., respectively. The mean intubation time was 17±4.8 hours in CABG group. In PCI group, LC has been performed under general anaesthesia without the cessation of clopidogrel (75 mg daily) and acetylsalicylic acid (ASA) (100 mg daily) two or three days later after revascularization. The mean operation time of LC was 56.5±15.6 min. in CABG group, and 51.3±17.6 minutes in PCI group (P=0.86). The mean intensive care unit (ICU) staying time was 3.1±1.4 days, and the mean postoperative hospital stay was 14.2±3.7 days in CABG group. In PCI group, the mean ICU stay time was 1.7±0.4 days, and the mean hospital staying time was 7.4±2.2 days. When compared to intubation time, ICU stays time and hospitalisation periods there were significant differences between the two groups (P1=0.001); (P2=0.0001). The mean hospitalisation time was significantly high in CABG group (P=0.001). No intra-abdominal complications were seen in both groups including bleeding and infection in both groups. Postoperative wound layer complications or mediastinitis were not seen in the setting of concomitant procedures in CABG group.

Conclusion: Simultaneous CABG or PCI (without cessation of dual antiplatelet treatment) and LC may be performed safely in patients with cholecystitis in selected patients. No bleeding was detected during and after surgery in both groups. Post-cholecystectomy ICU staying and intubation time was significantly low in PCI group. Therefore, PCI can be the first choice of safe revascularization procedure in selected CAD patients who have to require cholecystectomy prior to discharge from the hospital.

ID: 408

Topic: **Cardiovascular Surgery » Hybrid Cardiovascular Surgery**Presentation Type: **Oral****COEXISTENCE OF LOWER EXTREMITY EMBOLICTOMY AND PERIPHERAL ENDOVASCULAR PROCEDURES: GREAT RESULTS****Mustafa Dağlı***University of Health Sciences Konya Education And Research Hospital, Konya, Turkey***Corresponding Author (drmustafaaaa@gmail.com)**drmustafaaaa@gmail.com***Abstract Text****AMAÇ:**

Amacımız, akut alt ekstremitte iskemisi ile başvuran hastalarda eş zamanlı periferik endovasküler işlemlerin embolektomi ile yararını değerlendirmektir.

YÖNTEMLER:

Ocak 2016 ve Ocak 2019 arasında, akut alt ekstremitte embolisi için hibrit prosedür uygulanan 48 hasta (35 erkek, 13 kadın; ort. Yaş 69; dağılım 39-94) retrospektif olarak değerlendirildi. Tüm hastalar endovasküler tedavi ile tedavi edildi, embolektomi kateteri Fogarty distal olarak ilerlemiyordu.

SONUÇLAR

En sık görülen tromboembolizm lokalizasyonu femoropopliteal bölge (% 54.1) idi, sıklıkla kalp patolojileri (% 70.8) gördük, 21 hasta (% 45.8) ilk 6 saat içinde hastaneye yatırıldı.

Hastaların damar çaplarını eşleştirmek için poplitea, femoral arter ve diz altındaki iliak arterlere 3 ana damar sığdırmak için farklı çap ve uzunluktaki balonlar kullanıldı. Periferik balon anjiyoplasti, 48 hastaya 217 kez yapıldı. 2 hastada önceki işlemlere bağlı arteriyovenöz fistül gözlemlendi. Kaplanmış stentlerle tedavi edildi. Periferik stent 17 hastaya yerleştirildi (% 35.4). Plak yükü almak için 11 hastaya (% 22.9) atherektomi yapıldı. Hibrit işlem sırasında 7 hastaya (% 14.5) trombolitik tedavi uygulandı. İşlem sonrası, çift anti-trombosit tedavisi alan tüm hastalara yüksek doz statin tedavisi verildi.

Üç hastada (% 6.25) majör ve minör amputasyon yapıldı. 2 hastada (% 4.16) kalp patolojileri nedeniyle ölüm meydana geldi.

SONUÇLAR

Akut periferik arter tıkanıklıkları tanı ve tedaviye geç kaldıklarında mortalite ve morbiditenin yüksek olduğu klinik bir tablodur. Erken operasyonda hibrit prosedürlerin kullanılmasının yanı sıra ameliyatın da hastalara fayda sağlayacağı açıktır.

ID: 538

Topic: **Cardiovascular Surgery » Hybrid Cardiovascular Surgery**Presentation Type: **Oral****HYBRID APPROACH IN AORTIC ARCH DISEASES****Grigore Tinica¹**, Mihail Enache¹, Raluca Chistol¹, Cristina Furnica²¹*Cardiovascular Institute, Iasi, Romania*²*University of Medicine and Pharmacy, Iasi, Romania***Corresponding Author (grigoretinica@yahoo.com)**grigoretinica@yahoo.com, enackemisha@gmail.com, ralucachistol@gmail.com, cristinafurnica@yahoo.com***Abstract Text**

Aortic arch diseases mainly include aneurysmal dilatations, dissections and traumatic ruptures. Conventional repair has been the „gold standard” procedure for a long period of time and is the most complex arterial repair associated with high exclusion (20-40%) and mortality rates (5-15%). The aortic arch poses great technical and technological difficulties because of the angulations, the origin of the supra-aortic trunks, cerebral protection (the major cornerstone of aortic arch surgery), severe atherosclerosis and the proximity of the aortic leaflets. The emergence of endovascular procedures changed the therapeutic management strategy towards a completely endovascular or a hybrid approach combining endovascular exclusion of the affected area and debranching of supra-aortic trunks. In the current paper, the authors present their experience in preoperative evaluation, decision-making process, surgical alternatives and circulation management strategies for patients with aortic arch diseases depending on the involved zones together. There are evaluated 4 representative cases, 1 patient with traumatic rupture of the aortic isthmus, 1 patient with aorto-esophageal fistula and 2 patients with aortic arch aneurysms managed by endovascular or hybrid repair at the Institute of Cardiovascular Diseases from Iasi, Romania. In the former two cases, endovascular treatment was combined with complete arch debranching (Dacron graft sutured onto the ascending aorta from which branches to supra-aortic trunks arise) and left common carotid artery-left subclavian artery transposition with good long-term results. The slightest aggressiveness of endovascular techniques allows the treatment of high-risk patients for whom an open technique is contraindicated. A good collaboration between interventional cardiologists, cardiovascular surgeons, anesthesiologists and radiologists is essential to optimize the surgical choices.

ID: 531

Topic: **Cardiovascular Surgery » Coronary Bypass Surgery**Presentation Type: **Oral****ISOLATED CHYLOPERICARDIUM FOLLOWING CORONARY ARTERY BYPASS SURGERY: A RARE COMPLICATION OF A COMMON PROCEDURE****Ömer Faruk Çiçek, Ibrahim Enes Özdemir***Selçuk University School of Medicine, Konya, Turkey***Corresponding Author (farux@hotmail.com)**farux@hotmail.com, ibrahimenesozdemir@hotmail.com***Abstract Text****Introduction:**

Chylous trunk injury is an uncommon complication of cardiovascular surgery, yet more extraordinary after coronary artery bypass grafting through a median sternotomy without left internal mammarian artery harvesting. Rate of chylous injuries differentiate between 0.25% to 0.5% for all types of cardiothoracic surgical procedures. Herein we present a case of a 78-year-old male patient who underwent coronary artery bypass grafting surgery via median sternotomy for triple-vessel disease without left internal mammarian artery harvesting developed isolated chylopericardium in the early postoperative period.

Case report:

The patient's medical history was notable for hypertension and chronic kidney disease without dialysis. Under general anesthesia median sternotomy followed by standard aortocaval cannulation was performed and cardiopulmonary bypass was established. Left internal mammarian artery was not harvested and thus both pleuras were intact. The patient underwent routine coronary artery bypass grafting with four saphenous veins after cross-clamping aorta. The course of the operation was uneventful along with the sternotomy was closed successfully with surgical routine. The patient was extubated on the first postoperative day and inconsiderable amount of hemorrhage came from mediastinal drains in the first two days of intensive care unit, however on his postoperative 3rd day milky-white fluid appeared in mediastinal drains. Once we noticed chylous drainage from mediastinum, the patient's oral intake was switched to low-fat diet straight away. Surgical re-exploration was not needed and conservative approach with appropriate diet was enough to discontinue chylous drainage from mediastinum.

Conclusions:

The conservative treatment approach should be considered for a surprising chylopericardium which developed subsequent to coronary artery bypass grafting without using left internal mammarian artery.

Oral Presentations

Cardiac Tumors: Surgical Option

Date: 29.03.2019 Time: 10:30 - 11:30 Hall: 6

ID: 384

Topic: Cardiovascular Surgery » Risk Management in Cardiovascular Diseases

Presentation Type: Oral

OUR SURGICAL TREATMENT RESULTS AND EXPERIENCES IN PRIMARY HEART TUMORS; 41 YEARS OF EXPERIENCE IN 93 PATIENTS

Ahmet Aydın, Metin Demircin, Rıza Doğan, Mustafa Yılmaz, Murat Güvener

Hacettepe University, Ankara, Turkey

**Corresponding Author (ahmetcamsu@yahoo.com)*

ahmetcamsu@yahoo.com, demircin@hacettepe.edu.tr, rdogan@hacettepe.edu.tr, myilmazmd88@yahoo.com, guvener@doctor.com

Abstract Text

Our Surgical Treatment Results and Experiences in Primary Heart Tumors; 41 Years of Experience in 93 Patients

Introduction: Primary cardiac tumours are rare and Diagnosis was academic and outlook poor. With the advent of cardiopulmonary bypass, however, surgical management became possible, particularly of intracavity tumours. More recently, the development of echocardiography, computed tomography, and magnetic resonance imaging has contributed greatly to the process of preoperative diagnosis. In this single-center study we reviewed our 41 years of institutional experience with 93 patients operated for primary cardiac tumor.

Material and Methods: Of the 93 patients included in this study, 92.5% (n=86) had benign tumors and 7.5% (n=7) had malignant tumors. Benign tumors included myxomas (n=73) 78.5%, rhabdomyomas (n=9) 9.6% and papillary fibroelastomas (n=3) 3.2% and lipoma (n:1) 1.1%. Malignant tumors included angiosarcomas (n=4) 4.3% and rhabdomyosarcomas (n=2) 2.15% and primary cardiac lymphoma (n:1) 1.1%. The most frequent symptoms at admission were dyspnea (49.4%), palpitation (30.9%) and systemic embolization (14.8%). Tumors originated from the left atrium (LA) in 68 cases (73.1%), right atrium (RA) in 16 cases (17.2%), right ventricle (RV) in 5 cases (5.3%) and left ventricle (LV) in 4 cases (4.3%). The surgical approach was uniatrial in 60 patients (64.5%). Bilateral atriotomy was performed in 33 patients (35.5%). The incidence of postoperative complication was 15% (n=14).

Results: In-hospital (30 day) mortality was 5.3% (n=5). Other benign tumors and malignant tumors had poorer survival characteristics when compared to patients with myxomas.

Conclusion: Surgical resection of primary cardiac tumors with negative margins is associated with excellent long-term survival; patients with cardiac myxomas have survival characteristics that are similar to general population.

Table 1. Preoperative Characteristics

Variable	No. of Patients	%
Tumor pathology		
Myxoma	73	78.5
Rhabdomyoma	9	9.6
Papillary fibroelastoma	3	3.2
Lipoma	1	1.1
Angiosarcoma	4	4.3
Rhabdomyosarcoma	2	2.1
Primary cardiac lymphoma	1	1.1
Clinical symptoms		
Dyspnea	40	49.4
Palpitation	25	30.9
Embolic events	12	14.8
CNS	9	11.1
Peripheral	2	2.5
Pulmonary	1	1.2
Syncope	5	6.2
NYHA class		
I	36	44.4
II	29	35.9
III	12	14.8
IV	4	4.9
Tumor location		
Left atrium	68	73.1
Right atrium	16	17.2
Right ventricle	5	5.3
Left ventricle	4	4.3
Associated lesions		
Mitral stenosis/regurgitation	34	36.5
Tricuspid stenosis/regurgitation	9	9.6
Coronary artery disease	6	6.45
ASD	4	4.9

CNS, central nervous system; NYHA, New York Heart Association; ASD, atrial septal defect.

ID: 144

Topic: **Cardiovascular Surgery » Coronary Bypass Surgery**Presentation Type: **Oral****SUCCESSFUL SURGICAL EXCISION OF RARELY PRESENTING
CARDIAC ANGIOSARCOMA****Özgür Altınbaş***Training and Research Hospital, Konya, Turkey***Corresponding Author (ozgur_altinbas@yahoo.com)**ozgur_altinbas@yahoo.com***Abstract Text****OBJECTIVE**

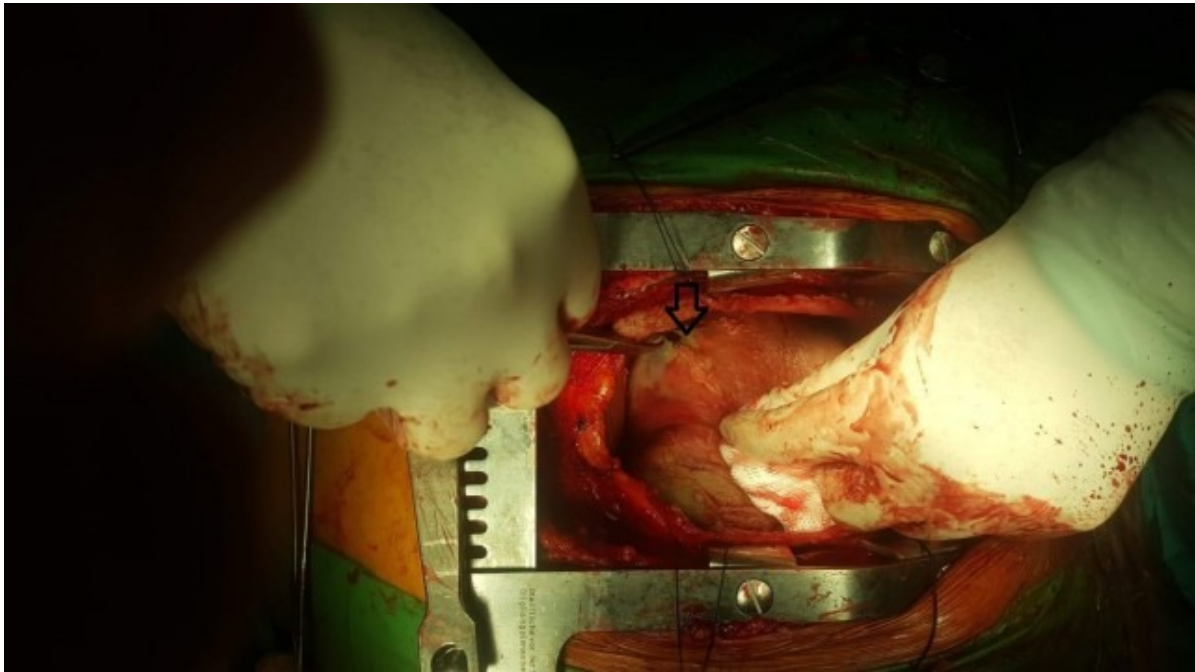
Primary cardiac sarcomas are extremely rare tumors. Angiosarcoma is the most frequent and aggressive type with a poor prognosis due to delayed diagnosis until tumor becomes untreatable and there is a high incidence of systemic metastasis at presentation. The diagnosis is often delayed because of the nonspecific clinical presentation. Symptoms differ due to the chambers and the cardiac structures involved, including dyspnea on exertion, congestive heart failure, pericardial effusion, cough, syncope, arrhythmias, pleuritic pain, fever and weight loss.

CASE REPORT

Herein we reported a 52-year-old previously healthy male who complained of dyspnea for one month and dry cough for 10 days. Transthoracic echocardiography showed a 34x42 mm intracavitary right atrial mass without the bulky, infiltrative growth typical of this location of the disease adhered to the upper lateral wall of the right atrium and prolonged to the right ventricle. After complete surgical resection the mass was confirmed to be an angiosarcoma. Postoperative third month CT revealed metastatic foci in liver without any cardiac problem and therapy was planned by oncologist for his lesion and still continues.

CONCLUSION

Primary cardiac tumors are rare but life-threatening with an incidence between 0,0017% to 0,003%. Thus early detection and aggressive treatment may lead to a more favorable outcome. A curative surgical resection may provide substantial symptom-free survival, but it has little influence on the rapid and aggressive natural course of primary cardiac angiosarcoma so additional treatment regimes including chemotherapy, radiation treatment and immunotherapy must be kept in mind.



ID: 353

Topic: Cardiovascular Surgery » Research

Presentation Type: Oral

CARDIAC TUMORS: A SPECTRUM OF PATHOLOGIES AND SCENARIOS**Mohammed Sanad***Mansoura University, Mansoura, Egypt***Corresponding Author (mohammedsanad2008@yahoo.com)**mohammedsanad2008@yahoo.com***Abstract Text**

Abstract:

Objective: Cardiac tumors are exquisitely rare, they may be symptomatic or found incidentally throughout evaluation for an ostensibly unrelated problem or physical finding. In symptomatic patients, a mass can practically always be detected by echocardiography, magnetic resonance imaging (MRI), and/or computed tomography (CT). Because symptoms may mimic other cardiac conditions, the clinical challenge is to consider the possibility of a cardiac tumor so that the appropriate diagnostic tests can be steered. The clinical scenario hangs mainly on tumor location and size rather than the histopathology. Surgical resection and prognosis is amenable in benign tumors while being very challenging in malignant tumors.

Case series: We present our case series of cardiac tumors encountered at our center throughout our experience. Forty nine Pathologies operated were 41 myxomas (5 left atrial, 33 right atrial, 2 biatrial, 1 Right ventricular outflow tract), 1 myxosarcoma, 1 thymoma, 1 hemangioendothelioma, 1 round cell tumor, 1 cardiac lymphoma, 2 rhabdomyomas and two extensions from renal cell carcinoma.

Keywords: cardiac tumor, malignancy, cardiac lesion, survival.

Figure 1: A spectrum of excised cardiac masses from our series

ID: 445

Topic: **Cardiovascular Surgery » Risk Management in Cardiovascular Diseases**Presentation Type: **Oral****A CASE REPORT OF METASTATIC TUMOR EXCISION ORIGINATING FROM MESENCHYMAL TISSUES OF ABDOMINAL WALL EXTENDING THROUGH THE INFERIOR VENA CAVA INTO THE RIGHT ATRIUM AND RIGHT VENTRICLE WHICH**

Seymur Mammadov, Seymur Musayev, Emin Gurbanov, Farid Huseynov

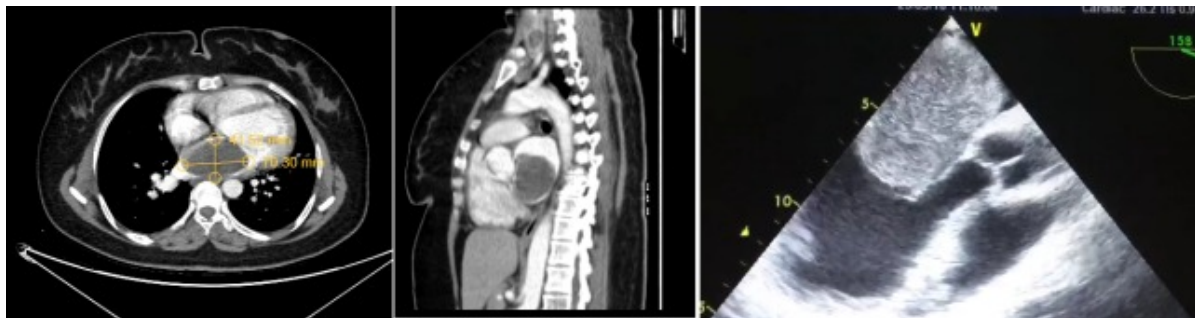
*Central Hospital for Oilworkers, Baku, Azerbaijan***Corresponding Author (emin405@hotmail.com)**emin405@hotmail.com, emin405@hotmail.com, emin405@hotmail.com, emin405@hotmail.com***Abstract Text**

Sarcomas are a heterogeneous group of rare and malignant neoplastic conditions with greater prevalence in adult male individuals. Soft tissue sarcomas correspond to 1% of malignant tumors in adults, and occurrence on the abdominal wall is considered rare as they correspond to 0.1% of malignant tumors. A 29-year-old man was admitted to a cardiovascular surgery intensive care unit complaining of mild chest pain and shortness of breath. He had progressive multiple lymphatic metastases of stage IIIB mesenchymal originated abdominal wall sarcoma that had initially been treated with concurrent chemoradiation. There were signs of renal and hepatic failure. There were signs of venous congestion in the lower half of the body. Echocardiogram showed pedunculated tumor in the right atrium (RA) and right ventricle (RV), computed tomography demonstrated the tumor mass extends from the renal vein through the inferior vena cava to the right atrium and right ventricle and vena cava inferior, renal, hepatic veins filled by metastatic tumor mass. The surgery was planned in two stages. In the first stage, tumor mass excised from the right atrium and right ventricle through the right atrial incision which was performed by cardiac surgery team through cardiopulmonary bypass extended into total circulatory arrest (TCA). The first stage operation terminated without complication. Second operation initiated 14 days after the cardiac surgery which was performed both by general and cardiac surgery team through median abdominal incision. The tumor mass was completely excised together with partly wall of inferior vena cava which was repaired using xenopericardial patch plasty technique. Second operation terminated without complication and patient was discharged from the hospital 10 days later with subsequent chemotherapy treatment.

ID: 376

Topic: Cardiovascular Surgery » Diagnosis and Treatment of Valvular Heart DiseasePresentation Type: **Oral****GIANT LEFT ATRIAL MYXOMA PRESENTING WITH COUGH- SYNCOPE SYNDROME****Esra Ertürk Tekin***Mersin City Training and Research Hospital, Mersin, Turkey***Corresponding Author (dresraer@yahoo.com)**dresraer@yahoo.com***Abstract Text****ABSTRACT:**

We report the case of 41-year-old female patient with symptoms of cerebrovascular accident manifesting with loss of consciousness during episodes of cough. Computed chest tomography showed that 7,3 cm by 4,15 cm mass in the left atrium. A transesophageal echocardiogram showed giant mass in the left atrium that passing through the mitral valve to left ventricle and was severe obstructive stenosis suggested by the mean transmitral gradient. We removed the mass, and it was determined to be an atrial myxoma. It is important for cardiac surgeons to be able to diagnose an atrial myxoma because of the risks associated with embolization and even sudden death as myxoma can block blood supply from atrium to ventricle.

Keywords: Cough- Syncope Syndrome, Myxoma, Syncope Attacks

ID: 373

Topic: Cardiovascular Surgery » Risk Management in Cardiovascular Diseases

Presentation Type: Oral

**BASIC PRINCIPLES OF DISTINCTION OF MEDICAL MALPRACTICE
WITH COMPLICATION**

Hasan Tahsin Keçeligil

Ondokuz Mayıs University School of Medicine and School of Law , Samsun, Turkey

**Corresponding Author (htkeceligil@yahoo.com)*

htkeceligil@yahoo.com

Abstract Text

The working area of the medical profession is the human body and is related to the right to life. Therefore, the responsibilities and obligations of physicians and health care providers are much higher than and above all occupations. Due to the nature of medical interventions, a harmful result may occur at any time. Despite all the necessary attention and care, the negative consequences are considered as normal deviations and risks of medical interventions. In order for the physician to be responsible, he / she must violate his / her obligations. The biggest problem here is how the physician fulfilled his obligations and in what situation he violated his obligations. At this point, one of the basic issues of medical law is the distinction between malpractice and complication. Medical malpractice is the basis of the physician's legal responsibility. In this presentation, it will be tried to clarify the characteristics of the issue of distinction between medical practice and complication with the eyes of a lawyer physician.

Keywords: Body integrity, right to live, medical intervention, medical malpractice, complication.

Oral Presentations

Perspectives in Abdominal Aortic Aneurysm

Date: 29.03.2019 Time: 11:30 - 12:30 Hall: 6

ID: 92

Topic: **Cardiology » Diseases of Aorta**

Presentation Type: **Oral**

THE DEVELOPMENT OF ABDOMINAL AORTIC DILATATION DUE TO GLUCAGON-LIKE PEPTIDE-1 REDUCTION AFTER TERMINAL ILEUM RESECTION

Mehmet Erin Tüysüz

T.C Bakanlıđı Mersin Şehir Hastanesi, Mersin, Turkey

**Corresponding Author (drmehterin@yahoo.com)*

drmehterin@yahoo.com

Abstract Text

The development of abdominal aortic dilatation due to glucagon-like peptide-1 reduction after terminal ileum resection

Abstract

Introduction: In addition to a number of known risk factors causing abdominal aortic aneurysm, it has been reported that the reduction of glucagon-like peptide-1 level leads to abdominal aortic dilatation. It is frequently released from the terminal ileum and has protective effects on the vascular system. The aim of our study was to evaluate the development of abdominal aortic dilatation in the postoperative period due to a decrease in the release of glucagon-like peptide-1 after terminal ileum resection in patients with gastrointestinal tract tumors.

Material and methods: Between January 2017 and December 2018, the data of 671 patients with gastrointestinal tract tumors were retrospectively analyzed. The patients who underwent the resection of stomach, terminal ileum and rectosigmoid region due to adenocarcinoma were included in the study. Preoperative and postoperative first year abdominal computed tomography of the patients were examined. The anteroposterior diameter of abdominal aorta in the first 3 cm distance of infrarenal level was measured and recorded. The primary interest was the comparison of abdominal aortic dilatation quantities that occurred after the different site resections in the gastrointestinal tract.

Results: 132 consecutive patients were included in the study. The mean age of patients was 60.8±11.4. The patients were divided into three groups according to the gastrointestinal tract site where tumor resection was performed. While 38 (28.8%) patients undergoing total gastrectomy were defined as the group 1, 42 (31.8%) patients undergoing terminal resection as the group 2 and 52 (39.4%) patients undergoing rectosigmoid colon resection as the group 3 were defined. There was no significant difference in aortic calcification rates in postoperative CT imaging. However, the quantity of abdominal aortic dilatation was significantly higher in terminal resection group compared to the others groups (p<0.001).

Comment: As a result of the resection of terminal ileum from which glucagon-like peptide-1 is released mostly, the vascular protective effect is eliminated due to the reduction of this hormone level and it results in abdominal aortic dilatation. Therefore, we recommend to perform vascular evaluation at the follow-up, because there is a risk of development of abdominal aortic dilatation after surgical resection in this region due to any reason.

ID: 425

Topic: **Cardiovascular Surgery » Abdominal Aortic Aneurism**Presentation Type: **Oral****OPEN SURGICAL REPAIR OF RUPTURED AAAS: A PARADIGM SHIFT FOR OPERATIVE MANAGEMENT****Yigit Akcali, Rukiye Atabey, Aydin Tuncay***Erciyes University, Kayseri, Turkey***Corresponding Author (yigitakcali@gmail.com)**yigitakcali@gmail.com, rukiyeatabey@hotmail.com, atuncay@erciyes.edu.tr***Abstract Text****OBJECTIVE**

An abdominal aortic aneurysm (AAA), which is a multifactorial disease, is the localized pathological enlargement of the aorta and can develop in both men and women. Progressive aneurysm dilatation can lead to rupture, which is the most frequent and lethal complication of AAAs. Typical clinical manifestations of patients with ruptured AAA (RAAA) include abdominal pain, pulsatile abdominal mass, back pain, hypotension and cardiac arrest (Video 1). Patients with RAAA, which require immediate open surgical (OSR) or endovascular repair (EVAR), may directly go to the operating room or endovascular suite. The management of hemorrhagic shock is accomplished by normotensive or controlled hypotension resuscitation strategies. The most important step in OSR on a patient with RAAA is a rapid, safe, and effective proximal aortic control (PAC) with a consequent reduction of blood loss. We presented our experience related to operative management of ruptured AAAs.

METHODS

In the last decade, 199 patients, 29 of whom were female (14.6%), who treated for abdominal aortic aneurysm were reviewed. Their median age was 65 years (range, 27 to 89). Congenital AAAs were excluded. Among these patients, 31 patients with ruptured AAA (RAAA) were re-evaluated for this study. Ten of them were female (32.2%), and the median age of all the patients with RAAA was 64 years (range, 30 to 84)(Figure 1). Stable patients underwent computed tomography angiography (CTA) to confirm the presence of an RAAA as well as demonstrate its extent, site of rupture, degree of iliac arterial involvement and the anatomic suitability for EVAR (Figure 2). All patients, except for one patient treated with EVAR, underwent to OSR under controlled hypotensive resuscitation. The PAC during OSR of RAAA was applied by transthoracic, supraceliac, suprarenal, and infrarenal ways.

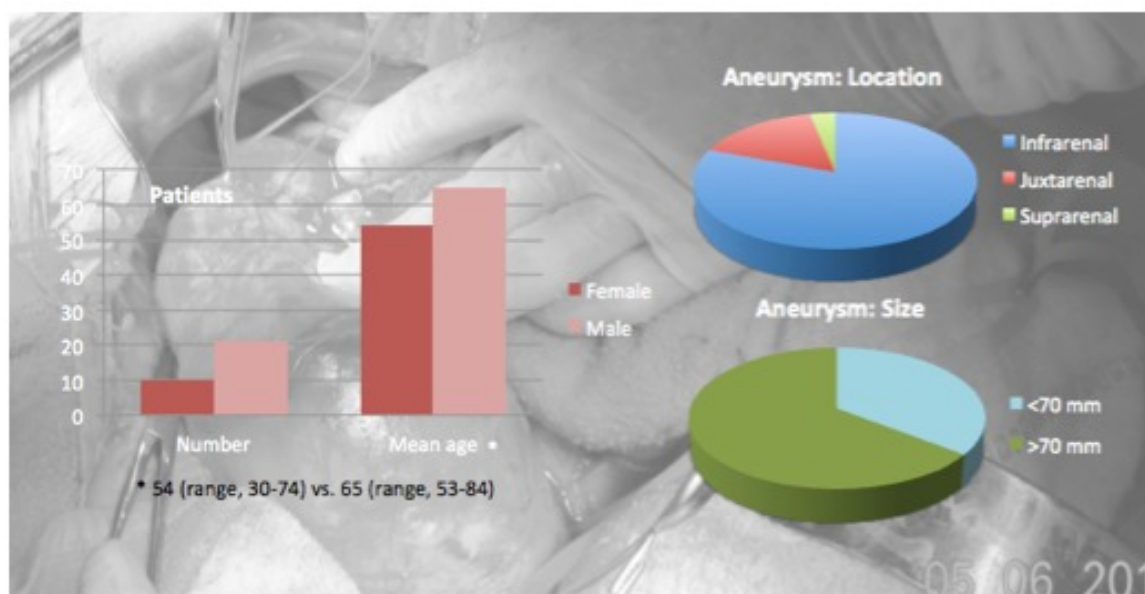


Figure 1. The patient and aneurysm characteristics.

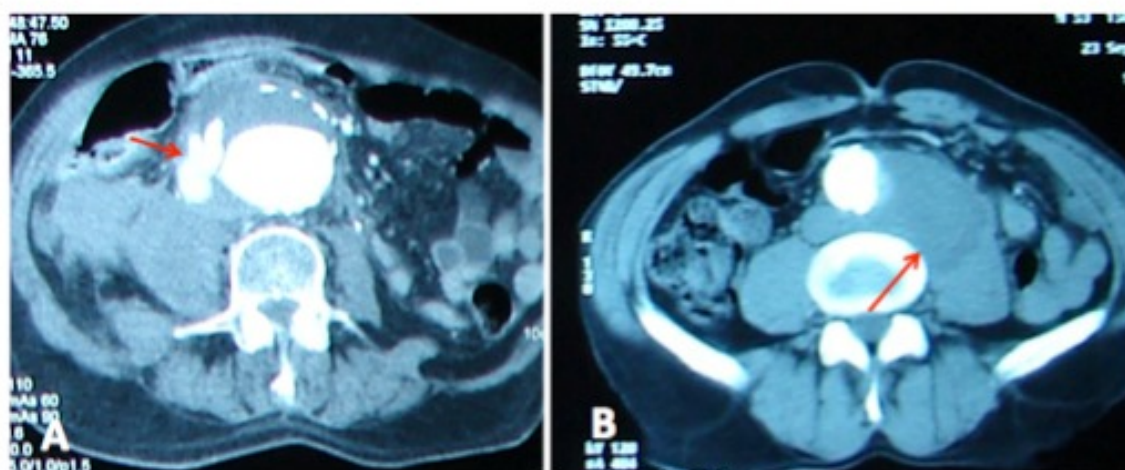


Figure 2. (A) Axial CTA image of a 67-year-old female patient with RAAA. It demonstrates active extravasation of contrast material (arrow) into the thrombosed portion of an AAA, as well as extensive retroperitoneal hemorrhage. (B) "Draped aorta sign" in a 53-year-old male patient with a known AAA. Axial CTA image represents a RAAA with a posterior aortic wall that follows the contour of the vertebral corpus with a draping effect that is indicative of a contained AAA rupture (arrow). CTA, computed tomography angiography; AAA, abdominal aortic aneurysm; RAAA, ruptured AAA.

RESULTS. Ruptured aneurysm was greater than 70 mm in 20 patients, with an average size of 98.7 mm. (Figure 1). The PAC was achieved by transthoracic (16.7%), supraceliac (13.3%), suprarenal (33.3%), and infrarenal (36.7%) approaches (Figure 3). The RAAA was most commonly localized infrarenally (80.6%). One of them had horseshoe kidney concomitantly (Figure 4). Tube grafts, which were mostly polyester grafts, were used in 11 patients (Figure 5); bifurcated grafts to the iliac (n=9) or the femoral arteries (n=9) were used. Graft materials were polyester (93.1%) and teflon (6.9%). The inferior mesenteric artery was reimplemented in 4 patients (13.3%)(Figure 6). Concomitant procedures were vascular (bypass grafting for lower extremity arterial disease) and nonvascular (debridement for hemorrhagic necrotizing pancreatitis and cholecystectomy for cholecystitis with cholelithiasis)(Figure 7). Abdominal re-exploration was not required in the patients with RAAA. The perioperative and postoperative mortality rates were 3.3%.

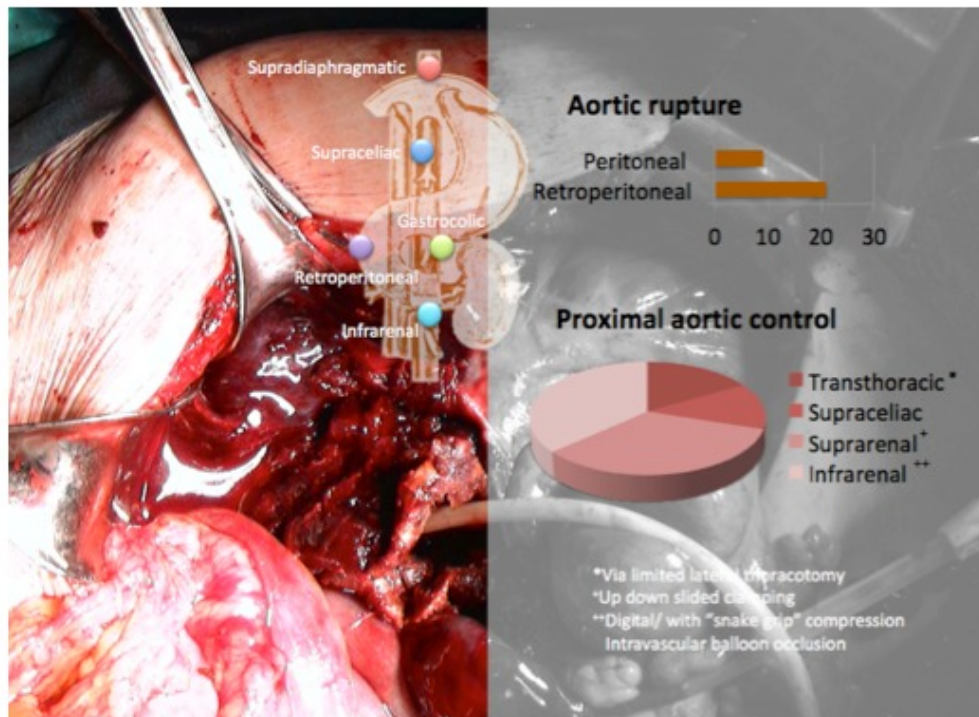


Figure 3. Abdominal aortic rupture and its proximal control.

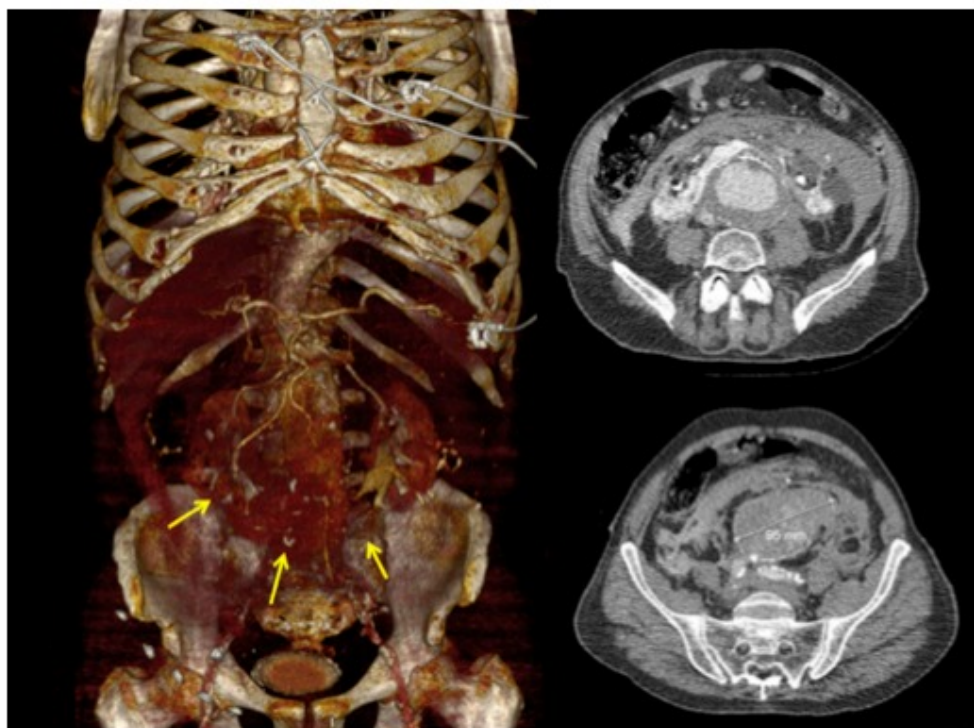


Figure 4. The CTA images of an 83-year-old male with infrarenal RAAA and HSK. The arrows on 3D-volume rendering CT sequence depict HSK. CTA, computed tomography angiography; RAAA, ruptured abdominal aortic aneurysm; HSK, horseshoe kidney.

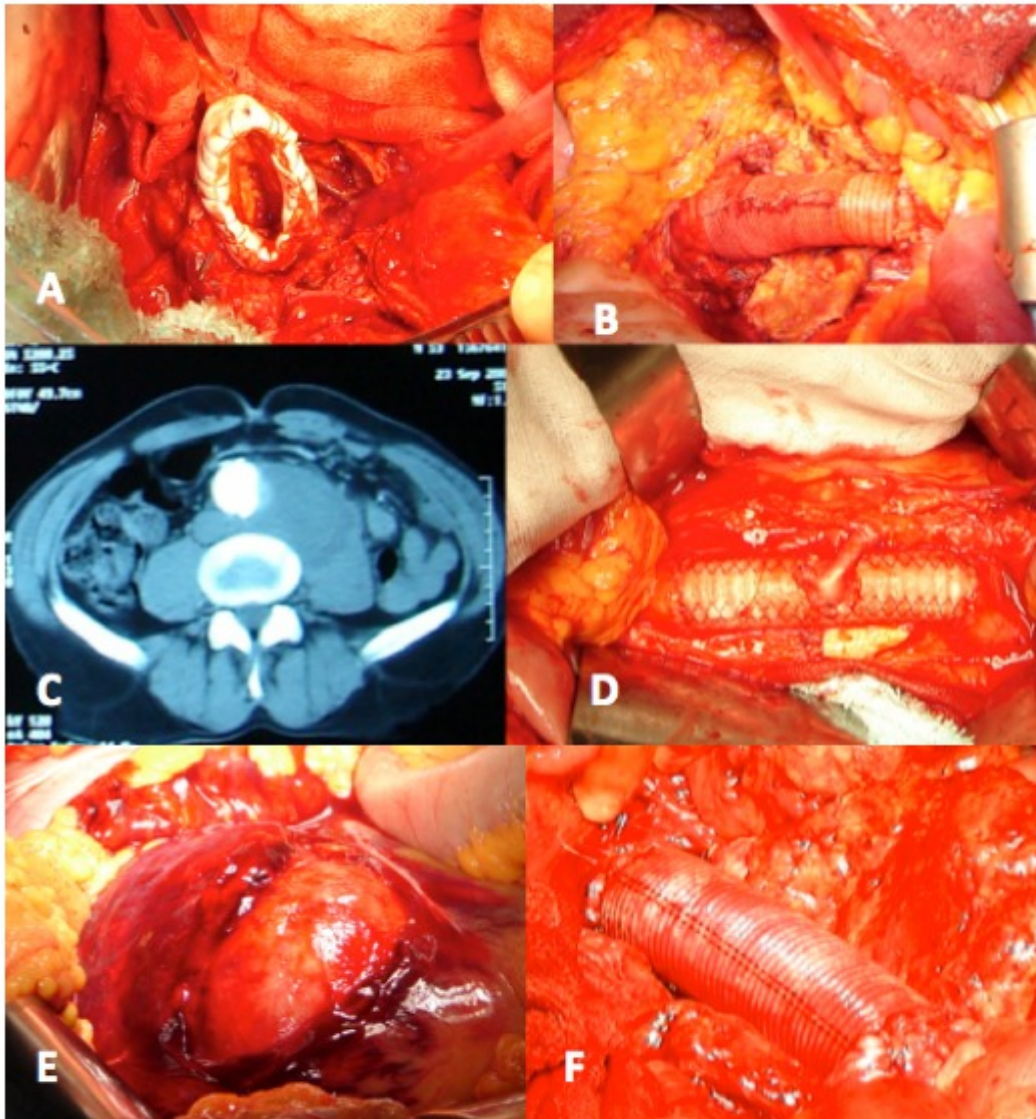


Figure 5. Examples of patients who underwent aortic interposition with polyester tube graft after resection of the aneurysm (A&B, C&D, and E&F). Note that native diseased aortic stump was re-inforced before proximal anastomosis in some patients (A).

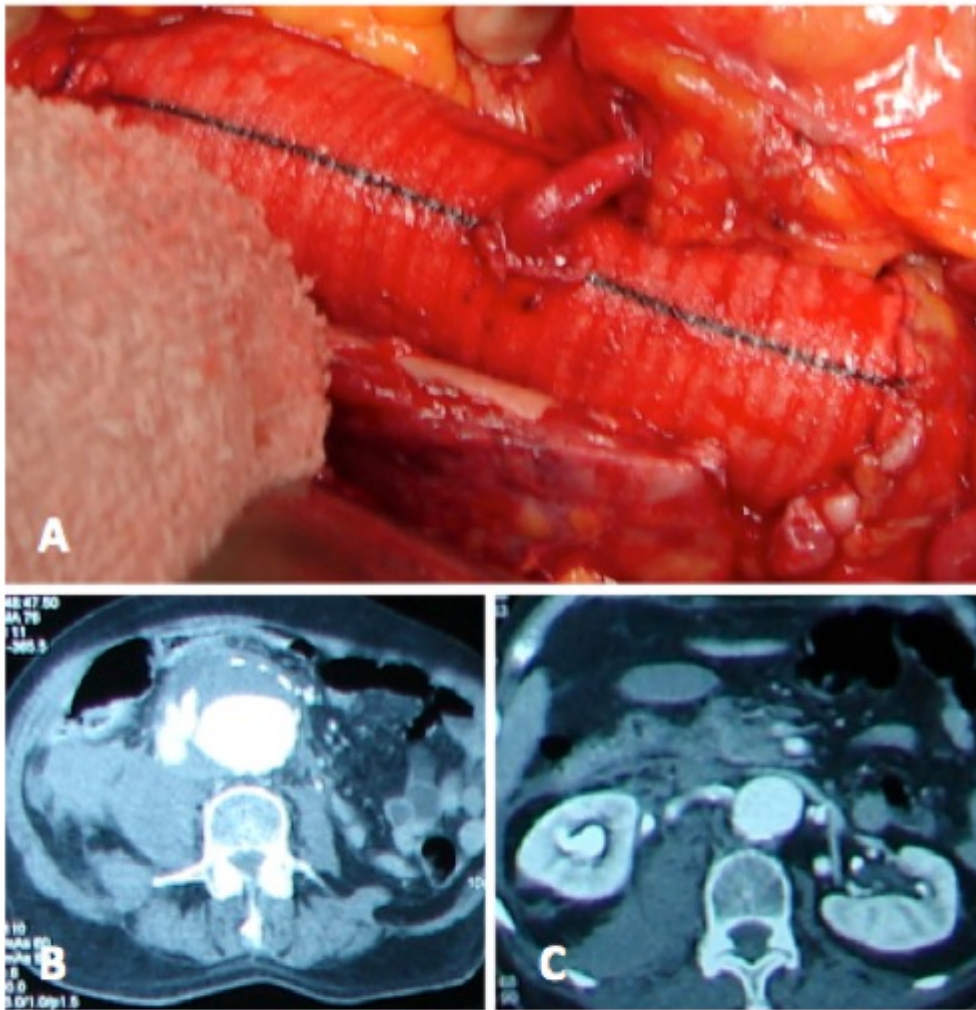


Figure 6. Appearances of surgical field and CTA images of a 74-year-old female with RAAA (A-C). The ruptured aneurysm was resected and aorta interposed with a polyester tube graft. Then, the inferior mesenteric artery, which is divided previous, was re-implanted in this graft (A). Note a transmural thrombus and an eggshell calcification of aneurysmal aorta (B) and periaortic hematoma extending into right retroperitoneal space (C). CTA, computed tomography angiography; RAAA, ruptured abdominal aortic aneurysm.

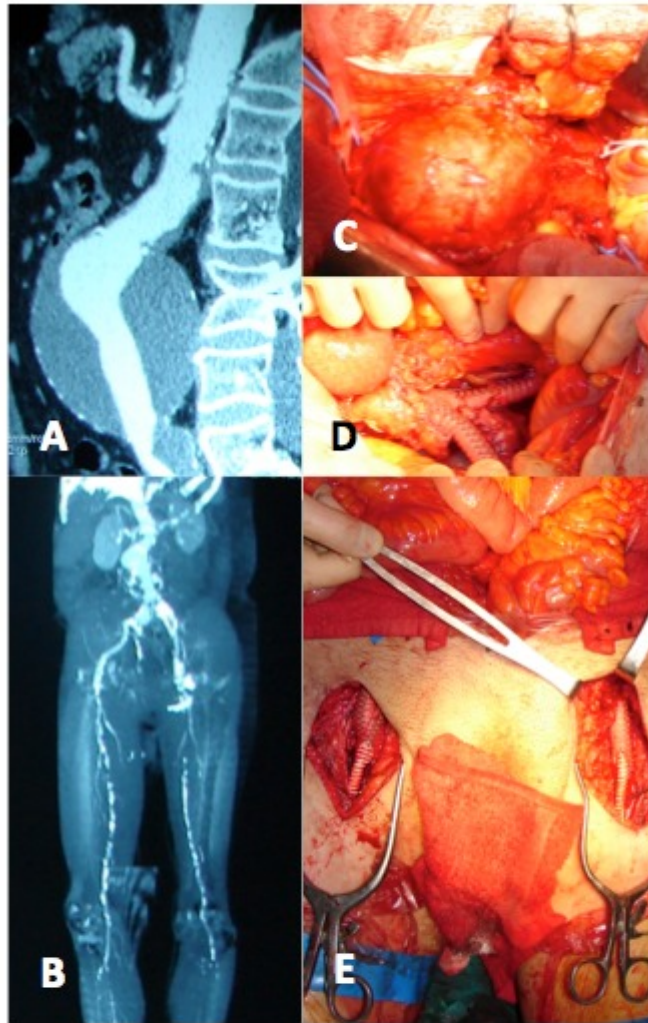


Figure 7. Appearances of the surgical field and computed tomographic angiography (CTA) images of a 76-year-old male patient who presented with abdominal pain, hypotension and abdominal pulsatile mass, previously known as abdominal aortic aneurysm (AAA) and lower extremity arterial disease. CTA shows infrarenal AAA (~ 90 mm), focal aneurysm at right common femoral artery (23 mm) and bilateral obliterated superficial femoral arteries that are weakly filled with collateral vasculature (A, B). Note the surgical field of this RAAA patient (C) who underwent aorto-bilateral-femoral bypassing with an end-to-end anastomosis proximally and end-to-side anastomosis distally using polyester bifurcated graft (D) and bilateral femoro-popliteal bypassing with a teflon graft (E).

CONCLUSIONS

Although endovascular repair has the advantage of having relatively low perioperative mortality and morbidity, surgical repair still plays an important role in the treatment of ruptured AAA due to the anatomical and institutional limitations of endovascular repair. There has been a paradigm shift after years of improvements in the survival outcomes of surgical repair. After all, a controlled hypotensive resuscitation strategy plus suitable proximal aortic control looks like a sine qua non for patients with ruptured AAA.

ID: 281

Topic: **Cardiovascular Surgery » Abdominal Aortic Aneurism**Presentation Type: **Oral****MANAGEMENT OF RUPTURED ABDOMINAL AORTIC ANEURYSMS****Eyüp Serhat Çalık, Ferhat Borulu, Ümit Arslan, Azman Ateş, Yahya Ünlü***Atatürk University Faculty of Medicine, Erzurum, Turkey***Corresponding Author (eyupserhatcalik@hotmail.com)**eyupserhatcalik@hotmail.com, fborulu@gmail.com, kvcumit@gmail.com, azmanates@atauni.edu.tr, yahyaunlu@hotmail.com***Abstract Text**

Management of Ruptured Abdominal Aortic Aneurysms

Eyüp Serhat Çalık, Ferhat Borulu, Ümit Arslan, Azman Ateş, Yahya Ünlü.

Atatürk University Faculty of Medicine, Department of Cardiovascular Surgery, Erzurum, Turkey

Objective: The fatal complication of abdominal aortic aneurysm is rupture which it is end of the natural process. Ruptured abdominal aortic aneurysm (RAAA) is one of the most fatal surgical emergencies. In spite of advances in intensive care unit management and techniques for repair, mortality following repair of RAAA remains high. The aim of this study to present the results of RAAA repair.

Methods: Between 1996 and 2018, 56 patients brought to the emergency department with RAAA. 14 (25%) of them were died before the repair in the emergency service or operating room, they were excluded from the study. We treated 42 of them for RAAA were analysed retrospectively.

Results: Thirty (71.4%) of the cases were male and 12 (28.6%) were female and the mean age was 65.76 ± 10.24 . Abdominal, back and side pain and abdominal pulsatile mass were the most common symptoms. The most common risk factors were hypertension, smoking, CAD and COPD. The patients were quickly examined and the necessary USG, BT or MRI examinations were performed immediately. At the beginning of the operation, 12 (28.6%) patients had blurred consciousness and 7 (16.7%) patients were unconscious. These patients were in shock table and were hemodynamically unstable. In one case, surgical correction was made by performing peroperative diagnosis in acute abdomen surgery. The aneurysm diameters were 6.91 ± 1.48 cm (range 4 to 9.8 cm) and 28 (66.7%) were fusiform, 6 (14.3%) were saccular, 6 (14.3%) were dissecting, and 2 (4.8%) were mycotic aneurysms. 22 aorto-biiliac graft bypass, 12 aortobifemoral graft bypass, 7 abdominal aorta tube graft interposition and 1 EVAR procedure were applied to the cases. Perioperative excessive bleeding was observed in 10 (23.8%) patients and in 7 (16.7%) of them DIC table developed. There were observed 5(11.9%) colonic ischemia, 4 (9.5%) extremity ischemia, 1 (2.4%) ureter injury at early postoperative period and 5 (11.9%) patients required reoperation and 2 (4.8%) amputation. Intensive care unite and hospital stay were 4.2 ± 2.8 days and 14 ± 4.8 days, respectively. Postoperative mortality was observed in 18 (42.9%) patients. The total mortality of 56 patients was 57.1% (32 patients).

Conclusions: Despite advances in health and care and improvements in repair technologies, mortality is still high in RAAAs. We think that early detection of the disease and the detection of the its prevalence by screening are vital in reducing mortality rates. Key words: Ruptured aortic aneurysm, early diagnosis, early surgical repair, mortality.

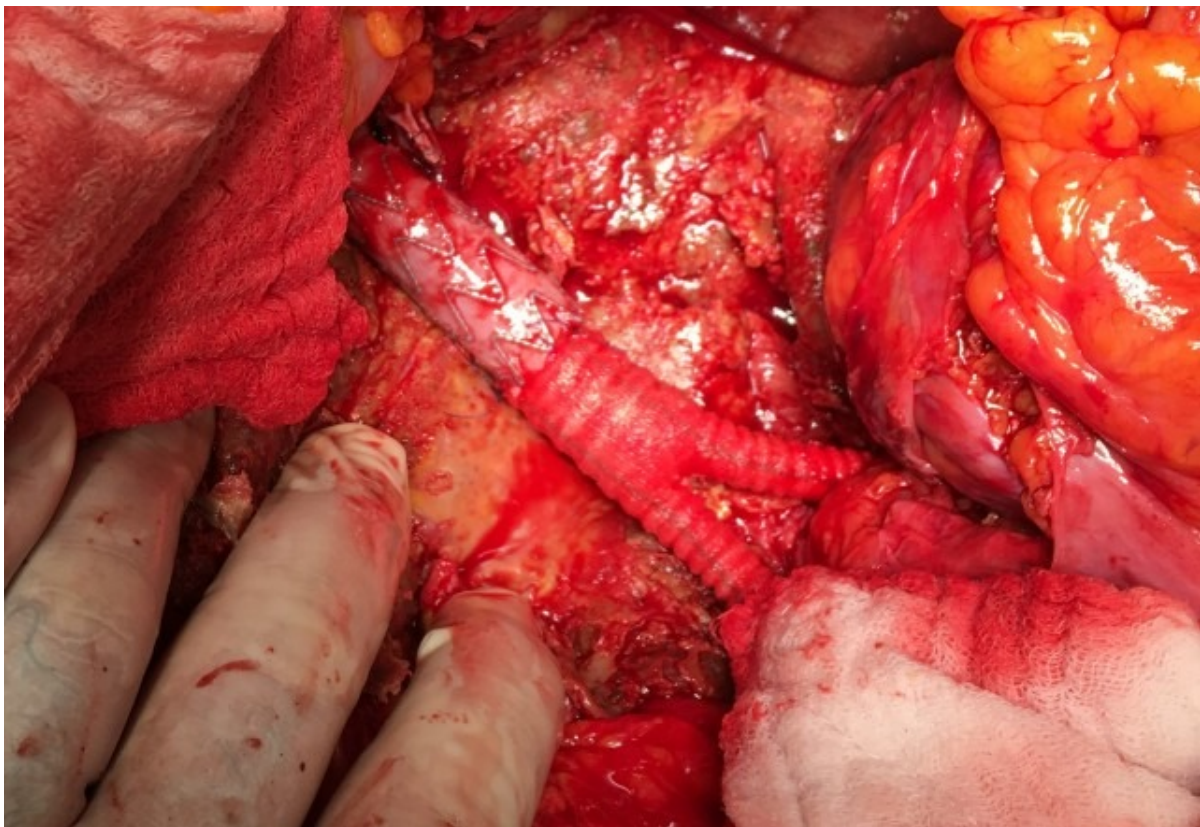
ID: 415

Topic: Cardiovascular Surgery » Abdominal Aortic Aneurism

Presentation Type: Oral

A NEW SURGICAL METHOD IN RUPTURED ABDOMINAL AORTIC ANEURYSM AFTER TYPE III ENDOLEAK**Özden Vezir***Mersin Şehir Hastanesi, Mersin, Turkey***Corresponding Author (ovezir@hotmail.com)**ovezir@hotmail.com***Abstract Text**

Objectives: Type III endoleaks can occur in the long-term follow-up after endovascular aneurysm repair graft (EVAR). A ruptured abdominal aortic aneurysm (AAA) with a type III endoleak requires urgent repair.



Case: A 64 years old man with severe abdominal pain was admitted to our emergency service. The patient's blood pressure and heart rate were 85-55 mmHg and 112 bpm respectively. The hemoglobin was 8.7 g/dl. CT scan showed a ruptured infrarenal abdominal aortic aneurysm with type III endoleak in previous EVAR. A stent-graft (The original company and brand unknown) was deployed 5 years before at outside center. Type III endoleak was certainly occurred due to the separation of left iliac stent-graft limb from the main body in the distal portion of AAA. The patient was operated under emergency conditions. Just after cleaning the hematoma located in retroperitoneal lodge, cross-clamp was placed under the renal arteries. It was clearly seen that the left limb of the stent-graft was dislocated in the left iliac artery. The main graft could not be taken out from the aorta. Cross-clamp was placed on the main portion of EVAR graft, right iliac limb was closed by cutting it from the bifurcation and left iliac limb was performed end to end anastomosed with a 14x7 knitted dacron graft via 3-0

polypropylene suture. The limbs of dacron graft were tunelled into the inguinal areas and were anastomosed to both common femoral arteries. The aneurysmatic iliac arteries were ligated and the aortic sac was wrapping around to the anastomosis.

Results: The patient was discharged on his postoperative 6th day. No complications and complaints were seen during the first year close follow up.

Discussion: An emergency approach to AAA rupture after type III endoleak may be an endovascular treatment or a surgical procedure. While previous EVAR stent can be totally extracted in the most cases, it should be remembered that the extraction could be challenging due to the cohesiveness of the stent graft itself into aortic wall and this procedure could cause the rupture. Likewise in this case, we may choose to perform the anastomosis between the EVAR and dacron graft without applying an extraction in order to avoid any extra complications.

ID: 73

Topic: Cardiovascular Surgery » Abdominal Aortic Aneurism

Presentation Type: Oral

TREATMENT MANAGEMENT IN A PATIENT WITH GIANT RUPTURED INTERNAL ILIAC ARTERY ANEURYSM

Mehmet ışık, Ömer Tanyeli

Necmettin Erbakan University Meram Faculty of Medicine , Konya, Turkey

**Corresponding Author (drmisik@hotmail.com)*

drmisik@hotmail.com, otanyeli@gmail.com

Abstract Text

OBJECTIVE

Internal iliac artery aneurysms are rare cases. They are mostly diagnosed incidentally in elderly men. Early diagnosis is important since mortality rate is high in ruptured aneurysms. In this study, we present a 88-year-old male patient with disrupted general status who had comorbidities and a ruptured internal iliac artery aneurysm of about 10 cm.

METHODS

Image was acquired by accessing with left femoral catheterization under general anesthesia, and extravasation was observed to continue. The aorta was turned and 16 coil embolizations (7 x 2,3 mm) were made into the right internal iliac artery, but only half of the aneurysm could be filled. Thereupon, 2 cc cyanoacrylate was poured on the coil embolizations, and inside the aneurysm was completely thrombosed. Next, a covered stent (13,5x10 cm) was inserted between the common iliac artery and external iliac artery via the right femoral artery, so as to close ostium of the internal iliac artery. In the control exposures, there were no extravasation and endoleak, and the operation was terminated.

RESULTS

Recently, with the advancements in stenting technology and operational experience, endovascular procedure have been a significant alternative to surgery. We aimed to discuss successful endovascular operation of ruptured internal iliac artery and treatment management of this patient.

CONCLUSIONS

Although 16 coil embolizations inserted, the aneurysm could not be closed. It was not reasonable to insert stent without thrombosing the aneurysms of such size. Because the stent might be displaced, leading to endoleak during the progression. Therefore, cyanoacrylate was added on the coil embolizations, and entire aneurysm was thrombosed. Making thrombosis with glue alone was also an alternative. However, we thought that glue could be extravasated from surface of the ruptured aneurysm. We do not know how would cyanoacrylate react after leaking to the abdomen. First, we performed coil embolization and closed the segment somewhat in order to avoid extravasation of

cyanoacrylate. Glue was added on it and total thrombosis was provided. A covered stent was then inserted on the segment which we thought to be stabilized.

Oral Presentations

Endovascular Interventions: Exploring New Directions

Date: 29.03.2019 Time: 13:30 - 15:00 Hall: 6

ID: 278

Topic: **Cardiovascular Surgery » Abdominal Aortic Aneurism**

Presentation Type: **Oral**

EVALUATION OF EFFECTIVENESS OF ENDOVASCULAR ABDOMINAL AORTIC REPAIR: MID AND LONG TERM OUTCOMES

Ümit Arslan, Eyüp Serhat Çalık, Ferhat Borulu, Bilgehan Erkut, Yahya Ünlü

Atatürk University Faculty of Medicine, Erzurum, Turkey

**Corresponding Author (kvcumit@gmail.com)*

kvcumit@gmail.com, eyupserhatcalik@hotmail.com, fborulu@gmail.com, bilgehanerkut@yahoo.com, yahyaunlu@hotmail.com

Abstract Text

Evaluation of Effectiveness of Endovascular Abdominal Aortic Repair: Mid and Long Term Outcomes

Ümit Arslan, Eyüp Serhat Çalık, Ferhat Borulu, Bilgehan Erkut, Yahya Ünlü.

Atatürk University Faculty of Medicine, Department of Cardiovascular Surgery, Erzurum, Turkey

Objective: In this study, we aim to discuss the early and mid-term outcomes of our patients who underwent endovascular stent graft replacement for the management of abdominal aortic aneurysms for 10 years.

Methods: Between 2008 and 2018, endovascular stent graft implantation was applied to 51 patients for abdominal aortic aneurysm. 45 patients were male and 6 were female. Mean age 71.1 years and ranged from 56-80. The mean aneurysm diameter was 68.4 mm in infrarenal abdominal aortic aneurysms and 58.8 mm in iliac artery aneurysms. Forty-four patients underwent elective surgery, while 7 patients were emergency. The aneurysms localized in infrarenal aorta and aortoiliac level in 46 patients and 5 were isolated in iliac artery level. Our study group consisted of non-specific degenerative aneurism cases, carrying risk if treated surgically.

Results: Endovascular interventions were applied to the patients under local anesthesia and mild sedation in elective surgeries and under general anesthesia in emergencies. During the process, there were no death, major complications or did not require open surgery. Endoleak was developed in 8 patients intraoperatively and in 6 patients in follow-up that they required reintervention. In three patients who underwent the aorta biiliac stent graft procedure developed complications. The right iliac leg implantation in one patient could not be performed due to stenosis and excessive tortuosity. Right iliac leg was occluded and left to right cross femoral bypass was performed. One patient developed acute graft thrombosis on postoperative 18th hour, thrombolytic therapy (t-PA) was applied and blood flow was supplied. Other patient underwent surgery on postoperative 15th day, between the left femoral to the right femoral cross bypass was made due to right iliac graft thrombosis. No graft infection was observed. The mean hospitalization time was 6.4 days (range, 3-24 days). The mean follow-up time was 28.3 months (range, 3-43 months). The hospital mortality was in 3 (5.8%) patients. Mortality occurred related to aneurysm in 5 (9.8%) patients during the follow-up.

Conclusions: Although they have disadvantages such as frequent re-intervention and lack of advantage in mortality in mid- and long-term, EVAR is a safe and useful treatment method for high risk surgical patients (elderly, comorbidity, prior abdominal surgery) and can be performed with low mortality and morbidity.

Key Words: Aortic aneurism; endoleak, endovascular graft; stent graft.

ID: 273

Topic: Cardiovascular Surgery » Thoracic and Thoracoabdominal Aortic Dissections and Aneurisms

Presentation Type: Oral

ENDOVASCULAR AORTIC REPAIR IN MANAGEMENT OF THORACIC AORTIC PATHOLOGIES

Eyüp Serhat Çalık, Ferhat Borulu, Bilgehan Erkur, Yahya Ünlü

Atatürk University Faculty of Medicine, Erzurum, Turkey

**Corresponding Author (eyupserhatcalik@hotmail.com)*

eyupserhatcalik@hotmail.com, fborulu@gmail.com, bilgehanerkut@yahoo.com, yahyaunlu@hotmail.com

Abstract Text

Endovascular Aortic Repair in Management of Thoracic Aortic Pathologies

Eyüp Serhat Çalık, Ferhat Borulu, Bilgehan Erkur, Yahya Ünlü.

Atatürk University Faculty of Medicine, Department of Cardiovascular Surgery, Erzurum, Turkey

Objective: Aneurysms, dissections and ruptures of the thoracic aorta are still potentially life-threatening disorders. The traditional operations are still associated with high mortality and morbidity. Thoracic endovascular stent graft repair (TEVAR) of these pathologies offers an alternative to conventional operations for management of thoracic aortic diseases. We aimed to present our experience with endovascular stent graft repair of thoracic aortic diseases.

Methods: Between January 2012 and December 2018, endovascular stent graft repair was performed in 18 patients. In 7 of the 18 patients there were emergent situations. In the postoperative period control CT scans were evaluated in the day of discharge, 3 rd, 6 th and 12 th months after the procedure.

Results: The mean age was 56.5 ± 14.7 (28-78) years. The thoracic aortic lesions were 7 thoracoabdominal aortic aneurysm, 5 type B aortic dissection, 3 traumatic thoracic aortic dissection and 3 thoracic aortic aneurysm rupture. The stent grafts implantation were successfully completed in the appropriate position in all patients. 13 of the applied grafts were the covered stent and 5 were the multilayer stent. The carotid- subclavian bypass was required in 3 patients and performed. There hospital mortality occurred in 2 (11.1%) patients. There was no conversion to open surgery. Mean follow up time was 26.8 ± 7.6 months. The total number of endoleaks were 4 (22.2 %) during the follow-up.

Conclusions: Thoracic endovascular stent graft application in thoracic aortic pathologies can be applied rapidly and safely in cases with high risk or in emergency cases. These endoluminal techniques can avoid the major trauma of the traditional surgery. However, these results require the support of larger scale and long-term studies.

Key words: Aortic pathologies; aneurysm; dissection; endovascular treatment; rupture.

ID: 411

Topic: **Cardiovascular Surgery » Endovascular Surgery**

Presentation Type: **Oral**

RUPTURED ABOMINAL AORTIC ANEURYSM DUE TO HYPERTENSION INDUCED MIGRATION IN A PATIENT UNDERGOING EVAR

Mustafa Dađlı

University of Health Sciences Konya Education and Research Hospital, Konya, Turkey

**Corresponding Author (drmustafaana@gmail.com)*

drmustafaana@gmail.com

Abstract Text

Endovasküler tedaviler yıllar içinde popülaritesini arttırdı ve büyük ilerleme kaydetti. Bu uygulama ile ilgili komplikasyonlar da artmış ve uygulamadaki artışla öne çıkmaya başlamıştır.

Tabii ki, bunlardan biri EVAR ve yıllar içinde parçalanmış bir abdominal aort anevrizmasına göç eden greftin göçü.

Vaka Raporu

İki yıl önce abdominal aort anevrizması nedeniyle EVAR yapılan 70 yaşında erkek hasta, bir aydır mevcut olan karın ağrısı nedeniyle dış merkeze başvurdu. Muayeneden sonra yırtık abdominal aort anevrizması tanısı kondu.

2 yıl tıbbi tedavi görmeyen ve EVAR'dan sonra rutin takip önerilmeyen hastamız kliniğimize 185/90 mmhg kan basıncıyla geldi. Rutinleri kötüydü ve ateşi vardı. Hemogloblin: 7,5 gr / dl, HTC: 22, P02: 58,9, Cts: 87,7, WBC: 12,94, Sedimantasyon: 43, CRP: 120 ve Prokalsitonin: 0,58.

Karın BT; Abdominal aortta, karın içi akışın ölçülmesine izin veren en geniş 10 cm alanda anevrizma gözlemlendi. Anevrizmada, karının sağına doğru uzanan, BT'de bir kan akımıyla (yırtilma) 2 cm'lik bir alan gözlemlendi.

Beta blokör ve perlinganit, zor olsa da, kontrol altında kan basıncının infüzyonu. Gerekli endovasküler materyal hızlı bir şekilde elde edildikten sonra, endovasküler prosedür uygulandı. Stent grefti hastanın renal arterlerinin bir uzantısı olarak yapıldı. Kanama durduruldu. Kanama kontrol altına alınmadığı takdirde kesinlikle acil ameliyat yapılır.

İlk aşamada amacımız kanamayı kontrol etmek ve daha sonra enfeksiyon parametrelerini ve böbrek değerlerini topladıktan sonra açık abdominal aort anevrizması yapmaktır. Bu işlemi bir ay sonra yapmak en uygun yöntemdi.

Sonuç olarak, hastaların tıbbi tedavisi ve rutin takibi, kesinlikle endovasküler tedaviden sonra yapılmalıdır.

ID: 97

Topic: Cardiovascular Surgery » Thoracic and Thoracoabdominal Aortic Dissections and AneurismsPresentation Type: **Oral****ENDOVASCULAR TREATMENT OF ASCENDING AORTIC PSEUDOANEURYSM****Tanıl Özer***Univercity of Health Sciences Kartal Koşuyolu High Speciality Educational and Research Hospital, Istnabul, Turkey***Corresponding Author (drtanilozer@gmail.com)**drtanilozer@gmail.com***Abstract Text****OBJECTIVES**

Tevar procedure is a rarely applied method for ascending aorta-zone 0 region while applying very frequently to arcus and descendant aortic lesions. In our case report, a 47-year-old female patient previously underwent AVR-MVR surgeries, followed by graft infection and associated pseudoaneurysm after Benthall re-operation. We aimed to treat this rare complication by performing TEVAR to the ascending aorta and shared our experience.

MATERIAL & METHODS

48 years old female patient with history of mitral valve replacement + aortic valve replacement 1 years ago and Bentall (with 32 no dacron graft) procedure 3 months after first surgery because of aortic paravalvular leak and ascending aortic aneurysm and finally surgical repair of ascending aortic pseudoaneurysm which is occurred 3 months after Bentall procedure referred to us with fatigue. She also had history of recurrent sternal dehiscence repair and prolonged sternal wound infection and healing process after these surgeries. Her hemoglobin value was 7 g/dl on CBC. We performed CT angiography and we diagnosed a new pseudoaneurysm through the distal suture line of graft. We decided to perform endovascular intervention instead of surgical approach and performed 32x52 mm successful TEVAR to ascending aorta via left subclavian artery which size was appropriate for using as an access vessel.

RESULT

There were no pseudoaneurysms on control CT angiography. Patient discharged from hospital 3 days after procedure.

CONCLUSION

Surgical intervention is gold standart procedure ascending aortic aneurysms and pseudoaneurysms. We preferred endovascular because patient has history of recurrent sternal dehiscence and prolonged sternal wound infection. As in this case endovascular approaches should be kept in mind beside surgical intervention.

ID: 237

Topic: Cardiovascular Surgery » Thoracic and Thoracoabdominal Aortic Dissections and AneurismsPresentation Type: **Oral****SUCCESSFUL TREATMENT OF RUPTURED DESCENDING THORACIC AORTIC ANEURYSM WITH TEVAR**

Gökhan Erol, Hüseyin Sicim, Emre Kubat, Murat Kadan, Kubilay Karabacak, Suat Doğancı, Cengiz Bolcal

*Gulhane Training and Research Hospital, Ankara, Turkey***Corresponding Author (drgokhanerol@gmail.com)**drgokhanerol@gmail.com, huseyinsicim@yahoo.com.tr, ekubat@gmail.com, mrtkdn@gmail.com, kubilaykarabacak@yahoo.com, suat_doganci@yahoo.com, bolcalc@yahoo.com***Abstract Text****INTRODUCTION:**

The development of thoracic endovascular aortic repair (TEVAR) versus conventional aortic surgery has allowed a minimally invasive approach to the management of thoracic aortic pathology. Rupture of thoracic aortic aneurysms is one of the fatal thoracic aortic pathologies. Due to its fast applicability and ease in suitable cases, TEVAR is rapidly becoming the preferred method. In this case report, we present the TEVAR application which we performed successfully in the patient who developed rupture thoracic aortic aneurysm.

CASE REPORT:

A 60-year-old male patient was admitted to the emergency department with dyspnea and back pain. The patient had a history of hypertension only and did not have a known aortic aneurysm or a history of cardiac disease. A thoracic aortic rupture was detected by computed tomography. CT revealed a 6-cm diameter aortic aneurysm with a periaortic hematoma, and an intensive hematoma in the intrapleural and mediastinal spaces. (Figure 1) TEVAR was planned as urgent. The procedure was performed under sedo anesthesia. A percutaneous 7 Fr sheath was inserted into the left femoral artery, and the right femoral artery was explored and 18 Fr sheath was inserted. A thoracic endovascular graft was placed in such a way that the left subclavian artery would not close its outlet. Control aortography revealed no endoleak and the procedure was terminated and the patient was taken to the intensive care unit without any complications. The patient was discharged from hospital on the 6th day after TEVAR.

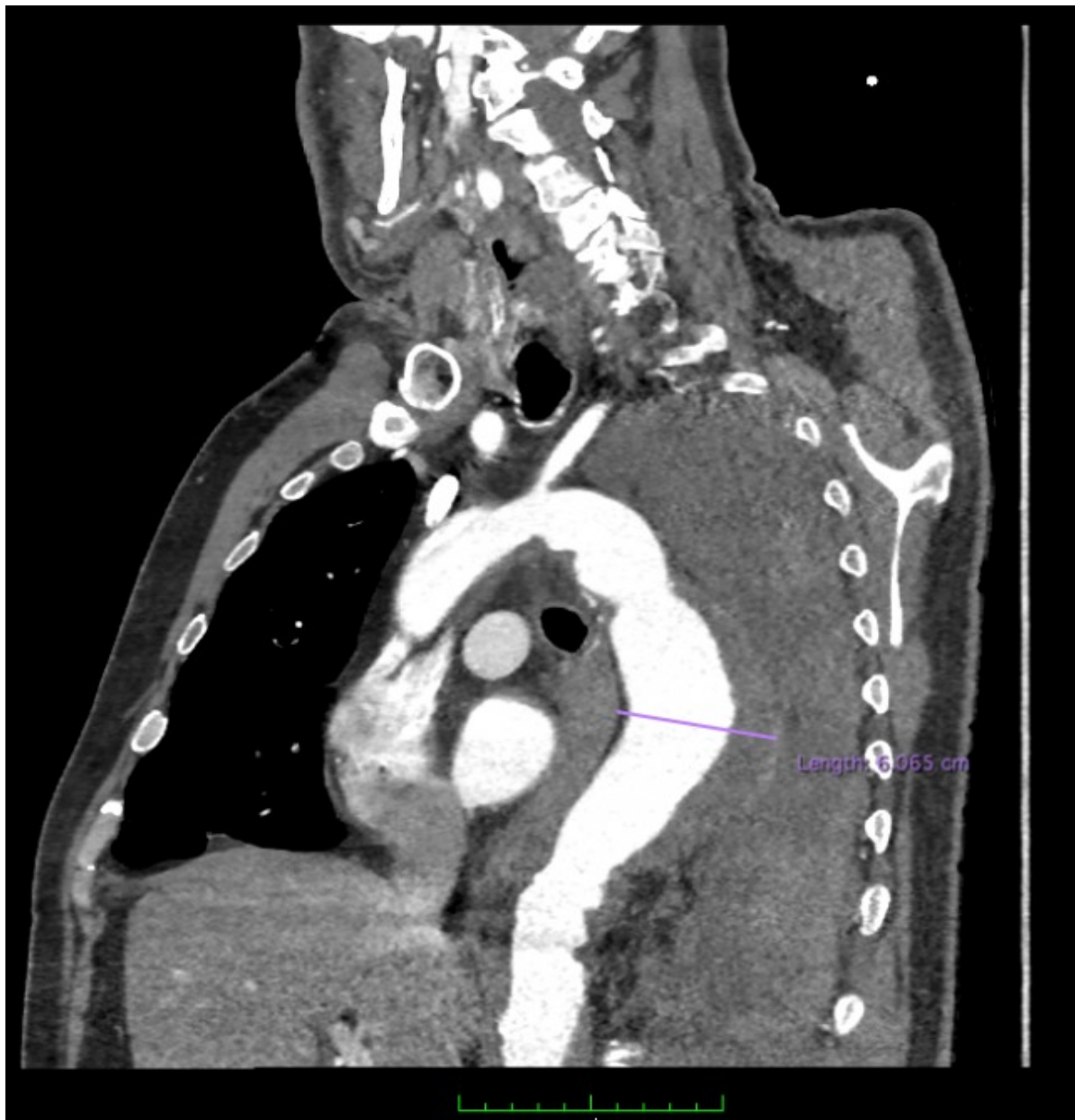


Figure 1. CT revealed a 6-cm diameter aortic aneurysm with haemothorax

DISCUSSION AND CONCLUSION:

The rupture of the thoracic aortic aneurysm is a condition with high mortality and morbidity rates that should be treated as early as possible in order to survive. Overall, the survival rate of surgical treatment is reported to be low due to serious complications. In patients with a reduced ability to tolerate surgery, such as the elderly, it is often difficult to perform because of the invasive nature of the surgery or because of the poor preoperative condition caused by the severity of the disease. In our patient, we wanted to emphasize the importance of rapid and effective TEVAR treatment with preoperative appropriate planning for ruptured ruptured descending to aortic aneurysm detected by CT angiography. It should be kept in mind that this method can be preferred as an alternative to surgery in appropriate cases.

ID: 157

Topic: Cardiovascular Surgery » Thoracic and Thoracoabdominal Aortic Dissections and AneurismsPresentation Type: **Oral****EVALUATION OF EARLY AND MID-TERM RESULTS OF TEVAR PROCEDURES WITH DIFFERENT ETIOLOGY.****Dilsad Amanvermez Senarslan, Funda Yıldırım, Omer Tetik***Manisa Celal Bayar University, Faculty of Medicine, Manisa, Turkey***Corresponding Author (damanvermez@yahoo.com)**damanvermez@yahoo.com, fundanizamoglu@yahoo.com, damanvermez@yahoo.com***Abstract Text**

Objective:

Endovascular aneurysm repair in thoracic aorta (TEVAR) is now preferred primarily for the treatment of degenerative aneurysms, saccular aneurysms and acute thoracic aortic syndromes. The aim of this study was to evaluate the early and mid-term results of TEVAR procedure in our clinic in the last 4 years.

Methods:

Thirty patients (25 males, 5 females) underwent TEVAR in our clinic in the last four years. Valiant™ Thoracic Stent Graft System (Medtronic®) was used in all patients.

Results:

The mean age of the patients was 60.4±18. Of the patients, 53,3% had degenerative aneurysm origin, 36,7% had acute thoracic aortic syndromes and 10% had aortic coarctation and concomitant poststenotic aneurysm. 63,3% of the patients were symptomatic and had back or chest pain. Technical success of the procedures was 100%. The mean duration of stay in the intensive care unit was 1 ± 2 days and the mean hospital stay was 3.2 ± 2 days.

There was no in-hospital mortality and 1 patient had mortality due to type 2 dissection in the first 30-day period. Endoleak was seen in two patients (2 type 2 endoleak) and no secondary procedure was required. In addition, subclavian artery was required to be closed in 3 patients. There was no significant difference in arterial blood pressure between the right and the left arm and no ischemia was observed in the left arm.

In spite of adequate hydration, in the early postoperative period, 2 patients had elevated creatinine levels and regressed to the normal in the follow-up. The mean follow-up period was 6 ± 9 months and total mortality rate was 2 in the long term. One patient, died of lung cancer and the other was independent of aneurysmal disease due to mesenteric ischemia.

Conclusion:

TEVAR is the firstline therapeutic option in anatomically suitable patients for the treatment of aneurysmatic disease of thoracic aorta or acute thoracic aortic syndromes. TEVAR can be applied with low morbidity and mortality compared to conventional surgery.

ID: 179

Topic: Cardiovascular Surgery » Thoracic and Thoracoabdominal Aortic Dissections and AneurismsPresentation Type: **Oral****ENDOVASCULAR SURGERY VERSUS OPEN SURGERY IN PATIENTS WITH ABDOMINAL AND TORACOABDOMINAL AORTIC ANEURYSM****Serkan Sönmez, Metin Yılmaz***Aksaray Education and Research Hospital, Aksaray, Turkey***Corresponding Author (drserkansonmez@hotmail.com)**drserkansonmez@hotmail.com, dr.metin_yilmaz@yahoo.com***Abstract Text**

Background and objectives: Endovascular stent graft application is widely used in selected patients nowadays as a less invasive treatment method in the repair of aortic pathologies. Endovascular treatment can be applied with advantages such as minimal trauma, short-term anaesthesia, less pain, less blood product use, low systemic inflammatory response and lower hospital and intensive care unit stay. In this study, we aimed to compare the advantages and benefits of endovascular treatment in thoracoabdominal and abdominal aortic aneurysms compared to open surgery.

Methods: Our study included 83 patients who underwent abdominal or thoracoabdominal aortic aneurysms since 2010 and surgical procedures consist of EVAR/TEVAR and open surgery. This study was designed as a double-centred, retrospective study of the data of the patients. Patients were included in the endovascular group who are treated with EVAR/TEVAR procedure and included in the surgery group who underwent open surgery. Demographic characteristics, preoperative, operative data and results of the operations were collected and analysed from both groups.

Results: The mean age was 71.1 ± 10.5 in the endovascular group and 65.8 ± 8.6 in the surgical group. 39 patients underwent EVAR and 6 patients underwent TEVAR in the endovascular group. Four patients underwent emergency EVAR because of acute ruptured abdominal aortic aneurysm and one patient underwent emergency TEVAR due to acute type 3 aortic dissection. While aorta-bi-femoral graft was applied to 34 of the patients in the surgical group, 4 patients underwent aortic tube graft with a thoracoabdominal incision for thoracoabdominal aortic aneurysm. All 8 patients who underwent an emergency operation in the surgical group were operated urgently due to a ruptured abdominal aortic aneurysm. In the endovascular group, mortality was observed in 2 patients (1 EVAR and 1 TEVAR and both operated in emergency operation), while 7 (4 aorta-bi-femoral emergencies operated, 1 aorta-bi-femoral elective, 2 thoracoabdominal surgery elective) patients in the open surgery group mortality were observed ($p = 0,045$). The mean duration of intensive care unit stay was 2.6 ± 4.3 in the endovascular group and 4.1 ± 4.7 in the surgical group ($p = 0.16$). The duration of hospital stay was 5.8 ± 6.2 in the endovascular group and 11.8 ± 10.1 in the surgical group ($p = 0.011$). While 0.6 ± 1.2 litres of blood transfusion was administered in the surgical group, the transfusion amount was 5.5 ± 5.4 in the surgery group ($p = 0.0001$). The operation time was $146,1 \pm 40,9$ mins in the endovascular group and $217,2 \pm 72,4$ mins in the surgical group ($p = 0.0001$). 29 (64%) of the patients in the endovascular group were operated with local anaesthesia and sedation support.

Discussion and Conclusion: In the open surgery group mortality cooperatives, duration of hospital stay in the hospital and intensive care unit, blood transfusion amounts and duration of operation were significantly higher than the endovascular group. In the case of anatomical compliance in patients, we think that endovascular treatment is superior to open surgery, especially in emergency situations in the presence of necessary infrastructure and equipment in the hospital. Larger series of studies and longer follow-up periods will determine better the future role of endovascular treatment.

ID: 517

Topic: **Cardiovascular Surgery » Endovascular Surgery**Presentation Type: **Oral****ENDOASCULAR TREATMENT OF AORTOILIAC AND ISOLATED ILIAC OCCLUSIVE ARTERY DISEASES**

Funda Yıldırım, Dilşad Amanvermez Şenarslan, **Bariş Bayram**, Abdülkerim Damar, Adnan Taner Kurdal, Ömer Tetik

Manisa Celal Bayar University, Faculty of Medicine, Manisa, Turkey

**Corresponding Author (fundanizamoglu@yahoo.com)*

fundanizamoglu@yahoo.com, damanvermez@yahoo.com, brsbyrm@hotmail.com, damanvermez@yahoo.com, damanvermez@yahoo.com, damanvermez@yahoo.com

Abstract Text**OBJECTIVE:**

Endovascular interventions in the treatment of aortoiliac diseases provides great convenience for the patient and the surgeon compared to the classical surgery. Abdominal surgery is problematic especially in obese patients and in those who have previous abdominal surgery. In this study, we presented the results of aortoiliac an isolated iliac endovascular procedures that we performed in our clinic in the last two years.

METHODS:

We reviewed our aortoiliac and isolated iliac interventions performed in the last two years. The study does not include iliac procedures performed in combination with EVAR procedures. We performed 65 endovascular interventions and we categorized them according to TASC II (Trans-Atlantic Inter-Society Consensus) classification in regard to their angiographic images.

RESULTS:

Lesion characteristics of the 65 patients: 20 patients had TASC A lesion, 12 patients had TASC B lesion, 10 patients had TASC C lesion, 23 patients had TASC D lesion. Four of the patients underwent CERAB (Covered endovascular reconstruction of aortic bifurcation). Five patients underwent kissing stents and the others underwent endoluminal stent or graft-stent. Technical success was 93%. Four patients needed to convert to open surgery because of the inadequacy of the inflow blood supply after the intervention. There was no mortality in the first 30 day. Five patients underwent open surgical intervention due to restenosis in their first 3 months follow-up.

CONCLUSIONS:

Endovascular approaches are the first line therapy for the patients with aortoiliac and isolated iliac occlusive lesions. Because they have less morbidity, mortality, reduced hospital stay, and early return to daily activity when compared to open surgery.

ID: 527

Topic: **Cardiovascular Surgery » Endovascular Surgery**

Presentation Type: **Oral**

LATE PERIOD FETAL COMPLICATIONS OF ENDOVASCULAR AORTIC REPAIR

Mustafa Dađlı, **Özgür Altınbaş**

Health Sciences University Konya Education And Research Hospitals, Konya, Turkey

**Corresponding Author (drmustafaaaa@gmail.com)*

drmustafaaaa@gmail.com, drmustafaaaa@gmail.com

Abstract Text

OBJECTIVE,

There are advantages to endovascular aortic repair (EVAR+TEVAR). However, these techniques have same complications. Multiple long term serious complications such as rupture, graft infection, endoleak and migration have been recognized.

METHODS,

Seven EVAR and TEVAR patients had been operated. The majority of patients (n:6) operated on in another hospital was admitted to the emergency service of our hospital. Rupture of aorta in 3 EVAR cases and graft infection in 3 patient with EVAR and TEVAR were found.

RESULTS,

Rupture cases were operated under emergency conditions. Proximal migration of endovascular grafts were seen them. One patient was died after operation because of multi organ failure by hemorrhagic shock. Diagnosis of graft infection was made by using computerised tomography in patients with EVAR and TEVAR. Patients with infected grafts were suppressed with antibiotic therapy.

CONCLUSIONS

Aortic neck attachment failure and proximal migration of endovascular grafts is serious problem and may lead aortic rupture. However, this complication can be prevented with proper patient selection, precise initial device placement and appropriate use of available devices.

Risks can be minimized by regular follow-up of patients' full medical treatment and routine CT checks.

Oral Presentations

Comtemporary Applications and Difficulties in Left Ventricular Mechanical Support

Date: 29.03.2019 Time: 15:15 - 16:45 Hall: 6

ID: 251

Topic: Cardiovascular Surgery » Medical and Surgical Treatment of Heart Failure

Presentation Type: Oral

INTRAORTIC BALLOON PUMP: 52 PATIENTS WITH 5 YEARS EXPERIENCE

Yusuf Kuserli

Bakirkoy Dr. Sadi Konuk Training and Research Hospital, Istanbul, Turkey

**Corresponding Author (ykuserli@yahoo.com)*

ykuserli@yahoo.com

Abstract Text

In the treatment of low cardiac output syndrome, when the medical treatment is insufficient, the most frequently used mechanical circulation support is intraaortic balloon pump(IABP). It increases oxygen supply in myocard, decreases workload in the left ventricul and increases cardiac output. This pump can be used in the operation of coronary bypass, myocard infarctus complications, persistant chest pains, valvular illnesses, cardiogenic shock and acute left heart incapacity.

Material and Method

52 patients who were implimented IABP between January 2011 and December 2017 were included in our study. The average age of the patients was 59.2±9.3 years (36- 72). %61.5 of the patients(32 patients) were male and %38.5(20 patients) were female. In the year of pre-operative characteristics in 28 patients(%53.8) diabetis mellitus, in 20 patients(%38.4) hypertension, in 38 patients(%73.1) hyperlipidemia in 4 patients(%7.7) chronic renal insufficiency, in 15 patients (%28.8) chronic obstructive lung disease, in 35 patients(%67.3) smoking habit, in 23 patients(%44.2) peripheral arterial disease, in 46 patient(%88.4) coronary artery disease, in 6 patients(%11.5) valv pathology which accompanies coronary artery disease were observed. 43 of these patients(%82.6) were implemented cardiac operation and 9 of them had low cardiac output pre-operatively.

Diagnosis

In 5 patients(%9.6) acute leg ischemia developed after 48 hours. In these patients IABP was removed out and embolectomy was implemented and current was given. In 3 patients(%5.7) thrombocytopenia (platelet<75000) developed after 48 hours. In 4 patients(%7.68) bleeding occured in local femoral. In 1 patient(%1.9) infection occured in femoral entrance. In 6 patients(%11.5), while IABP was practised, became ex due to low cardiac output.

Discussion

Eventhough in cardiologic clinics and intensive care units it is extensively used, IABP is mainly used in open heart operation centers. The three reasons for this.

1-To stop myocardial iskemi and low cardiac output in pre-operative period.

2-To provide assistance to the patients who can not be seperated from heart-lung machine in intra-operative period.

3-To stop arhythmia which is resistant to the medical treatment or low output in the intensive care unit in the postoperative period.

The position of the patient should be changed every two hours in order to stop atelectasy and to protect the skin unity and to stop complications. Some protocols defend the idea that patients should be in left lateral position due to the fact that it assists pulmonary circulation. In order to diagnose bleeding that may be related to mechanical problems, thrombocitopenia and the entrance region should be checked.

Conclusion

The most important reason why mortality rate is high in IABP assistance patients is because they are highly risk patients and have major heart failure problems. However, this mechanical assistance is fast and can be easily implemented, for this reason, it is the first option for open heart operations and intensive care unit patients. Despite the fact that IABP practice is highly in increase, the mortality rate that balloon cathetry can cause can be decreased with appropriate observation and on time reaction. The risk for causing fatal mortality is very low and so this method can be used without hesitation. Before or after the operation in the appropriate indications using IABP without time wasting will be a life savor.

ID: 442

Topic: Cardiovascular Surgery » ECMO

Presentation Type: Oral

SALVAGE VENO-VENO EXTRA-CORPOREAL MEMBRANE OXYGENATION RESUSCITATION FOR POSTPARTUM HEMORRHAGE PATIENT

**Dianne E McCallister, Md, Mba, Michael S Firstenberg, Md, Linda Pilon, Rn, Chakradhar Kotaru, Md,
Gregory Hickey, Md, Ahmad Alsaleem, Md**

The Medical Center of Aurora, Aurora, United States

**Corresponding Author (diannemcca@aol.com)*

*diannemcca@aol.com, msfirst@gmail.com, linda.pilon@healthonecares.com, chakradhar.kotaru@ccpcmd.com,
gregory.hickey@ccpcmd.com, ahmad.alsaleem@ccpcmd.com*

Abstract Text

Salvage Veno-Veno Extra-Corporeal Membrane Oxygenation (VV-ECMO) was successfully implemented as a lifesaving measure to assist in resuscitation of an otherwise healthy 28-year-old Gravida4-Para3 female with severe post-partum hemorrhage due to uterine eversion requiring surgical intervention, massive transfusion and a damage control laparotomy. The patient suffered an apparent amniotic fluid embolus, precipitating 2 cardiopulmonary arrests and Acute Respiratory Distress Syndrome). Because of inability to adequately oxygenate the patient despite ventilator settings of TV 500, PEEP of 18, RR of 30, 100% FiO₂, and inhaled nitric oxide, the ECMO team was consulted to initiate salvage therapy. Femoral-femoral cannulation for VV-ECMO was performed – specifically, percutaneously, a 25-French venous drainage and a 23-French inflow cannula were placed at the bedside in the ICU and connected to an ECMO circuit (Medtronic BioMedicus, Medtronic USA). Adequate flows and function were achieved and successfully brought oxygenation to 97%. Patient required ECMO support for four days, and discharged to home after a 24-day hospital stay. Total blood product utilization during hospitalization was 80 units; 59 products prior to ECMO, 14 products during ECMO, and 7 units after ECMO. Three months postpartum, mother and baby are healthy without end-organ damage.

While on ECMO, the patient required operative removal of perihepatic packing placed in the ICU for bleeding, as well as suturing of the liver, and in the OR, the surgical packing and intra-abdominal clot were removed. Additionally, the patient developed right ventricular clot, requiring low-dose anticoagulation, resolved per serial echocardiograms.

The Hospital approved a formal ECMO therapy program a month prior. The collaborative development of the criteria to identify patients for VV ECMO, based on the CESAR and EOLIA trials and creation of protocols and education of all ICU physicians, nurses and respiratory therapists on ECMO criteria helped identify this obstetric patient for ECMO – in part because our Institutional protocol recognized the potential for “unconventional” application of ECMO beyond the most common indications of acute cardiogenic shock and infectious pneumonia. Creation of an ECMO cart allowed for one-hour deployment and cannulation in the ICU.

Summary: Rapid deployment of VV ECMO was life-saving for a young mother with severe ARDS following postpartum hemorrhage, cardiopulmonary arrest, massive transfusion, and amniotic fluid embolism at a hospital that had just implemented their ECMO program. All ECMO programs must consider unusual patient populations, such as obstetrics and the needed surgical interventions, when considering salvage interventions.

ID: 493

Topic: Cardiovascular Surgery » ECMO

Presentation Type: Oral

OUTCOME OF ECMO THERAPY IN CARDIOGENIC SHOCK: A PROGNOSTIC CORRELATION WITH LACTATE CLEARANCE

Sanjay Kumar¹, Vladimir Schumater²

¹Institute of Medical Sciences, Banaras Hindu University, Varanasi, India

²Yale University School of Medicine, New Haven, United States

**Corresponding Author (sanjaykr33@hotmail.com)*

sanjaykr33@hotmail.com, sanjaykr33@hotmail.com

Abstract Text

BACKGROUND:

Extracorporeal membrane oxygenation (ECMO) is one of the methods used to provide temporary mechanical support of the cardiac and/or pulmonary function for patients in the refractory cardiogenic shock. We evaluated the dynamic lactate indices during the ECMO therapy and its prognostic role on mortality.

METHODS:

We gathered data on all consecutive patients between February 2016 and November 2018 who were treated with ECMO therapy longer than 48 h. The Blood lactate level before ECMO implantation and at specific time points during ECMO support were studied. In this study, the Lactate clearance at specific time points (Lactate clearance-1) and the duration that lactate cleared more than 10% of the initial lactate level (Lactate clearance-2) was measured. We did statistical analysis of the data to predict 30-day mortality.

RESULTS:

36 patients underwent ECMO therapy for refractory cardiogenic shock resulting in 68% mortality. The lactate levels before and after ECMO therapy as well as the dynamic changes were significantly correlated with mortality variable. With ROC calculation, LC-2 has a significant discrimination (AUC = 0.94) on 30-day survivors and nonsurvivors. LAE-LBE (AUC = 0.678), L48-LBE (AUC = 0.607) showed moderate predictive power on 30-day mortality.

CONCLUSIONS:

Based on our results, an early insertion of ECMO before lactate gets high was suggested. Serial changes on lactate levels and calculation of its clearance may be superior to single lactate value on both effective circulatory support and as prognostic prediction marker. LC-2 showed a strong discrimination on 30-day mortality.

ID: 424

Topic: **Cardiovascular Surgery » Perfusion Course**Presentation Type: **Oral****CPB MANAGEMENT USING HIGH-VOLUME CONTINUOUS HEMOFILTRATION****Vadim Popov**, Georgiy Plotnikov, Vladimir Chagirev, Giorgiy Edzhibiya, Amiran Revishvili*A.V. Vishnevsky National Medical Research Center of Surgery, Moscow, Russia***Corresponding Author (la4ge@yandex.ru)**la4ge@yandex.ru, la4ge@yandex.ru, la4ge@yandex.ru, la4ge@yandex.ru, la4ge@yandex.ru***Abstract Text**

BACKGROUND: This prospective study's goal was to determine continuous hemofiltration effectiveness for CPB management

METHODS: Prospective controlled clinical trial included 62 open-heart surgery patients with the CPB by roller pump and duration more than 180 min. Patient's mean age was 67±14 (min 45, max 82). 1st group (controlled, n=29) included standard CPB, 2nd group (analyzed, n=33) included CPB with the high-volume hemofiltration using polyionic buffered solution 80 ml/min. Hemofiltration has been also supported by ultrafiltration when hydrobalance maintenance was needed at the level of 8-10 ml/kg. Anesthesia protocol was standard; myocardial protection was administered with Custodiol® solution. Main preoperative clinical data was comparable in both groups. To evaluate the perfusion aggressiveness, following laboratory tests were made: IL-6, IL-10, WBC, PLT, procalcitonin, lactate, C-RP and metalloproteinase. Check points were before, right after the surgery and in 24 h. Presence of respiratory and renal complications, drainage blood loss, hemostasis disorders, ICU and in-hospital stay were also analyzed.

RESULTS: IL-6 level in 2nd group was significantly lower (p=0,0017) and did not exceed 7,4 pg/ml. C-RP, metalloproteinase and procalcitonin levels were lower too, but not statistically significant. Lactate level in analyzed group was in reference range, while in control group after perfusion it increased to 8,3±4,2 mmol/l. 3 patients (10,3%) from controlled group had the hemostasis disorders, while in analyzed group they did not occurred at all. Blood transfusion occurrence was the same in both groups. Renal dysfunction, requiring dialysis, was diagnosed in 6 (20,7%) patients from controlled group vs. 2 patients (6,1%) from analyzed group. Respiratory insufficiency developed in 3 patients (10,3%) only in controlled group. In-hospital stay was significantly lower in analyzed group - 10±1 days vs 25±2 days in controlled group, and so was the ICU length - 2±1 vs 4±2 respectively. Polyorganic insufficiency syndrome (POIS) occurred in 3 patients(10,3%) from the controlled group.

CONCLUSIONS: CPB management using continuous hemofiltration with polyionic buffered solution reduces the incidence of specific complications.

ID: 358

Topic: Cardiovascular Surgery » ECMO

Presentation Type: Oral

SUCCESSFUL MANAGEMENT OF A PATIENT WITH MASSIVE PULMONARY EMBOLISM COMPLICATED WITH CARDIOPULMONARY SHOCK BY IMPLEMENTING EXTRACORPOREAL MEMBRANE OXYGENATION

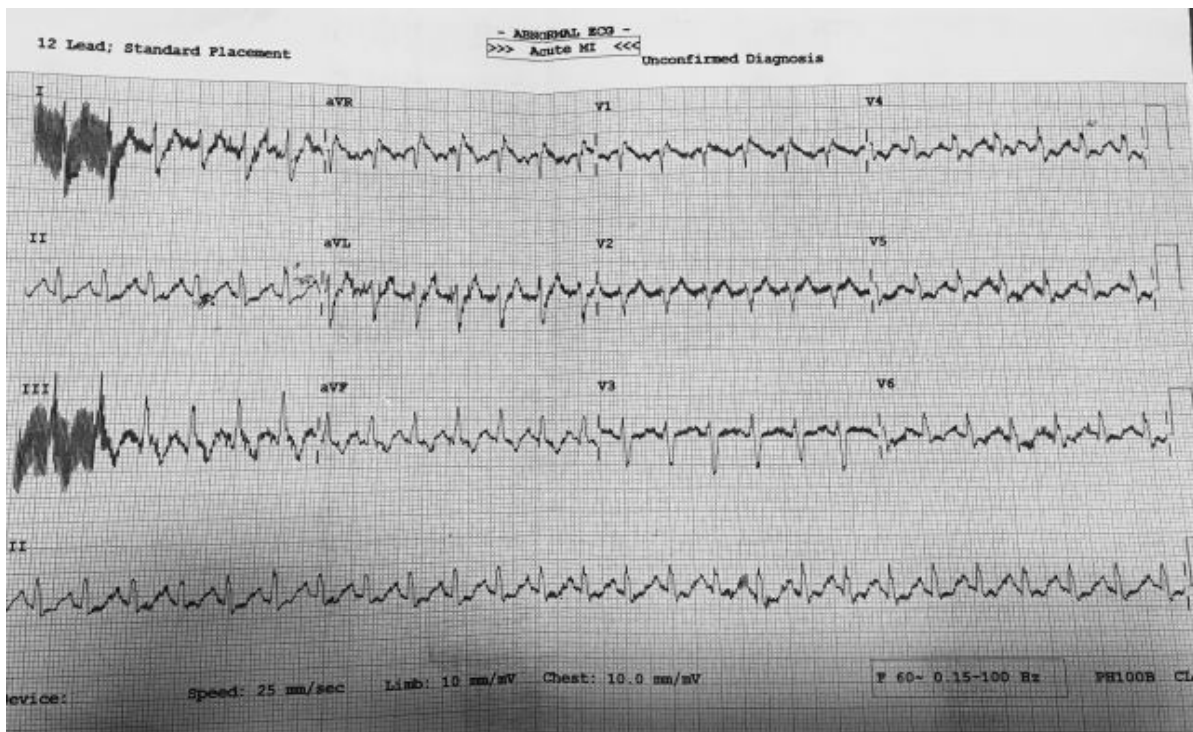
Umut Kocabaş, Deniz Kızılay, Hakan Altay, Vedat Bakuy, Gülay Eren, Deniz Süha Küçükaksu

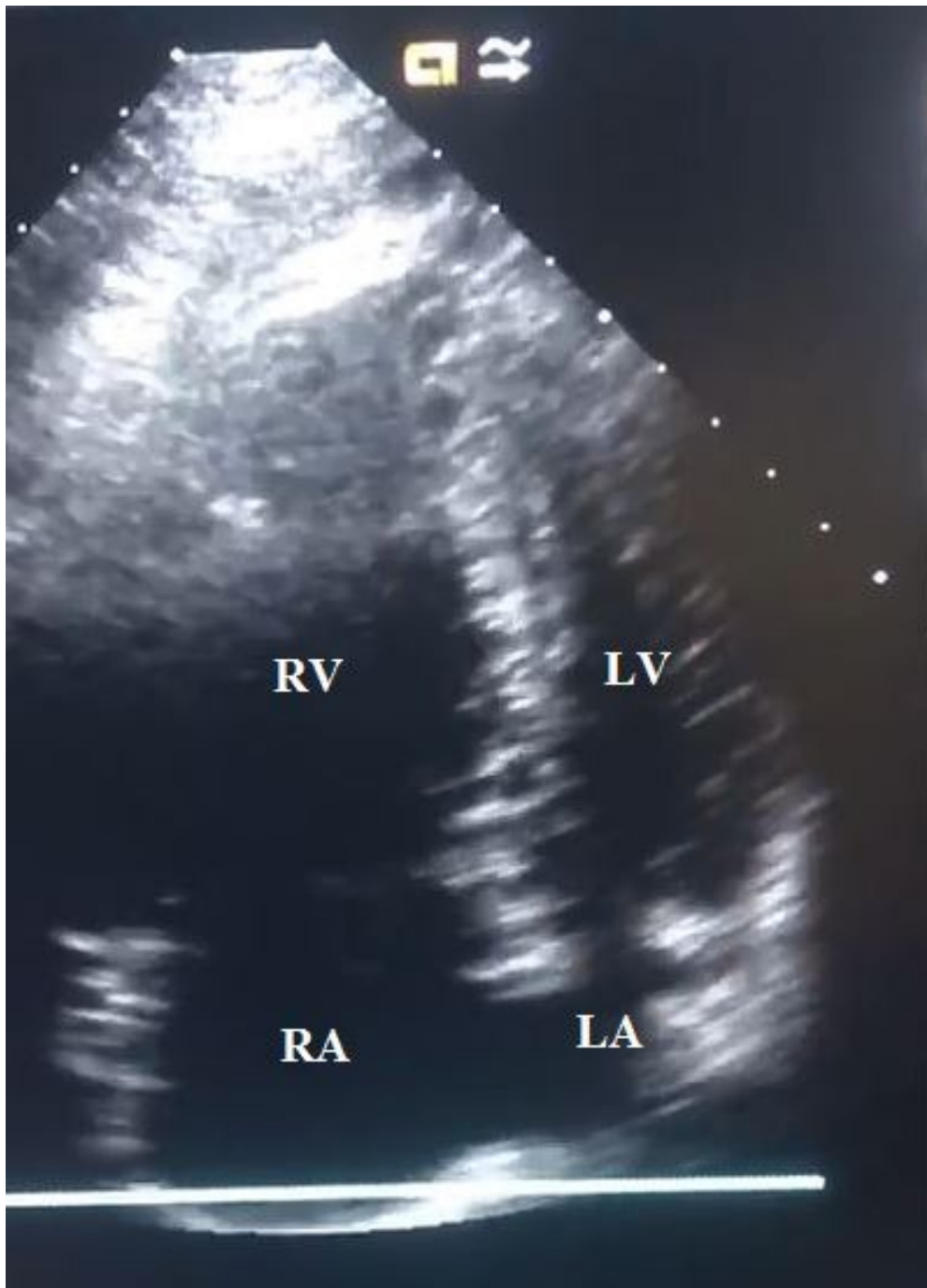
Başkent University School of Medicine, Istanbul, Turkey

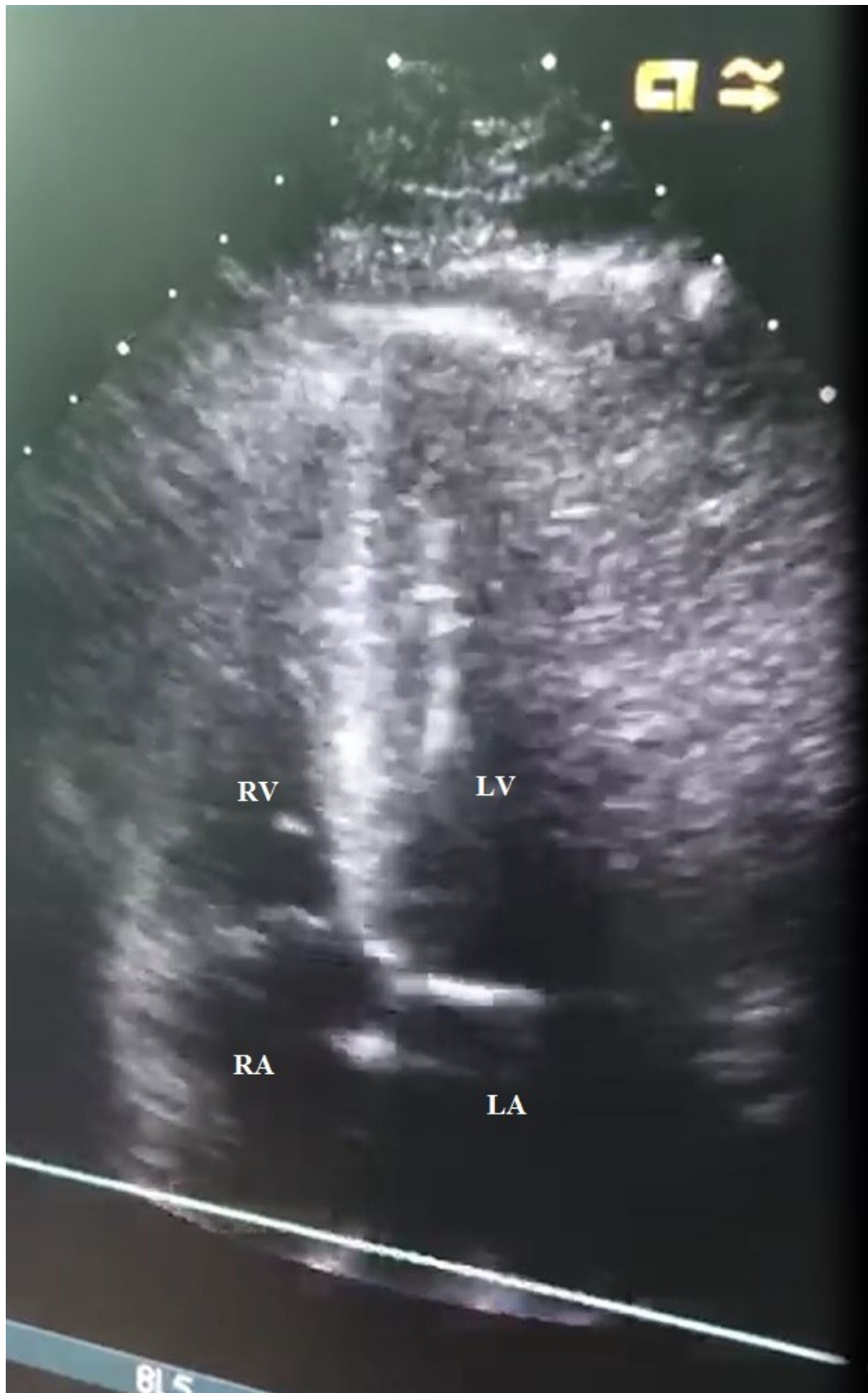**Corresponding Author (umutkocabas@hotmail.com)*

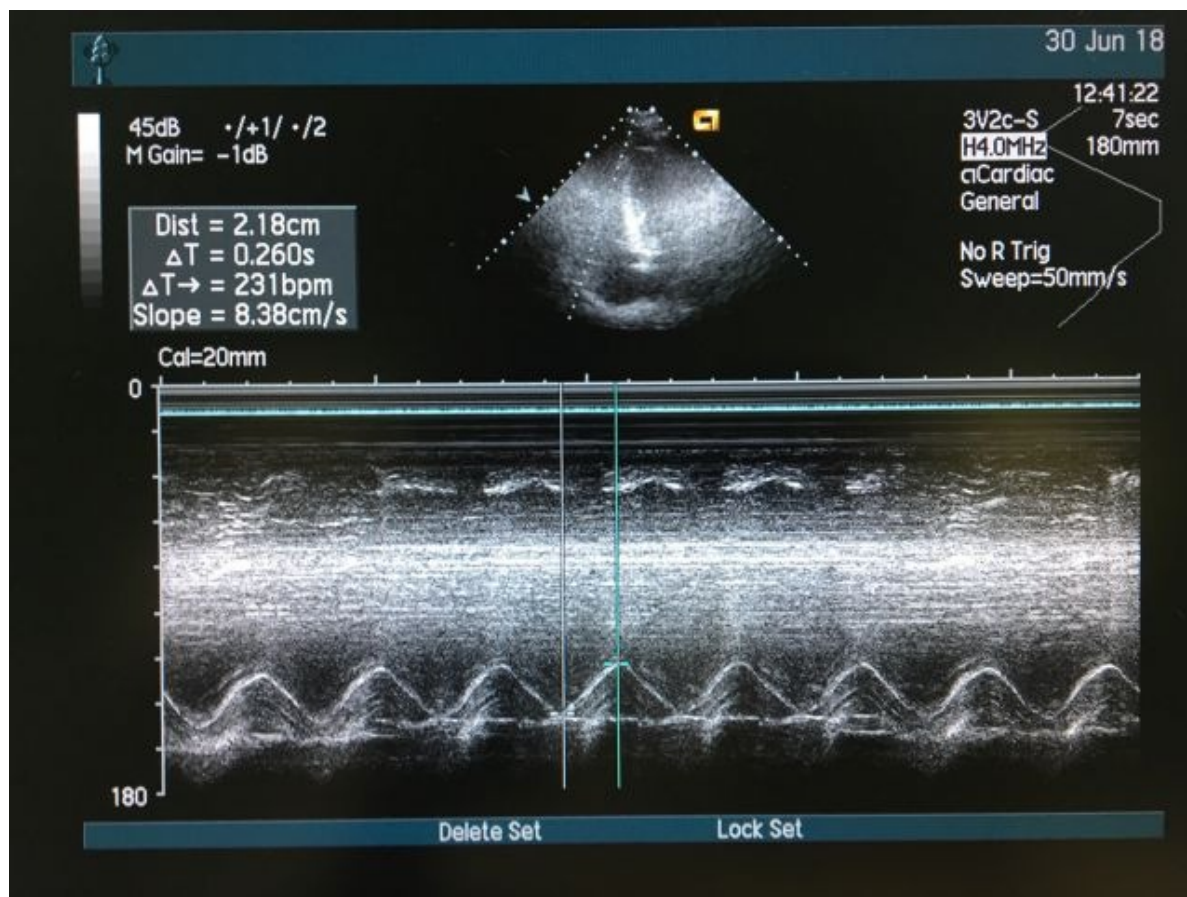
umutkocabas@hotmail.com, denizkizilay@yahoo.com, sakaltay@gmail.com, vedatbakuy@hotmail.com, gulayeren@hotmail.com, suha.kucukaksu@gmail.com

Abstract Text









BACKGROUND: We hereby present a patient with cardiogenic shock and acute respiratory failure who was successfully managed with the presumptive diagnosis of massive PE.

CASE: A 26-year-old man with a history of tibia fracture presented to ED in acute respiratory failure and cardiogenic shock. Initial systolic BP was 80 mmHg and HR was 126 bpm. Blood gas analysis showed hypoxia, hypocarbia and lactic acidosis. Electrocardiography revealed sinus tachycardia along with S wave in lead I, Q wave and inverted T wave in lead III (Figure 1). During diagnostic work-up, cardiopulmonary arrest occurred, the patient was intubated and cardiopulmonary resuscitation (CPR) was initiated. As the patient was unresponsive to the initial CPR therapy along with iv vasopressor therapy, bedside transthoracic echocardiography (TTE) was performed concurrently with CPR which revealed severe right ventricular dilatation with poor systolic function, moderate tricuspid regurgitation (TR) with a systolic pulmonary artery pressure (sPAP) of 50 mmHg (Figure 2). In the light of these examinations, acute PE was suspected and iv unfractionated heparin plus systemic thrombolytic therapy (TT) with infusion of tissue plasminogen activator at a rate of 50 mg/h for 2 hours were started immediately. At the 45th minutes of CPR, TT stopped and the patient transferred to operating room under CPR and femoro-femoral veno-arterial extracorporeal membrane oxygenation (ECMO) (Medos Medizintechnik AG, Germany) was initiated with a 23 Fr venous and 17 Fr arterial cannula with restoration of systemic blood flow and oxygen delivery (4.5 L/min, 3600 rpm). On the next day, pulmonary angiography was performed under ECMO support in the catheterization laboratory which demonstrated filling defects of the left lobar arteries which were consistent with acute PE. After 24 hours, bedside TTE showed complete recovery of right ventricular function with a tricuspid annular plane systolic excursion 24 mm and mild TR with a sPAP of 35 mmHg (Figure 3-4). Patient was weaned from ECMO after 43 hours without hemodynamic deterioration. After weaning from mechanical ventilation and deep-sedation, patient woke-up with right hemiparesis. Cranial CT demonstrated left middle cerebral artery territory infarction due to possible ECMO-related thromboembolism. During hospital stay, patient was followed-up with rivaroxaban 20 mg/day and stroke rehabilitation programme. At the end of 20 days, patient was discharged from hospital with mild neurological sequelae.

CONCLUSION: Management of PE guidelines recommends TT in patients with massive PE complicated by cardiopulmonary arrest. On the other hand, ECMO is suggested to provide cardiopulmonary circulatory support in patients with high-risk PE complicated with sustained hemodynamic and respiratory failure despite initial TT and vasopressor therapy. To conclude, combined usage of TT and ECMO is an important therapeutic strategy in acute massive PE and cardiopulmonary arrest.

ID: 364

Topic: Cardiovascular Surgery » ECMO

Presentation Type: Oral

EXPERIENCES OF PEDIATRIC EXTRACORPOREAL MEMBRANE OXIGENATION

**Nur Dikmen Yaman, Burcu Arıcı, Ata Niyazi Ecevit, Semih Ufuk Tezeren, Tanıl Kendirli, Tayfun Uçar,
Zeynep Eyiletten, Adnan Uysalel**

Ankara University School of Medicine, Ankara, Turkey

**Corresponding Author (nurdikmen@yahoo.com)*

*nurdikmen@yahoo.com, burcuincekalan@hotmail.com, drataecevit@gmail.com,
semihufuktezeren@hotmail.com, tanilkendirli@hotmail.com, tayfunucar@yahoo.com, zeyiletten@gmail.com,
uysalel@gmail.com*

Abstract Text

Introduction

Extracorporeal membrane oxygenation (ECMO) is a life-saving treatment for pediatric patients with respiratory and/or cardiac failure. The ECMO circuit oxygenates and sometimes pumps the blood, effectively replacing lung and/or heart function temporarily. ECMO patients are clinically very complex not only because of their underlying, life-threatening pathology, but also because of the many physiological parameters that must be monitored and adjusted to maintain adequate tissue perfusion and oxygenation.

Patients

A total of 80 pediatric ECMO cases were identified for the study period between April 2014 and October 2018. Of the 80 cases, overall survival to discharge rate was 23,7%. Decannulation rates were 41,25%. Median age was 1 year.(min, max:1,17). Median hospital stay was 13 days (min, max: 1,98).

Factors effecting mortality according to our study were prior diagnosis, asidosis, lactate levels, liver and kidney functions and hipoalbuminemia.

	<u>Decannulation (%)</u>	<u>Survival to discharge (%)</u>
Dilated KMP	40	20
Restrictive KMP	0	0
<u>Acute myocarditis</u>	42,8	14,2
E-CPR	23,2	7,6
Trauma	0	0
<u>Respiratuar causes(Pneumonia, ARDS)</u>	57,1	42,8
Malignity	16,6	0
Metabolic diseases	0	0
After other surgical procedures	0	0
<u>Congenital heart surgery</u> <u>Postcardiotomy n:6</u> <u>Low cardiac output n:11</u> <u>Preoperative n:3</u>	70	45,4

Discussion

Since the inception of the Extracorporeal Life Support Organization (ELSO) in 1989, approximately 98,840 patients have benefited from ECMO worldwide (41% neonate, 23% pediatric, and 36% adult).

ECMO can be veno-venous (VV ECMO), used in respiratory failure with normal cardiac function, or veno-arterial (VA ECMO), used in cardiac or cardiopulmonary failure. VA ECMO may also be used in neonates with respiratory failure.

There are several goals in pediatric ECMO use. The bridge to recovery strategy replaces the heart and/or lung functions until the host's organs recover. In the bridge to decision strategy, ECMO stabilizes the patient to buy time for assessing end organ function and re-evaluating treatment goals.

Common ECMO complications are vascular, including bleeding, thrombosis, embolism, ischemia and vessel damage. Additional complications are equipment-related, such as cannula kinking or fracture, cannula malposition and equipment failure.

Monitoring the ECMO program for morbidity, comparing results with national benchmark data, such as provided by the ELSO registry, and striving to become an ELSO Center of Excellence are all important goals.

As technology continues to advance, ECMO and related therapies will continue to evolve. Research to reduce complications, obtain more data on both short-term and long-term outcomes and review the cost-benefit of this lifesaving but resource-heavy technology is ongoing.

ID: 102

Topic: Cardiovascular Surgery » ECMO

Presentation Type: Oral

SIDE GRAFT PERFUSION IS ASSOCIATED WITH HIGHER INCIDENCE OF BLEEDING THAN PERCUTANEOUS PERFUSION FOR ECMO THERAPY

Cemal Kemaloğlu

Akdeniz University, Antalya, Turkey

**Corresponding Author (cemalkemaloglu@hotmail.com)*

cemalkemaloglu@hotmail.com

Abstract Text

OBJECTIVE:

To Evaluate the different complications for different techniques for ECMO therapy.

METHODS:

19 ECMO patients is divided in two groups: First group is consisted of patients with direct percutaneous arterial cannulation with a backflow cannula(N=10) while an end to side graft anastomosis was made to patients in group 2.(N=9). After initiation of ECMO perfusion, patients were evaluated for complications related to arterial cannulation.

RESULTS:

One patient's arterial cannulation was converted from axillar artery to percutaneous femoral artery by Seldinger technique due to hemorrhage in axillar artery cannulation site. One Patient with arterial cannulation through a femoral graft had arterial re-cannulation three times due to bleeding. First, arterial cannulation through a femoral graft was performed to the contralateral leg, then femoral cannulation was made percutaneously form to first cannulation site percutaneously. None of the cases developed ischemic leg complications Vascular complications (dissection, rupture etc) requiring surgical treatment were not found in both groups. There was no episodes of cannula related infection in both groups. But in group 2, 2 patient had graft infection and separation at anastomosis. There was significantly higher rate of bleeding in group 2. Seven patient had bleeding and they all required surgical re-exploration. Grafting technique was abandoned because of this high rate of bleeding.

CONCLUSIONS:

There is no statistically significant difference between two techniques in terms of avoiding ischemia of cannulated extremity while grafting technique has much more bleeding complication which is statistically significant.(p<0,001)

ID: 540

Topic: Cardiovascular Surgery » Medical and Surgical Treatment of Heart FailurePresentation Type: **Oral****PROGNOSTIC INDICATORS OF SUCCESSFUL OUTCOME FROM ECMO IN PATIENTS WITH FULMINANT MYOCARDITIS**Sanjay Kumar¹, Vladimir Schumaster²¹*Institute of Medical Sciences, Banaras Hindu University, Varanasi, India*²*Yale University School of Medicine, New Haven, CT, United States***Corresponding Author (sanjaykr33@hotmail.com)**sanjaykr33@hotmail.com, sanjaykr33@hotmail.com***Abstract Text****AIMS:**

Fulminant myocarditis (FM) is an inflammatory disease of the myocardium that causes acute onset of heart failure. FM has a rapidly progressive course, resulting in cardiogenic shock. Treatment often requires mechanical circulatory support, including extracorporeal membrane oxygenation (ECMO) and ventricular assist device (VAD) implantation. This study aims to clarify the prognostic indicators of successful weaning from ECMO in FM patients.

METHODS:

We studied 29 consecutive FM patients supported by percutaneous ECMO as the initial form of mechanical circulatory support between January 1998 and December 2018 in our hospital.

RESULTS:

Twenty-two (59%) patients were successfully weaned from ECMO, while 15 (41%) were not. There were significant differences in levels of peak creatine kinase and those of its MB isoform (CK-MB), cardiac Troponin I (cTnI), left ventricular wall thickness (LVWT), and prevalence of cardiac rhythm disturbances. Receiver operating characteristic curve analysis revealed that a peak CK-MB level of 185 IU/L, cTnI of 12 ng/mL and LVWT of 11 mm were the optimal cut-off values for predicting successful weaning from ECMO (areas under the curve, 0.87 and 0.89, respectively). During the follow-up [median 52 (interquartile range 8-116) months], 78% of FM patients who were weaned from ECMO survived, with preserved ejection fraction and fractional shortening based on echocardiography. Of the 9 FM patients who were not weaned from ECMO, 7 bridged to VAD, and only three were successfully weaned from VAD and survived.

CONCLUSIONS:

These results indicate that myocardial injury, as evidenced by CK-MB and cTnI alongwith LVWT, and prolonged presence of cardiac rhythm disturbances are prognostic determinants of successful weaning from ECMO.

ID: 238

Topic: Cardiovascular Surgery » Risk Management in Cardiovascular Diseases

Presentation Type: Oral

THE PREDICTIVE VALUE OF LEFT VENTRICULAR MASS INDEX ON POSTOPERATIVE OUTCOMES AND MAJOR ADVERSE EVENTS IN PATIENTS UNDERGOING CABG

Mehmet Dedemoğlu

Mersin City Educational and Training Hospital, Mersin, Turkey

*Corresponding Author (mehmetdedemoglu@yahoo.com)

mehmetdedemoglu@yahoo.com

Abstract Text

Objective: Increased left ventricular mass has been demonstrated to be an independent predictor for mortality and major adverse event including coronary artery disease, stroke and heart failure. However, there has been few report about the impact of left ventricular mass on postoperative outcomes after coronary artery bypass grafting (CABG). The purpose of our study is to determine to the predictive value of left ventricular mass index on postoperative outcomes and major adverse cardiac and cerebral event in patients undergoing CABG.

Methods: We analyzed patients with left ventricular mass index data in a retrospective registry enrolling consecutive patients undergoing CABG in our clinic. The formula developed by Devereux was utilized to calculate left ventricular mass index. Primary outcome of interest was major adverse cardiac and cerebral event and postoperative outcomes including low cardiac output syndrome (LCOS), prolonged intensive care unit (ICU, >24 hours) and hospital stays (>7 days). Major adverse cardiac and cerebral event is defined as an all-cause mortality, cerebrovascular event and early graft occlusion requiring surgical intervention. Univariate and multivariate logistic regression analyses were used to determine the predictive risk factor(s) for postoperative outcomes and major adverse cardiac and cerebral event.

Results: 313 patients were included into the study. Mean age was 59.2±9.6 years and 252 (80.5%) out of patients were male gender. Mean left ventricular mass index value was 106.9±24.2 g/m². 31 (9.9%) patients had major adverse cardiac and cerebral event, 11 (3.5%) patients had LCOS, 55 (17.6%) patients had prolonged ICU stay and 102 (32.6%) patients had prolonged hospital stay. The hospital mortality was also seen in 6 (1.9%) patients. In the multivariate analyses: age, symptomatic carotid lesion, left ventricular mass index and cardiopulmonary bypass (CPB) time for major adverse cardiac and cerebral event; left ventricular mass index and CPB time for LCOS; age, symptomatic carotid lesion, pulmonary arterial pressure > 25 mmHg and CPB time for prolonged ICU stay; age and cross clamp time for prolonged hospital stay were found to be an independent predictor after CABG (Table).

Conclusions: The predictive value of left ventricular mass index on poor postoperative outcomes in patients undergoing CABG was demonstrated with the help of our study. Therefore, we suggest that preoperative left ventricular mass index should be evaluated in the candidates for CABG before the surgical intervention in order to prevent postoperative poor results.

Table: Multivariate analyses for MACCE and the other postoperative outcomes

Variables	OR	95% CI lower	95% CI upper	P value
MACCE				
Age	1.06	1.01	1.10	0.02
Symptomatic carotid lesion	7.87	1.12	55.17	0.04
LVMi	1.02	1.00	1.03	0.01
CPB time	1.02	1.01	1.03	0.001
LCOS				
LVMi	1.03	1.01	1.06	0.005
CPB time	1.04	1.02	1.06	<0.001
Prolonged ICU stay				
Age	1.05	1.01	1.09	0.007
Symptomatic carotid lesion	8.16	1.22	54.44	0.030
PAP > 25 mmHg	5.55	1.65	18.63	<0.001
CPB time	1.02	1.01	1.03	0.006
Prolonged Hospital stay				
Age	1.04	1.01	1.07	0.005
Cross clamp time	1.01	1.00	1.02	0.007

CBP: Cardio pulmonary bypass, CI: Confidence interval, ICU: Intensive care unit, LCOS: Low cardiac output syndrome, LVMi: Left ventricular mass index, MACCE: Major adverse cardiac and cerebral event, OR: Odds ratio, PAP: Pulmonary arterial pressure.

Oral Presentations

Evaluation in Endovascular Techniques

Date: 29.03.2019 Time: 16:45 - 18:15 Hall: 6

ID: 67

Topic: Cardiovascular Surgery » Endovascular Surgery

Presentation Type: Oral

EARLY RESULTS OF PERCUTANEOUS TREATMENT OF ACUTE ARTERIOVENOUS FISTULA THROMBOSIS WITH PHARMACOMECHANICAL THROMBECTOMY DEVICE

Cemal Kocaaslan

Istanbul Medeniyet University Goztepe Education and Research Hospital, Istanbul, Turkey

**Corresponding Author (cemalkocaaslan@yahoo.com)*

cemalkocaaslan@yahoo.com

Abstract Text

Purpose:

Arteriovenous fistulas, especially radiocephalic fistulas, are the most offered vascular access type for hemodialysis but thrombosis is a common complication that may be seen during long follow-up. The AngioJet Hemolytic Thrombectomy Device "AngioJet" (Boston Scientific, Marlborough, MA, USA) is a pharmacomechanical thrombectomy device that can be used for the treatment of arteriovenous fistula thrombosis. We aimed to investigate the early results of the procedure that was performed with AngioJet system for thrombosed fistulas and to determine the occurred complications.

Materials and methods:

From January 2017 to June 2018, 13 patients who were admitted with acute arteriovenous fistula thrombosis and treated with AngioJet system were included in the study. Technical success, clinical success, one-month primary patency, adjunctive treatment therapies and procedure-related complications were examined retrospectively.

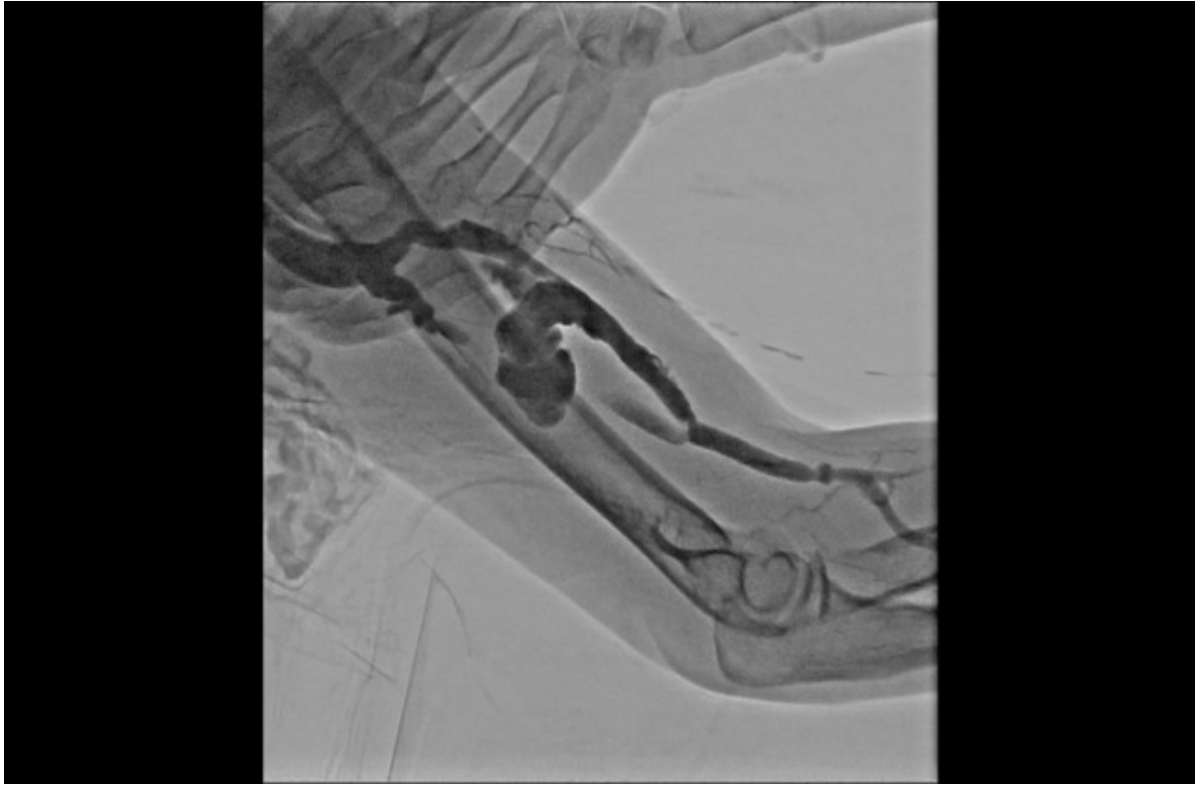Results:

Technical success was 92.3%(12/13 patients). Clinical success was 84.6% (11/13). Complications were vascular rupture (n:1), hematoma (n:2), thrombosis < 24 hours (n: 1). The one-month primary patency was 76.9% (10/13). Balloon angioplasty was performed as adjunctive treatment therapy at 11 of 13 patients (84.6%). There was no 30 day mortality.

Conclusions:

Percutaneous pharmacomechanical thrombectomy treatment for thrombosed arteriovenous fistula is a safe procedure with low complication and one-month primary patency rates and also an effective method for restoring the arteriovenous fistula with adjunctive therapy.

Figure 1: A vascular rupture occurred at the venous segment of a brachio-brachial arteriovenous fistula



ID: 388

Topic: Cardiovascular Surgery » Endovascular Surgery

Presentation Type: Oral

PHARMACOMECHANICAL THROMBECTOMY TREATMENT FOR PATIENTS WITH ACUTE ILIO-FEMORAL DEEP VEIN THROMBOSIS.

Zafer Erk¹, Kenan Abdurrahman Kara²

¹Antalya Eğitim ve Araştırma Hastanesi, Antalya, Turkey

²Yeditepe Üniversitesi Tıp Fakültesi, Istanbul, Turkey

**Corresponding Author (zafererk07@gmail.com)*

zafererk07@gmail.com, kenankaradoc@gmail.com

Abstract Text

Abstract: Deep venous thrombosis (DVT) is a life-threatening and morbid pathology which can cause pulmonary embolism or post-thrombotic syndrome even treated with anticoagulants. Endovascular treatment of acute iliofemoral deep venous thrombosis is popular and usefull method. Our aim was to summarize our results using these method.

Methods: Between 2015-2018 twenty patients with acute ilio-femoral DVT were enrolled in this study. Patients' data were recorded retrospectively. Pharmacomechanical thrombectomy treatment was applied in a single session for patients with acute ilio-femoral deep vein thrombosis. Venography was performed and each assessment was made based on lysis rates and clinical results.

Results: The median age of the patients was 62 years, the female: male ratio was approximately 2:1. The mean time between the onset of the symptoms and the procedures was 3.4 days. The total recanalization-rate was more than 70% in 3 months , 95% in 6 months follow-up. We did not find any severe PTS among our patients during the 3 and 6 months follow-up visits.

Conclusion: Invasive cathater-based therapies provides very satisfactory results in a single procedure, as a usefull method in the treatment of acute deep vein thrombosis. Our single center twenty patients group will be helpfull to have an opinion for improving our understanding and the proper management of acute deep vein thombosis.

ID: 545**Topic: Cardiovascular Surgery » Endovascular Surgery****Presentation Type: Oral****RESUSCITATIVE ENDOVASCULAR BALLOON OCCLUSION OF THE AORTA****Ali Kagan Coskun, Bilgehan Savaş Öz***UHS, Gulhane School of Medicine, Ankara, Turkey***Corresponding Author (kagancoskun@gmail.com)**kagancoskun@gmail.com, bilgehansavas.oz@sbu.edu.tr***Abstract Text**

Hemorrhage is the leading cause of preventable death following trauma especially for non-compressible torso hemorrhage. It is usually caused by the torso vessels, pulmonary parenchyma, solid abdominal organs, or pelvis bone. REBOA is a technic used to temporarily stopping blood flow in vessels for supporting of hemorrhage control using a balloon catheter. It is a minimal invasive procedure. A special designed catheter is needed for the procedure. REBOA is an option for non-compressible torso hemorrhage. Anatomical zones of aorta are the critical points for the placement of baloon. Ballon are usually placed at zone I or zone III. A temporary occlusion of blood flow is achieved up to the definitive surgery. It could be used at either trauma zone or hospital. Reboa is an alternative approach to resuscitative thoracotomy at traumatic arrests. The survival rates following using REBOA are varies between %20- 55 in selected cases. It could be suggested for non-compressible torso hemorrhage to obtain time up to definitive surgery.

ID: 519

Topic: Cardiovascular Surgery » Thoracic and Thoracoabdominal Aortic Dissections and AneurismsPresentation Type: **Oral****SUCCESSFUL PERCUTANEOUS TREATMENT OF SEVERE LEFT COMMON ILIAC STENOSIS DUE TO THE N-BCA EMBOLIZATION AFTER ENDOLEAK CLOSURE****Atila Iyisoy***Gülhane Training Research Hospital, ankara, Turkey***Corresponding Author (aiyisoy@hotmail.com)**aiyisoy@hotmail.com***Abstract Text**

In previous reports using of n-BCA has been described in the treatment of type 1 endoleak after abdominal endovascular aneurysm repair. The most feared complication of this procedure nontargeted embolization into arterial circulation and catheters being glued to the graft. In our case, we retrieved the catheter successfully but n-BCA embolized left iliac artery and cause severe stenosis. We report a case that percutaneous successful angioplasty and stent implantation of left common iliac artery due to the n-BCA material which was embolized to the left iliac artery, which is a fearful complication.

A 69-year-old man who presented to our clinic an 63x61,5 mm asymptomatic saccular aneurysm of the abdominal aorta (Fig 1A). Aneurysm was treated percutaneously with an AFX Endovascular AAA System (Endologix, USA) (Fig 1B). A type 1A endoleak was noticed during the procedure. So we decided to treat the endoleak with n-butyl-2-cyanoacrylate (n-BCA) embolization during procedure . A solution n-BCA and 50% iohexol contrast agent was prepared and was injected slowly through the pigtail catheter which was still in the aneurysm sac under the graft stent to the site of the endoleak where proximal edge of the stent graft. Subsequently, the catheter was withdrawn under the graft stent. At the end of the procedure, we noticed a moving part of solution but later it was immobil so we finished the procedure. On clinical follow-up, the patient had a great problem during walking within short distance because of feeling severe pain at his left leg. On the examination, we could not get the left lower extremity pulses including femoral artery. CT tomographic angiography showed severe stenosis of left common iliac artery probably due to the trombus material (Fig 1C). We decided to perform percutaneous intervention. A 0,014 inch hi torque 40 floppy guidewire was advanced using Judkins 6Fr diagnostic right coronary catheter via right common femoral artery approach and lesion was crossed but the balloon could not be advanced due to narrow iliac angulation because of the metallic greft material (Fig 1D). We crossed the lesion via right brachial artery using 0,014 inch hi torque 40 floppy guidewire through the right coronary catheter and then we performed angioplasty with 3,5x20 mm Invader PTCA balloon several times (Fig 1E). We crossed the lesion with the 0,035 guidewire via right brachial artery, so we used a snare to catch the 0,035 guidewire via left femoral artery retrogradely. The wire removed from left femoral sheath (Fig 1F). First, we performed angioplasty over 0,035 guidewire with a 7x30 mm periferic balloon and then we implanted a 12x30 balloon expandable stent and then angiographic result was excellent (Fig 1G, 1H). On clinical follow, his left lower extremity pulses were taken strongly. The embolized n-BCA material, very though material, was treated successfully percutaneously.

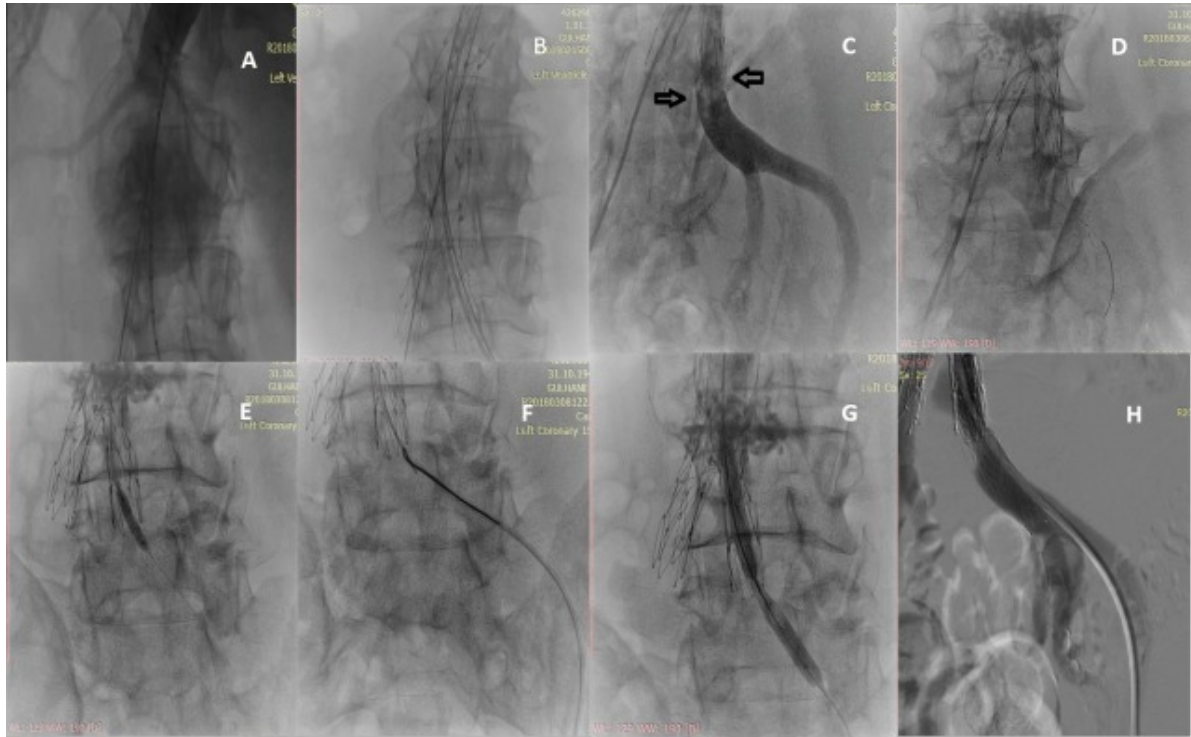

Figure 1

ID: 128

Topic: Cardiovascular Surgery » Endovascular Surgery

Presentation Type: Oral

GIANT FEMORAL PSEUDOANEURYSM AFTER CARDIAC CATHETERIZATION: REPORT OF TWO CASES

Metin Yılmaz

Aksaray Eğitim ve Araştırma Hastanesi, Aksaray, Turkey

**Corresponding Author (dr.metin_yilmaz@yahoo.com)*

dr.metin_yilmaz@yahoo.com

Abstract Text

Objectives: The most frequent injury after cardiac catheterization is iatrogenic femoral pseudoaneurysms. Especially in delayed cases, large-scale pseudoaneurysm, prominent mass effect due to common hematoma and associated ulcer /necrotic/infected skin tissue can be seen in femoral region. In such patients who have advanced age and additional risk factors, performing immediate open surgery may lead to uncontrolled bleeding (especially due to lack of exposure) may increase the risk of mortality cooperative. In these cases, stopping bleeding using an endovascular method in the preservation of intraarterial balloon and using tissue adhesives (n-butyl-cyanoacrilate) prior to surgery

may reduce the risk of uncontrolled bleeding and allow surgery to be performed with lower risk and better wound debridement and skin reconstruction.

Methods: After cardiac catheterization two patients who developed giant femoral pseudoaneurysm were intervened with endovascular method and pseudoaneurysm repair was performed. Then a patient underwent hematoma removal and wound debridement. No surgical treatment was required in the follow-up to the other patient.

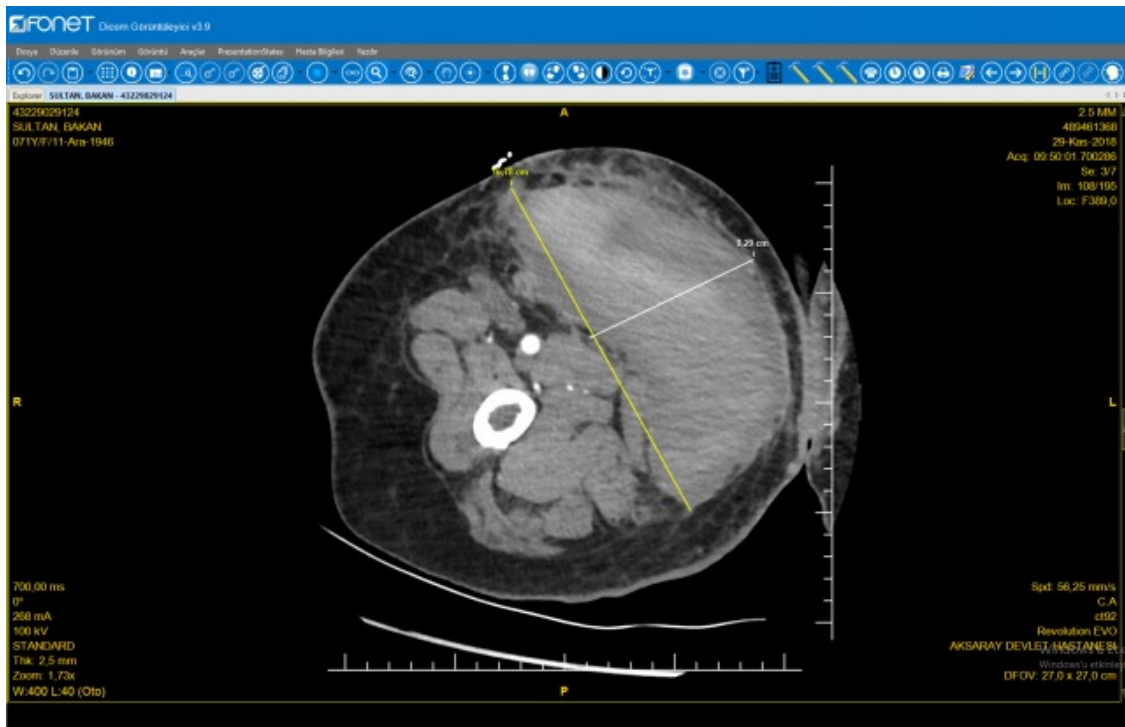
Results: Femoral pseudoaneurysm was successfully repaired in two patients with this method. No complication was observed in any patient due to the intervention. No recurrence was observed in the patients after the intervention. In addition to the patient with significant hematoma and ulcerated/necrotic wound in the groin, surgery was needed.

Discussion and Conclusion: We believe that performing percutaneous pseudoaneurysm repair in patients who develop iatrogenic femoral pseudoaneurysm, especially in delayed cases with large hematoma, and ulcerated/necrotic skin, will provide a better surgical procedures by reducing peroperative mortality.

Keywords: femoral pseudoaneurysm, balloon-assisted embolization, n-butyl-cyanoacrylate

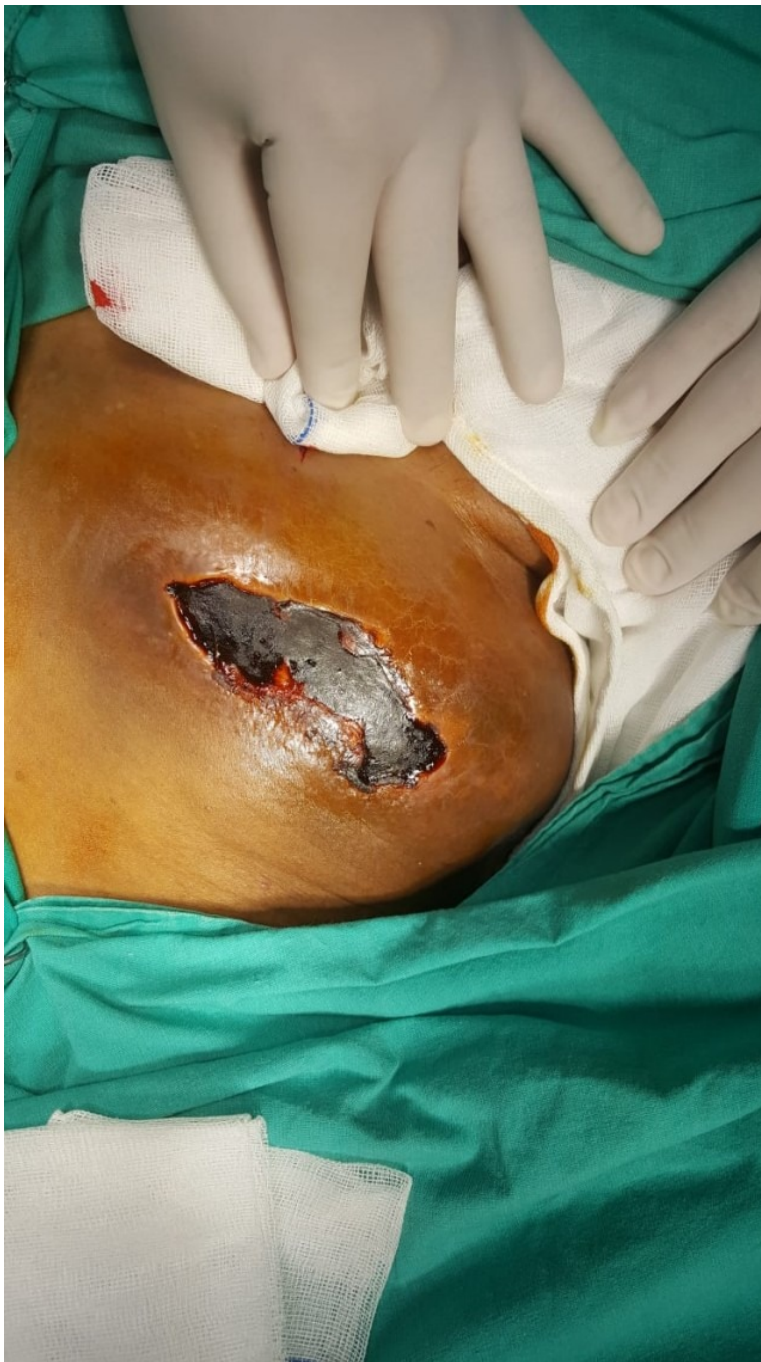

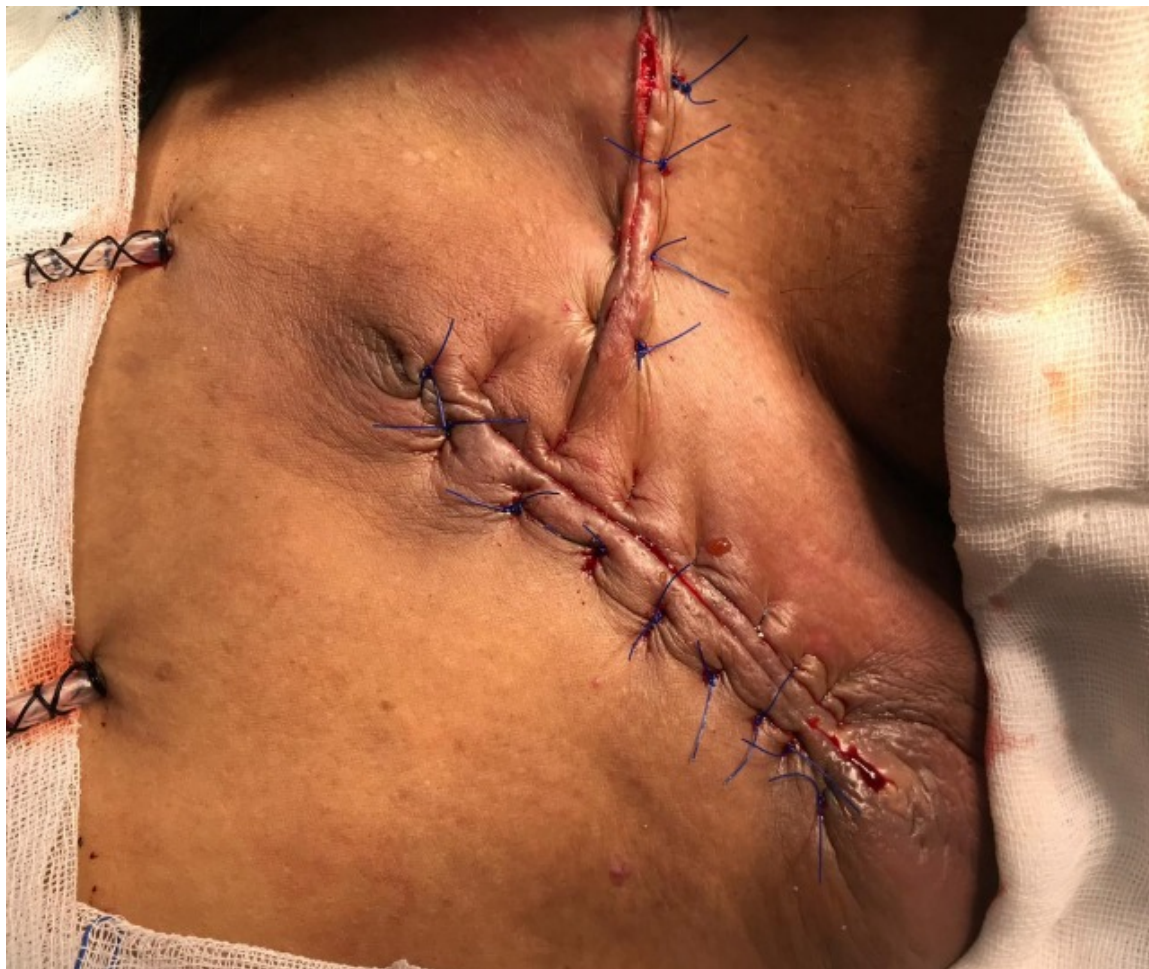Figure 1



Figur 2



Figur 3

ID: 530

Topic: Cardiovascular Surgery » Thoracic and Thoracoabdominal Aortic Dissections and AneurismsPresentation Type: **Oral****A MORTAL COMPLICATION DURING STENT IMPLANTATION FOR AORTIC COARCTATION: STENT MIGRATION TO THE AORTIC ARCH AND EMERGENCY SURGERY****Hüseyin Sicim, Hakan Kartal, Gökhan Arslan, Celalettin Günay, Bilgehan Savaş Öz***Gulhane Training and Research Hospital, Ankara, Turkey***Corresponding Author (huseyinsicim@yahoo.com.tr)**huseyinsicim@yahoo.com.tr, hakhankartal@gmail.com, drgokhanarslan@gmail.com, celalettin.gunay@sbu.edu.tr, bilgehansavas.oz@sbu.edu.tr***Abstract Text****Introduction:**

Aortic coarctation is a disease that should be treated in order to prevent complications that may cause long-term morbidity and mortality in patients. In recent years, endovascular techniques have become an alternative to surgery. Stent implantation is accepted as the first-line treatment in most adolescents and adults because of the good results of the first and the late period. However, fatal complications, such as aortic rupture, aneurysm formation, stent migration, may develop. In this case report, we present an emergency surgical approach to aortic stent migration which is a fatal complication.

Case Report:

A 22-year-old male patient was diagnosed with aortic coarctation. There is no history of additional disease or drug use. He had undergone catheterization for angioplasty and stenting of a coarctation of the aorta. Catheterization, under conscious sedation, from the right femoral artery was achieved. Balloon expandable stent implantation was performed to the coarctation segment at the beginning of the left subclavian artery. When the balloon was extinguished, the stent was migrated to the aortic arch. It was decided to remove the stent which was movable in the aortic arch and could not be fixed by endovascular methods. The patient was immediately taken into operation. Sternotomy was performed. A selective cannulation was performed to the innominate artery to remove the stent by placing X-clamp. Right atrial cannulation was performed for venous cannula. X-clamp was placed, cardiac arrest was achieved after cardioplegia, and a stent-graft was removed by aortotomy. (Figure 1) The aortotomy was closed and the operation was terminated. The patient was discharged from the hospital on the 6th postoperative day.

Discussion And Conclusion:

Aortic coarctation is a disease that can decrease life expectancy in the following years. At the beginning, open surgery option has been applied more frequently but endovascular methods have come to the fore in recent years. Although the success rates of surgery are high, interventional and invasive applications have become the first choice of treatment methods in recent years due to possible long-term complications such as aneurysm development, restenosis and hypertension. However, precautions should be taken in terms of complications that may occur during endovascular methods and the treatment strategy should be planned. As in this case, emergency surgical intervention for aortic stent migration, which is a fatal complication, can be life saving.

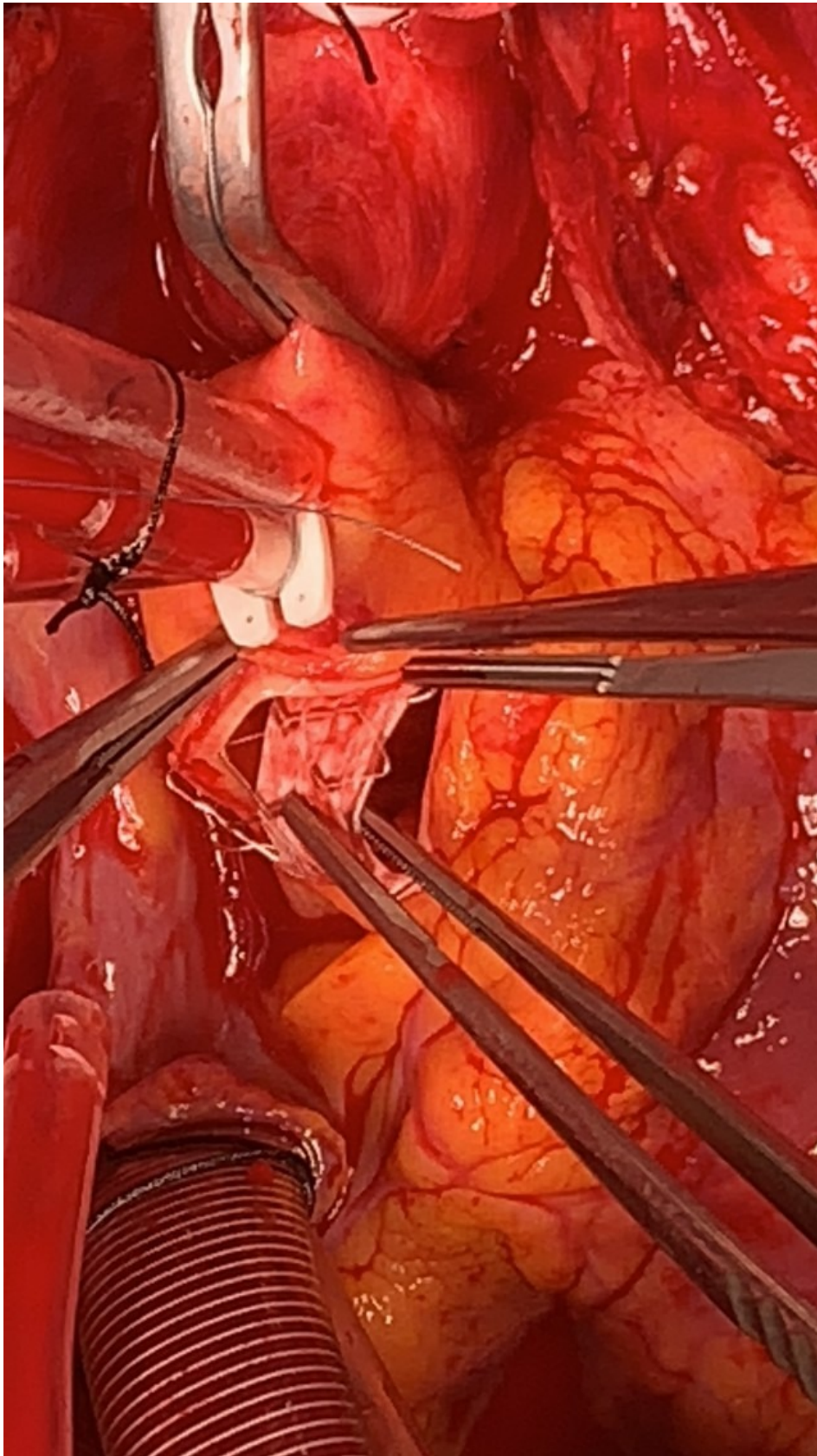


Figure 1. Removal of the stent that migration to the aortic arch by aortotomy

ID: 125

Topic: **Cardiovascular Surgery » Endovascular Surgery**Presentation Type: **Oral****ENDOASCULAR PROCEDURE HAS BECOME THE FIRST OPTION FOR NUTCRACKER SYNDROME****Ismail Selcuk, Ahmet Turan Yilmaz***SBU Sultan Abdulhamid Han Training and Education Hospital, Istanbul, Turkey***Corresponding Author (ismailselcuk35@gmail.com)**ismailselcuk35@gmail.com, atyilmaz@gmail.com***Abstract Text**

OBJECTIVE: Nutcracker Phenomenon (NCP) is described as the compression of left renal vein between superior mesenteric artery and the aorta. This causes increased renal vein pressure and renal vein dilatation proximal to the compression [2]. Nutcracker Syndrome (NCS) refers to the symptoms and findings of hematuria, orthostatic proteinuria, pelvic congestion, varicocele and flank pain due to the increased left renal vein pressure [2]. We report two patients who presented with nutcracker syndrome and underwent successful endovascular treatment with renal vein stenting.

METHODS: Two young women (age range 22 and 32 years old) presented with symptoms of fatigue, dark colored urination, severe left flank pain, blood transfusion history due to anemia admitted to our hospital. Computed tomographic angiography revealed nutcracker syndrome. Imaging studies demonstrated compression of the LRV between the superior mesenteric artery and aorta in both patients.

RESULTS: Both patients were treated with endovascular approach. The 14 x 40 mm self-expanding nitinol stents were deployed. The procedure was ended due to the reference of control angiography demonstrating stenosis was eliminated All patients were placed on clopidogrel post-operatively. On the post-operative second day, hematuria was vanished with urine analysis showing no evidence of microscopic hematuria. The duration of follow-up ranged from 3 and 17 months, both patients were asymptomatic and duplex ultrasonography demonstrated stent patency.

CONCLUSIONS: NCS should be kept in mind in the differential diagnosis of hematuria in young adults due to its life-threatening complications. Symptomatic NCS's necessitate invasive treatment. Medial nephropexy and excision of the renal varices, left renal vein bypass, transposition of the left renal vein or stent placement in the left renal vein are the treatment options [3]. Early results of endovascular approach, which is a minimally invasive surgery are encouraging surgeons to think it as a first option in treatment of NCS.

ID: 460

Topic: **Cardiovascular Surgery » Thoracic and Thoracoabdominal Aortic Dissections and Aneurisms**

Presentation Type: **Oral**

ANTEGRADE IMPLANTATION OF PREVIOUSLY FENESTRATED STENT FOR ARCH REPAIR FOR ACUTE STANFORD TYPE A AORTIC DISSECTION

Qing Zhou

The Affiliated Drum Tower Hospital of Nanjing University Medical School, Nanjing, China

**Corresponding Author (qingzhou_gl@163.com)*

qingzhou_gl@163.com

Abstract Text

Background: The best surgical strategy for acute Stanford type A aortic dissection (aTAAD) involving the arch is controversial. We have used a novel method that antegrade implanting a previously fenestrated stent for arch repair, which have revealed acceptable results.

Methods: From December 2014 to December 2016, 81 aTAAD patients (52 male, 29 female) underwent ascending aorta replacement and fenestrated stent graft implantation. The fenestrated stent graft was implanted into the true lumen of aortic arch and proximal descending aorta with the fenestration opening at the ostia of three head vessels in the arch. The proximal end of the stent graft was anastomosed to the distal end of the Dacron tube graft that replaced the proximal ascending aorta. All patients had contrast enhanced computed tomography angiography before discharge and during follow up.

Results: The cardiopulmonary bypass time was 213 ± 49 minutes, aortic cross-clamp time was 133 ± 39 minutes, and selective cerebral perfusion and lower body arrest time was 27 ± 8 minutes. There were 5 in-hospital deaths due to circulation failure (mortality 6.2%). 5 patients died during follow-up period. The surviving patients had contrast enhanced CT scans in the 3rd, 6th, and 12th months. The flow up CT revealed increasing false lumen thrombosis.

Conclusion: In patients with aTADD, the previously fenestrated stent graft results in excellent aortic remodeling of the aortic arch and descending aorta without increasing morbidity and mortality.

Oral Presentations

New Perspectives in Surgery of Aorta

Date: 29.03.2019 Time: 18:15 - 19:30 Hall: 6

ID: 22

Topic: Cardiology » Diseases of Aorta

Presentation Type: Oral

SHOULD WE STILL PREFER POSTERIOR ROOT ENLARGEMENT IN NARROW AORTIC ROOTS? RISKS AND PROGNOSSES OF MANOUGIAN AND NICKS PROCEDURES

Ünsal Vural

Dr. Siyami Ersek Cardiovascular Surgery Center, İstanbul, Turkey

**Corresponding Author (unsalvural@gmail.com)*

unsalvural@gmail.com

Abstract Text

Abstract:

Purpose:

In small aortic roots, the goal is to provide regression in ventricular hypertrophy and to increase the effort capacity by ensuring minimal gradient in the valve. In our study, we tried to analyze the superiority, feasibility and problems of Nicks and Manougian procedures in the light of literature data, independent of valve type and BSA values.

Material and Method:

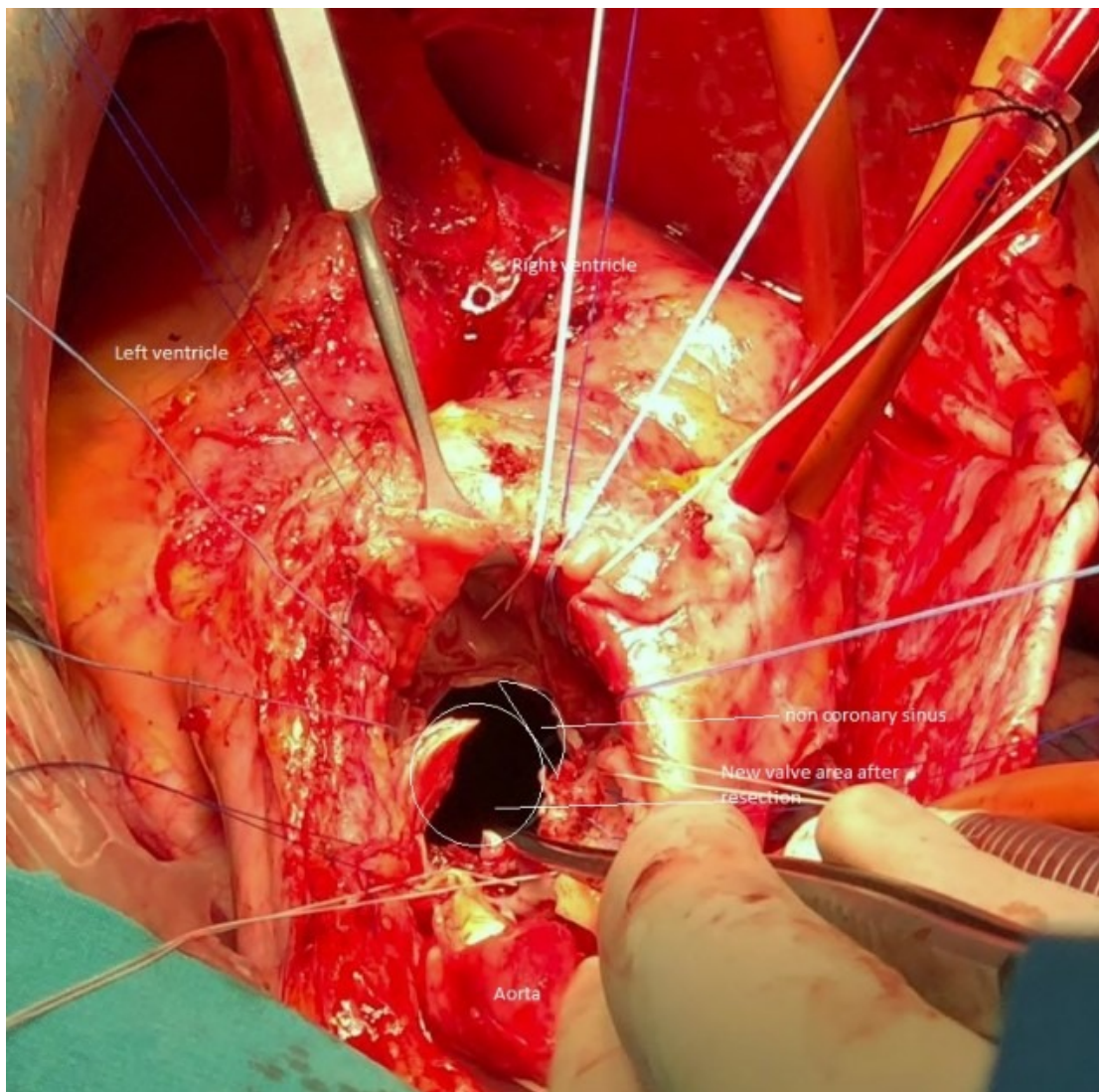
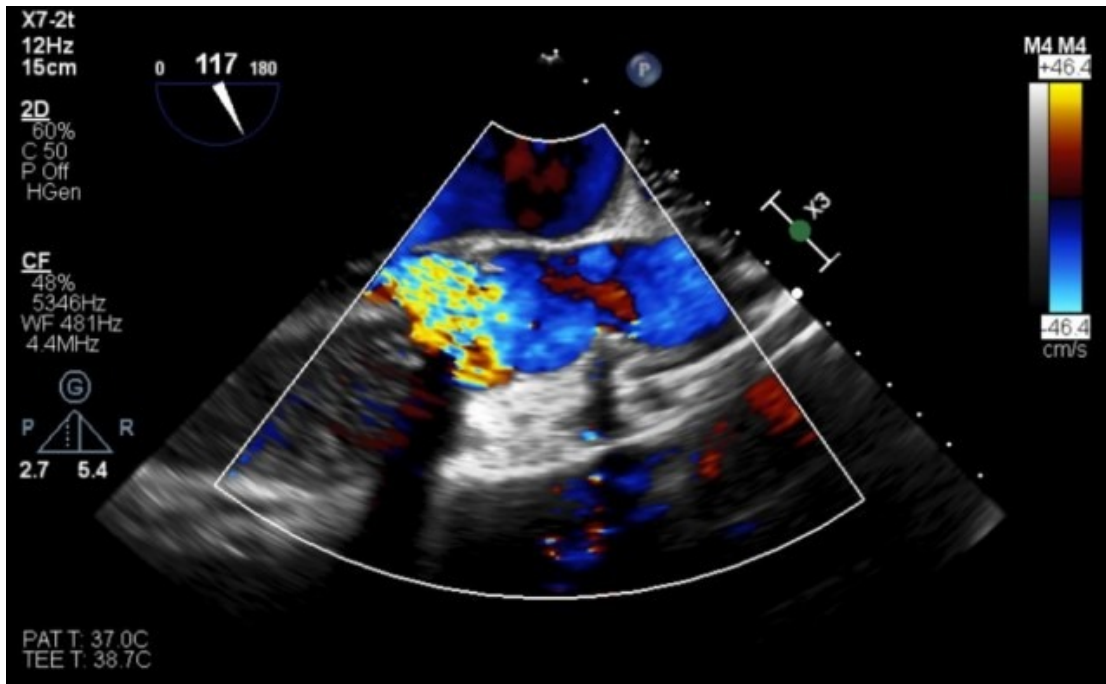
The study included patients who underwent Manougian (n=40;46,5%) and Nicks (n=46;53,5%) procedures between 2009-2017. The effects of the procedures on left ventricular functions at the postoperative 0-12th months, postoperative complications and mortality were evaluated.

Results:

Postoperative effective orifice area index was higher in the Manougian procedure (1,28Vs1,17cm/m²;p=0,001). NYHA functional capacity was decreased by 1.58±0.7 postoperatively (inter-procedures p=0,809). Early and late mortality rates for Manougian and Nicks procedures were 0% , 2,2% and 2,5%, 2,2%, respectively(p=0,641). Reoperation rate due to bleeding, thrombosis, infection and the paravalvular leak was 15% at the end of the first year (inter-procedures p=0,565). The changes of echocardiographic parameters were significant in all cases against time. On the other hand, fractional shortening and gradient changes were significantly higher for Manougian procedure compared to Nicks, while ejection fraction and septum thickness change were not significant.

Conclusion:

Although both methods had a positive effect on left ventricular function, Manougian procedure was more effective because it provided larger valve area and near-normal left ventricular function. Considering risk factors for the optimal size valve implant, the choice of root dilatation method instead of alternative prostheses doesn't affect morbidity and mortality.



		Aortic root enlargement					Total	
		Manouguian		Nicks		<u>p^a</u> <u>value</u>	<u>n</u>	<u>%</u>
		<u>n</u>	<u>%</u>	<u>n</u>	<u>%</u>			
Gender	Female	29	73	29	63	0,351	58	67
	Male	11	27	17	37		28	33
Hypertension	(-)	31	78	35	76	0,877	66	77
	(+)	9	22	11	24		20	23
Cigaret	(-)	26	65	30	65	0,983	56	65
	(+)	14	35	16	35		30	35
COPD	(-)	28	70	37	80	0,261	65	76
	(+)	12	30	9	20		21	24
Diabetes mellitus	(-)	32	80	33	72	0,374	65	76
	(+)	8	20	13	28		21	24
Mortalite	(-)	39	98	44	96	0,641	83	97
	Early	0	0	1	2,2		1	1,2
	Late	1	2,5	1	2,2		2	2,3
Reoperation	(-)	33	83	40	87	0,565	73	84,9
	Bleeding	3	7,5	2	4,3		5	5,8
	Infection	3	7,5	2	4,3		5	5,8
	Thrombosis	0	0	1	2,2		1	1,2
	p. leakage	1	2,5	1	2,2		2	2,3
Strok&TIA	(-)	39	98	45	98	0,920	84	98
	(+)	1	2	1	2		2	2
Preoperative NYHA	I	3	7	4	9	0,732	7	8
	II	9	23	10	22		19	22
	III	22	55	27	59		49	57
	IV	6	15	5	11		11	13
Postop 6 th Month NYHA	I	34	85	40	87	0,809	74	86
	II	5	12	5	11		10	12
	III	1	3	1	2		2	2
	IV	40	0	0	0		0	0
		Mean	Sd	Mean	Sd	<u>p^b</u> Value	Mean	Sd
Age		55,1	10,4	55,0	12,3	0,969	55	11,4
Cross-clamp time		70,4	6,4	67,5	5,2	0,029	68,9	5,9
Total CPB duration		96,4	6,9	95,7	5,7	0,635	96	6,3
Body surface area		1,59	0,1	1,58	0,1	0,845	1,59	0,1
Hospitalization		8,6	2,7	8,1	1,3	0,274	8,3	2,1
ICU Stay		1,2	0,4	1,4	0,5	0,149	1,3	0,5

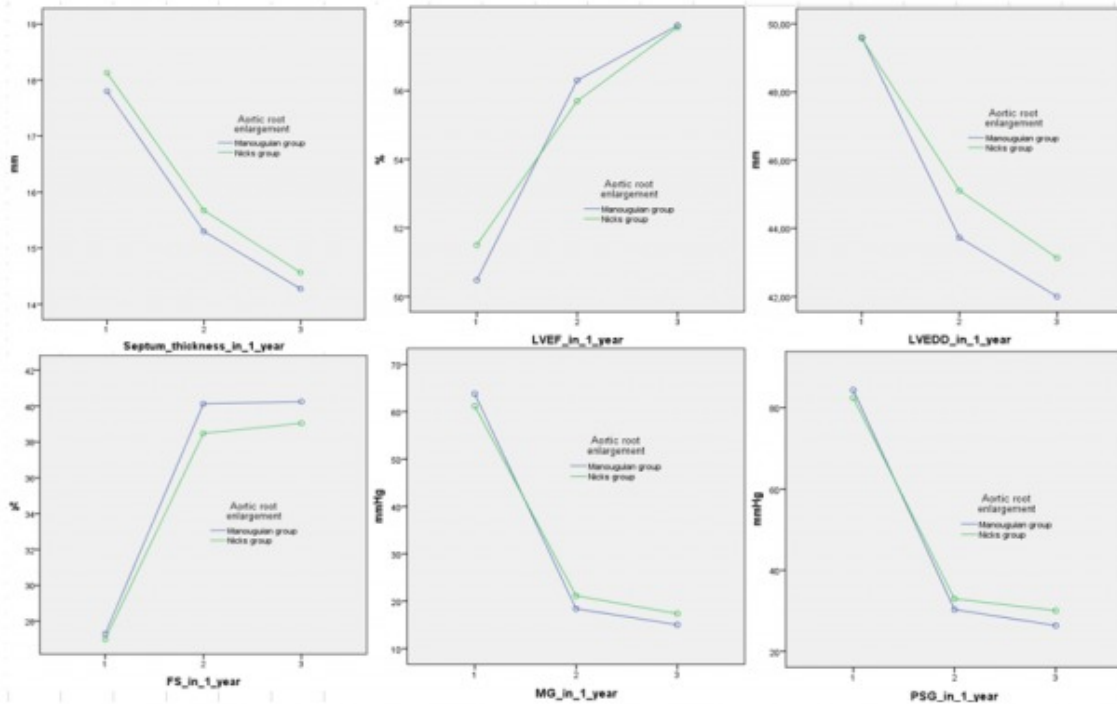
p^a= Pearson Chi-Square-test and Fisher's Exact test, p^b=undependentsample t-test

Table-1: Inter-procedure distribution of Preoperative, operative and postoperative characteristics of cases and their statistical analysis

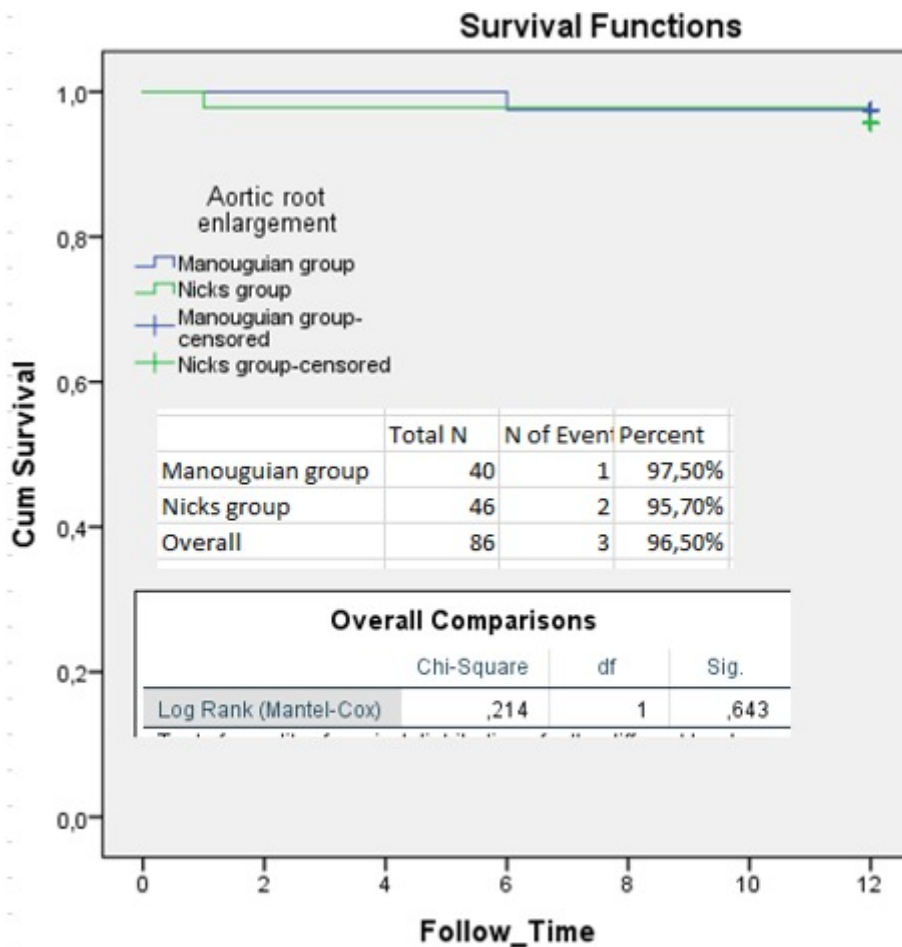
		Aortic Root Enlargement						
		Manouguian		Nicks		P ^b Value	Overall average	
		Mean	Sd	Mean	Sd		Mean	Sd
Effective orifice area index	Preoperative	0,58	0,04	0,61	0,03	0,007	0,60	0,0
	6 th ay	1,28	0,07	1,17	0,007	0,001	1,22	0,1
P value		0,001		0,007			0,001	
Left Ventricular Ejection Fraction	Preoperative	50,5	3,9	51,3	4,9	0,293	51,0	4,5
	6 th Month	56,3	3,1	55,7	0,293	0,376	56,0	3,1
	12 th Month	57,9	2,3	57,8	0,376	0,921	57,9	2,4
P ^a value		0,001		0,001			0,001	
Fractional Shortening	Preoperative	27,3	3,0	27	3,2	0,655	27,1	3,1
	6 th Month	40,1	2,7	38,5	0,655	0,002	39,2	2,5
	12 th Month	40,2	3,0	39,0	0,002	0,069	39,6	3,1
P ^a value		0,001		0,001			0,001	
Left Ventricular End-Diastolic Diameter	Preoperative	49,6	3,3	49,6	2,4	0,956	49,6	2,8
	6 th Month	43,7	2,6	45,1	0,956	0,017	44,5	2,7
	12 th Month	42,0	2,6	43,1	0,017	0,037	42,6	2,5
P ^a value		0,001		0,001			0,001	
Septum Thickness	Preoperative	17,8	2,1	18,1	2,1	0,462	18,0	2,1
	6 th Month	15,3	1,5	15,7	0,462	0,299	15,5	1,7
	12 th Month	14,3	2	14,6	0,299	0,459	14,4	1,8
P ^a value		0,001		0,001			0,001	
Mean Gradient	Preoperative	63,7	5,9	61,1	4,4	0,024	62,4	5,3
	6 th Month	18,4	4,1	21,0	0,024	0,004	20,0	4,5
	12 th Month	15,0	4,2	17,4	0,004	0,017	16,3	4,6
P ^a value		0,001		0,001			0,001	
Peak Systolic Gradient	Preoperative	84,3	6,6	82,4	7,9	0,219	83,3	7,4
	6 th Month	30,3	5,4	33,0	0,219	0,055	31,7	6,3
	12 th Month	26,4	5,3	30,0	0,055	0,008	28,3	6,4
P ^a value		0,001		0,001			0,001	

P^a= Repeated measurement anova test and Paired sample t-test were used in the 6th and 12th month comparisons. P^b= Independent sample t-test

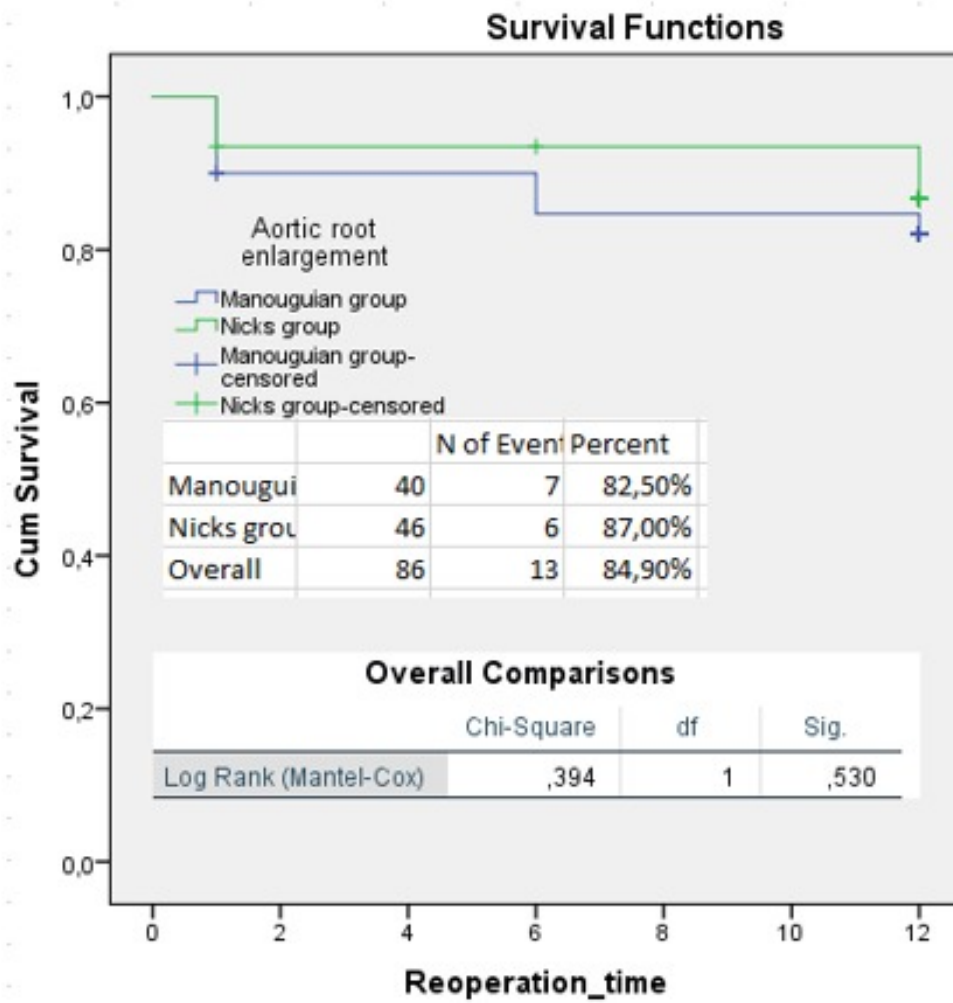
Table-2: Statistical analysis of change in echocardiographic parameters according to the procedures and months.



Graph-4: Graphical analysis of the change in septum thickness, left ventricular ejection fraction and end-diastolic diameter, fractional shortening, mean and peak systolic gradient in a one year period.



Graph-5: Surveys of procedure cases in one year (Log Rank(Mantel-cox)=0,643)



Graph-6: Analysis of reoperations in one year according to procedures

ID: 108

Topic: **Cardiology » Diseases of Aorta**Presentation Type: **Oral****VALVE-SPARING OPERATIONS IN BICUSPID AORTIC VALVE: SINGLE CENTRE EXPERIENCE****Aleksei Semagin** , V.v. Aminov , E.v. Ignatov , D.r. Tereschenko, M.a. Svetkin, O.p. Lukin*Federal State Institution "Federal Centre for Cardiovascular Surgery," the Ministry of Health of the Russian Federation, Astrakhan, Russia***Corresponding Author (voland420@gmail.com)**voland420@gmail.com, voland420@gmail.com, voland420@gmail.com, voland420@gmail.com, voland420@gmail.com, voland420@gmail.com***Abstract Text**

Background: There is a lack of uniformity in the techniques for bicuspid aortic valve (BAV) repair and limited information about the long-term outcomes of reparative procedures. The aim was to research our results of BAV repair according to initial anatomy of the aortic valve and the root.

Methods: From January 2015 to July 2018 an aortic valve-sparing operation in BAV was performed in 26 patients. The mean age was $42,8 \pm 13,5$ years. Aortic insufficiency was indication for surgery in 14 patients (53,8%), aortic aneurysm – in 12 (46,2%). If some segments of the ascending aorta had a diameter more than 45 mm it was replaced. If the diameter of the sinuses was more than 40 mm the David procedure was performed. The aim was to achieve the annulus of less than 25 mm, an effective height of coaptation of more 10 mm, the diameter of STJ less 35 mm.

Results: The aortic valve repair was performed in 9 patients, plus supracoronary aortic replacement – in 5, David procedure – in 12. Tricuspidalisation of the BAV was performed in 3 cases. The second clamp was necessary in 5 patients: the mitral valve repair was performed in 1, additional plication of cusps – in 2, aortic valve replacement – in 2. The patients with a replacement of the aortic valve were excluded from follow-up analysis. At discharge freedom from regurgitation more than mild was 100%. During follow-ups, freedom from insufficiency more than moderate was 100% (one patient has regurgitation from mild to moderate).

Conclusions: Repair of regurgitant BAV is feasible and provides excellent freedom from valve-related complications. The technique of the BAV should be tailored to the specific anatomy of the valve and the root. Freedom from reoperation and recurrent insufficiency are acceptable at midterm follow-up.

ID: 95

Topic: Cardiovascular Surgery » Thoracic and Thoracoabdominal Aortic Dissections and Aneurisms

Presentation Type: Oral

NON-CORONARY SINUS REPLACEMENT IN PATIENTS WITH ASCENDING AORTIC DISEASE AND MILD AORTIC ROOT ENLARGEMENT

Erhan Kaya

Private Pendik Regional Hospital, Istanbul, Turkey

**Corresponding Author (drerhankaya@yahoo.com)*

drerhankaya@yahoo.com

Abstract Text

Objective: During the ascending aort surgery, replacement of the aortic root is a big challenge in the patient with mild-moderate aortic enlargement. While replacement of the aortic root increases operative risks, further aortic root enlargement might be cause of the reoperation. In this study we are reporting our results of non-coronary sinus replacement in the patients with mild aortic enlargement.

Methods: Patients who underwent ascending aortic surgery with the diagnosis of ascending aortic aneurysm or aortic dissection between 01.01.2012-01.11.2018 in our hospital were retrospectively analysed. We included patients with mild to moderate aortic root enlargement and excluded patients without root enlargement or severe aortic root enlargement.

Results: In this period there were 42 elective aortic aneurysm and 7 aortic dissection surgery. 14 of aortic aneurysm and 4 of aortic dissection patients had mild aortic enlargement (< 45 mm). In these patients we replaced non-coronary sinus with tongue-shaped Dacron graft. There was one postoperative mortality, due to respiratuary dysfunction and there was no re-operation due to aortic root enlargement in the follow-up period.

Conclusions: Non-coronary sinus replacement can easily and safely perform during the ascending aortic surgery without increasing operative risk. This technique preserves root flexibility and decrease further aortic root enlargement.

ID: 136

Topic: Cardiovascular Surgery » Thoracic and Thoracoabdominal Aortic Dissections and AneurismsPresentation Type: **Oral****A MODIFIED TECHNIQUE OF ANASTOMOSIS BETWEEN AORTA AND A DACRON TUBE GRAFT: PLICATION OF AORTA****Salih Salih***Okan University Hospital, Istanbul, Turkey***Corresponding Author (drssalihi@yahoo.com)**drssalihi@yahoo.com***Abstract Text**

A Modified Technique of Anastomosis Between Aorta and a Dacron Tube Graft: Plication of aorta

OBJECTIVES:

We describe a modified technique of anastomosis between ascending aorta and a Dacron tube graft with the aim of minimizing suture line complications.

METHODS:

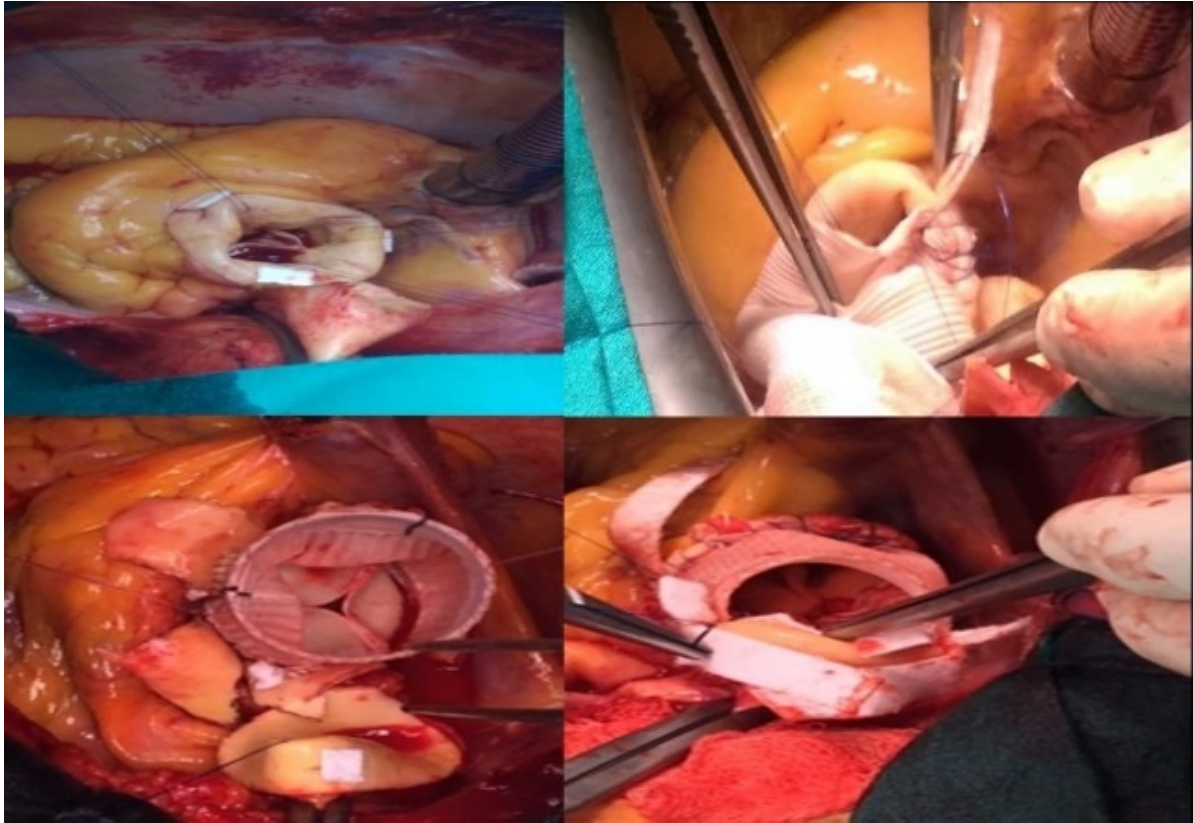
From March 2018 through December 2018, 52 patients underwent ascending and arch replacement at our department. Forty one patients who underwent ascending aortic surgery were included in this study. The diseased segment of the ascending aorta is excised and replaced with a tube graft. A tube graft of appropriate size is sutured to the proximal aorta with three 4/0 polypropylene suture incorporating a 5 mm strip of polytetrafluoroethylene (PTFE) felt. Anastomosis line is performed by plication of the aorta (Figure 1). The same anastomosis was performed in the distal part of the tube graft. Preoperative, perioperative, and postoperative parameters of the patients were analyzed.

RESULTS:

Aneurysm repairs were performed by plication in 41 patients. Thirteen patients were female (31.7%) and the mean age was $58,53 \pm 11,82$ years (range, 27 to 76 years). The most common indication for ascending aortic replacement was aneurysm in 36 patients (87,8%). Selective antegrade cerebral perfusion was used in 15 patients (36,6%). Aortic cross-clamp time was 60 ± 26 minutes and cardiopulmonary bypass time was 106 ± 34 minutes. There were no postoperative deaths. One patient had pulmonary morbidity. Postoperative complications occurred in four patients (9,7%). Postoperatively, one patient required reexploration for bleeding and he had insignificant oozing from the operation site.

CONCLUSION:

We consider our modification an easy, effective approach to minimize suture line complications in ascending aortic replacement with a Dacron tube graft.



ID: 256

Topic: Cardiovascular Surgery » Thoracic and Thoracoabdominal Aortic Dissections and Aneurisms

Presentation Type: Oral

RESULTS OF SURGICAL TREATMENT OF ASCENDING AORTA ANEURYSM OR DILATATION

Yahya Ünlü, Azman Ateş, Bilgehan Erkut

Atatürk University, Erzurum, Turkey

**Corresponding Author (yahyaunlu@hotmail.com)*

yahyaunlu@hotmail.com, azmanates@atauni.edu.tr, bilgehanerkut@yahoo.com

Abstract Text

Background: In this retrospective study , we aimed to present results of surgery for ascending aortic aneursym and dilatation.

Methods and Results: Between January 2000 and November 2018, 46 patients who were diagnosed with ascending aortic aneurysm and dilatation and underwent replacement or wrapping.

Result: The study consisted of 46 patients (male/female, 34/12) with mean age of 56.33±12 years (min-max: 23-76). 10 patients with ascending aortic aneurysm were treated with only supracoronary tubular graft. Supracoronary graft and aortic valve replacement were

applied to 12 patients. Modified Bentall technique was performed to 16 patients. Wrapping technique was performed to 8 patients with ascending aortic dilatation.

4 patients had prolonged hospital stay. We found that two patients had systemic infection and two patients had mediastinitis treated with omentoplasty. Mortality rate within 30 days was recorded in two patients (4.3%)

Conclusions: Ascending aortic replacement and wrapping are lifesaving and can be performed with low hospital mortality and morbidity.

ID: 339

Topic: Cardiovascular Surgery » Thoracic and Thoracoabdominal Aortic Dissections and Aneurysms

Presentation Type: Oral

EARLY AND MID-TERM RESULTS OF SURGICAL TREATMENT OF ASCENDING AORTIC ANEURYSMS IN LOW-VOLUME CENTER

Abdusalom Abdurakhmanov, Oybek Mashrapov

Republican Research Center of Emergency Medicine, Tashkent, Uzbekistan

**Corresponding Author (ab.abdurakhmanov@yandex.com)*

ab.abdurakhmanov@yandex.com, docmashrap@yahoo.com

Abstract Text

OBJECTIVE: Surgical treatment of the ascending aortic aneurysms nowadays is a routine procedure and in experienced Centers followed by very low mortality and complications rate. But learning curve for the Bentall procedure is relatively long and in low-volume Centers can be associated with high incidence of death and procedure related complications. We decided to analyze the immediate and mid-term results of surgical treatment of ascending aortic aneurysm patients in single low-volume Center.

METHODS: This study included 12 patients operated for an aneurysm of the ascending aorta in RRCEM for the period from 2016 to 2018. The mean age of the patients was 52.5 ± 2.7 years (28-70 years). The average diameter of the ascending aorta in its widest part was 6.5 ± 0.8 cm (5.2-9.5 cm). In all cases, the aortic aneurysm was combined with the aortic valve disease, of which in 10 cases the aortic aneurysm was caused by aortopathy associated with the bicuspid aortic valve. In two cases, 3-d grade aortic regurgitation and in the 8 cases severe aortic valve stenosis with average systolic gradient 100 mm Hg was diagnosed. In one case, the aneurysm of the ascending aorta was combined with symptomatic stenosis of the tricuspid aortic valve, the average gradient on the valve was 103 mm Hg, and in the remaining one case ascending aortic aneurysm was associated with Marfan syndrome. Mean CPB time was 304.4 ± 59.2 min; mean aortic cross-clamp time – 207.5 ± 55.7 min. In 11 cases, the aortic root composite graft replacement procedure (mechanic valve St.Jude Medical; tubular prosthesis - Vascutek) was performed, in three cases coronary artery bypass grafting procedure was performed concomitantly. In one case, isolated aortic valve and ascending aorta replacement procedure was performed.

RESULTS: Average bleeding after operation was 725 ± 183.2 ml. The average duration of the postoperative hospital period was 12.8 ± 1.2 days. In the early postoperative period nor any postoperative complications or death were observed. Mean follow –up period consisted 16.8 ± 7.2 months, during this period two patients died due to valve related complications (thrombosis and gastro-intestinal bleeding).

CONCLUSION: Surgical treatment of the ascending aortic aneurysms in low-volume center can be associated with satisfactory immediate and midterm results.

ID: 395

Topic: Cardiovascular Surgery » Thoracic and Thoracoabdominal Aortic Dissections and AneurismsPresentation Type: **Oral****A NEW AORTIC ROOT RECONSTRUCTION TECHNIQUE IN ASCENDING AORTIC ANEURYSM SURGERY "GÜLER TECHNIQUE".****Mustafa Güler¹, Sinan Göçer¹, Hüseyin Gemalmaz²**¹*BAU MedicalPark Göztepe Hastanesi, İstanbul, Turkey*²*Memorial Bahçelievler Hastanesi, İstanbul, Turkey***Corresponding Author (drmguler@gmail.com)**drmguler@gmail.com, drsinangocer@gmail.com, huseyin.gemalmaz@memorial.com.tr***Abstract Text****OBJECTIVE:**

Several alternative surgical methods are used in the treatment of ascending aortic aneurysm patients with aortic valve disease. In some cases, ascending and aortic root diameters of the patients undergoing aortic valve replacement may be at the limit (45 mm). In these cases, it is not easy to decide whether or not to replace the aortic root as the surgery becomes more complex. In this study, we describe a unique surgical method in which aortic root reconstruction is performed during aortic valve replacement.

METHODS:

This technique was performed in 16 patients between May 2016 and December 2018. While AVR was performed in all patients, this method was applied instead of changing the aortic root in cases with an aortic root diameter at the limit (45mm) by intra operative evaluation. This technique is based on the narrowing of the sinus of Valsalva by securing the pledgetted mattress stitches together with the aortic wall and the annulus during AVR. The stitches can be placed in the non-coronary cusp to narrow all the sinus of Valsalva, but the sutures should be passed just below the coronary ostia in the left and right coronary cusps. As a result, aortic root is narrowed in cases where aortic root diameter is at the limit during aortic valve replacement. In 14 of 16 cases, a separate graft was placed in the ascending aorta.

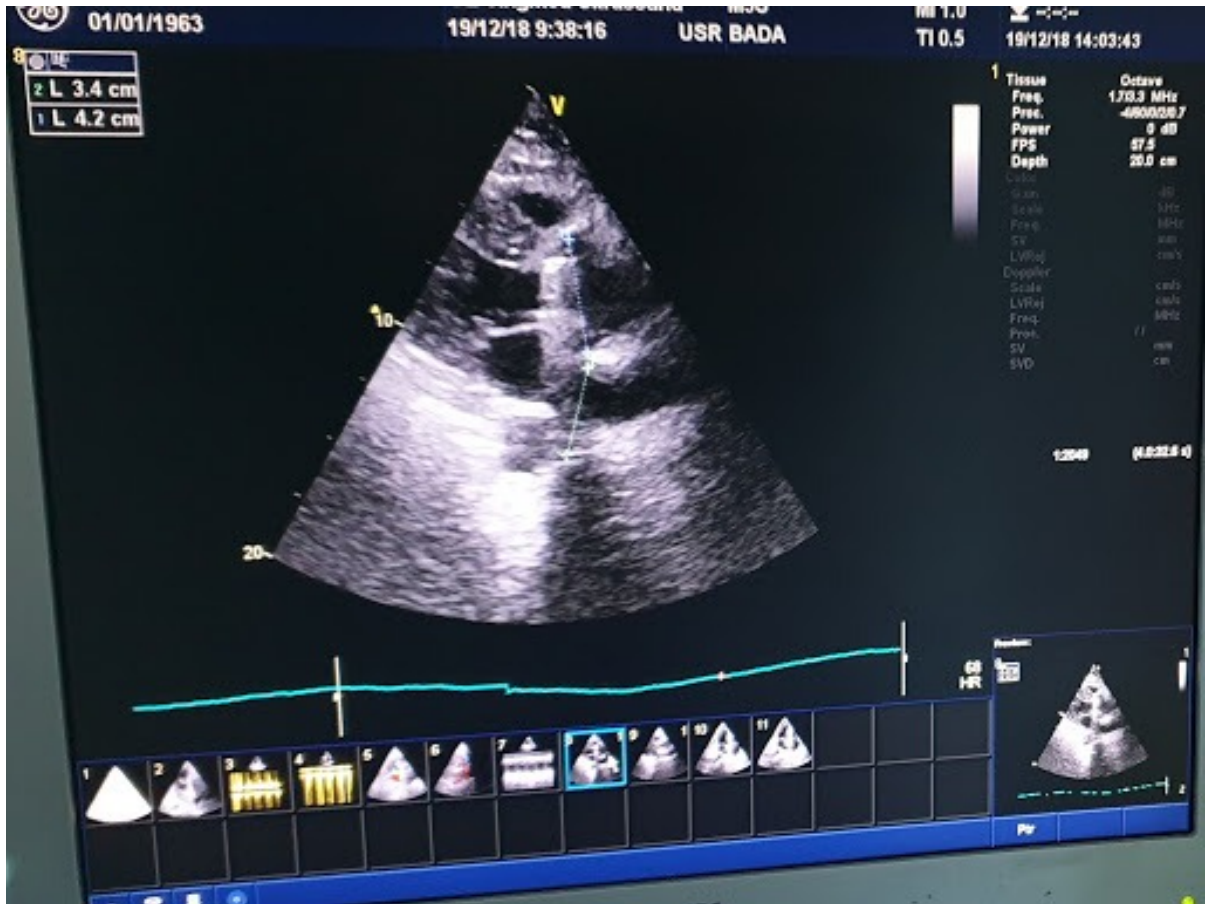
RESULTS:

No early or late mortality was observed. One case was revised because of bleeding. The transient AV complete block developed in 1 patient and atrial fibrillation in 2 cases. Echocardiographic examination was performed in the early postoperative period and postoperative 6th month. All patients had normal aortic valve function in the control echoes and no aortic root dilatation was detected in any patient.

CONCLUSIONS:

This technique can be applied in cases of ascending aortic aneurysms with non-connective tissue disease when performing aortic valve replacement, if the size of the aneurysm is at the limit. With this method, sinus of Valsalvas are narrowed together during aortic valve replacement, and if necessary, an additional graft is placed in the ascending aorta. Thus, patients with moderate aortic root aneurysms are not left untreated or more complex procedures such as Bentall are not required. Although early results are quite satisfactory, expecting late term results is a must for full evaluation.

Image 1. Postoperative echocardiography.



ID: 508

Topic: **Cardiovascular Surgery » Thoracic and Thoracoabdominal Aortic Dissections and Aneurisms**

Presentation Type: **Oral**

ASENDAN AND ARCH REPLACEMENT USING RETROGRADE CEREBRAL PERFUSION IS SAFE TECNIQUE

Mustafa Dađlı, **Mustafa Cüneyt Çiçek**

University Of Health Sciences Konya Education and Research Hospital, Konya, Turkey

**Corresponding Author (drmustafaana@gmail.com)*

drmustafaana@gmail.com, drmcuneyt@hotmail.com

Abstract Text**OBJECTIVE,**

This is a report to update our experience with asendan and arch replacement with aid of retrograde cerebral perfusion.

METHODS,

Retrospective data were collected from 2013 to 2019 and analysis was conducted on 51 patients who had aneurysm or dissection involving asendan and arch. Our hypothermic circulatory arrest and retrograde cerebral perfusion technique was as follows, temperature was 21-26° Celsius. During circulatory arrest, perfusing directly into the SVC, maintaining a central venous pressure of 20 mm Hg, averaging flow of 400 mL/min (range, 300 to 750) with a temperature of inflow blood kept at 10° Celsius.

RESULTS,

The median age of the patients was 72 years. The cases included 32 male and 19 female. Four patients (7,8%) underwent previous cardiac surgery. In the hospital mortality 31,3% (16 patients) and stroke occurred in 5 patients (9,8%). In univariate analysis of the risk factors for death, the factor was the duration of operation (p:0,0005)(symptom timing to operation timing). In multivariate analysis, chronic renal failure defined as serum creatinine levels over 2,0 mg/dl was single independent risk factor for in hospital mortality.

CONCLUSIONS

Retrograde cerebral perfusion was safe and sufficient technique for asendan and arc replacement. Chronic renal failure was significantly associated with in hospital mortality.

ID: 284**Topic: Cardiology » Cardiac Imaging - Echocardiography****Presentation Type: Oral****ASSESSMENT OF LEFT VENTRICULAR DIASTOLIC FUNCTIONS IN PATIENTS WITH SEVERE PATIENT-PROSTHESIS MISMATCH****Altuğ Ösken***Siyami Ersek Thoracic And Cardiovascular Surgery Center, Istanbul, Turkey***Corresponding Author (alorsk@hotmail.com)**alorsk@hotmail.com***Abstract Text**

Background: Aortic valve disease is usually observed in the cardiology clinics especially in the elderly population. Although aortic valve replacement (AVR) successfully performed in low mortality rates in selected patients, prosthesis-patient mismatch (PPM) can be seen in the majority of these patients. In patients with aortic stenosis, left ventricular (LV) wall thickness increases to compensate the increased wall stress caused by chronic pressure overload. When the LV pressure increases further over time, LV volumes and left ventricle ejection fraction (LVEF) remains within normal limits, but diastolic dysfunction may be observed in these patients. There is no study comparing the diastolic parameters with PPM in the literature. The aim of this study was to assess left ventricular diastolic parameters in patients with aortic PPM with preserved LVEF.

Methods: We retrospectively examined all consecutive patients with isolated AVR at our center from 2005 to 2015. A total of 1060 patients were analyzed. Inclusion criteria were determined and 52 patients eligible for the study were included. Severe PPM was defined as an indexed effective orifice area (iEOA) of $\leq 0.65 \text{ cm}^2 / \text{m}^2$. The baseline information were collected and compared between the two groups as patients with severe PPM (n=26) and normofunctional aortic prosthetic valve as control group (n=26). All patients underwent baseline echocardiography.

Results: LV E velocity (95.5 ± 33.8 vs 75.1 ± 14 , $p=0.007$), LV e' lateral velocity (9.3 ± 1.9 vs 8.2 ± 1.2 , $p=0.02$) and IVRT (isovolemic relaxation time) values (137 ± 43 vs 115 ± 25 , $p=0.03$) were significantly higher in severe PPM group.

Conclusion: In patients with severe PPM, LV diastolic functions may deteriorate by indirect effect of increased LV filling pressures.

Table. Baseline clinical and echocardiographic characteristics of the study population

	Severe PPM (+) n=26	PPM (-) n=26	P
Age	55±17	54±14	0.84
Female (n; %)	16 (72)	9 (35)	0.07
Height (cm)	1.63±0.06	1.68±0.07	0.02
Weight (kg)	74±8	73±12	0.76
BMI	27.9±3.7	25.8±3.4	0.04
BSA (kg/m ²)	1.80±0.15	1.82±0.17	0.72
LVEDd (mm)	47.8±4.2	48.5±3.5	0.5
LVESd (mm)	30.5±4.4	31.4±4.2	0.48
LVEDV (ml)	136.6±19.5	141.3±17.8	0.37
LVESV (ml)	55.2±12	53.5±10.5	0.58
LVEF (Simpson %)	59±2.9	60±3.1	0.11
IVSd (mm)	12.3±1.6	11.7±1.2	0.12
PWd (mm)	10.8±1.1	10.7±1.2	0.72
LA dimension M-mode (mm)	37.9±10.9	40.7±3.8	0.22
LA volume (ml/m ²)	31.7±8	30.8±5.5	0.63
LV mass (g)	212.8±52.6	206.4±43.6	0.64
LVMI (g/m ²)	115.7±26.6	112.8±23.2	0.67
iEOA (cm ² /m ²)	0.53±0.09	0.92±0.05	0.000
LV E velocity	95.5±33.8	75.1±14	0.007
LV A velocity	76.7±27.3	69.1±21.6	0.27
E/A	1.38±0.7	1.13±0.2	0.12
e' lateral	9.3±1.9	8.2±1.2	0.02
a' lateral	7.9±2.3	8.2±1.6	0.51
E/e'	10.3±3	9.3±1.7	0.16
E wave dt (ms)	206±53	199±23	0.51
IVRT	137±43	115±25	0.03

ID: 12

Topic: **Cardiovascular Surgery » Congenital Heart Disease**Presentation Type: **Oral****SURGICAL PDA LIGATION WITH LEFT ANTERIOR MINI-THORACOTOMY IN NON-HEART CENTER SECONDARY HOSPITAL**Mehmet Dedemođlu¹, Fatih Özdemi²¹*Mersin City Education and Research Hospital, Mersin, Turkey*²*Diyarbakır Gazi Yaşargil Education and Research Hospital, Diyarbakır, Turkey***Corresponding Author (mehmetdedemoglu@yahoo.com)**mehmetdedemoglu@yahoo.com, fatih.ozdemir.83@gmail.com***Abstract Text**

Objective: The purpose of this study is to evaluate the early outcomes of premature patients undergoing surgical patent ductus arteriosus ligation with left anterior mini thoracotomy in non-heart center secondary hospital.

Methods: Premature patients having very low weight, low gestation age and pda despite medical closure treatment and undergoing surgical ligation with left anterior mini thoracotomy were included to the study. Surgical technique: A minimal incision was performed approximately 1 cm below the left clavicle and thoracotomy was performed through the 2nd intercostal space. Thymus tissue was retracted and pericardium was opened. Aorta, main pulmonary artery, left and right pulmonary artery and ductus arteriosus were visualized. Ductus arteriosus was ligated using clips material. De-airing was applied with the help of closed drainage system and the layers were closed without using drainage tube.

Results: 11 patients were included to the study. Gestational ages and weights at birth of patients were 25.9±2.0 week and 871.8±221.2 g. Ages and weights during operation were 38.6±20.0 days and 1179.1±288.0 g. 6 (54.5%) out of patients were male. 9 (81.8%) out of patients were needed preoperative mechanical ventilation. Mean PDA diameter was 3.1±0.8 mm and mean operation time was 48.4±8.7 min. Surgical and hospital mortality was not observed in any patient. None of the patients had infection, pneumothorax. After 1 week of follow-up control echocardiography, no patient had residual PDA.

Conclusions: Left posterolateral thoracotomy which is the classical method in surgical PDA ligation has several troubles such as greater incision, excessive traction of the left lung, more surgical area exposed to cold, longer operating time. In this method we apply, all pulmonary artery branches are clearly visualized and there is no risk of possible pulmonary artery branch ligation as well as there is smaller incision, almost no contact with the lungs and a short operative period. We recommend this method, which is particularly effective in limiting surgical equipment, especially in non-cardiac centers.

Oral Presentations

Arrhythmias and Antiarrhythmic Therapies: New Approaches

Date: 30.03.2019 Time: 08:00 - 09:30 Hall: 5

ID: 341

Topic: Cardiology » Arrhythmias and Antiarrhythmic Therapy

Presentation Type: Oral

2:1 AV BLOCK SENSITIVE TO PREDNISOLONE 72 HOURS POST WPW ABLATION

Kivanc Yahn, Ilhan Koyuncu

Usak University, Faculty of Medicine, Usak, Turkey

**Corresponding Author (yalinkivanc@gmail.com)*

yalinkivanc@gmail.com, ilhank@hotmail.com

Abstract Text

A 32-year-old woman presented to our hospital due to recurrent drug refractory supraventricular tachycardia. Her rest ECG showed short PR interval and delta waves suggesting WPW syndrome (Figure 1). An EP study was performed, earliest V signal was recorded at midseptal region below His catheter. During 25 W radiofrequency current delta waves were disappeared and no AV conduction delay or fast nodal beats were observed. Single RF application was performed. Ten minutes after RF application Wenckebach periodicity were recorded, and HV interval was found to be normal (38 ms). Prednisolone 80 mg was ordered. One day after the procedure 2:1 AV conduction was present (Figure 2) and 80 mg prednisolone was infused. On second day AV Wenckebach was again recorded and on third day normal AV conduction was observed (Figure 3). Patient was asymptomatic without necessity for pacemaker implantation at 6 months follow-up.

Possible explanation for the delayed development of an AV block in our patient could be that around the region of RF application inflammation and edema caused impaired myocardial and AV node conduction. Late AV block formation after RF ablation reaching from several hours to several years after the ablation with the need of permanent pacemaker implantation was described. Largely, this had been explained by progression of tissue lesion and scar formation around the ablated area. Reversibility of the AV block in the presented case is due to the early administration of antiphlogistic medications. We believe that this could have prevented the development of late thermal injury that would have otherwise caused irreversible damage to the conduction properties of the AV node with the necessity of permanent pacemaker implantation.

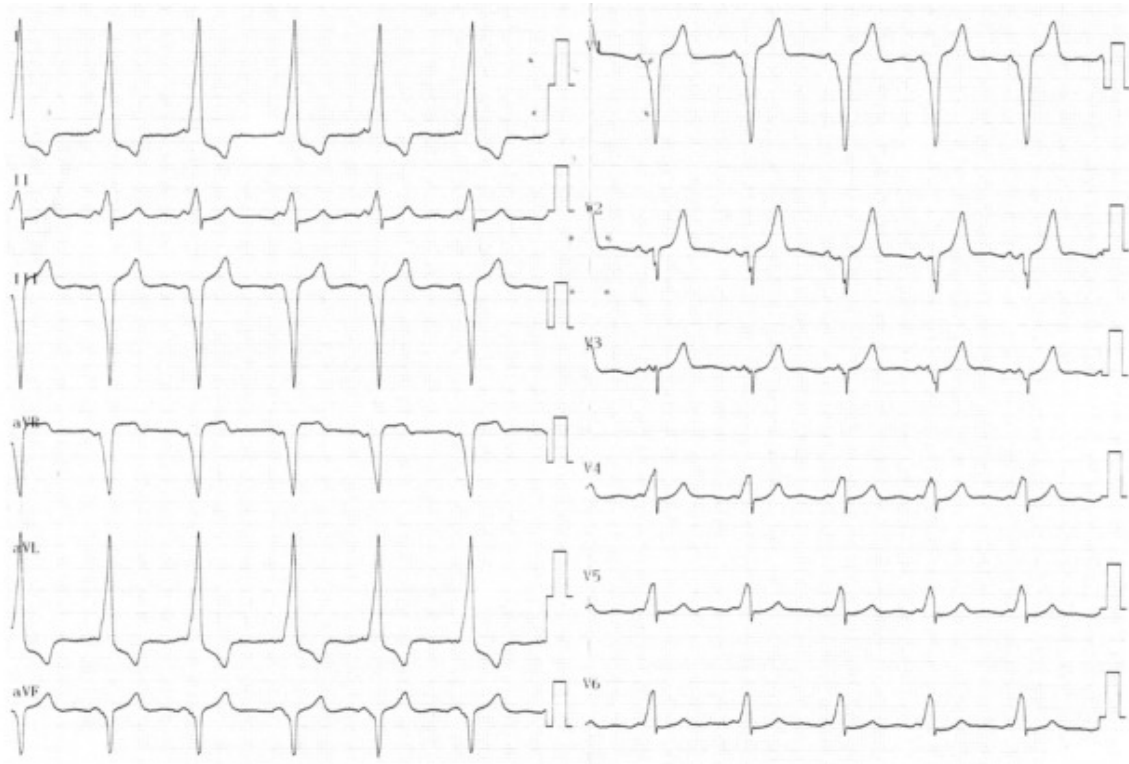


Figure 1.

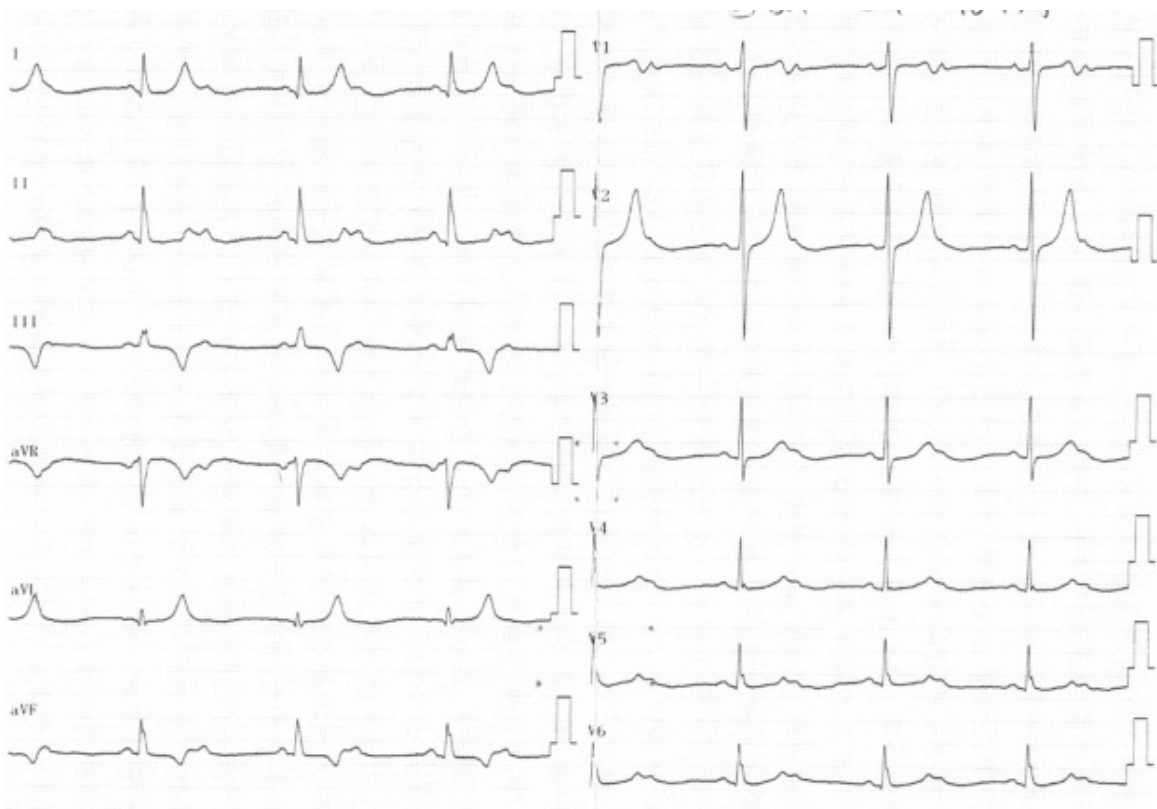


Figure 2.

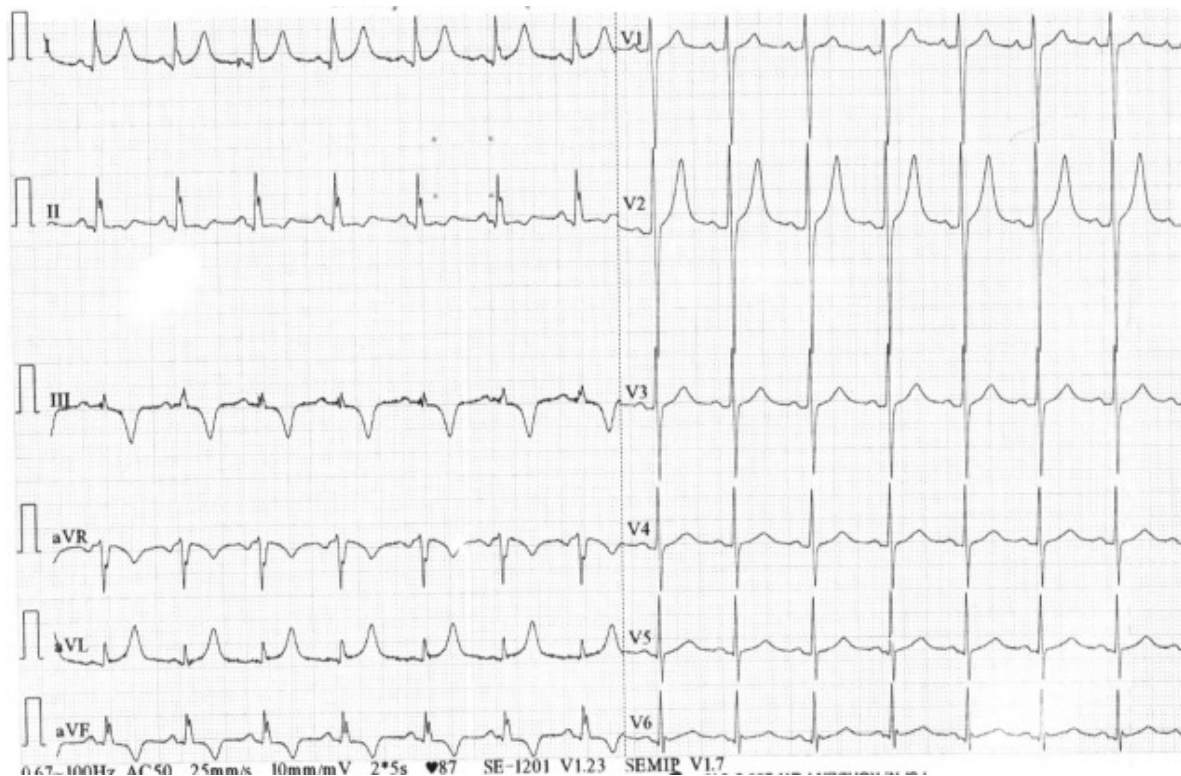

Figure 3.

ID: 340

Topic: **Cardiology** » **Arrhythmias and Antiarrhythmic Therapy**Presentation Type: **Oral**

SLEEP APNEA AND MALIGNANT VENTRICULAR ARRHYTHMIAS: THE DYNAMIC DUO OF SUDDEN DEATH. CRITERIAS FOR PREVENTION AND PROGNOSIS.

Stoianovici Radu Virgil

*Emergency County Hospital Craiova, Dolj, Romania, Craiova, Romania***Corresponding Author (radu_virgil_2006@yahoo.com)**radu_virgil_2006@yahoo.com***Abstract Text**

The malignant ventricular arrhythmias spectrum, linked with sleep apnea, corresponds to a anfractuous prevention of sudden death, the comorbidities being encumbered with a poor prognosis. We associate these two pathological entities to assess prevention criterias, for an improved prognosis. All patients with sleep apnea and malignant ventricular arrhythmias, seen during a one year period, were enrolled in a cohort study, with a total of 150. Each patient underwent a comprehensive EKG Holter and polysomnography study. 75% were males; 70% of those patients had as arrhythmogenic trigger sleep apnea itself, the electrical disturbances being detected as following: 50% unsustained ventricular tachycardia, 20% sustained ventricular tachycardia, 5% torsades des pointes, and 5% ventricular fibrillation. We can assert that sleep apnea, through the cascade of changes in matter of pathophysiology at myocardial level, corresponds to an arrhythmogenic trigger.

ID: 140

Topic: **Cardiology » Pregnancy and Heart Diseases**

Presentation Type: **Oral**

EFFECTIVENESS OF DIGOXIN TREATMENT IN FETAL SUPRAVENTRICULAR TACHYCARDIA

Şeyda Yavuzkır, Melike Başpınar

Firat University, Elazığ, Turkey

**Corresponding Author (syavuzkır@firat.edu.tr)*

syavuzkır@firat.edu.tr, mbaspınar@firat.edu.tr

Abstract Text

EFFECTIVENESS OF DIGOXIN TREATMENT IN FETAL SUPRAVENTRICULAR TACHYCARDIA

INTRODUCTION

Fetal supraventricular tachycardia (FSVT) is associated with poor pregnancy prognosis. 1: 1 Optimal treatment is not clear for atrioventricular-associated FSVT. The purpose of the study was searching the effectiveness of transplacental treatment protocols of digoxin which is used for FSVT.

METHODS:

Fetal supraventricular tachycardia was classified as short VA or long VA by mechanical ventriculoatrial (VA) time intervals. Intravenous maternal digoxin was used as a pharmacological treatment in 14 fetuses. Treatment success was defined as > 20% decrease in fetal heart rate or restoration to sinus rhythm (SR).

RESULTS:

The short VA interval occurred in 13 fetuses (95%) and long VA occurred in 1 (5%) of them. Hydrops were present in 9 (33%). For short VA SVT, restoration to SR was occurred in 5 (69%) for digoxin. Digoxin only provided speed control in the remaining 8 patients, digoxin only provided speed control for long VA SVT. In 2 (9%) of the hydropic fetuses treated with digoxin, intrauterine or neonatal death occurred.

DISCUSSION

Digoxin treatment is an effective method in fetal supraventricular tachycardia.

ID: 129

Topic: Cardiology » Stroke Prevention in Atrial Fibrillation

Presentation Type: Oral

SELF-MONITORING AND SELF-MANAGEMENT OF INTERNATIONAL NORMALIZED RATIO- EFFICACY AND FEASIBILITY

Elif Ijlal Cekirdekci

Dr. Suat Gonsel University of Kyrenia Hospital, Kyrenia, Turkish Republic of Northern Cyprus

*Corresponding Author (elifcekirdekci@hotmail.com)

elifcekirdekci@hotmail.com

Abstract Text

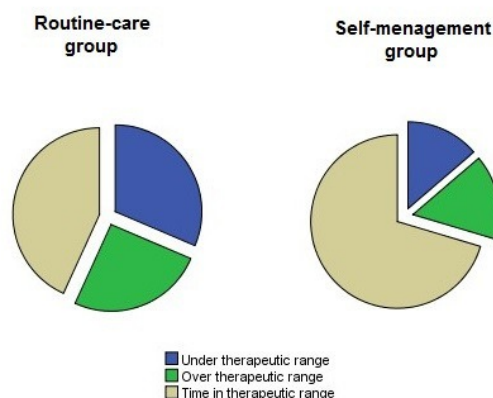
Objective: The safety and effectiveness of warfarin therapy associated with the quality of anticoagulation control, often assessed using the percentage time in therapeutic range (TTR). This study aimed to evaluate the variation in INR and TTR between individual and center-based measurements and to observe how this variation affects the effectiveness of oral anticoagulant therapy.

Methods: A total of 237 patients were selected in the current study. Patients were divided into two groups: The routine care group consisted of 179 subjects (75 men, with a median of 61 years), and the self-management group included of 58 age and sex-matched individuals (26 men, with a median of 64 years). **Objective:** The safety and effectiveness of warfarin therapy associated with the quality of anticoagulation control, often assessed using the percentage time in therapeutic range (TTR). This study aimed to evaluate the variation in INR and TTR between individual and center-based measurements and to observe how this variation affects the effectiveness of oral anticoagulant therapy.

Results: The patients in self-management group had significantly higher levels of TTR ($72.7 \pm 22.8\%$ vs. $44.9 \pm 31.6\%$, $p < 0.001$), but the time below range (%) and the time above range (%) were significantly lower than routine-care group (14.1 ± 16.5 vs. 32.7 ± 23.5 , $p < 0.001$, 16.4 ± 18.8 vs. 26.4 ± 23.6 , $p = 0.004$, respectively). HF (3.281, 95% CI 1.561 -6.897, $p=0.002$), renal dysfunction (3.754, 95% CI 1.224 - 11.519, $p=0.021$), younger age (<65 years) (2.786, $p=0.004$), CHA2DS2-VASc (1.339, $p=0.010$), and routine-care management (8.113, $p < 0.001$) were the independent predictors of having lower TTR.

Conclusion: Self-management strategy has good outcomes in terms of prevention of major thromboembolic and bleeding complications. The home testing devices may provide better management of being safe for long-term oral anticoagulation.

Keywords: Warfarin, Time in therapeutic range, Anticoagulation



ID: 289

Topic: **Cardiology » Chronic Stable Angina Pectoris**Presentation Type: **Oral****MYOCARDIAL BRIDGING: AS A PREDICTOR OF EXERCISE INDUCED VENTRICULAR TACHYCARDIA**

Umit Yuksek, Levent Cerit, Belma Yaman, Songul Usalp, Hamza Duygu

*Near East University, Nicosia, Turkish Republic of Northern Cyprus***Corresponding Author (uyuksek@yahoo.com)**uyuksek@yahoo.com, drcerit@hotmail.com, belmayaman@yahoo.com, dr.songulusalp@hotmail.com, hamzakard@yahoo.com***Abstract Text**

OBJECTIVE: Myocardial bridging is a congenital disorder in which a segment of coronary artery has an intramyocardial course. It is generally thought to be a benign anomaly. But in some cases it may cause angina, myocardial ischemia, myocardial infarction, arrhythmias or even sudden cardiac death. In these patients, exercise may induce ventricular arrhythmias. Myocardial bridging and ventricular arrhythmia association is a rare condition. So we report here a case of a patient with myocardial bridging on coronary angiography and a non-sustained ventricular arrhythmia episode during exercise stress test.

METHODS: A fifty-nine year old man presented to the cardiology outpatient clinic with angina and palpitation. He had no cardiac disease history, but he had hypertension for 10 years and hyperlipidemia which required drug treatment. His ECG was completely normal with no ischemic changes and with a normal QT interval of 347 ms (corrected QT interval=419 ms). QT dispersion was 40 ms (corrected QT dispersion=52 ms). An echocardiography was performed which showed a normal EF, left ventricular diastolic dysfunction and an aortic root dilatation of 4.3 cm. Afterwards, to inspect for cardiac ischemia, an exercise stress test was performed. In the exercise stress test, at the recovery stage the patient had a non-sustained monomorphic ventricular tachycardia which lasted 7-8 seconds together with mild ischemic changes on lateral derivations (Figure1). The ventricular tachycardia recovered spontaneously and frequent premature ventricular extrasystoles followed. At first minute of recovery phase of exercise stress test, QT interval was calculated as 278 ms, but corrected QT interval was 467 ms. QT dispersion was 40 ms (corrected QT dispersion was 67 ms). His blood biochemistry showed no abnormality in serum electrolytes.

RESULTS: We decided to take the patient to coronary angiography laboratory immediately to look for a potential coronary occlusion. But the coronary angiography revealed no significant coronary vessel occlusion, instead we observed a myocardial bridge on mid left anterior descending coronary artery which caused a 70% of narrowing of the vessel during systole. We started beta-blocker treatment and we are following the patient for symptom relief and for any arrhythmic episode.

CONCLUSION: Myocardial bridging is mostly a benign condition. But sometimes it may be associated with ventricular arrhythmias. Exercise stress test may induce arrhythmias in these patients. Ventricular repolarization abnormalities during exercise may be the underlying cause. So, myocardial bridging should be remembered as a potential diagnosis in patients developing any kind of arrhythmias during exercise stress test.

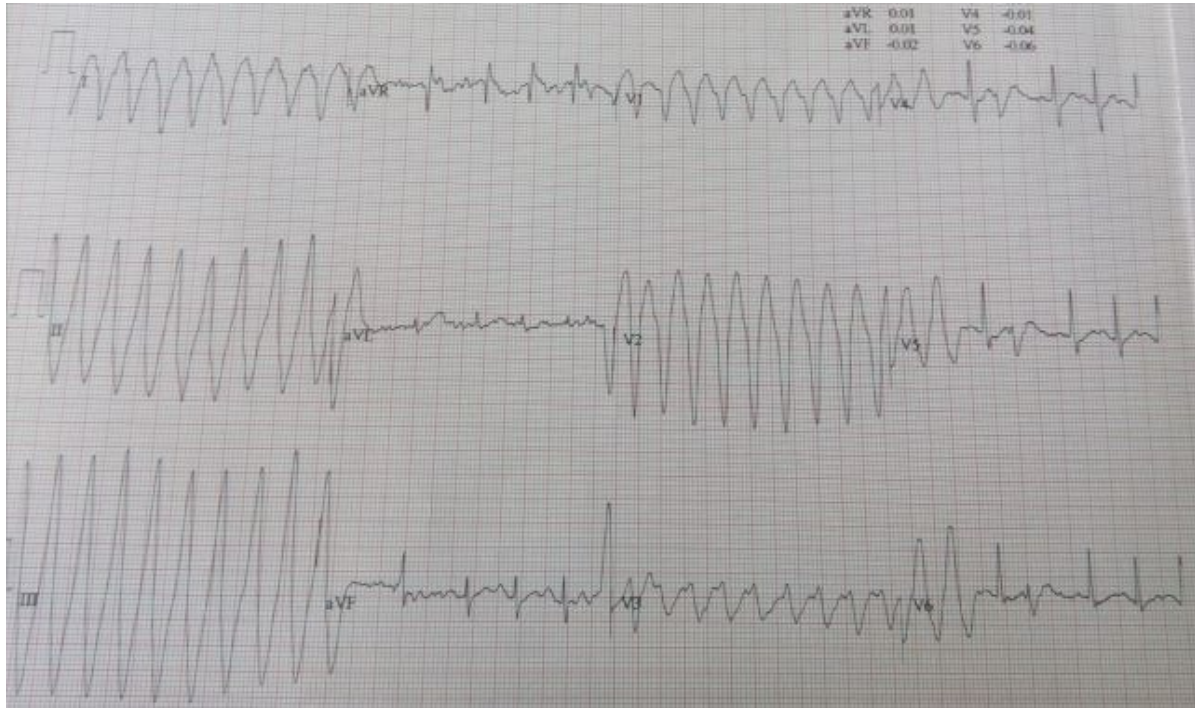


Figure 1. Ventricular tachycardia observed in exercise stress test

ID: 110

Topic: **Cardiology » Arrhythmias and Antiarrhythmic Therapy**

Presentation Type: **Oral**

**CAN NON-CONDUCTED PREMATURE ATRIAL CONTRACTION BE THE
RUNNER OF DISTAL CONDUCTION SYSTEM DISEASE?- AN
EDUCATIONAL CASE REPORT.**

Kamal Isgandarov

Özel Eskişehir Anadolu Hastanesi, Eskişehir, Turkey

**Corresponding Author (kemalazeri@hotmail.com)*

kemalazeri@hotmail.com

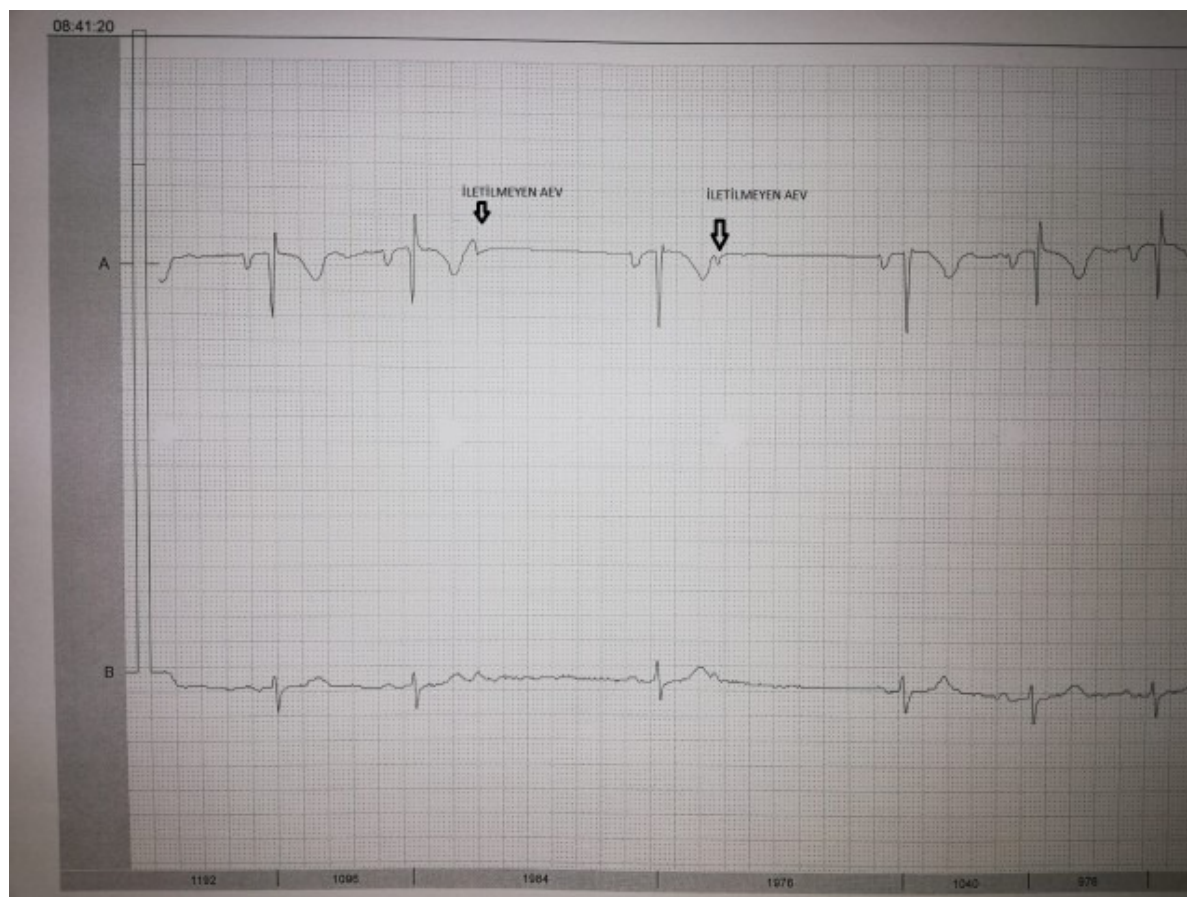
Abstract Text**ABSTRACT**

Introduction: Premature atrial contraction(PAC) is a type of arrhythmia, which is frequently associated with predisposing factors such as age, overweight, cardiovascular disease, high natriuretic peptide levels(1).Normal functions of sinus and AV nodes can be impaired by PACs(2,3).

Case Presentation: A 70-year-old female was admitted to hospital with dyspnea, fatigue and weakness. Physical examination,TTE and blood tests were normal. The electrocardiogram(ECG) was sinus rhythm, 65bpm and PR 180msec. In rhythm Holter, approximately 1700 nonconducted PACs were revealed. Treadmil exercise test(TET) was performed to evaluate the conduction system according to physiological demand.Heart rate increased to 142bpm and PACs conducted succesfully. The conduction of PACs even in shorter cycles during TET pushed us to follow-up. We had two options for the treatment of PACs. If it is unifocal, the atrial substrate should be ablated or controlled by antiarrhythmics.We preferred to try betabloker because it was multifocal. Metoprolol was started at 25 mg once a day. After 3 days, the patient was admitted with complete AV block. EPS performed to evaluate the distal conduction system. The baseline measurements were AH:114ms, HV:54ms, BCL:73ms, PR:175msn. The corrected sinus node recovery time was 422, 496, 423ms at 600,550,500ms, respectively. With 570msec cycle length programmable stimulation from RA showed 2:1 AV conduction and ending of this nonconducted stimuli showed disease of distal conduction system. Then DDD-R pacemaker was implanted. Patient reported no complaints at the end of the 3.5-month follow-up. For the existing PACs metoprolol succinate 25 mg was started once a day. After 15 days PACs almost completely disappeared.

Discussion:In 24 hours, existing > 76 PACs was associated with increased mortality, cardiovascular hospitalization and permanent cardiac pacemaker. Frequent PAC is closely correlated with sick sinus syndrome and permanent pacemaker implantation due to high-grade AV block(4).In our case, it was observed that PACs entered the sinus node and performed early depolarization. Therefore, compensatory pause was recorded. Sucession of this condition concluded with a ventricular rate of about 30bpm. We think symptoms are related to this condition. There was not enough data about using betabloker and the requirement of permanent pacemaker in nonconducted PACs .In such cases worsening of infrahisian conduction and occurence of brady-tachy syndrome due to use of betabloker have been previously reported(5).It is important to evaluate the distal conduction system if the patient has symptoms of heart failure and the absence of any other abnormality that explains this condition.

Keywords: nonconducted premature atrial contractions,distal conduction disease, permanent pacemaker.



ID: 329

Topic: **Cardiology » Inherited Arrhythmia Syndromes**Presentation Type: **Oral****ICD IMPLANTATION BEFORE/AFTER SURGERY, A CASE REPORT...FINALLY SUDDEN DEATH.**Mehmet Ali Yeşiltaş, **Sadiye Deniz Özsoy***Istanbul University Cardiology Institute, İstanbul, Turkey***Corresponding Author (dr.maliyes@gmail.com)**dr.maliyes@gmail.com, sdenizozsoy@gmail.com***Abstract Text****INTRODUCTION**

Brugada syndrome is genetic disease that can causes sudden death. In the brugada syndrome, syncope or electrocardiographic shows ST segment elevation and normal QT interval in right bundle branch block in the right precordial leads(V1- V3). these findings do not have to be in every patient.The cause of syncope and sudden cardiac death is ventricular tachycardia or ventricular fibrillation. treatment strategies for Brugada are developing. But we have some of treatment options. one of them is the implanted cardioverter defibrillator (ICD).

CASE REPORT

A 34-year-old male patient was being followed for 4 years due to mitral valve stenosis. he recently admitted to our hospital for mitral valve replacement due to increased dyspnea. All finding derived from physical examination,chest radiography and laboratory tests were normal. His angiography was normal too, but his electrocardiography showed ST elevation of V1 to V3. His echocardiography showed a mitral valve area of 1.3mm², a peak gradient of 24mmHg, mean gradient of 8mmHg, but measurements of atriums and ventricles are normal. his genetic results showed a homozygous SCN5A gene mutation. After that we exchanged ideas with anesthesiologists and cardiologists on the path that should be followed during the operation. It was discussed whether the ICD should be insert before preoperation, peroperation or after the surgery. Because he had never experienced a syncope or ventricular arrhythmia attack. We have operated for mitral valve replacement due to mitral valve stenosis. We inserted a number 29 prosthesis mitral valve. During the surgery we completed the procedure without any problems. he was extubated in the intensive care unit at the sixth hour and went to the service on the postoperative first day. Before discharge, the patient was told that again ICD insertion could prevent sudden death due to a possible ventricular arrhythmia because of Brugada Syndrome. But the patient refused. he was discharged from the hospital on the postoperative 6th day. no rhythm disorder developed in these processes. His rhythm is sinus and 80 in minute. Beta blockers, warfarin and quinidine were given for life-long use. Ten days after the patient came to the control. Everything was in his controls. Because it would use warfarin, it was called to check after a month to see the INR value. The patient didnot come to the hospital next three month control. the patient was followed for 3 months. holter was attached and the rhythm problem was not seen according to the holter result. But the patient did not come for the fourth month. we were told that he was found dead in his bed at home in the morning.

DISCUSSION

Antiarrhythmic drugs are “Isoproterenol/isoprenaline, quinidine”, “Orciprenaline” (ClassIIa). Other substance is “Cilostazol”antiarrhythmic as medication for BS patients.

In patients with asymptomatic brugada syndrome, there is no consensus among physicians about the indication of ICD. ICD insertion at early age is balanced by the risk of sudden death compared to complications.

CONCLUSION

Our patient had never experienced any arrhythmic symptom, syncope but he had type 1 ECG, two person of his family members had experienced sudden cardiac death. Despite our recommendation, the patient did not accept ICD insertion. So we have followed up with medical treatment. Unfortunately, our patient died 4 months later. So ICD should be inserted in patients with BS? If we are going to insert ICD, when should we insert in?

ID: 139

Topic: Cardiology » Stroke Prevention in Atrial Fibrillation

Presentation Type: Oral

COMPARISON OF LABORATORY AND CLINICAL PARAMETERS IN PATIENTS WITH FIRST ISCHEMIC STROKE AND HEALTHY CONTROLS

Tahir Bezin, Ruhan Özcan

*Gebze Fatih Devlet Hastanesi, Kocaeli, Turkey***Corresponding Author (bezingintahir3@yahoo.com)**bezingintahir3@yahoo.com, ruhanozcan@yahoo.uk***Abstract Text**

Aim: We aimed to compare characteristics of age and sex matched controls with patients (pts) hospitalized for first ever ischemic stroke, to determine predictors of mortality during median 33 months follow-up.

Materials and Method: A total of 78 pts (female: 33(42,3%) diagnosed with first ever ischemic stroke admitted to the hospital and 43 age sex matched controls (ctrl) were included in this prospective study. Patient survival was assessed by the telephone contact and national mortality record. Results: 61 (78,2%) patients had sinus rhythm during their initial ECG record. None of patients had internal carotid stenosis above 50%. Compared to ctrl, pts had higher WBC (7676±2200 vs. 6820±1993, p= 0,04), neutrophil lymphocyte ratio (NLR) [82,3 (1,8-3,5) vs. 2,3 (1,8-3,5), p=0,001], Nt-pro BNP [55 ng/l (19-104) vs. 9 (7-18,6), p= 0,001], CRP [0,6 (0,3-1,5) vs. 0,3 (0,3-0,8), p=0,006], glucose [106 mg/dl(95-161) vs. 100 (86-121, p=0,04], Hba1c [9,2 % (5,8-10,4), vs. 5,8 (5,3-6,8), p=0,02], creatinine (0,99±0,29 mg/dl vs. 0,75±0,16, p=0,001), triglyceride (166,7±105 mg/dl vs. 117,3±46,5, p=0,001), uric acid (5,5±1,6 mg/dl vs. 4,8±1,5, p=0,02) and lower HDL mg/dl (41,7±8,9 vs. 46,4±10,4, p=0,01) levels. There was no difference in other rheologic and biochemical parameters, vitamin-D, parathyroid hormone, D-dimer and fibrinogen levels among pts and ctrl. Pts those dead compared to survivors during follow-up were older (71,72±10,88 years vs. 64,42±11,21, p=0,02), higher incidence of atrial fibrillation [n=7 (41,2, %)], higher NLR [3 (2,2-5,3) vs. 2,3 (1,6-3,2), p=0,04], higher NT-pro BNP [90,1 ng/l (43,4-266,2) vs. 42,9 (11,7-93,6), p=0,03], higher TSH [1,7 mIU/l (1,2-3,1) vs. 1,1 (0,5-1,9), p=0,03] and lower Vitamin D levels [8,9 µg/l (2,8-12,4) vs. 12,4 (8,4-17,2), p=0,02].

A cut off value ≥ 2.15 of NLR was found to predict stroke with 62 % sensitivity and 76 % specificity in ROC analysis.

Conclusion: NLR, presence of AF are important predictors of mortality in patients with stroke.

ID: 561

Topic: **Cardiology » PI for SHD - Others**Presentation Type: **Oral****PERCUTANEOUS CLOSURE OF THE LEFT ATRIAL APPENDAGE:
INITIAL EXPERIENCE WITH THE AMPLATZER™ AMULET™.**Hakan Aksoy, Sercan Okutucu, **Begum Yetis Sayin**, Ebru Ercan Akgul, Ali Oto*Memorial Ankara Hospital, Ankara, Turkey***Corresponding Author (haksoy63@yahoo.com)**haksoy63@yahoo.com, sercanokutucu@yahoo.com, begumyts@yahoo.com, ebruercan@yahoo.com,
alioto@tksv.org***Abstract Text**

Objectives: Percutaneous left atrial appendage (LAA) closure is an important therapeutic option for prevention of thromboembolic stroke in patients with atrial fibrillation (AF), especially when contraindications exist for oral anticoagulation. The Amplatzer™ Amulet™ (Amulet) is the evolution of the Amplatzer™ Cardiac Plug, a dedicated device for percutaneous LAA occlusion. We aimed to evaluate our short term results of LAA closure (initial experience) using the Amulet LAA system.

Study design: Nineteen patients (11 men, 8 women; mean age 78.8±2 years) with nonvalvular AF, a high risk for cardioembolic stroke (mean CHA2DS2-VASc score 4.0±1.5), and contraindications to oral anticoagulation or history of stroke despite anticoagulation underwent percutaneous LAA closure using the Amulet LAA system. All the procedures were performed under general anesthesia and fluoroscopy and transesophageal echocardiography (TEE) guidance. Transthoracic echocardiography was performed 24h after the procedure in order to rule out procedural complications before discharge.

Results: The LAA was successfully occluded in all the patients (100%). The mean device size was 26.3±1.4 mm. The median hospital stay was 1 day. None of the patients experienced major adverse events during a median follow-up of 90 days (interquartile range 60-185 days).

Conclusion: Our initial experience suggests that percutaneous LAA closure with the Amulet LAA system is safe and feasible, with favorable short-term clinical outcomes.

Oral Presentations

Treatment Strategies in Atrial Fibrillation

Date: 30.03.2019 Time: 09:45 - 11:15 Hall: 5

ID: 410

Topic: **Cardiology » Electrocardiography and Non Invasive Electrocardiology**

Presentation Type: **Oral**

EVALUATION WITH ECG OF CARDIOPROTECTIVE EFFECTS TO GLUCAGON-LIKE PEPTIDE ANALOG EXENDIN-4 IN DOXORUBICIN INDUCED CARDIOTOXICITY

Serdar Savaş Gül¹, Hatice Aygün²

¹Visart Medical Imaging Center, Ankara, Turkey

²Gaziosmanpaşa University, Tokat, Turkey

**Corresponding Author (gopnukleertip@gmail.com)*

gopnukleertip@gmail.com, hatice_5aygun@hotmail.com

Abstract Text

ABSTRACT

BACKGROUND: Doxorubicin is an antineoplastic drug that is widely used in chemotherapy. The cardiotoxicity of doxorubicin is commonly seen toxicity with high morbidity and mortality. It is aimed to evaluate effects of glucagon-like peptide (GLP-1) analog exendin-4, on doxorubicin -induced cardiotoxic rat by electrocardiographic (ECG) methods in this study.

METHODS: 28 male Wistar rats randomly divided into 4 groups named as: untreated control, doxorubicin-induced cardiotoxicity, exendin-4 treated and doxorubicin + exendin-4 treated groups. Cardiotoxicity was induced by DOX injection (cumulative dose: 18 mg/kg, intraperitoneal [i.p.]) at an interval of 24 hours (h) for three day (5th 6th and 7th) in study. As substance control, exendin-4 (10 µg/kg/i.p) were given to rats for 7 days. Rats receiving exendin-4 treatment in the doxorubicin-induced cardiotoxicity group received exendin-4 (10 µg/kg/i.p) for 7 days and were injected with (18 mg/kg, i.p.) on doxorubicin 5th, 6th and 7th days. On the 8th day, we examined the ECG, results of exendin-4 on the doxorubicin -induced changes.

RESULTS: Cardiotoxicity of doxorubicin, which were characterized with conduction abnormalities which is increased QRS complex ($p < 0.001$), QT interval durations ($p < 0.001$), T wave duration ($p < 0.001$) and elevation of ST segment amplitude ($p < 0.001$). Treatment with exendin-4 significantly decreased all AMT-associated conduction abnormalities in ECG ($p < 0.001$) (Figure 1).

CONCLUSIONS: ECG abnormalities can show doxorubicin-induced cardiotoxicity. According to results of this study, exendin-4 has potent beneficial effects on doxorubicin induced cardiotoxicity.

Key words: exendin-4, GLP, doxorubicin, cardiotoxicity, rat

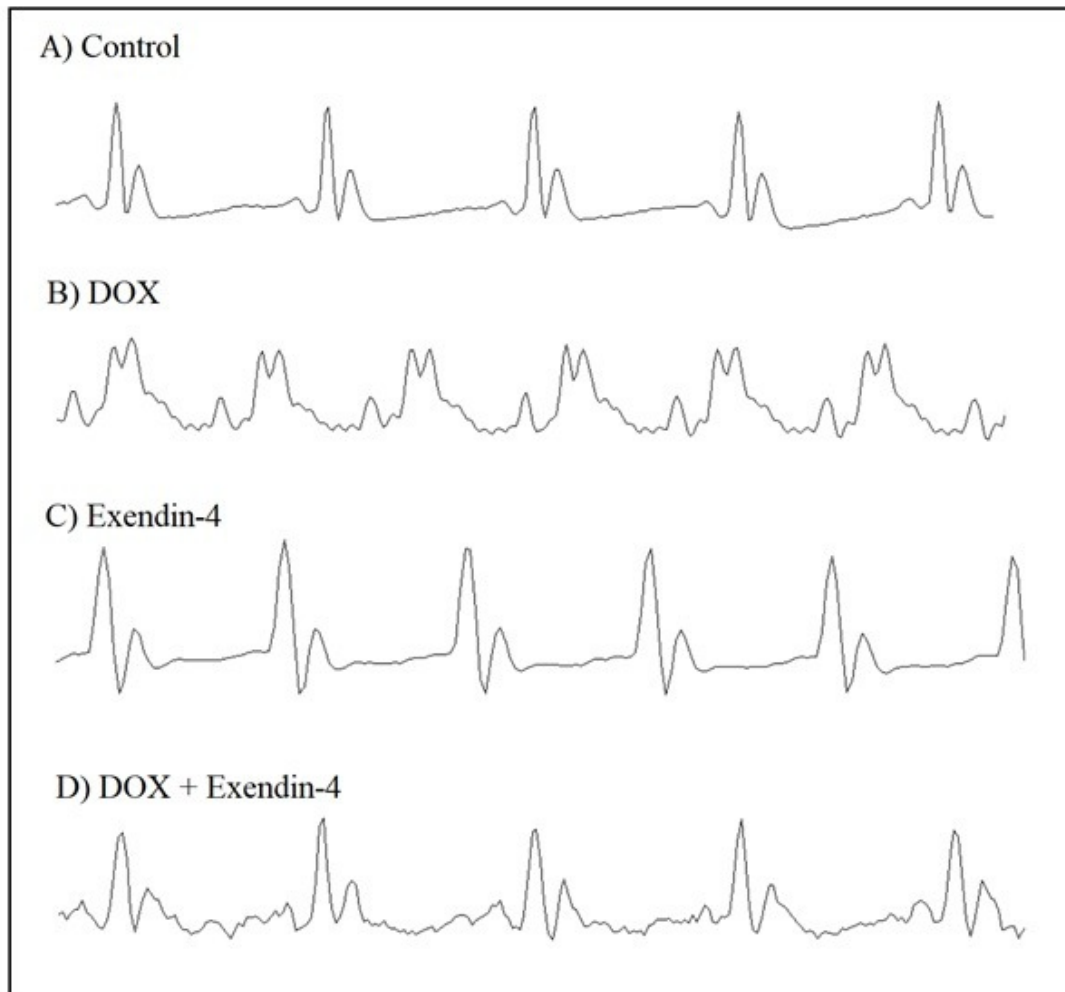


Figure 1. Cardiotoxicity of doxorubicin, which were characterized with conduction abnormalities which is increased QRS complex and QT interval durations and also potent cardioprotective effect of glucagon-like peptide analog exendin-4.

ID: 239

Topic: **Cardiology » Transcatheter Ablation for Tachyarrhythmias - Atrial Fibrillation**

Presentation Type: **Oral**

AUTOMATIC MARKING AS A TOOL FOR IDENTIFYING POSSIBLE GAPS OF THE ABLATION LINE IN ATRIAL FIBRILLATION ABLATION

Krasimir Dzhinov, Tosho Balabanski

National Heart Hospital, Sofia, Bulgaria

**Corresponding Author (dzhinov@yahoo.com)*

dzhinov@yahoo.com, tbalabanski@gmail.com

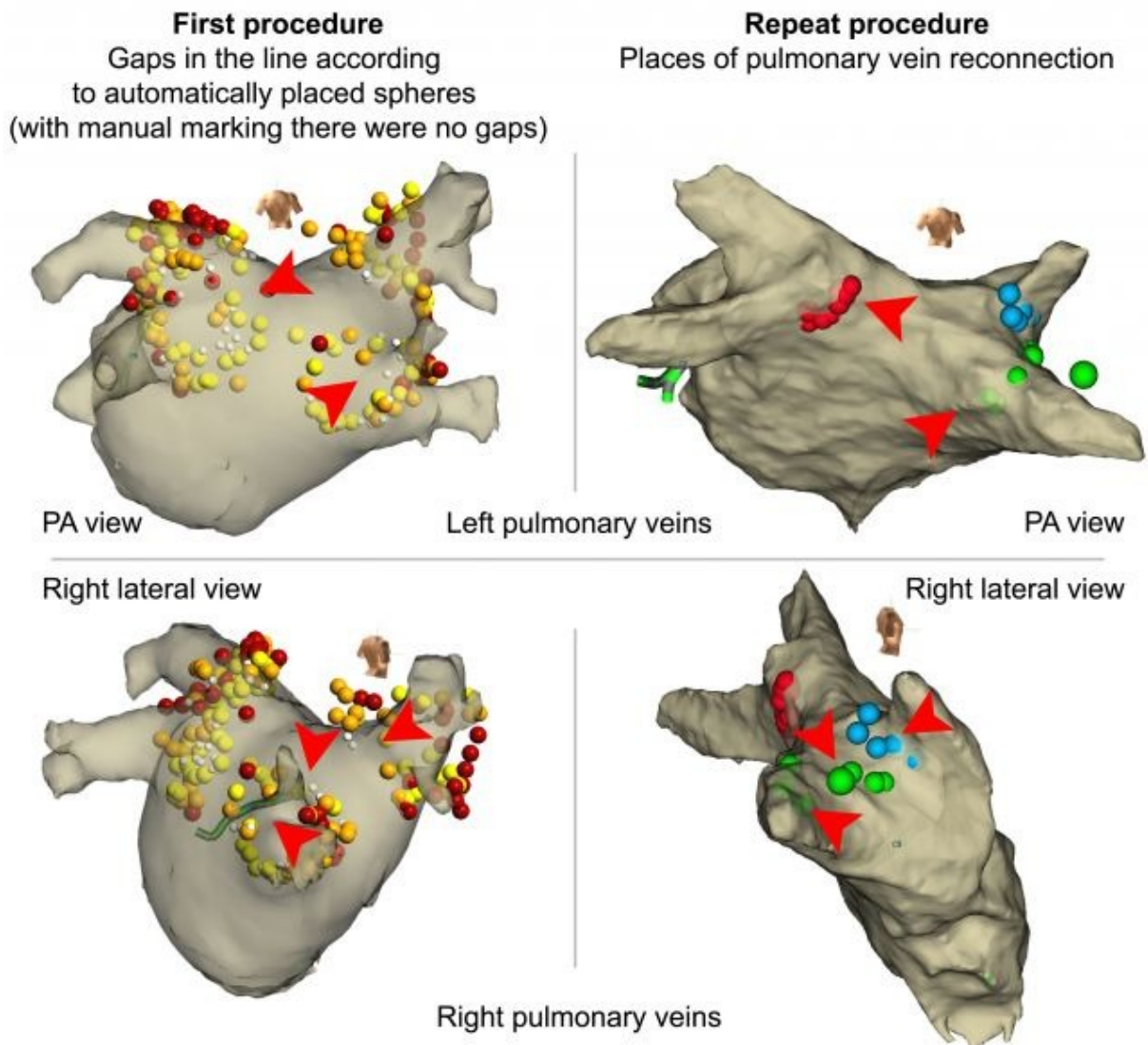
Abstract Text

BACKGROUND: Pulmonary vein (PV) reconnection is an important reason for atrial fibrillation (AF) recurrence. Manual marking is the current widespread practice for visualization of the ablation lesions. The aim of this study was to compare manual and automatic marking for the validation of gaps in the ablation lines.

METHODS: Thirty-one patients with paroxysmal AF underwent electroanatomical mapping and radiofrequency ablation using manual and automatic marking of the lesions. PV isolation was performed in all patients. Lesions were marked automatically in different colors depending on force-time integral, absolute impedance drop and ablation time as follows: white (<50 gs; <6 Ω; < 5 s); yellow (50-150 gs; 6-8 Ω; 5-15 s); orange (150-300 gs; 8-10 Ω; 15-30 s); red (>300 gs; >10 Ω; >30 s). The operators were blinded for automatic marking. Auto-marks were compared with manually placed spheres for the allocation of acute reconnection sites during the procedure. 24-hour Holter ECG monitoring was performed on the first and third month after the ablation and during follow-up. Second procedure was considered in case of AF recurrence.

RESULTS: Acute PV reconnections were determined by pacing maneuvers in 14 patients during the index procedure and were treated with additional energy application. Gaps in the lines in these patients were also identified with automatic marking (n=9 patients) while manual marking showed no gaps (n=0 patients, p=0.0006). At the end of the procedure, visual gaps in the ablation lines were identified in 27 patients with automatic marking versus 9 patients with manual marking (p<0.0001) despite that PV isolation was achieved in all patients. Recurrence of AF was documented in 9 of 31 patients (mean age 56.9±8.5 years, 22 males) during follow-up (9.3±6.8 months). Gaps in the lines were identified in five of these patients with automatic marking versus one with manual marking (p=0.015). Two patients underwent re-ablation while 2 procedures were postponed because of left atrial appendage thrombi. Three of 9 patients had asymptomatic recurrences and refused a redo procedure while 2 patients experienced recurrences in the blanking period. The sites of the PV reconnections identified during repeat procedures correlated positively with the gaps in the line visualized with automatic marking during the first procedure (Figure).

CONCLUSIONS: Automatic marking identifies gaps in the ablation lines more accurately than manual marking. The long-term effect of these gaps on the arrhythmia free survival is uncertain due to the small sample size.



ID: 361

Topic: Cardiology » Transcatheter Ablation for Tachyarrhythmias - Atrial FibrillationPresentation Type: **Oral****CORONARY ARTERY DOMINANCE MAY PREDICT ATRIAL FIBRILLATION RECURRENCE AFTER CRYOBALLOON PVI**

Ahmet Korkmaz, Ilyas Emre Yakıcı, Bekir Demirtaş, Funda Başığit, Havva Tuğba Gürsoy, Emrullah Kızıltunç, Ender Örnek, Özgül Uçar Elalmış, Mehmet Ileri, Ümit Güray

Ankara Numune Education and Research Hospital, Ankara, Turkey

**Corresponding Author (drahmtkrkmz07@gmail.com)*

drahmtkrkmz07@gmail.com, ilyasemreyakicii@gmail.com, bkrdemirtas@gmail.com, ftuna02@yahoo.com, tugbagursoy@yahoo.com, e.kiziltunc@gmail.com, ender_ornek@hotmail.com, ozgul_ucar@yahoo.com, maraspoli2000@yahoo.com, umit.guray@gmail.com

Abstract Text**ABSTRACT**

BACKGROUND AND AIM: Catheter-based atrial fibrillation (AF) ablation primarily for pulmonary vein isolation (PVI) has become a significant therapeutic alternative with improved efficacy and safety for symptomatic and drug-refractory AF patients. It is evident that AF time and left atrium (LA) diameter have the most critical impact on AF recurrence. Coronary artery dominance (CAD) influences the amount and anatomic location of myocardium that is perfused by the left or right coronary circulation. In this study, we aimed to evaluate the role of CAD for predicting AF recurrence after cryoballoon PVI.

METHODS: We retrospectively analyzed clinical, laboratory, and angiographic data from consecutive patients who underwent coronary angiography and successful cryoballoon ablation method for 12-lead ECG confirmed, symptomatic, and drug refractory paroxysmal AF. Images of the coronary angiography were retrospectively reviewed for the coronary artery dominance by two experienced observers. The coronary artery system was classified as right dominant if the RCA, as left dominant if the LCX. Significant coronary artery disease was defined as $\geq 50\%$ narrowing of the luminal diameter in at least one projection of at least one major epicardial artery and was excluded.

RESULTS: A total of 140 patients without coronary artery disease and structural heart disease who underwent successful cryoballoon ablation were included in the study. There were 101 right dominant (72%), and 39 left dominant (28%) pattern. A total of 26 patients (22%) had developed AF recurrence during follow up (Table 1). No significant difference was observed between the AF recurrence (+) and (-) groups regarding age, sex, other baseline clinical and laboratory characteristics ($p > 0.05$) (Table 2). AF recurrence rates were 41% in the left coronary dominant group and 15% in the right coronary dominant group ($p=0.001$). According to AF recurrence after cryoballoon PVI, only follow-up time (15.7 ± 2.4 vs 14 ± 1.8 months, $p=0.001$), left atrium diameter (LAD) (41.8 ± 2 vs 40.6 ± 1.8 , $p=0.003$) and CAD (left CAD, 51.6% vs 21.1%, $p=0.001$) were significantly associated with AF recurrence (Table 2-3, Figure 1). AF recurrence rates in multivariable logistic regression analysis according to AF recurrence after cryoballoon PVI, follow-up time, LAD and CAD were independent predictors of AF recurrence (Table 4).

CONCLUSIONS: Our findings suggested that left CAD may be related to AF recurrence after cryoballoon PVI. Coronary artery dominance may be an additional predictor of atrial fibrillation recurrence if supported by larger prospective studies.

Key Words: Atrial fibrillation, Coronary artery dominance

Table 1. Baseline characteristics and demographical features of the study population.

		Min-Max	Median	Mean. \pm s.d./n-%
Age		19.0 - 63.0	43.0	41.8 \pm 7.8
Sex	Female			57 40.7%
	Male			83 59.3%
Weight,kg		58.0 - 112.0	75.0	78.0 \pm 11.6
Height,m		147.0 - 182.0	162.0	162.9 \pm 6.5
BMI		21.3 - 34.6	28.9	29.4 \pm 4.3
Coronary dominance	Right			101 72%
	Left			39 28%
Smoking				38 27%
DM				18 13%
HT				53 38%
Recurrence	Yes			31 22%
	No			109 78%
LAD,mm		37.0 - 47.0	40.0	40.8 \pm 1.9
Follow-up time		12.0 - 20.0	14.0	14.4 \pm 2.1
WBC, $\times 10^9$ /L		4.1 - 14.2	7.1 4.4	7.4 \pm 2.0
Neutrophil, $\times 10^9$ /L		1.9 - 11.2	2.2	4.5 \pm 1.5
Lymphocytes, $\times 10^9$ /L		1.0 - 6.6	13.9	2.4 \pm 0.9
Hgb, g/dL		9.6 - 18	262	14.1 \pm 1.5
PLT, $\times 10^9$ /L		122 - 472	96	267 \pm 65
Glucose,mg/dL		81 - 373	0.8 7.4	98 \pm 28
Creatinine,mg/dL		0.5 - 1.2	4.5	0.8 \pm 0.1
Total proteine,g/dL		5.8 - 8.5	144	7.4 \pm 0.5
Albumine, g/dL		3.7 - 5.1	200	4.5 \pm 0.3
TG, mg/dL		70 - 760	47	180 \pm 144
T.Cholesterol, mg/dL		101 - 360	118.0	202 \pm 48
HDL, mg/dL		28 - 77	20	47 \pm 11
LDL, mg/dL		58 - 255	20	120 \pm 38
ALT, U/L		13 - 52	1.9	23 \pm 10
AST, U/L		11 - 48	116	21 \pm 7
NLR		0.8 - 6.2		2.0 \pm 0.8
PLR		43 - 286		120 \pm 41

BMI, body mass index; DM, diabetes mellitus; HT, hypertension; Hgb, haemoglobin; HDL-C, high density lipoprotein cholesterol; LDL-C, low density lipoprotein cholesterol; LAD, left atrium diameter; NLR, neutrophil-to-lymphocyte ratio; PLT, platelet; PLR, platelet-to-lymphocyte ratio; TG, triglyceride; WBC, white blood count

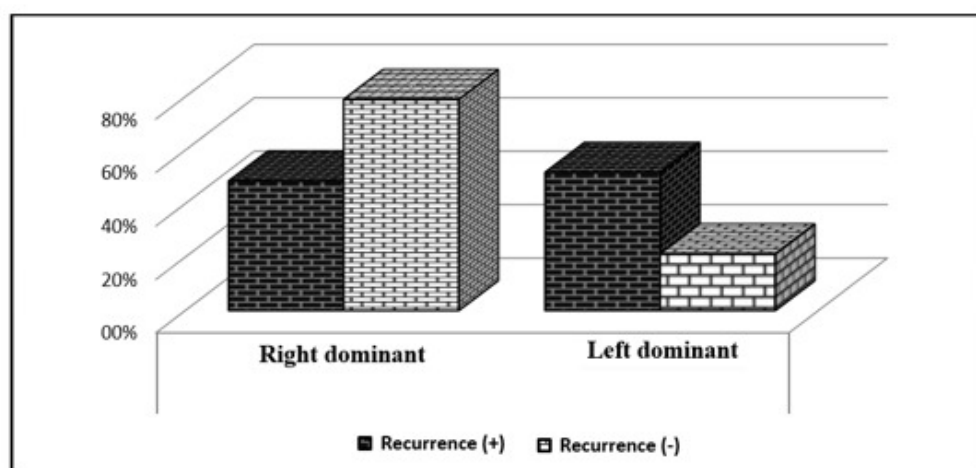
Table 2. Baseline characteristics and laboratory parameters of the study population according to AF recurrence after cryoballoon PV isolation.

		Recurrence (+) n=31		Recurrence (-) n=109		P
		Mean±sd / n-%	Median	Mean±sd / n-%	Median	
Age		42.6 ± 5.9	42	41.6 ± 8.3	43	0.850 ^m
Sex	Female	15 48.4%		42 38.5%		0.324 ^{x†}
	Male	16 51.6%		67 61.5%		
BMI		30.3 ± 3.7	29.7	29.2 ± 4.4	27.8	0.070 ^m
Coronary dominance	Right	15 48.4%		86 78.9%		0.001^{x†}
	Left	16 51.6%		23 21.1%		
Smoking		7 22.6%		31 28.4%		0.517 ^{x†}
DM		2 6.5%		16 14.7%		0.217 ^{x†}
HT		10 32.3%		43 39.4%		0.466 ^{x†}
LAD,mm		41.8 ± 2.0	42.0	40.6 ± 1.8	40.0	0.003^m
Follow-up time,mo		15.7 ± 2.4	15.0	14.0 ± 1.8	14.0	0.001^m
WBC,×10 ⁹ /L		7.6 ± 1.9	7.1	7.4 ± 2.1	7.2	0.547 ^m
Neutrophil,×10 ⁹ /L		4.7 ± 1.4	4.6	4.5 ± 1.5	4.2	0.221 ^m
Lymphocytes,×10 ⁹ /L		2.6 ± 0.8	2.5	2.4 ± 0.9	2.1	0.073 ^m
Hgb,gr/dL		14.1 ± 1.3	14.4	14.0 ± 1.6	13.7	0.511 ^m
PLT, ×10 ⁹ /L		263 ± 61	258	268 ± 67	263	0.648 ^m
Glucose,mg/dL		93 ± 19	96	99 ± 29	95.0	0.530 ^m
Creatinine,mg/dL		0.8 ± 0.1	0.9	0.8 ± 0.1	0.8	0.239 ^m
Total proteine,g/dL		7.3 ± 0.4	7.4	7.4 ± 0.5	7.4	0.337 ^t
Serum albumine, g/dL		4.4 ± 0.3	4.3	4.5 ± 0.3	4.5	0.076 ^m
TG, mg/dL		163 ± 69	151	185 ± 59	139	0.962 ^m
T.Cholesterol, mg/dL		208 ± 54	193	200 ± 46	200	0.646 ^m
HDL, mg/dL		48.8 ± 12.6	46	46.9 ± 10.8	47	0.614 ^m
LDL,mg/dL		126.5 ± 43.7	121	117.9 ± 36.1	118	0.462 ^m
ALT, U/L		23 ± 11	20	23 ± 10	20	0.813 ^m
AST, U/L		22 ± 10	19	21 ± 7	20	0.457 ^m
NLR		2.0 ± 0.7	2.0	2.0 ± 0.9	1.8	0.681 ^m
PLR		110.4 ± 42	107	122.2 ± 41	118	0.054 ^m

BMI, body mass index; DM, diabetes mellitus; HT, hypertension; Hgb, haemoglobin; HDL-C, high density lipoprotein cholesterol; LDL-C, low density lipoprotein cholesterol; LAD, left atrium diameter; mo, months; NLR, neutrophil-to-lymphocyte ratio; PLT, platelet; PLR, platelet-to-lymphocyte ratio; TG, triglyceride; WBC, white blood count, ^t t-test/ ^m Mann-Whitney U test/ ^{x†} Chi-squared test

Table 3. The relationship between coronary artery dominance and recurrence of paroxysmal AF after catheter ablation.

	Recurrence (+),n=31 (22%)	Recurrence (-),n=109, (78%)	p
Right Coronary Dominance n=101, (72%)	15 (15%)	86 (85%)	0.001
Left Coronary Dominance n=39, (28%)	16 (41%)	23 (59%)	

**Figure-1. The relationship between coronary artery dominance and recurrence of paroxysmal AF after catheter ablation.****Table 4. Multivariate logistic regression analysis showing independent predictors of AF recurrence after cryoballoon PV isolation.**

Variables	Odds ratio	95% CI	P value
Age	1.007	0.942-1.076	0.839
Sex (Male)	1.381	0.502-3.797	0.532
Albumine	0.753	0.135-4.215	0.747
PLR	0.840	0.650-1.250	0.358
BMI	1.030	0.921-1.151	0.604
LAD	1.670	1.266-2.203	<0.001
Follow-up time	1.518	1.182-1.950	0.001
Coronary dominance	5.701	1.994-16.301	0.001

BMI, body mass index; LAD, left atrium diameter; PLR, Platelet-to-lymphocyte ratio

ID: 14

Topic: **Cardiology » Management of Atrial Fibrillation**Presentation Type: **Oral****THE NOVEL CHA₂DS₂VASC-FSH SCORE IS PREDICTIVE OF SEVERE CORONARY ARTERY DISEASE ON CORONARY ANGIOGRAPHY IN PATIENTS WITH ATRIAL FIBRILLATION AND UNSTABLE SYMPTOMS****Orçun Çiftci, Ibrahim Haldun Müderrisoğlu***Başkent University Faculty of Medicine, Ankara, Turkey***Corresponding Author (orucun@yahoo.com)**orucun@yahoo.com, ihaldunum@gmail.com***Abstract Text**

Objective: Atrial fibrillation may create confusion about the presence of severe or unstable coronary artery disease (CAD) in cases with unstable symptoms. We aimed to test a newly developed score for various settings, the CHA₂DS₂VASC-FSH score, for the prediction of severe and unstable CAD in patients with AF and unstable symptoms.

Materials and Method: We retrospectively analyzed 72 patients presenting with atrial fibrillation with unstable symptoms (chest pain or one or more of its equivalents, including resting dyspnea, palpitations, altered consciousness, syncope, diaphoresis, agitation, decompensated heart failure or pulmonary edema), who underwent coronary angiography at Başkent University Faculty of Medicine Hospital between April 2011 and January 2016. We compared patients with and without severe coronary lesions on coronary angiography with respect to demographic, biochemical, echocardiographic parameters, as well as the newly defined CHA₂DS₂VASC-FSH score. Independent predictors of severe and unstable coronary artery disease were also sought for by univariate and multivariate analysis.

Results: Seventy-two patients aged 65.7 ± 11.2 years were enrolled. Thirty-five (48.6%) patients had new-onset AF; 13 (18.1%) patients had paroxysmal AF; 4 (5.6%) had persistent AF; and 20 (27.8%) had permanent AF. Eleven (15.3%) patients had unstable CAD. A total of 30 (41.7%) patients had admission troponin I positivity; 44 (61.1%) had follow-up troponin I positivity, 50 (69.4%) patients had overall troponin I positivity, and 38 (52.8%) patients had a clinically significant delta troponin I change. Thirty-five (48.6%) patients had severe CAD. Among these, 8 (22.9%) had single vessel-disease and 27 (77.1%) had multivessel disease. A total of 24 (33.3%) patients underwent coronary intervention. Among these, 7 (29.2%) underwent coronary artery bypass grafting and 17 (70.8%) underwent percutaneous coronary intervention and stenting.

The comparison of the two groups with and without severe CAD revealed that the significant CAD group had a significantly greater CHA₂DS₂VASC-FSH score ($p < 0.05$). On univariate analysis, severe CAD was significantly correlated to CHA₂DS₂VASC score ($r = 0.335$; $p < 0.05$), CHA₂DS₂VASC-FSH score ($r = 0.359$; $p < 0.05$), hypertension ($r = 0.330$; $p < 0.05$), coronary artery disease (CAD) ($r = 0.287$; $p < 0.05$), chronic renal disease ($r = 0.338$; $p < 0.05$), chest pain ($r = 0.293$; $p < 0.01$), creatinine ($r = 0.250$; $p < 0.01$), and RDW ($r = 0.270$; $p < 0.01$). In multivariate analysis the CHA₂DS₂VASC-FSH score ($X^2 = 1.80$ (95% CI 1.24-2.61; $p < 0.05$) and severe chronic renal disease ($X^2 = 7.96$ (95% CI 1.46-43.51; $p < 0.05$) were significant predictors of severe coronary artery disease. In ROC analysis a CHA₂DS₂VASC-FSH score of 3 or greater having a sensitivity of 77.1% and a specificity of 56.8% for severe CAD (AUC 0.703 (0.582-0.825)).

Conclusion: In patients with AF and unstable symptoms, the CHA₂DS₂VASC-FSH score may predict severe CAD. In clinical settings where clinical doubt exists whether symptoms are caused by severe or unstable CAD, a CHA₂DS₂VASC-FSH score of at least 3 and/or a positive delta troponin I change can be used to make decisions regarding with invasive coronary angiography. In the future, the CHA₂DS₂VASC-FSH score can be combined with other biochemical and echocardiographic predictors of atherosclerosis to make better predictions for the presence of CAD in patients with AF.

Keywords: Atrial fibrillation, coronary artery disease, unstable

ID: 212

Topic: **Cardiology » Management of Atrial Fibrillation**Presentation Type: **Oral****LINK BETWEEN EPICARDIAL FAT THICKNESS AND TIME TO
CONVERSION OF RECENT-ONSET ATRIAL FIBRILLATION TO SINUS
RHYTHM WITH AMIODARONE THERAPY****Ihsan Dursun, Selim Kul***Sağlık Bilimleri University, Ahi Evren Education and Research Hospital, Trabzon, Turkey***Corresponding Author (ihsandursun76@gmail.com)**ihsandursun76@gmail.com, selimkul@gmail.com***Abstract Text**

BACKGROUND AND AIM: Recent-onset atrial fibrillation (AF) is a frequent cause for presentation to the emergency department. Clinical studies have demonstrated that epicardial fat (EPF) thickness is associated with the presence, severity, and recurrence of AF. There is no study investigates to predictors of the time to conversion of AF to sinus rhythm with amiodarone therapy. The aim of this study was to investigate predictors of time to conversion of AF to sinus rhythm in patients with recent-onset AF during cardiovascular emergency phase.

METHODS: All 102 patients admitted to the emergency room with symptomatic recent-onset AF (lasting <48 h), were hemodynamically stable, were registered consecutively. Patients received an intravenous amiodarone doses of 150 mg over 10 minutes, with a subsequent infusion of 1mg/minute for six hours, then 0.5 mg/minute for 36 hours. Those who converted to sinus rhythm within the first 48 hours after the therapy were included. Finally 82 patients were assigned in our study. Time taken from the beginning of drug administration to conversion to sinus rhythm were recorded. EPF thickness was measured using 2-D echocardiographic parasternal long-axis views. Patients were divided into two group according to conversion duration; Group 1 had shorter conversion time (<12 h) and Group 2 had longer conversion time (>12 h).

RESULTS: Median age was 62 years (interquartile range (IQR) 54-69 years). The mean initial heart rate was 138 ± 21 bpm. Median admission time to hospital was 420 min (IQR 150-840 min) and time to conversion to sinus rhythm after the amiodarone therapy was 230 min (IQR 60-720 min). No significant differences were observed in the baseline characteristics of the two groups (Table 1). Mean EPF thickness were higher in group 2 compared to group 1 (4.6 ± 1.25 mm vs. 5.2 ± 1.4 mm, $P=0.04$). Also, a significant positive correlation was found between EPF thickness and conversion duration ($\rho = 0.307$, $P=0.005$) in all patients (Figure1). Multivariate logistic regression analysis (including age, sex, diabetes mellitus, hypertension, LVEF, BMI, left atrial diameter, number of AF attack, duration of AF before the treatment, EPF thickness, C-reactive protein, troponin I) showed that EPF thickness ($P=0.022$, OR:2.9, 95% CI:1.1-7.6), admission troponin I level > 0.01 ($P=0.024$, OR:27, 95% CI: 1.5-48.7), lower age ($P=0.018$, OR: 0.7, 95% CI: 0.6-0.9), female sex ($P=0.039$, OR: 139, 95% CI: 1.2-14.6) and low LVEF ($P=0.039$, OR: 0.6 95%CI: 0.4-0.9) were significantly associated with longer conversion time.

CONCLUSIONS: Our study is the first to evaluate to conversion duration by amiodarone therapy of recent-onset atrial fibrillation. We found that the EPF thickness were associated with time to conversion of sinus rhythm in patients with recent-onset AF. EPF thickness may be used in prediction of the longer time to conversion. Longer conversion times extend the in-hospital stay length, which can affect medical care and costs

ID: 20

Topic: **Cardiology » Arrhythmias and Antiarrhythmic Therapy**Presentation Type: **Oral****THE ASSOCIATION BETWEEN APO-A1 LEVELS AND LONE ATRIAL FIBRILLATION****Tufan Çınar¹, Veysel Ozan Tanık², Kadir Gurkan³***¹Health Science University, Sultan Abdülhamid Han and Training Hospital, Istanbul, Turkey**²Ankara Dış Kapı Yıldırım Beyazıt Training and Research Hospital, Ankara, Turkey**³Siyami Ersek Cardiovascular and Thoracic Surgery Hospital, Istanbul, Turkey***Corresponding Author (drtufancinar@gmail.com)**drtufancinar@gmail.com, drozantanik@gmail.com, drkadirgurkan@gmail.com***Abstract Text****Objective:**

In recent studies it has been stated that atrial fibrillation (AF) is closely related to inflammation. Apolipoprotein-A1 (Apo-A1) has anti-oxidant, anti-inflammatory, and anti-thrombotic effects. This study aimed to figure out the relation between lone AF and Apo-A1 levels.

Material and Method:

This prospective study consisted of 35 patients (24 males and 11 females). The control group consisted of 34 comparable healthy subjects. The participants were followed-up at least for 1 year after restoration of the normal sinus rhythm.

Results:

As an inflammatory marker, serum high sensitive C-reactive protein (HsCRP) level was significantly higher in lone AF group ($p=0.016$). The level of Apo-A1 was significantly lower in lone AF group ($p=0.001$). Apo-B levels were not statistically different between the groups. The ratio of ApoB/Apo-A1 was lower in the control group. The disease duration and the frequency of AF episodes were not correlated with Apo-A1 levels.

Conclusion:

The present study showed that the patients with lone AF have low levels of Apo-A1 and high levels of HsCRP compared to healthy subjects. As a result, Apo-A1 may play a role in the pathophysiology of AF.

Table 1: The comparison of biochemical and hematological measurements between lone AF and control group

	Total	Control (n=34)	Patients (n=35)	P value
HbA1c (mg/dL)	5.69±0.33	5.62±0.36	5.75±0.30	0.123
LDL (mg/dL)	122.07±28.41	122.21±28.25	121.94±28.98	0.970
VLDL (mg/dL)	26.13±13.48	21.73±11.54(19.0)	30.40±13.99(29.0)	⁴ 0,007**
Total Cholesterol (mg/dL)	199.78±36.64	198.21±38.22	201.31±35.53	0.727
HDL(mg/dL)	50.30±11.50	52.74±10.24	47.94±12.30	0.084
TG(mg/dL)	129.30±64.22	111.91±59.48	146.2±64.95	0.025*
BUN	14.39±3.07	15.12±2.96	13.69±3.06	0.052
Creatin (mg/dL)	0.84±0.15	0.82±0.13	0.85±0.16	0.347
AST (U/L)	24.13±8.16	23.35±8.46	24.89±7.90	0.439
ALT (U/L)	29.20±23.57	26.50±23.28(21.0)	31.83±23.89(27.0)	⁴ 0,003**
Fasting blood glucose (mg/dL)	93.35±8.85	92.85±8.05	93.83±9.66	0.651
HsCRP	2.08±6.65	1.06±2.01(0.40)	1.54±1.99(1.02)	⁴ 0,016*
Apo-A1	2.19±0.70	2.55±0.44	1.84±0.74	0.001**
Apo-B	1,03±0,37	1,08±0,36	0,99±0,38	0,339
Apo-B/ Apo-A1	0,51±0,21	0,42±0,12(0,43)	0,59±0,24(0,60)	⁴ 0,002**
Hemoglobin (g/dL)	14.28±1.43	14.18±1.31	14.37±1.54	0.597
HCT (%)	42.85±4.08	42.45±3.78	43.23±4.39	0.433
WBC (x10 ³ µl)	6.58±1.73	6.63±1.87	6.53±1.6	0.821
MPV (fL)	8.93±0.85	8.79±0.82	9.08±0.87	0.160

ID: 321

Topic: **Cardiology » Arrhythmias and Antiarrhythmic Therapy**Presentation Type: **Oral****SILENT ATRIAL FIBRILLATION IS ASSOCIATED WITH INCREASED AORTIC INTIMA-MEDIA THICKNESS IN PATIENTS OVER 75 YEARS****Abdullah Orhan Demirtaş, Yahya Kemal İçen, Hasan Koca, Mevlüt Koç***Adana Şehir Hastanesi, Adana, Turkey***Corresponding Author (aorhandemirtas@gmail.com)**aorhandemirtas@gmail.com, dryahyakemalicen@gmail.com, hasankoca90@hotmail.com, mevlutkoc78@yahoo.com***Abstract Text**

Objective: In previous studies, although the increase in aortic intima-media thickness (a-IMT) has been shown as a risk factor for many cardiovascular diseases, its association with silent AF is unclear. The aim of this study was to investigate the relationship between a-IMT thickness and silent AF in patients over 75 years of age.

Methods: 216 patients (102 males, 114 females) were included in the study. All the patients included in the study were in the sinus rhythm. In the 12-lead Holter ECG; if i) atrial activity is irregular, and there is variability in the length of the atrial cycle (shorter than 200 ms) ii) there is irregularity in R-R interval iii) there is absence of recurrent significant P waves iv) instead of P waves, fast, irregular, different shapes and sizes of fibrillation waves can be seen v) there is irregular and variable ventricular rate; the rhythm was considered to be as silent AF. The abdominal aorta and left and right common and internal carotid (CC and IC) arteries were examined with a high-resolution ultrasound system. Then, patients were divided into two groups as patients with and without silent AF.

Results: Patients were divided two groups as with and without silent AF. Silent AF was detected in 39 patients (18.1 %) when the 72-hour Holter ECG record of 216 patients was examined. It was determined that the longest episode of the patients with silent AF was 52 hours. When demographic findings were compared, patients with silent AF were found to be more obese, had a higher incidence of smoking, COPD and stroke, other findings were similar. When the medical treatments of patients with silent AF were examined, it was found that the medical treatments were not statistically significant between the two groups. When risk scores were compared, CHA2DS2-VASc and TIMI-AF scores were significantly higher in the group of patients with silent AF, HAS-BLEED scores were similar. When laboratory findings were compared, NT-proBNP serum levels were found to be significantly higher in patients with silent AF, other findings were similar. When the echocardiographic data were compared, LA systolic and end-diastolic diameters, LAV and LAVI values were significantly higher in silent AF patients, other echocardiographic parameters were similar. When the vascular USG data were compared, a-IMT and ic-IMT values were higher in silent AF patients, cc-IMT values were similar between the two groups. In binominal logistic regression analysis, TIMI-AF score, a-IMT, and LAVI were found to independently predictor for silent AF (Table). When ROC analysis of cut-off values of a-IMT value, LAVI value and TIMI-AF score were performed in terms of identifying patients with silent AF, the area under the ROC curve was 0.904, 0.870 and 0.709, respectively, and statistically significant ($p < 0.001$, for each, Figure 3). When the cut-off values taken for a-IMT, LAVI and TIMI-AF score were 2 mm, 47 ml/m² and 7; respectively, the possibility of silent AF with the best sensitivity and specificity was determined.

Conclusion: Increased a-IMT is closely associated with silent AF in over 75 years of age.

Keywords: Silen AF, Aortic intima-media, over 75 years.

ID: 484

Topic: **Cardiology » Arrhythmias and Antiarrhythmic Therapy**Presentation Type: **Oral****CAN MONOCYTE - HDL RATIO BE USED FOR PREDICTING ATRIAL FIBRILLATION AFTER CORONARY ARTERY BYPASS SURGERY?**Gökhan Arslan¹, Gökhan Erol¹, Celal Selçuk Ünal², Ertan Demirdaş¹¹*Gulhane Training and Research Hospital , Ankara, Turkey*²*Karabük Training and Research Hospital , Karabük, Turkey***Corresponding Author (drgokhanarslan@gmail.com)**drgokhanarslan@gmail.com, drgokhanerol@gmail.com, drselcukunal@yahoo.com, dr.ertandemirdas@gmail.com***Abstract Text****Introduction:**

Postoperative atrial fibrillation (POAF) is the most common type of arrhythmia that occurs after coronary artery bypass grafting (CABG) surgery. POAF that occurs in the early postoperative period of CABG is mostly short-lasting and sometimes it dissolves spontaneously. It is not an deadly complication but it is an important situation which may cause severe hemodynamic impairment, thromboembolic events and more serious arrhythmias. Discharge of inflammatory mediators and oxidative stress during cardiopulmonary bypass (CPB) are the most accused factors.

Lately monocyte count / HDL ratio (MHR) has been proposed to be an independent determinant of major cardiovascular diseases and a new prognostic factor for cardiovascular diseases. Inflammation, oxidative stress and atrial fibrosis have been shown to play a role for AF development. High MHR levels are accepted as an indicator for inflammation and oxidative stress. This study was designed in retrospective manner to investigate the role of MHR for predicting POAF development, of which oxidative stress is accused the most.

Methods:

This study included 780 patients whom underwent CABG surgery at Cardiovascular Surgery Clinics of Akay Hospital between December 2012 - September 2014 and whose monocyte counts and HDL results on the first postoperative day was available. The patients with normal sinus rhythm but have a history of atrial fibrillation, the patients whom had emergency CABG surgery or the ones whom had additional procedures along with CABG surgery were excluded. The patients were divided into two groups according to the development of POAF. MHR values were calculated for both groups.

Results:

179 (22.9%) of 780 patients who had CABG surgery developed POAF. MRH value was 14.3±8.1 in the group of patients that developed POAF and 11.2±5.4 in the group that did not develop POAF. This difference was statistically significant. (p=0.001).

Conclusion:

In conclusion, in our study we found that the patients who have high MHR values also have a high risk of developing POAF and MHR value is an important parameter for predicting POAF development after CABG surgery.

ID: 492

Topic: **Cardiology » Arrhythmias and Antiarrhythmic Therapy**Presentation Type: **Oral****IS THERE ANY RELATIONSHIP BETWEEN POSTOPERATIVE ATRIAL FIBRILLATION (POAF) AND VITAMIN D LEVELS ?****Erdem Çetin¹**, Celal Selçuk Ünal¹, Ertan Demirdaş², Gökhan Erol²¹*Karabük Training and Research Hospital , Karabük, Turkey*²*Gulhane Training and Research Hospital , Ankara, Turkey***Corresponding Author (erdem1978@gmail.com)**erdem1978@gmail.com, drselcukunal@yahoo.com, dr.ertandemirdas@gmail.com, drgokhanerol@gmail.com***Abstract Text**

Introduction

In addition to the bone, vitamin D receptors are also found in many cell membranes, especially in the cardiovascular system. Many mechanisms have been described showing that vitamin D deficiency is associated with postoperative atrial fibrillation (POAF) development. The most important of these mechanisms is the activation of the renin angiotensin aldosterone system (RAAS). Since vitamin D inhibits this axis, the formation of arrhythmias is facilitated due to the activation of this system in vitamin D deficiency. The aim of this study is to determine the relationship between vitamin D levels and POAF in patients with isolated coronary artery bypass grafting (CABG) operations.

Material-Method:

Our study was conducted between April 2017 and May 2018 in Karabük University Faculty of Medicine, Cardiovascular Surgery Clinic. Patients with a history of supraventricular arrhythmia, chronic renal failure, chronic hepatic failure, hyperparathyroidism, hyperthyroidism, hypercalcemia were excluded from the study. Patients using Vitamin D supplements and antiepileptic drugs were also excluded. 25-(OH) D levels were measured at postoperative second day in all patients.

Results:

Between April 2017 and May 2018, a total of 217 patients were included in the study. Of these patients, 35.1% (n = 76) were female and 64.9% (n = 141) were male. 25 (OH) D levels were below 30 ng / mL in 165 patients. POAF development was observed in 42 (19.3%) of 217 patients. In the POAF group, 25 (OH) D levels were significantly lower than those without POAF (9.51 ± 4.75 , 14.17 ± 9.23 , $p = 0.024$, respectively).

Conclusion:

When we evaluated the results obtained in our study, a significant relationship was found between 25 (OH) D levels and POAF development. We think that vitamin D replacement in patients with low levels of 25 (OH) D may be one of the strategies to prevent POAF development.

ID: 302

Topic: Cardiology » Stroke Prevention in Atrial Fibrillation

Presentation Type: Oral

PERCUTANEOUS LEFT ATRIAL APPENDAGE CLOSURE IN A PATIENT WITH HEMOPHILIA AND ATRIAL FIBRILLATION

Ümit Güray, Ahmet Korkmaz, Havva Tuğba Gürsoy, Özgül Uçar Elalmış

*Ankara Numune Education and Research Hospital, Ankara, Turkey***Corresponding Author (umit.guray@gmail.com)**umit.guray@gmail.com, drahtkrkmz07@gmail.com, tugbagursoy@yahoo.com, ozgul_ucar@yahoo.com***Abstract Text**

Abstract

Background: Atrial fibrillation (AF) is the most common cardiac arrhythmia and is a major cause of embolic stroke. In patients with hereditary bleeding disorders such as hemophilia, management of AF particularly anticoagulation can be quite challenging. Left atrial appendage(LAA) closure is an emerging option in AF patients who are not eligible for oral anticoagulation therapy because of contraindications or high bleeding risk.

Case Summary: A 67-years-old man with permanent AF and hemophilia was referred for further evaluation to our cardiology clinic by his primary hematologist. The CHA₂DS₂-VASc score was estimated to be 3 and the HAS-BLED score was 3. In our patient due to high risk of bleeding we decided to perform percutaneous LAA closure. Pre-procedural cardiac computerized tomography angiography and transesophageal echocardiography (TEE) performed for measurements of LAA dimensions and exclude the LAA thrombus. Percutaneous LAA occlusion was performed using 28 mm Amplatzer™ Amulet™ device. The final result was excellent without significant residual leak, pericardial effusion and embolic complication. Clopidogrel 75 mg/d and aspirin 81 mg/d for 1 month with adequate FVIII prophylaxis and then only aspirin 81 mg/d for two months were recommended. No antithrombotic was given after three months. The patient did not report any thrombotic or hemorrhagic adverse events and there were no complications related to implanted device after one year of follow up.

Discussion: In patients with hereditary bleeding disorders such as hemophilia, management of AF particularly anticoagulation can be quite challenging. In this report, we present a case of percutaneous LAA occlusion using Amplatzer™ Amulet™ device in a patient who has hemophilia and permanent AF. LAA closure has a potential to be more cost effective as compared to oral anticoagulation therapy due to lesser necessity of clotting factor infusion.

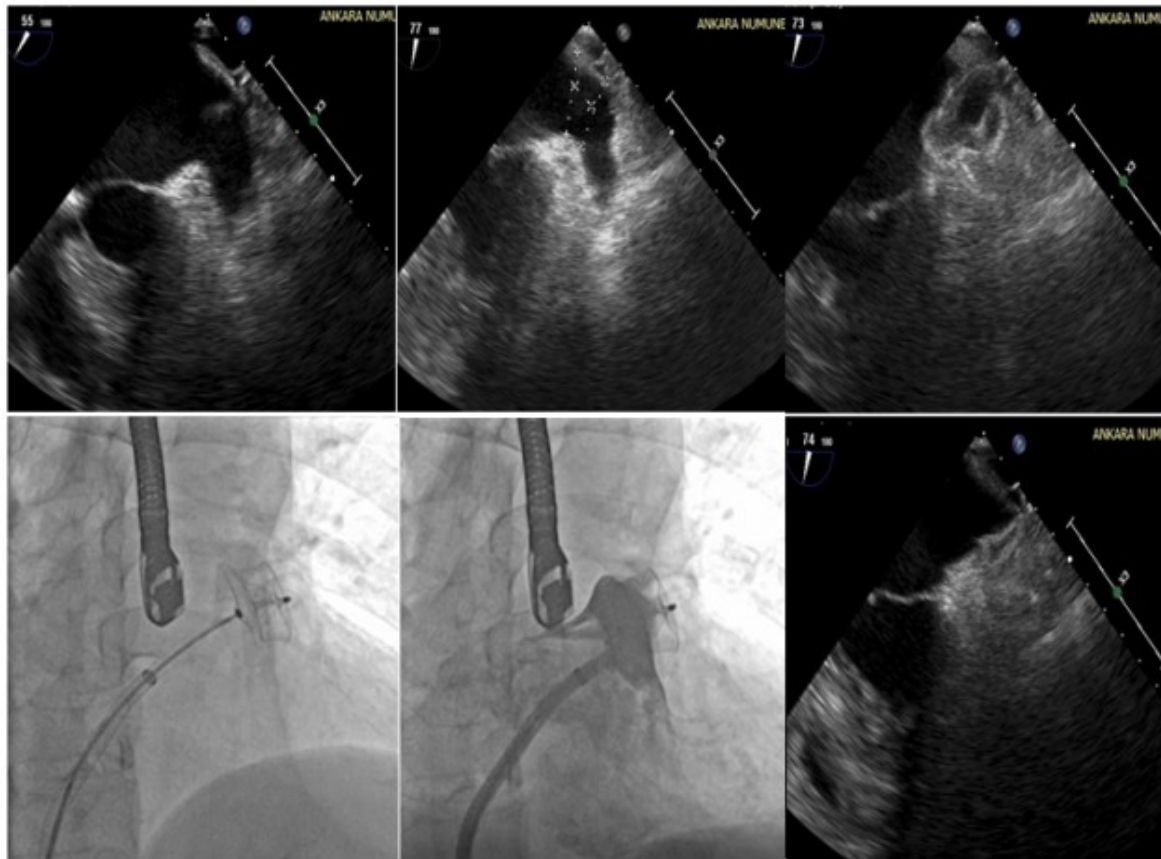

Figure 1. Two dimensional TEE, fluoroscopic and angiographic images of left atrial appendage closure procedure

Oral Presentations**Cardiac Implantable Devices and Arrhythmia Practice**

Date: 30.03.2019 Time: 11:15 - 12:45 Hall: 5

ID: 166**Topic: Cardiology » Cardiac Pacing for Bradyarrhythmias****Presentation Type: Oral****THE EFFECT ON UPPER EXTREMITY FUNCTIONS OF CARDIAC ELECTRONIC DEVICE PLACEMENT ON THE DOMINANT HAND SIDE****Ersin Şimşek¹, Aylin Şimşek², Uğur Kocabaş³, Doğaç Gürbüz³, Ayhan Aşkın⁴**¹*Tepecik Training and Research Hospital, İZMİR, Turkey*²*Dokuz Eylül University, Faculty of Medicine, İZMİR, Turkey*³*Katip Çelebi University Atatürk Training and Research Hospital, İZMİR, Turkey*⁴*Katip Çelebi University, Faculty of Medicine, İZMİR, Turkey***Corresponding Author (ercagsim@hotmail.com)**ercagsim@hotmail.com, dr.aylinsimsek@hotmail.com, ugurk46@yahoo.com, dr_dgc_gurbuz@hotmail.com, ayhanaskin@gmail.com***Abstract Text**

Background: Although cardiac implantable electronic device (CIED) implantation is considered to be minor surgery almost 60% of patients suffer from shoulder-related problems a short time after the procedure. The purpose of this study was to determine the possible effects of the preference of the dominant side for CIED implantation on the ipsilateral superior extremity functions.

Methods: The study included a total of 107 patients who had been living with a CIED for > 6 months. Patients were separated into two groups according to the dominant hand and side of the CIED. The ipsilateral dominant-hand group comprised those with a CIED on the same side as the dominant hand and the contralateral dominant hand group included patients with the CIED placed on the contralateral side to the dominant hand. Visual analogue scale (VAS) pain score, quick disability of the arm shoulder and hand questionnaire (QuickDASH) and maximum isometric grip strength tests were used to evaluate the upper extremity disabilities.

Results: No significant difference was determined between the groups in respect of VAS pain scores (p:0.10), QuickDASH scores (p: 0.21), and limitations of the shoulder joint range of motion (p:0.192). The maximum isometric grip strength was significantly different in the right hands between two groups (34(16-95) - 40(24-85)) (p: 0.02).

Conclusion: The present study shows that the joint range of motion limitation, pain, and disability of the upper extremity were no different in the affected arm compared to the healthy contralateral side with respect to the placement of the CIED on the dominant or non-dominant side.

ID: 489

Topic: Cardiology » Cardiac Pacing for Bradyarrhythmias

Presentation Type: Oral

ULTRASOUND-GUIDED PECTORAL NERVE BLOCK AND AXILLARY VENIPUNCTURE FOR IMPLANTATION OF PACEMAKERS**Serdar Bozyel, Ahmet Yalnız, Tümer Erdem Güler, Tolga Aksu***Health Sciences University, Derince Training and Research Hospital, Kocaeli, Turkey***Corresponding Author (drserdarbozyel@gmail.com)**drserdarbozyel@gmail.com, ahmetyalniz12@gmail.com, mettalamus@gmail.com, aksutolga@gmail.com***Abstract Text****Background:**

Combined ultrasound (US) guided pectoral nerves (PECS) block and axillary vein (AV) puncture for cardiac implantable electronic devices (CIEDs) can be effective to achieve optimal perioperative pain management and prevent access-related complications.

Methods:

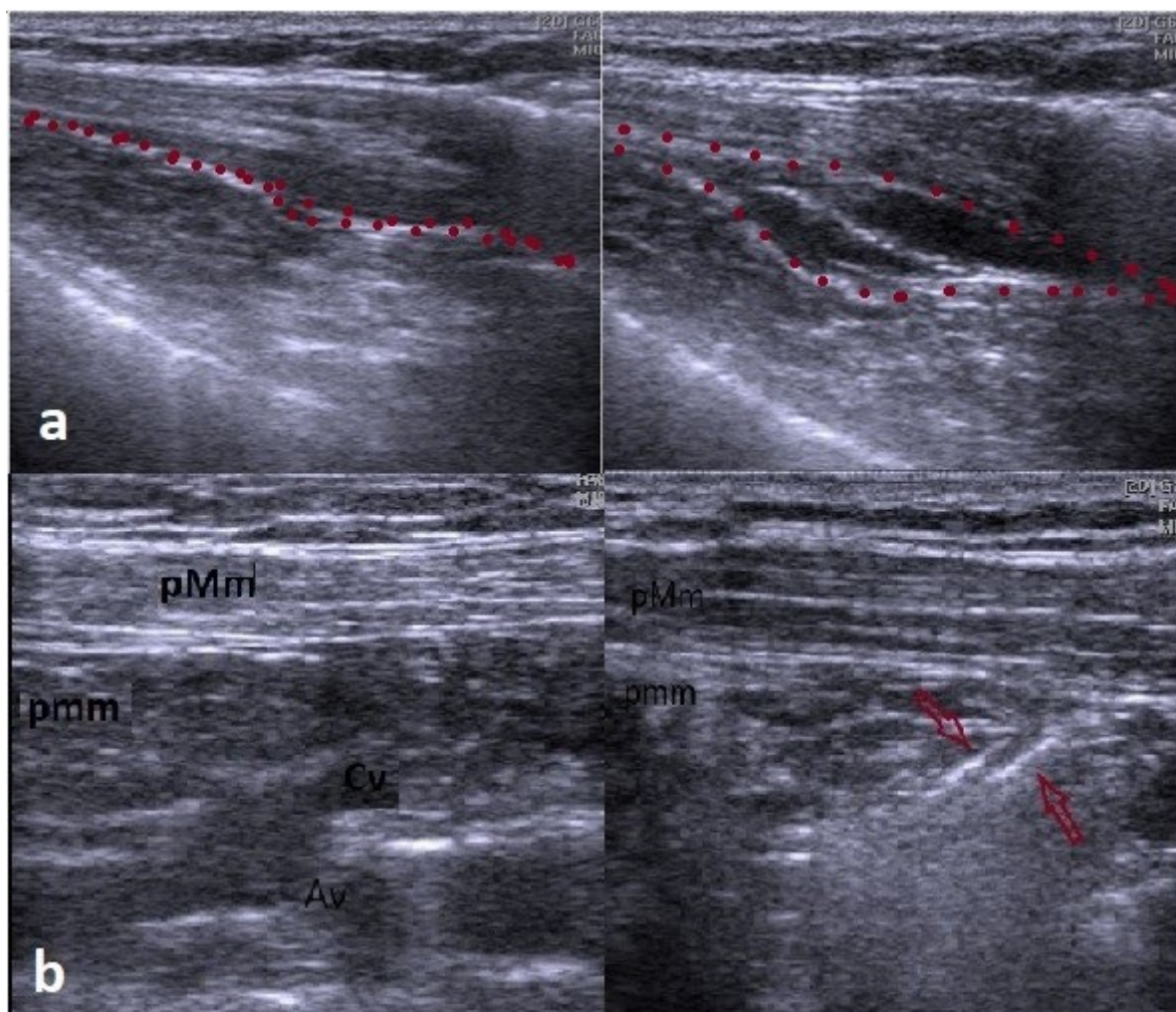
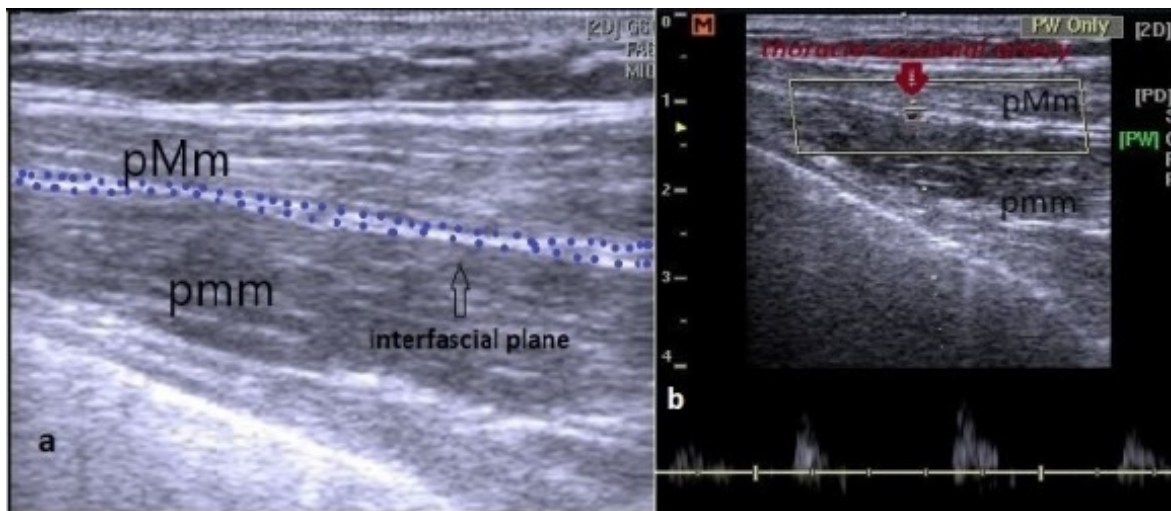
36 patients underwent combined US-guided PECS block and AV puncture were included. All routinely-recorded periprocedural parameters including clinical and demographic characteristics of patients, procedural medical administration (anesthetics, sedatives, analgesics etc.), procedure time (defined as the time from determining sonographic landmarks to the last skin suture), the time taken for both AV puncture and PECS block, postprocedural analgesic requirement, postprocedural pain score (measured by visual analogue pain scale), procedure-related complications (pneumothorax, hemothorax, arterial puncture, pocket hematoma, pocket infection, lead dislodgement, lead fracture, etc.) were collected and analysed to gather information regarding safety and efficacy of this new combined technique.

Results:

54 leads were placed in 36 patients. Combined procedure performed successfully in 35 (97,2%) patients without the need for fluoroscopy or venography. AV for each lead was achieved in a single attempt in 80,6% of cases. The time for both PECS block and AV puncture was 223,6±52.1 seconds, including the time to apply incision site anesthesia. Additional sedatives and/or local anesthetics were required in two patients during procedure. VAS average of the patients in the 1st, 6th, 24th hours were 3,7±1.14, 1,61±1,29 and 0,08±0,28 respectively. After procedure, 4 patients (3 of them woman) were needed analgesics. There was no any venous access-related complications.

Conclusions:

This new combined technique maintains both surgical and postoperative analgesia and prevents vascular access-related complications without significant increase on procedure time.



ID: 266

Topic: **Cardiology » Cardiac Pacing for Bradyarrhythmias**Presentation Type: **Oral****FIRMWARE UPDATE OF IMPLANTABLE CARDIAC PACEMAKERS IN ORDER TO AVOID CYBERSECURITY VULNERABILITIES**Kivanc Atilgan¹, Ertan Demirdas², **Cengiz Zafer Er**³¹*TOBB ETU Hospital, Ankara, Turkey*²*Gülhane Eğitim ve Araştırma Hastanesi, Ankara, Turkey*³*Bozok University, Yozgat, United States***Corresponding Author (kivancatilgan@gmail.com)**kivancatilgan@gmail.com, dr.ertandemirdas@gmail.com, erzafer2008@gmail.com***Abstract Text**

Objective: In terms of bad scenarios, the main question is which of the precautions should a practitioner take while updating the firmware of a cardiac pacemaker? And what can an exploitation of a cybersecurity vulnerability of a firmware of a cardiac pacemaker cause?

Methods: A firmware is a software helping the device to communicate with integral mechanical components and other devices. As the technology improves it does not only help us adjust medical devices without cables such as; cardiac pacemakers, which are wounded under the skin but also brings out the cybersecurity vulnerabilities. First on August 23 in 2017, Abbott released a planned upgrade to the firmware installed on certain implantable cardioverter defibrillator (ICD) or cardiac resynchronization therapy defibrillator (CRT-D) devices in order to improve performance and strengthen the security of these devices, which meant that 350000 patients had been affected, and a second firmware update was released on April 16, 2018. The question is what does it mean?

Conclusion: Among the technological devices in our routine life especially computer components a firmware update is a common and well-known process. With or without being concerned with technology, every one of us in our daily life encounter with some software updates for either of our cellphones, which have become a part of our upper extremities, or computers, internet modems etc. As these updates bring out many improvements to our devices such as increasing performance, patching cybersecurity vulnerabilities they may also harm the device even during or following the updating process leading to malfunction. What if this happens to a patient having a cardiac pacemaker? What could be the results of it?

Keywords: Firmware update, technology, cybersecurity vulnerability, implantable cardiac pacemaker

ID: 430

Topic: Cardiovascular Surgery » Medical and Surgical Treatment of Heart FailurePresentation Type: **Oral****ORTHOSTATIC SYNCOPE DUE TO GIANT LEAD VEGETATION****Doğan Kahraman***Gaziantep University Faculty of Medicine, Gaziantep, Turkey***Corresponding Author (drdogankahraman@gmail.com)**drdogankahraman@gmail.com***Abstract Text**

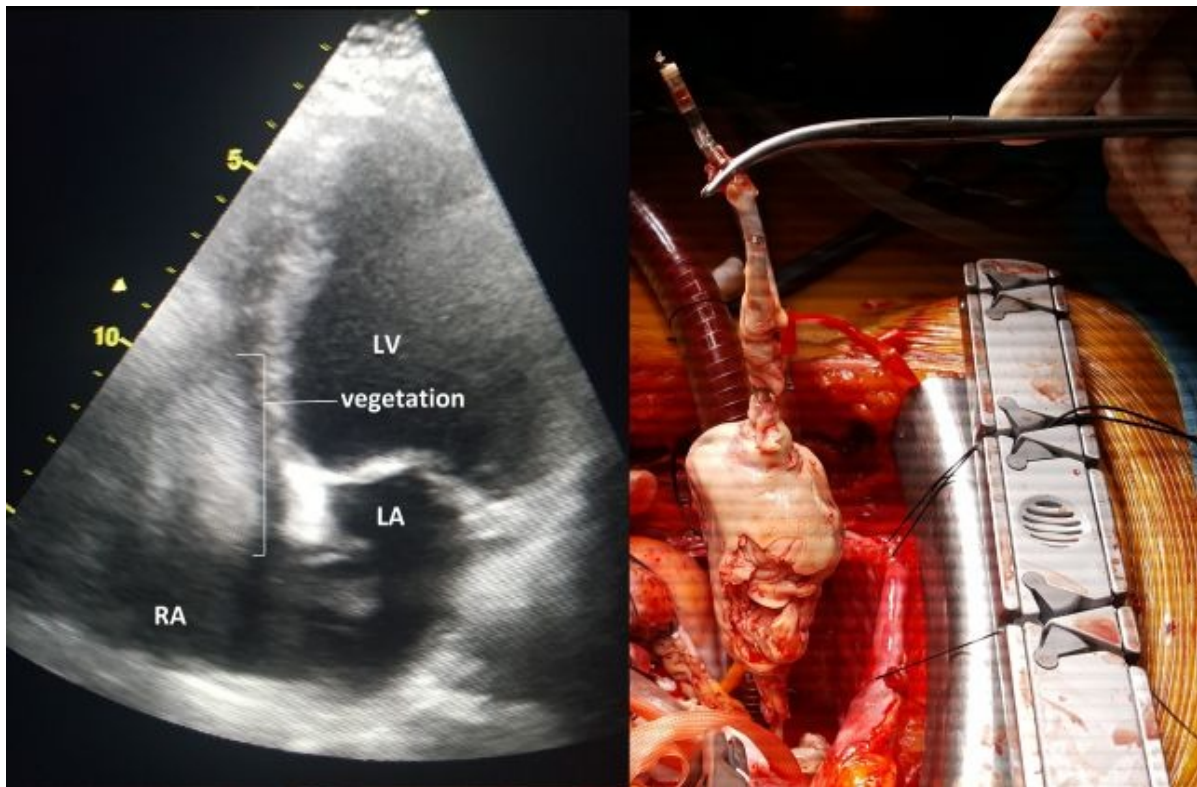
Background: Pacemaker lead infections are rare, and most related to pacemaker pocket. Lead related endocarditis accounts for 0,5-7%. Though giant vegetations are frequent findings of fungal endocarditis, we present a case of an *Enterococcus faecalis* lead infection with recurrent syncope attacks.

Case: An 55 years old male patient who had been implanted a cardiac resynchronization therapy device 3 years ago were seen for several attacks of orthostatic syncope. Her medical history revealed that he had been treated oral antibiotic therapy for the ventricular lead vegetation during the last 6 months. The patient had been hospitalized 4 times due to subfebril infection and she had been given the fibrinolytic treatment. Since the size of vegetation increased in time, surgical removal of the device had been proposed to the patient, she denied the surgery until syncope attacks. The syncope had been resolved every time she lied supine. After admission to the hospital, the transthoracic echocardiography showed a giant right atrial lead vegetation moving through the tricuspid annulus (Picture 1). The patient was on diuretic medication for cardiac insufficiency.

Results: The patient was operated to remove vegetation (Picture 1). The patients postoperative status was ordinary and she was discharged at 5th day following the operation. *Enterococcus faecalis* was cultivated from vegetation.

Discussion: The rate of the intracardiac device utilization and related infections has been rising over the past decades, and they are potentially life-threatening. Complete device and lead removal are recommended (class IA) in patients with definite infection. Those patients have a high prevalence of lead vegetations. Though percutaneous lead extraction techniques are generally safe and feasible in patients with small vegetations, the risk of massive, hemodynamically significant pulmonary embolism in those with large vegetations is usually prohibitive for the percutaneous techniques.

Most intracardiac device infections are caused by *Staphylococcus* species and are monomicrobial rather than polymicrobial. Device infections caused by *Enterococcus faecalis*, a Gram-positive facultative anaerobic bacillus, are rare. Giant lead vegetations are mostly seen with fungal infections. Symptoms related to endocarditis were expected rather than mass-related symptoms. We suggest that large atrial mass attached to the ventricular lead pretended as a plug to obstruct right ventricular inflow when the dehydrated patient stands up. She becomes conscious when she lied supine and the right atrial filling pressure increase to dilate the tricuspid annulus.



Picture 1: Preoperative echocardiography of the lead vegetation and its operative view.

ID: 113

Topic: **Cardiology » Arrhythmias and Antiarrhythmic Therapy**Presentation Type: **Oral****USEFULNESS OF PLATELET TO LYMPHOCYTE RATIO FOR
PREDICTING RECURRENCE OF ATRIAL FIBRILLATION AFTER
DIRECT CURRENT CARIOVERSION**Seçkin Dereli¹, Adil Bayramoğlu², Osman Can Yontar³¹*Ordu State Hospital, Ordu, Turkey*²*Ordu University, Ordu, Turkey*³*Samsun Training and Research Hospital, Samsun, Turkey***Corresponding Author (drseckindereli@gmail.com)**drseckindereli@gmail.com, dradil@yahoo.com, drcanyontar@gmail.com***Abstract Text**

Objective: Atrial fibrillation (AF) is the most common cardiac rhythm disorder with the associated risks of stroke and mortality. The usefulness of platelet to lymphocyte ratio (PLR), a recently described inflammatory marker, in predicting adverse cardiovascular events has been demonstrated in several studies. In the current study, we investigated the role of PLR in predicting recurrence after successful electrical cardioversion (ECV) in patients with non-valvular persistent AF.

Methods: A total of 287 patients with non-valvular persistent AF achieving restoration of the sinus rhythm after successful ECV were included in this study. At study entry, complete blood count, routine biochemistry tests, and transthoracic echocardiography (TTE) were performed routinely in all subjects. Patients were followed up for 6 months following the procedure and comparisons were performed between patients who recurred and who maintained the sinus rhythm (SR).

Results: At 6 months of follow-up, AF recurred in 108 patients, corresponding to a recurrence rate of 39%. Mean PLR values in the "AF recurrence group" (mean age 57.4 ± 12.0 years, 47.6% [n = 80] female) and in "SR maintenance" group (mean age 65.0 ± 9.4 years, 55.6% [n = 60] female) were 184.8 ± 44.2 and 103.3 ± 44.2 , respectively, with a significant difference between the two groups ($p < 0.001$). In multiple regression analyses, PLR emerged as a risk factor associated with AF recurrence during the 6-month follow-up period after successful ECV (odds ratio [OR]: 3.029 (1.013–9.055 95% confidence interval [CI]), $p = 0.047$). When a cutoff value of 147 was used, the sensitivity and specificity of PLR for predicting AF recurrence were 83.3% and 84.5%, respectively.

Conclusion: Elevated PLR is a marker of increased inflammation and may serve as a practical and inexpensive predictor for recurrence during 6 months of follow-up in patients with non-valvular persistent AF who had restoration of the sinus rhythm after successful ECV.

ID: 114

Topic: **Cardiology » Management of Atrial Fibrillation**Presentation Type: **Oral****EPICARDIAL FAT THICKNESS: A NEW PREDICTOR OF SUCCESSFUL ELECTRICAL CARDIOVERSION AND ATRIAL FIBRILLATION RECURRENCE**Seçkin Dereli¹, Adil Bayramoğlu², Sinan Cersit³, Mustafa Ozan Gürsoy⁴¹*Ordu State Hospital, Ordu, Turkey*²*Ordu University, Ordu, Turkey*³*Kartal Koşuyolu Research and Training Hospital, Istanbul, Turkey*⁴*İzmir Katip Çelebi University, İzmir, Turkey***Corresponding Author (drseckindereli@gmail.com)**drseckindereli@gmail.com, dradil@yahoo.com, drsinan@yahoo.com, drmustafa@yahoo.com***Abstract Text**

Objective: In recent years, epicardial fat tissue (EFT) has been found to be strongly associated with the development of atrial fibrillation (AF) and post-ablation long-term recurrence. The current study investigated the procedural success rate of electrical cardioversion (ECV) and potential predictors of treatment failure in patients with nonvalvular persistent AF.

Methods: A total of 262 nonvalvular persistent AF patients who were scheduled for elective ECV were included in this prospective study. Routine transthoracic echocardiography was performed before the procedure and EFT thickness was measured. The presence of left atrial appendage thrombus was evaluated by transesophageal echocardiography. The patients were followed up for 6 months to examine any recurrence after ECV.

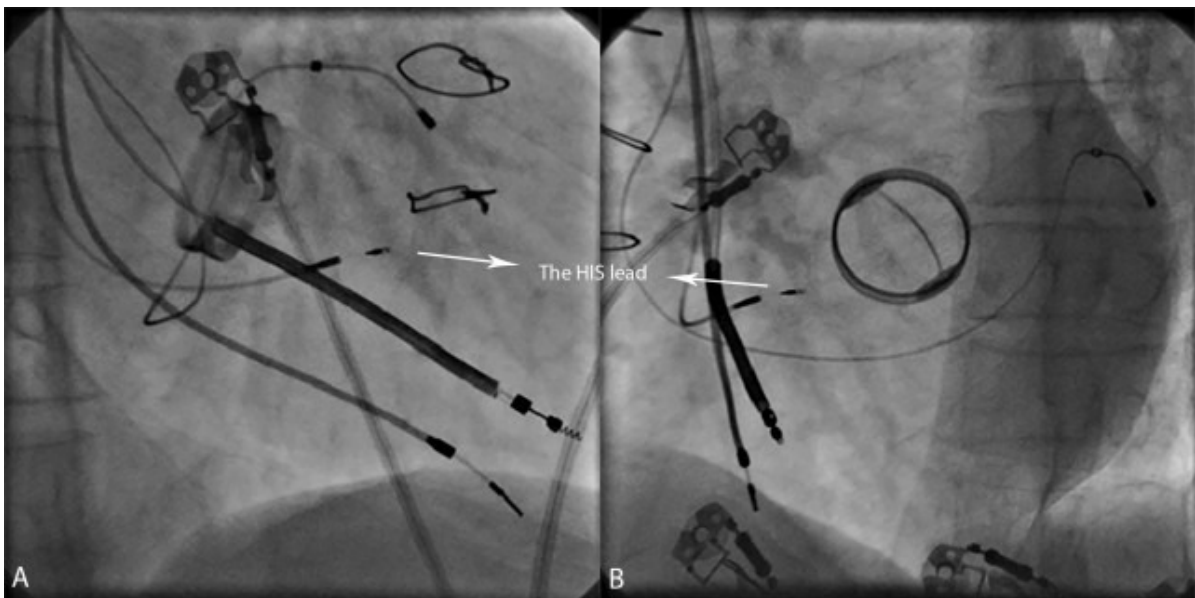
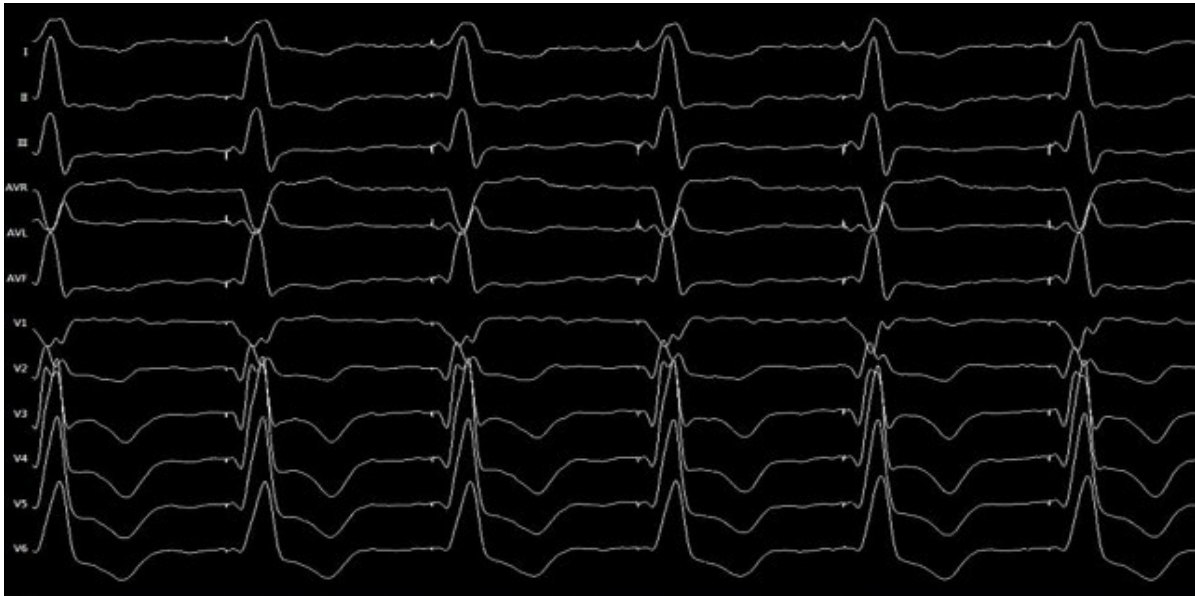Results: The success rate of ECV was 85% and the recurrence rate was 35% during the 6-month follow-up period. The mean EFT thickness was 8.67 ± 1.2 mm in the persistent AF group with unsuccessful ECV and 6.81 ± 0.8 in the patients in whom sinus rhythm (SR) was maintained, the EFT was significantly thicker in the AF group ($P = 0.001$). EFT ($P = 0.001$) and left ventricular end-diastolic diameters (LVEDD) ($P = 0.001$) were significantly different between those who had maintained SR and those with recurrent AF during the 6-month follow-up period after ECV. In the multiple logistic regression analysis, LVEDD (odds ratio [OR]: 1.320 (1.023–1.703 95% confidence interval [CI]), $P = 0.032$) and EFT [OR: 3.029 (1.013–9.055 95% CI), $P = 0.047$] were identified as independent predictors of successful ECV.

Conclusion: Epicardial fat tissue thickness can be effectively used for the prediction of successful ECV and AF recurrence during follow-up in AF patients.

ID: 190

Topic: **Cardiology » Cardiac Resynchronization Therapy**Presentation Type: **Oral****SWITCHING PACING FOR CARDIOMYOPATHY****Serkan Cay, Ozcan Ozeke, Firat Ozcan, Dursun Aras, Serkan Topaloglu***University of Health Sciences, Yuksek Ihtisas Heart-Education and Research Hospital, Ankara, Turkey***Corresponding Author (cayserkan@yahoo.com)**cayserkan@yahoo.com, ozcanozeke@gmail.com, doctorfiratozcan@gmail.com, drdaras@gmail.com, drtopaloglu@gmail.com***Abstract Text**

A 62-year-old female patient with non-ischemic cardiomyopathy (left ventricular ejection fraction, 25%), mechanical mitral prosthesis, atrial fibrillation, and single-chamber pacemaker implanted after the mitral procedure (complete pacemaker dependency) was referred to our arrhythmia center for cardiac resynchronization therapy (CRT) upgrade. Admission ECG showed pure right ventricular (RV) apical pacing configuration with underlying atrial fibrillation. An upgrade procedure with a different approach was performed. A 4.1F lumenless active-fixation lead (SelectSecure™, Medtronic, Inc.) was implanted using a C315-HIS delivery catheter (Medtronic, Inc.). Pace mapping was used to determine the most appropriate region of implantation. The implantation region was just beneath the HIS bundle due to infra-His complete block. Unipolar pacing from that site resulted in non-selective HIS bundle pacing with good pacing parameter (capture threshold, 0.75V@1ms). No baseline R-wave amplitude was present due to complete pacemaker dependency. Surface ECG showed narrowed QRS complexes with non-selective HIS pacing characteristics (Figure 1). An RV single-coil active-fixation lead was implanted in the RV apex. A left ventricular (LV) passive lead was implanted in the basal lateral branch of the coronary sinus (Figure 2). The HIS lead, RV lead and the LV lead were connected to the right atrial (RA) port, RV port and the LV port, respectively. The pulse generator was programmed to dual-chamber mode with pacing in the RA port and sensing in the RV port without LV port activation. The paced atrio-ventricular delay was set to 100 ms to avoid unnecessary RV pacing without compromising RV back-up pacing in the case of dislocation or abrupt increase of the capture threshold in the HIS lead. Single-chamber biventricular pacing configuration was also tested using RA port off. Surface ECG showed narrowed QRS complexes with biventricular pacing pattern. If clinical and imaging follow-ups show improvement, HIS pacing configuration with LV port off will continue. However, if no improvement will be detected, the pacing configuration will be switched to biventricular pacing with RA port off.



ID: 176

Topic: **Cardiology » Cardiac Pacing for Bradyarrhythmias**Presentation Type: **Oral****UNEXPECTED CYANOSIS AFTER PACEMAKER IMPLANTATION:
METHEMOGLOBINEMIA DUE TO LOCAL ANESTHESIA****Kardelen Ohtaroglu Tokdil, Deniz Mutlu, Hasan Tokdil, Eser Durmaz, Baris Ikitimur, Bilgehan Karadag, Zeki Ongen***Cerrahpasa Medical Faculty, Istanbul, Turkey***Corresponding Author (kardelenohtaroglu@gmail.com)**kardelenohtaroglu@gmail.com, deniz.mutlu92@gmail.com, hasantokdil@gmail.com, durmazeser@hotmail.com, ikitimur@gmail.com, karadag@istanbul.edu.tr, z_ongen@yahoo.com.tr***Abstract Text**

Case: An 82-year-old female was admitted with symptomatic third degree AV block. After implantation of a transvenous temporary pacemaker, permanent DDD pacemaker implantation was planned.

20 ml of prilocaine was administered subcutaneously to induce local anesthesia at the left pectoral region. The implant was carried out uneventfully. About 30 minutes after the procedure, perioral cyanosis and slight hypoxia on pulse oximetry (SpO₂: 88-90%) was detected during routine examination of the asymptomatic patient in the cardiology ward. Further physical examination revealed clear lung fields with no evidence of pneumothorax, however tachypnea was noted. Bedside echocardiography was performed to rule out pericardial tamponade revealing no fluid in pericardial cavity and a left ventricular ejection fraction of 55%, with no findings suggestive of dilatation of right heart chambers. Blood drawn for arterial blood gas analysis (ABG) was noted to be of very dark brown color raising suspicion of methemoglobinemia. ABG showed pH=7.44, pO₂:104 mmHg, pCO₂:26.3 mmHg, Lactate:0.9 mmol/L, Methemoglobin:19%. Local anesthesia induced methemoglobinemia was thought as the primary diagnosis.

Methylene Blue was not applied since methemoglobin level was <20% and there were no additional pathological signs and hemodynamic compromise. 500 mg Ascorbic Acid was given intravenously every 6 hours for 3 days. Twice daily control ABG analyses showed methemoglobin levels to decrease gradually (19%>14%>9.5%>6.2%>2.1%). Her perioral cyanosis was completely resolved five hours after the first IV ascorbate dose.

Discussion: In healthy individuals, methemoglobin levels are <2% due to the cytochrome b5 reductase enzyme system. The o-toluidine metabolite of prilocaine has been previously reported to cause methemoglobinemia 20-60 minutes after application in susceptible individuals, a risk known to be dose dependent. When methemoglobin levels are <20%, offending medication should be withdrawn if applicable, which may actually be enough for resolution of symptoms. In methemoglobin levels exceeding 20%, methylene blue, as well as vitamin C (ascorbic acid), which is usually more readily accessible albeit acting more slowly, may be utilized. Methemoglobinemia may complicate any cardiovascular procedure in which local anesthesia is required by agents like prilocaine, including oropharyngeal administration in trans-esophageal echocardiography procedures. Previous knowledge of the condition as well as appropriate therapeutic interventions is essential to tackle this rare complication of invasive procedures.

Oral Presentations**Interventional Strategies in Peripheral Arterial Disease**

Date: 30.03.2019 Time: 13:30 - 15:00 Hall: 5

ID: 263**Topic: Cardiology » Interventions for Peripheral Arterial Diseases****Presentation Type: Oral****PERIPHERAL ARTERIAL INJURIES AFTER ANGIOGRAPHY****Ümit Arslan**, Eyüpserhat Çalık, Yahya Ünlü*Ataturk University, Erzurum, Turkey***Corresponding Author (kvcumit@gmail.com)**kvcumit@gmail.com, eyupserhatcalik@hotmail.com, yahyaunlu@hotmail.com***Abstract Text**

BACKGROUND: We aim to determine the incidence of vascular complications following angiography and to introduce our therapeutic approach at this study.

METHODS: Between 2000 – 2018 angiography was performed to 38245 patients. Surgical intervention was applied to 342 (0.9 %) patients with vascular injury due to complications of angiography.

The study included 342 patients (male/female, 187/155) with mean age of 62.5 (min-max: 18-92) Femoral artery pseudoaneurysm were seen in 237 (69.3%) patients, femoral artery emboli in 34 (9.9%), hematoma of the femoral area in 21 (6.1%), brachial artery pseudoaneurysm in 17 (4.9%), foreign body in 11 (3.2%), brachial emboli in 9 (2.6%), radial artery thrombosis in 8 (2.3%) and perforation of common iliac artery in 5 (1.5%).

RESULTS: Pseudoaneurysms were repaired primary sutured in the greatest majority of the patients. Embolectomy was performed in 54 patients. Saphenous graft interposition at the radial artery was performed in 5 patients. Aorta- Iliac graft bypass was performed in 5 patient because of iliac rupture. The foreign bodies were subtracted and repaired femoral artery in 11 patients. Hematoma was emptied in 21 patients. Reoperation was necessary in 5 cases. Infection of surgical wound in the femoral area was treated in 27 patients, and plastic surgery was needed in 9. Three patients (0.9%) were died. Death was occurred because of cardiac failure in two and septic shock in one.

CONCLUSIONS: Vascular complications after angiography are rare but, it has increased the morbidity and cost of treatment, as well as prolonged duration of hospital stay

ID: 240**Topic: Cardiology » Peripheral Arterial Diseases**

Presentation Type: **Oral**

CRUSH IMPLANTATIONS OF COVERED BALLOON EXPANDABLE STENT AND SELF-EXPANDING STENT OVER A SUBINTIMALLY RECANALIZED STENT IN A TASC D LESION OF THE SUPERFICIAL FEMORAL ARTERY AFTER FAILED FEMOROPOPLITEAL BYPASS GRAFTING

Lütfi Öcal, Sinan Cerşit

Kartal Koşuyolu heart training and research hospital, istanbul, Turkey

**Corresponding Author (lutfiocal@hotmail.com)*

lutfiocal@hotmail.com, sinancersit@hotmail.com

Abstract Text

Relevant clinical history and physical exam: A 60 years old male patient has the risk factors of hypertension and dyslipidemia for many years. He had right superficial femoral artery (SFA) occlusion and underwent stent implantations and femoro-popliteal bypass surgery 3 years ago. He had resting pain for 3 weeks. Under the diagnosed of CLI, he admitted for further evaluation and treatment.

Relevant test results prior to catheterization: ABI: right leg 0.5; left leg 0.8 Relevant catheterization FINDINGS: The right limbs angiography showed totally occlusion of vein-graft bypass from SFA to popliteal artery and in-stent occlusions of SFA.

[Interventional Management]Procedural step: After left femoral artery puncture, A 6 Fr guiding catheter (Sheath less PV) was inserted and crossed over to right common femoral artery. We crossed the occlusion lesion using 0.035-inch stiffness wire with microcatheter and noticed that wire passing through the subintimal space after dilated and crushed the total occlusion part of previously implanted self expanding stent with standart peripheral balloon, inflated to 6-8atm. Despite crushing of the stent with a series of increasingly sized standard balloons, a significant recoil remained in the area of the crushed stent. To secure patency of the femoropopliteal artery and to crush powerfully previously implanted stent, we therefore decided to implant firstly Atrium Advanta V12 covered balloon expandable stent 7.0x59mm and then Epic self-expanding nitinol stent 6.0x100mm was deployed due to providing higher radial strength to be patent covered balloon expandable stent and to resist crushed self expanding stent. Good patency was achieved in right SFA. Case Summary: This 60 years old male patient admitted due to resting pain for 3 weeks. The angiography showed totally occlusion of vein-graft bypass from SFA to popliteal artery and in-stent occlusions of SFA. A 6 Fr guiding catheter (Sheath less PV) was inserted and crossed over to right common femoral artery. We crossed the occlusion lesion using 0.035 -inch stiffness wire with microcatheter and noticed that wire passing through the subintimal space after dilated and crushed the total occlusion part of previously implanted self expanding stent with standart peripheral balloon, inflated to 6-8atm. To secure patency of the femoropopliteal artery and to crush powerfully previously implanted stent, we therefore decided to implant firstly Atrium Advanta V12 covered balloon expandable stent 7.0x59mm and then Epic self-expanding nitinol stent 6.0x100mm was deployed due to providing higher radial strength to be patent covered balloon expandable stent and to resist crushed self expanding stent. Good patency was achieved in right SFA.

ID: 7

Topic: **Cardiology » Peripheral Arterial Diseases**Presentation Type: **Oral****PARAPLEGIA AFTER PERCUTANEOUS ILIAC STENTING: HOW DID THAT HAPPEN?****Emre Özdemir***Katip Celebi University, Atatürk Education and Research Hospital, Izmir, Turkey***Corresponding Author (emreozdemir27@yahoo.com.tr)**emreozdemir27@yahoo.com.tr***Abstract Text**

Paraplegia after abdominal aortic or iliac processes is rare, and unpredictable complication. It is frequently due to the spinal cord ischemia (SCI). SCI carries a high rate of morbidity. The main cause of SCI-associated paraplegia is an intervention or surgery with the presence of atherosclerosis.

Aortic cross-clamping during endovascular or surgical treatment of abdominal aortic aneurysm may be the one of the mechanism for SCI. But percutaneous interventions to iliac arteries may cause too much rarely to SCI.

We presented a case that suffered with paraplegia after percutaneous iliac stenting, and we will discuss potential aetiological factors with this case.

68-year-old male patient with known coronary by-pass applied to the cardiology with claudication. Peripheral angiography performed and total occlusion of right main iliac artery, and 90% lesion on left iliac artery was found. A retrograde pass was succeed with a puncture through the collaterally filling of right femoral artery and right iliac stenting was performed successfully . One week later , retrograde left femoral arterial access was planned but could not get pulse of left femoral artery. After right femoral artery puncture, peripheral angiography performed and seen that right iliac stent was patent but left iliac 90% lesion became a total occlusion. Left iliac total lesion could not be passed with different catheter back-up from antegradely via right femoral artery approach and retrograde approach with a puncture through the collaterally filling of left femoral artery was also failed. For a better back-up via right femoral arterial approach was engaged to left main iliac artery by Agilis Introducer. Total occlusion was successfully passed. Superficial femoral artery angioplasty was performed with SeQuent® Please drug coating balloon and main iliac artery was stented via 10mmx 90cm VascuFlex® Peripheral self-expanding stent. Twenty minutes after the patient was taken to his bed, patient suffered from pain, motor and sensory deficit on his left leg. Left femoral, popliteal and dorsalis pedis arteries pulses could not been sense. Control peripheral angiography performed and left iliac stent was seen as thrombosed. Balloon dilatation was performed and distal arterial blood flow was achieved. Intravenous heparin and ilomedin infusion were started. Also acetyl salicylic acid + clopidogrel + statin were continued. In the intensive care unit follow-up, patient was suffering from paraplegia without any distal arterial pulse deficit. After a neurology consultation, there was no cerebral pathology. On the follow-up, patient got hemodialysis for 4 times due to contrast induced nephropathy. There were high T2 signals in spinal MRI. Due to this, methylprednisolone 4mg started to prevent potential spinal cord injury. On the fifth day after event, EMG detected bilateral lower limb motor deficit was found that was thought a spinal cord injury. We seen no spinal arterial variability but diffuse atherosclerosis on thoraco-lomber CTA. After 20 days of physiotherapy, motor functions were healed nearly to totally on the right leg but the left side continued as a monoparesis.

Paraplegia not expected as a catastrophic complication after percutaneous Iliac angioplasty. But it should not be forgotten that such a complication may be caused by the change of spinal blood flow in patients with diffuse atherosclerosis. In the post-procedural period, any sensory or motor impairment or unexpected incontinence must bring to mind a SCI.

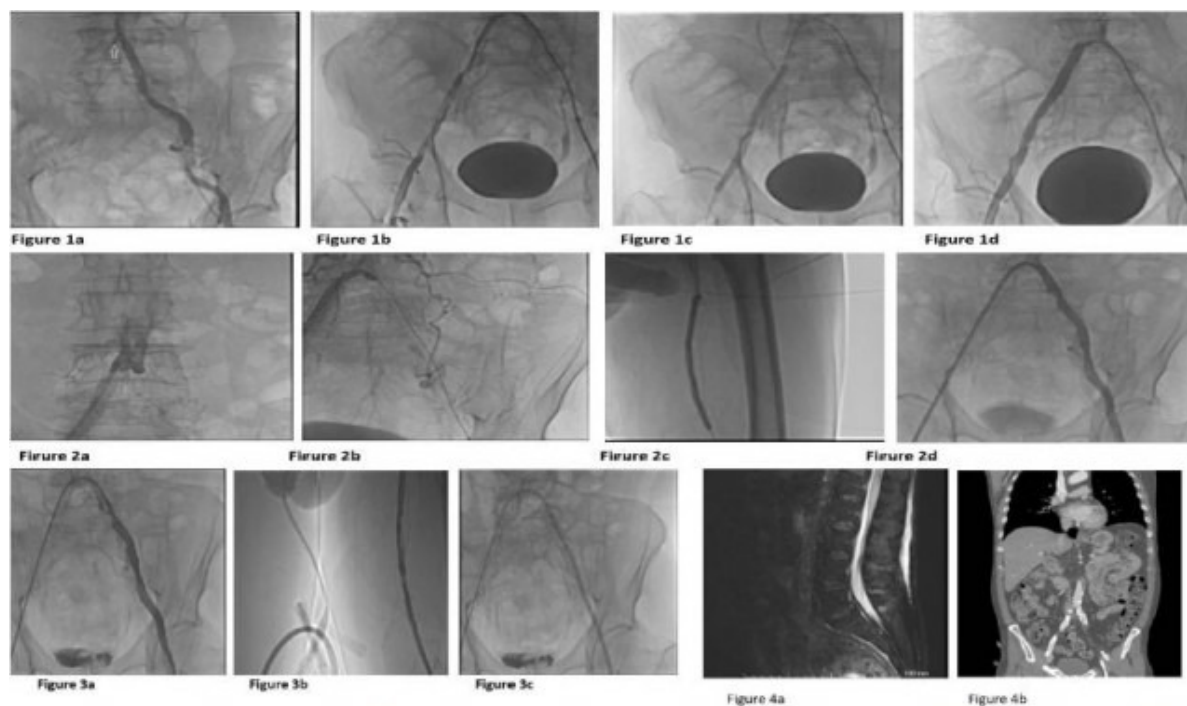


Figure 1a: The white arrow shows the right main iliac total occlusion segment. 1b: Occlusion was passed with 0.035 guide-wire. 1c: after balloon angioplasty to occlusion segment, 1d: stent was implanted and blood flow was provided
 Figure 2a: Left main iliac was total occluded, 2b: Total occlusion was passed with 0.035 guide-wire via Agilis™ Steerable Introducer back-up, 2c: after balloon angioplasty to occlusion segment, 2d: stent was implanted and blood flow was provided with a non-critical residue.
 Figure 3a: proximal stent proximal thrombosis that was separated after wire was passed, 3b: There was also thrombosis in distal femoral artery, 3c: balloon angioplasty was repeated.
 Figure 4a: MRI showed high T2 signals in the spinal cord, 4b: CT showed diffus atherosclerosis on thoraco-lomber aorta.

ID: 151

Topic: Cardiology » Interventions for Peripheral Arterial Diseases

Presentation Type: Oral

SUCCESSFUL PERCUTANEOUS TREATMENT OF A TOTAL LEFT SUBCLAVIAN VEIN OCCLUSION DUE TO PREVIOUS DIALYSIS CATHETER IMPLANTATION ATTEMPT

Elton Soydan, Mustafa Akın

Ege University, Izmir, Turkey

*Corresponding Author (eltonsoydan@hotmail.com)

eltonsoydan@hotmail.com, drmustafaakin35@gmail.com

Abstract Text

An 80 years old male patient was referred to our clinic with left arm swollness and pain. He had been experiencing these complains for 1 week and had had some antibiotic therapy with no result. His medical history consisted of morbid obesity (Body mass index 40) chronic kidney disease due to hypertension and diabetes with regular hemodialysis for 3 years and some unsuccessful attempts of implantation of hemodialysis catheter on the left Subclavian vein. He had had hemodialysis from his left brachial arterio- venous fistula (AVF) for 1 year on, but unfortunately he had experienced problems with the fistula not working properly with suboptimal hemodialysis procedure during the last week. On admission he looked pale; felt itching like pain on his left swollen arm. Peripheral pulses were normally palpated. Electrocardiography showed a normal sinus rhythm with a heart rate of 90 bpm. Left arm Doppler ultrasonography showed normal Doppler parameters in the arterial system, in contrast there was a profound turbulence of blood flow in the left brachial AVF location and emerging thrombus formation in the upstream Axillary vein with ignorant outflow velocity parameters implying a near occlusion in the Subclavian vein circulation (Figure 1).

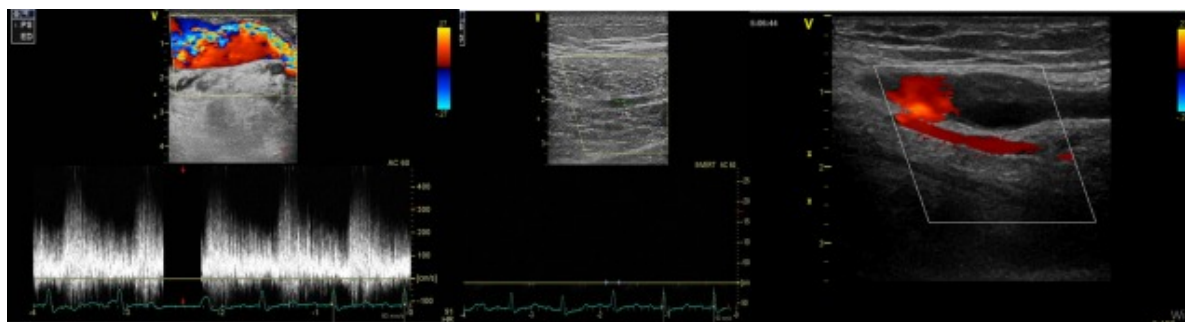

Figure 1: From left to right: Profound turbulence of blood flow in the left brachial AVF; No blood outflow implying occlusion in the left Subclavian Vein; Thrombus formation in the left Axillary vein.

Broad spectrum antibiotic therapy with arm elevation and proper dressing with Eau de Goulard solution was administered. After slight relieving of pain and swelling, a venous angiography was performed through a right femoral vein approach and a total occlusion of the left Subclavian vein was revealed (Video 1). Total occlusion was crossed through a supporting microcatheter (Trailblazer) and multiple coronary balloon (4*20mm) predilatations were performed. Venous angiography showed thrombus formation in the valve location of the axillary vein and straight line dissection in the left Subclavian vein. Catheter directed thrombolysis was decided and a pigtail catheter was inserted into the left Axillary vein through which a low dose of 10 mg t-PA infusion for 15 hours (1mg for 5 hours, 0,5mg for 10 hours) was administered. After 15 hours of t-PA infusion, astonishingly the swelling of the patient arm was diminished and pain complain recovered at all (Figure 2).

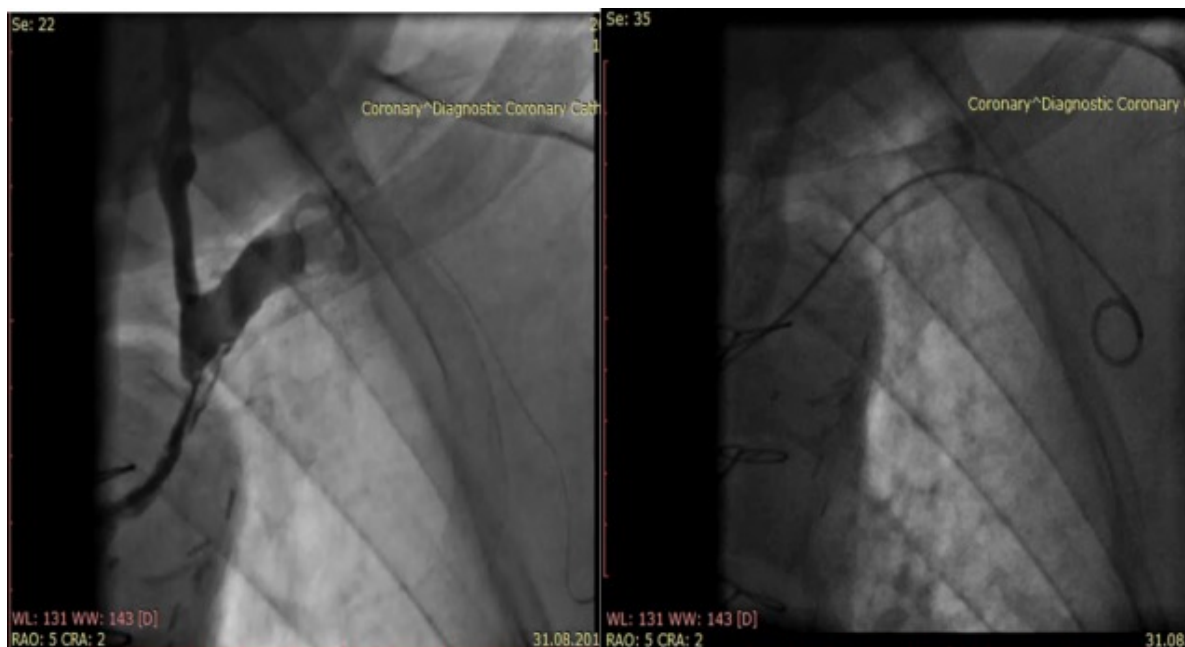


Figure 2. From left to right: Selective venous angiography depicting thrombus formation in the Axillary vein and dissection in the Subclavian vein; Catheter directed thrombolysis through pigtail catheter insertion into the left Axillary vein.

Selective vein angiography was performed by a right Judkins 4 catheter revealing no thrombus sequelae and residual stenosis in the left Subclavian vein. A peripheral self- expandable stent (7*60 mm) was successfully implanted and a good blood outflow was restored(Video 2). Patient clinical scenario showed a dramatical immediate recovery after the stenting procedure and hemodialysis went on normally through the brachial AVF.

ID: 170

Topic: **Cardiology » Interventions for Peripheral Arterial Diseases**Presentation Type: **Oral****SUCCESSFUL PERCUTANEOUS INTERVENTION OF AN OCTOGENAREAN PATIENT WITH LERICHE SYNDROME**

Elton Soydan, Mustafa Akın

*Ege University, Izmir, Turkey***Corresponding Author (eltonsoydan@hotmail.com)**eltonsoydan@hotmail.com, drmustafaakin35@gmail.com***Abstract Text**

An 86 years old female patient was admitted to our clinic with buttock pain and severe pain in both legs. She had been experiencing these complains for 1 month and that the legs pain severity had increased the last week. Her medical history consisted of coronary artery bypass, hypertension hyperlipidemia and diabetes. She had an optimal medication including antihypertensive, statin, aspirin, oral antidiabetics and her blood pressure and diabetes situation was under control. Physical examination showed nonpalpable bilateral femoral pulses with thinned legs and a profound paleness. Electrocardiography showed a sinus tachycardia with a heart rate of 100/bpm. There were no remarkable signs in the cardiorespiratory system examination. Echocardiography showed a preserved left ventricle ejection fraction with no valvular dysfunction. Doppler arterial ultrasonography of the lower extremities showed bilateral severe stenotic atherosclerotic lesions in the aortoiliac bifurcation reflecting a Leriche syndrome ultrasonography phenotype. This was verified by infrarenal aortic angiography through a 6 French Pigtail catheter advanced from the left distal radial artery (Figure 1; Video 1).

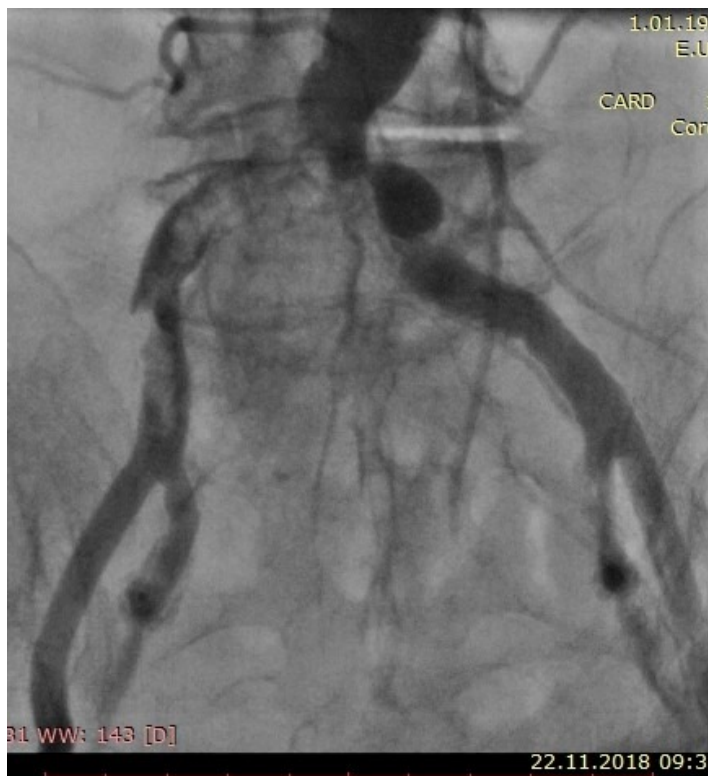

Figure 1: Peripheral angiography showing severe distal Aortic-iliac disease.

Due to the advanced age and comorbidities a percutaneous intervention was decided. Bilateral femoral arteries were engaged with 7 French femoral sheath through which two hydrophilic Terumo guidewires of 0,35 inches were advanced and crossed the lesions falling into the abdominal aorta. Peripheral Balloons of 6*40 mm sizes were simultaneously dilated at the stenotic lesions area. Residual stenosis was successfully resolved by simultaneously implantation of peripheral self-expanding stents (right 10*80 mm; left 10*60 mm) (Figure 2).

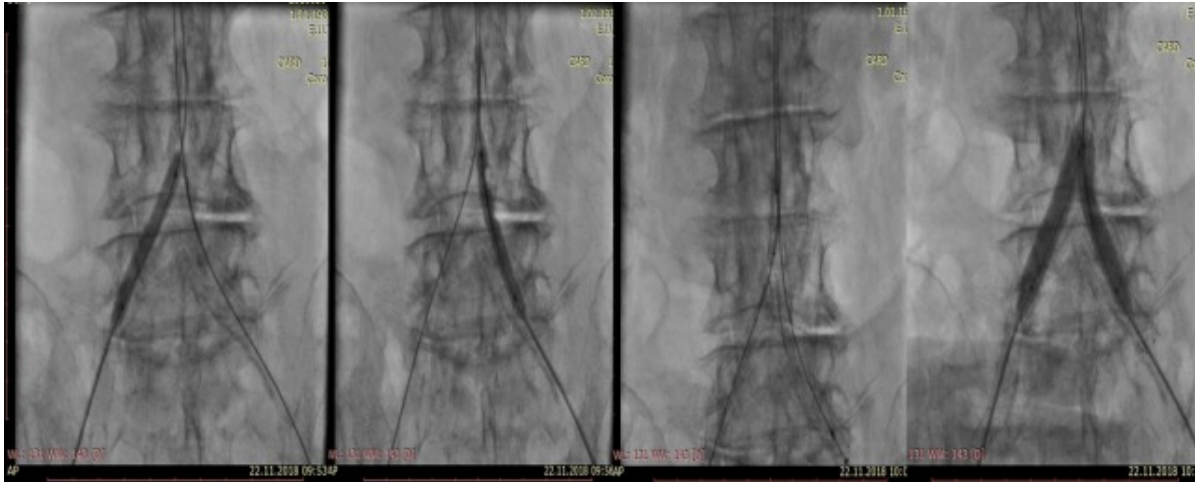

Figure 2: Bilateral balloon predilatation of both of the common Iliac arteries; simultaneous implantation of two self -expandable peripheral stents with final kissing balloon postdilatation.

Percutaneous intervention was successfully contemplated by final balloon kissing procedure and an optimal blood flow with no vascular complications was restored (Video 2).

ID: 173

Topic: **Cardiology » Interventions for Peripheral Arterial Diseases**

Presentation Type: **Oral**

PERCUTANEOUS TREATMENT OF A DISSECTED MISDIAGNOSED SYMPTOMATIC CAROTID ARTERY DISEASE

Elton Soydan, Mustafa Akin

Ege University, Izmir, Turkey

**Corresponding Author (eltonsoydan@hotmail.com)*

eltonsoydan@hotmail.com, drmustafaakin35@gmail.com

Abstract Text

An 80 years old male patient was referred to our clinic with intermittent syncope episodes. He had been experiencing syncope during routine daily activities lasting for a few minutes with no extra neurologic deficit for one month. One week before admission he had a suddenly visual neglect that caused falling down the road and got injured (multiple bruises and abrasions over the hands and face). He were taken by an ambulance and examined in another hospital in which no pathologic causes were found. On admission patient was frightened, trying to convince us that there was something happening with his brain. His medical history consisted of hypertension, coronary artery bypass surgery. On physical examination blood pressure was in normal range (130/80 mmHg), there were no neurological deficit and no lateralization signs. Interestingly we heard a low pitched murmur over the right carotid artery area. Cardiorespiratory system was unremarkable. He did not describe any palpitation or chest pain in the past before or after the syncope episodes. Electrocardiography showed a normal sinus rhythm with no ischemic changes and a heart rate of 70/bpm. There was a preserved left ventricle ejection fraction (60%) with no severe valvular dysfunction in transthoracic echocardiography. A 24 hours rhythm holter recording resulted in no pathologic brady or tachyarrhythmia related with the patient complains. Orthostatic hypotension was assessed by the Tilting test with no abnormal blood pressure and heart rate response. Biochemical blood tests showed normal cardiac biomarkers with an efficient Hemoglobin level of 14 g/dl with no electrolyte imbalance and normal Glomerular Filtration rate. Carotid artery Doppler ultrasonography showed diffuse atherosclerotic plaques in the left extra cranial Carotid artery system. Astonishingly there was flep- like dissected segment of the right internal carotid artery surrounded by intensive calcified (hyper echogenic) atherosclerotic plaque but with no high peak systolic flow (120cm/sec) originating from the Bulbus segment (Figure 1). Cranial computed tomography revealed some ischemic changes in the the right cerebral hemisphere, the sign of which was verified by the Neurologic department as an outcome of right dissected internal carotid artery and the patient was assessed as symptomatic. The patient clinical scenario was evaluated in our hospital council made by Cardiology, Neurology, Radiology and Cardiovascular Surgery departments and a percutaneous treatment with stent implantation was decided as the best accurate management. After approved consent, the patient was delivered to angiography laboratory. An 8 French femoral sheath was inserted into the right femoral artery by which an 8 French right Judkins (4 cm) guiding catheter was advanced and selective carotid angiography revealed the severe dissection of the right internal carotid artery (Figure 2; Video 1).

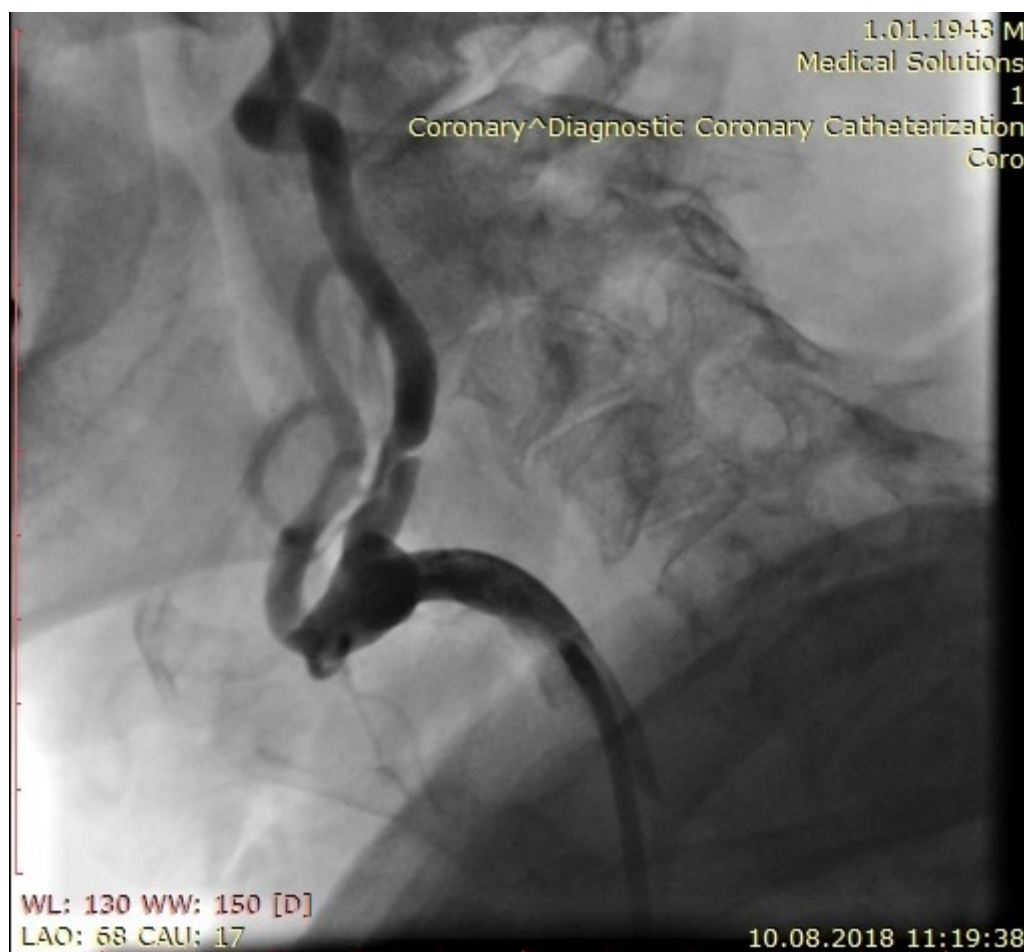

Figure 2: Dissected internal carotid artery.

After successful advancement of the distal embolic protection device (Spider FX 5mm) a direct stent strategy was decided and an (8*6*30 mm) open cell self-expanding conic shaped stent (Protege EV 3) was successfully implanted and totally covered the dissected segment of the right internal carotid artery. Final selective carotid angiography showed an optimal blood flow through the internal carotid artery with no residual plaque or dissection (Video 2). Patient was discharged with dual antiplatelet therapy in a healthy condition.

ID: 185

Topic: Cardiology » Interventions for Peripheral Arterial Diseases

Presentation Type: Oral

SUCCESSFUL PERCUTANEOUS TREATMENT OF ACUTE DEEP VEIN THROMBOSIS WITH MECHANIC THROMBECTOMY (ANGIOJET CATHETER SYSTEM) AND STENT IMPLANTATION

Elton Soydan, Mustafa Akin

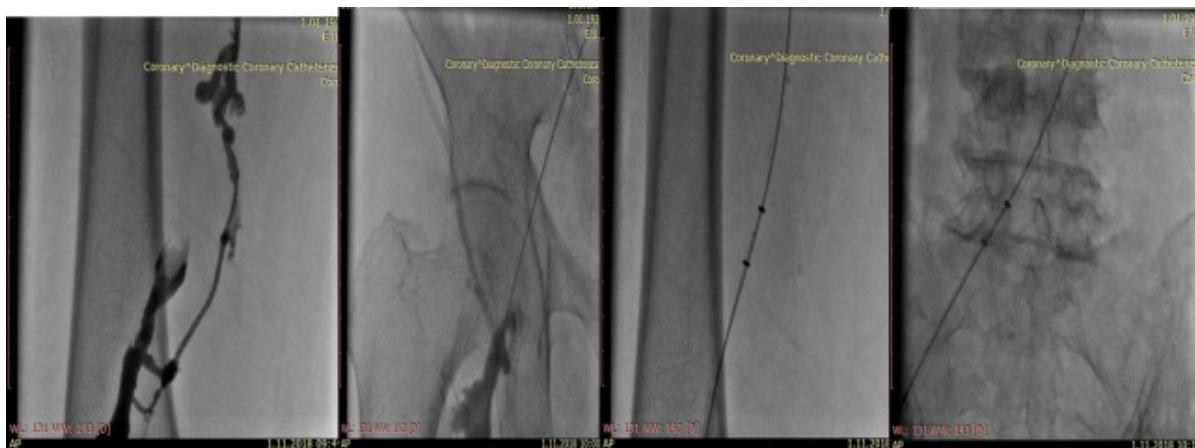
Ege University, Izmir, Turkey

*Corresponding Author (eltonsoydan@hotmail.com)

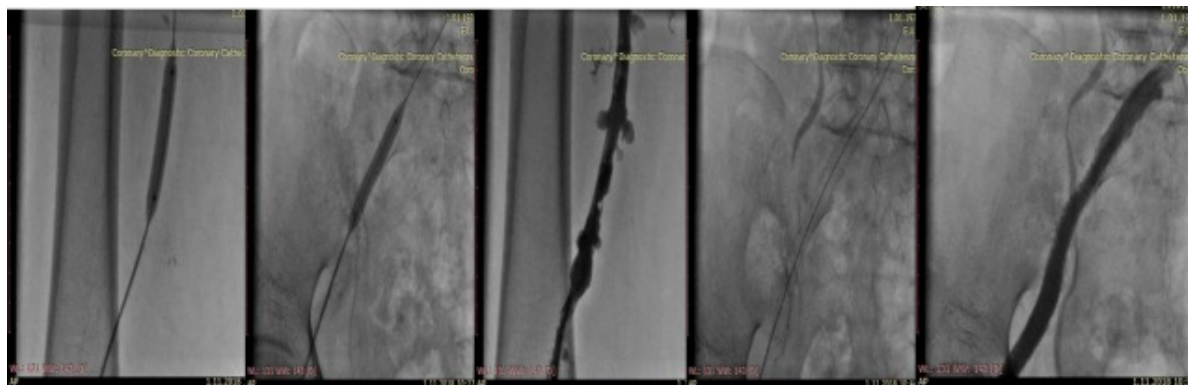
eltonsoydan@hotmail.com, drmustafaakin35@gmail.com

Abstract Text

An 87 years old female patient was referred to our clinic with sudden onset of left leg pain and continuous swelling in the last week. She described pain all over her leg with no possible movement at all. She was transferred by ambulance because of impossible standing on her own feet. The patient denied dyspnea, chest pain and syncope. Her medical history consisted of hypertension that was under control with antihypertensive drugs. She described a common cold last week that made her very weak and spent all the week lying in the bed without any other daily activities. On admission her left leg was prominently swollen, with red colorization and severe pain on gentle palpations. Peripheral arterial pulses were normally palpated. The other leg was in normal diameter with no abnormal characteristics. Blood pressure was in normal range (130/80 mmHg) with a sub febrile fever (37,5°C). Doppler ultrasonography of the lower extremities showed normal arterial Doppler flow parameters, in contrast profound thrombus formation originating from the proximal part of the left popliteal vein was recognized. Thrombus was extended upstream to the left common iliac vein causing total occlusion there. Biochemical tests resulted in efficient Hemoglobin level (13 g/dl) high D-dimer (1000 ng/mL), normal cardiac troponin I, high C-reactive Protein (5 mg/L) and normal renal functions (GFR 60 ml /min/1.73m²). Electrocardiography showed a normal sinus rhythm with a heart rate of 80 bpm. Echocardiography revealed a normal right ventricle chamber with no dilatation and with preserved systolic function. Systolic pulmonary artery pressure was measured as 25 mmHg and no additional structural pathologies were noticed. Immediate anticoagulation with Enoxaparin (6000 Units two times a day sc.) and appropriate antibiotic regimen was begun. The patient left leg was elevated and adequately dressed with Eau De Goulard solution. After 5 days of stricted bed rest and intense treatment with anticoagulation and antibiotics, infectious markers and the swelling were decreased. In contrast D-Dimer was found consistently increasing and the Doppler ultrasonography verified this by describing the continuous presence of the thrombus in the left common iliac vein. The patient was then transferred to the angiography laboratory for diagnosis and intervention purposes. After the patient was turned upside down an 8 French sheath was inserted with the assistance of a portable echo device into the left popliteal vein. Venous angiography showed total occlusion in the distal part of the femoral vein (Video 1). After advancing 0,35 inch Terumo guidewire we performed mechanical thrombectomy with the AngioJet (Zolante DVT) catheter system (Figure 1).



Angiography showed an astonishing restoring of blood flow in the vein but with total occlusion the left common iliac vein. Mechanical thrombectomy was applied into the iliac vein multiple balloon inflation (7*40 mm) but with not an optimal result. In order to provide patency of the vessel we successfully implanted 2 self-expandable stents (8*100; 8*80 mm) and with post dilatation inside the stented segment resulted in an optimal patency of the left common iliac vein (Figure 2).



Final angiography resulted in an opened upstream vein circulation (Video 2). Patient experienced a dramatic recovery and the left leg turned to normal shape and size with no pain at all. Patient was discharged on anticoagulation and varice socks.

ID: 23

Topic: **Cardiology » Peripheral Arterial Diseases**

Presentation Type: **Oral**

CORRELATION BETWEEN PLATELET INDICES AND SEVERITY OF PERIPHERAL VASCULAR DISEASE

Seçkin Satılmış

Acibadem Mehmet Ali Aydınlar University - Atakent Hospital, ISTANBUL, Turkey

**Corresponding Author (drseckin50@gmail.com)*

drseckin50@gmail.com

Abstract Text

BACKGROUND AND AIM: Platelets play a major role in the atherothrombosis and atherosclerosis. Platelet indices, particularly mean platelet volume (MPV), platelet distribution width (PDW) and plateletcrit (PCT) was associated with presence of coronary heart disease which was demonstrated with numerous studies. Platelet indices are also associated with extent of coronary vascular disease. On contrary, clinical importance of the platelet indices as a prognostic biomarker in the peripheral vascular disease (PVD) was not reported extensively. Herein, we aimed to show the correlation between platelet indices and severity of PVD in term of angiographic evaluation.

METHODS: A total of 117 subsequent patients who underwent peripheral lower extremity angiography were evaluated retrospectively. Upon admission, platelet indices was measured with automated complete blood count. Severity of the PVD was evaluated according to TASC-II classification. TASC-II A-B lesion was defined as simple PVD and TASC-II C-D lesion was defined as pravelent and complex PVD. Then, both groups compared statistically according to clinical, laboratory and demographic features including MPV, PDW and PCT levels.

RESULTS: The mean age was $58,5\pm 11$ with male predominance. On the 49,6 % of the patients, TASC-II C-D lesions were observed. Advanced age, male gender, body mass index were associated with TASC-II groups. Only MPV levels was correlated with presence of PVD ($p:0.05$). There was not any correlation between PDW, PCT and presence of PVD, as well as severity of PVD. There was not any correlation between upper quartiles of platelet indices and severity of PVD. In the multivariate regression analysis, elevated MPV was predict the presence of PVD with near-borderline statistical significance (OR:1.82, with a 95 % CI -0.006 – 0.138; $p:0.07$).

CONCLUSIONS: The predictive values of platelet indices in the atherosclerotic vascular disease was already reported before. However, we did not find significance correlation between platelet indices and severity of PVD. Small sample size might be the major limitation of our study. Further investigations with higher patient numbers would review this correlation more clearly.

Keywords: Platelet, mean platelet volume, atherosclerosis, peripheral vascular disease, biomarker

Table 1: Distribution of clinical and demographic characteristics of the patients according to presence and severity of peripheral vascular disease.

Variables	PVD (-) (N:33)	TASC-II A-B (n:26)	TASC-II C-D (n:58)	p
Age (years)	$53,5\pm 10,8$	$58,5\pm 12,4$	$61,5\pm 9,5$	0,001
Sex (male)	54,5%	80,8%	91,4%	0,001
Diabetes mellitus	31,3%	28,0%	31,0%	0,95
Hypertension	48,5%	26,9%	29,4%	0,12
Dyslipidemia	34,4%	23,1%	24,1%	0,51
Smoking	43,8%	38,5%	29,3%	0,36
Creatinine (mg/dl)	$0,89\pm 0,18$	$0,86\pm 0,30$	$1,15\pm 0,95$	0,11
BMI (kg/m^2)	$25,9\pm 2,4$	$28,1\pm 4,7$	$28,5\pm 4,3$	0,009
MPV (fL)	$10,12\pm 0,73$	$10,74\pm 1,02$	$10,45\pm 1,06$	0,05
PDW (fL)	$12,15\pm 2,41$	$13,46\pm 2,46$	$12,69\pm 2,30$	0,12
PCT (%)	$0,26\pm 0,12$	$0,24\pm 0,11$	$0,27\pm 0,14$	0,62
Total	28,2%	22,2%	49,6%	

PVD: Peripheral vascular disease, TASC:Trans-Atlantic Inter-Society Consensus, BMI:Body mass index, MPV:Mean platelet volume, PDW: Platelet distribution width, PCT:Plateletcrit

ID: 567

Topic: **Cardiology » Metabolic Syndrome**

Presentation Type: **Oral**

METABOLIC SYNDROME AND SERUM LEVEL OF APELINE IN PERIPHERIC ARTERY DISEASE

Gunduz Yumun, Savas Guzel, Ahsen Yilmaz, Selami Gurkan, Ozcan Gur

Namik Kemal University, Tekirdag, Turkey

**Corresponding Author (gunduzyumun@gmail.com)*

gunduzyumun@gmail.com, savasguzel@yahoo.com, ahsenyilmaz6@gmail.com, gurkancem@yahoo.com, ozcangur@hotmail.com

Abstract Text

Objective: The aim of this study was to investigate the presence of metabolic syndrome and serum apelin and serum apelin receptor levels in patients with peripheral arterial disease.

Material and Method: This prospective study included 50 patients with PAH who applied to the cardiovascular surgery outpatient clinic between 2017 and 2018 and 50 healthy subjects who were accepted to be included in the study as a control group member. Serum apelin and serum apelin receptor levels were measured with the routine blood tastes from the patients at the outpatient clinic. Clinical features were recorded, and metabolic syndrome and peripheral arterial disease were diagnosed and classified.

Results: The study included 50 patients and 50 volunteers. Smoking was the only risk factor in peripheral artery patients compared to the control group. The number of patients with obesity, gender, diabetes and metabolic syndrome were similar in two groups. Serum apelin level was lower in patients with peripheral arterial disease compared to the control group, while apelin receptor was higher in peripheral arterial patients.

Conclusion: In this study, the number of metabolic syndromes was similar to normal subjects in peripheral arterial patients, however in this patients lower serum apelin and apelin receptor levels were observed just like patients with coronary artery disease compared to normal individuals. This is the first study to investigate apelin in peripheral arterial disease.

Oral Presentations

Coronary Surgery: New Insights and Modalities

Date: 30.03.2019 Time: 08:00 - 09:30 Hall: 6

ID: 486

Topic: Cardiovascular Surgery » Risk Management in Cardiovascular Diseases

Presentation Type: Oral

SHORT AND LONG TERM PREDICTORS OF MORTALITY IN CARDIAC SURGERY

Mustafa Dađlı, Kadir Durgut

University of Health Sciences Konya Education and Research Hospital, Konya, Turkey

*Corresponding Author (drmustafaaaa@gmail.com)

drmustafaaaa@gmail.com, kdurgut@yahoo.com

Abstract Text

AMAÇ

Kalp ameliyatı geçiren 620 kısa ve uzun dönem mortalite belirleyicilerini değerlendirmek

YÖNTEM

Tüm sezon Ocak 2013 ile Ocak 2018 arası çok amaçlı ameliyatla ameliyat edildi. Tüm Üyeler İçin Aralık 2019'a kadar olan tüm ülkeler için Ulusal İstatistik Ofisi'nden elde edildi. Cox birden fazla lojistik regresyon ve çok değişkenli Cox teklif tehlike modelleri kullanıldı. EuroSkore, kalp cerrahisi, ameliyat önceliđi, LV'deki, tesis, yaş, cinsiyet, hipertansiyon, sigara, böbrek ve nörolojik hastalıklar ve DM survival analizleri ameliyat sonrası 30 gün içinde ölen sınıfları dahil edildi.

Sonuçlar

Kalan çocukları için 53 hasta (% 8,5) 30 gün içinde ortalama 12,9 EuroSkore, diđer odalar için 4,7 ortalama EuroSkore ile orada öldü (p <0,0001, t-testi). 30 günlük mortalite, EuroSkore (p: 0,001), konjestif kalp yetmezliđi (p: 0,002), renal hastalıkları (p: 0,003) ve yaş (p: 0,01) ile ROC eğrisi altındaydı. Uzun süreli mortalite analizi 567 hastaya dayanıyordu, bunlardan 8'i 6 yıla kadar bir süre içinde öldü (3,3 yaş ortanca takip). Uzun dönem mortalitenin ana belirleyicileri yaş (p: 0,0001), düşük LVEF (p: 0,0001), kalp hücrelerinde (p: 0,0001) serebrovasküler (p <0,01), renal (p: 0,0001)), respiratuar hastalığı (p: 0,02), DM (p: 0,003), sigara (p: 0,014) ve hipertansiyon (p: 0,01).

Sonuçlar

EuroSkore, CHF, böbrek hastalığı ve yaş, kısa süreli mortalite tahmini ediciyken, uzun süreli mortalite, kardiyak endüstri şirketleri, LVEF, daha geniş preoperatif hastalıkları ve sigara içimi ile buradadır.

ID: 491

Topic: **Cardiovascular Surgery » Coronary Bypass Surgery**Presentation Type: **Oral****DEALING WITH PATIENTS UNDERTAKEN URGENT/EARLY CORONARY ARTERY BYPASS GRAFT SURGERY WHILE USING KLOPIDOGREL****Deniz Özsoy, Sadettin Cöhcen, Ismail Haberal***İÜ Cerrahpaşa Kardiyoloji Enstitüsü, İstanbul, Turkey***Corresponding Author (sdenizozsoy@hotmail.com)**sdenizozsoy@hotmail.com, scohcen@hotmail.com, drhaberal@hotmail.com***Abstract Text****OBJECTIVE:**

In this study we examined the effect of preoperative klopidogrel usage on the postoperative bleeding in the patients having urgent and/or early bypass grafting surgeries.

METHODS:

In this study two groups of patients were compared statistically in terms of bleeding, the type and amount of blood transfusions and the number of revisions . The first group consisting of 66 patients who did not have an additional cardiac disease and had not undergone additional surgical procedure and who were undertaken urgent and/or early surgical operation because of acute coronary syndrome while using klopidogrel; the second group of 68 adult patients who did not use klopidogrel and did not have additional cardiac surgical procedure.

RESULTS:

Among the 134 patients examined in this study 75,4% consisted of men (n=101) and the 24% were women (n=33%). 49,3% of the patients (n=66) were using klopidogrel and 50,7 % of them were non-users. The average age of those using klopidogrel was 60,74±16,96 while the average age of the non-users was 59,10±9,82 and there was not a statistical difference observed between them (p:0,363). While the postoperative drainage amount of the group using klopidogrel was 410 (150-1300)ml and that of non-users was 640(150-2750)ml. In according to the result of the Mann WhitneyU test, the amount of postoperative drainage observed in the group not using klopidogrel was found significantly higher compared to the group using it(p<0,001). There was not a significant difference between two groups in the terms of erythrocyte suspensions used(p:0,525). On the other hand, if we compare the amount of the fresh frozen plasma and thrombocyte suspensions used, they were find significantly higher in the group using klopidogrel(p;<0,001, <0,001). Revisions were observed in 4,6%(n=3)of 130 patients. One of these three patients was using klopidogrel. According to the Fisher exact test , a statistically significant difference was observed between them(p:0,616).

CONCLUSION:

In many studies klopidogrel was proved to be a medication that is useful for recovery of ischemic cases. However ; our study shows that we should be cautious about its relative effect on increasing the usage of fresh frozen plasma and thrombocyte suspension regarding their cost and transfusion complications, even though klopidogrel does not increase the risk of bleeding, the number of revisions and the suspension usage.

ID: 438

Topic: **Cardiology » Coronary Artery Disease - CABG Surgery**Presentation Type: **Oral****VACUUM-ASSISTED CLOSURE THERAPY FOR THE MANAGEMENT OF DEEP STERNAL WOUND INFECTIONS AFTER CARDIAC SURGERY**Yusuf Velioglu¹, Mustafa Çağdaş Çayır², Ahmet Yüksel¹¹*Abant İzzet Baysal University Faculty of Medicine, Bolu, Turkey*²*Pamukkale University Faculty of Medicine, Denizli, Turkey***Corresponding Author (yusufvelioglu@gmail.com)**yusufvelioglu@gmail.com, dr.mcc@hotmail.com, ahmetyuksel1982@mynet.com***Abstract Text**

BACKGROUND: Deep sternal wound infection is a serious postoperative complication that develops in 1% to 3% of patients undergoing cardiac surgery. It causes not only impaired quality of life of patients but also prolonged hospitalization, increased morbidity and mortality, and high medical cost. There is no universal consensus on its optimal management. Vacuum-assisted closure (VAC) therapy has been increasingly used to accelerate wound healing through the application of negative pressure.

OBJECTIVE: To investigate the effect of VAC therapy on deep sternal wound infections following cardiac surgery.

METHODS: A total of 1827 patients underwent cardiac surgery between January 2011 and July 2018. Of them, 33 (1.8%) had deep sternal wound infection and received VAC therapy. A retrospective analysis of these patients with deep sternal wound infection was conducted through electronic file scanning. In the management of deep sternal wound infections, VAC therapy was combined with parenteral antibiotherapy and sternal debridement in all patients. Negative pressure in the sternal wound was applied at a continuous pressure of -125 mmHg in majority of patients. Every 2-3 days, the wound was opened and polyurethane foam was changed. The samples for microbiological culture analysis were taken each time the wound was opened. It was planned to close the wound if the microorganism was not isolated in the culture analyzes examined consecutively twice.

RESULTS: Mean age of patients was 66.5±6.9 years (range: 53-84), twenty (60.6%) of them were male. The most commonly encountered comorbidities were diabetes mellitus, hypertension, hyperlipidemia and obesity in 24, 23, 20 and 16 patients, respectively. The most common surgical procedure was isolated CABG which was performed to 29 (87.8%) patients. Other performed procedures were CABG+mitral ring annuloplasty, CABG+mitral valve replacement, modified button Benthal, and David procedure. The most commonly isolated microorganisms in wound cultures were methicillin-resistant staphylococcus epidermidis and methicillin-resistant staphylococcus aureus in 13 and 10 patients, respectively. Other isolated microorganisms were escherichia coli, pseudomonas aeruginosa, klebsiella pneumoniae and acinetobacter baumannii in 3, 2, 2 and 1 patients, respectively. No microorganism was isolated in 2 patients. Mean duration of VAC therapy was 14.5±7.2 days (range: 3-33), and mean length of hospital stay was 22.7±9.5 days (range: 8-46). No serious VAC therapy-related complication was observed. Mortality was occurred in only 1 patient during the treatment period.

CONCLUSION: VAC therapy seems to be an effective and safe treatment modality in the management of deep sternal wound infections after cardiac surgery.

ID: 300

Topic: Cardiology » Coronary Artery Disease - CABG Surgery

Presentation Type: Oral

A NEW SURGICAL APPROACH TO INTERNAL THORACIC ARTERY SPASM TREATMENT USING THE RADIAL AND GASTROEPIPLOIC ARTERIES DURING CABG

Ömer Faruk Doğan, Kevser Tural

Kars Kafkas University School of Medicine, Kars, Turkey

**Corresponding Author (ofdogan@hacettepe.edu.tr)*

ofdogan@hacettepe.edu.tr, ktr12011@hotmail.com

Abstract Text

Background: Spasm of the internal thoracic artery (ITA) conduit remains a life threatening problem during and after coronary artery bypass graft (CABG). Different systemic and local vasodilators have been suggested to prevent ITA spasm. Unfortunately, spasms can be refractory to pre-treatment with vasodilators. We describe a new surgical techniques using the radial artery (RA) or gastroepiploic artery (GEA) as a patch or tubular conduit to resolve ITA spasm and extend the artery in patients who underwent CABG.

Methods: We included 210 patients with multi-vessel coronary artery disease who underwent isolated total arterial CABG between 2008 and 2013. We detected low blood flow due refractory spasm of the ITA (after harvesting or prior to anastomosis) in 35 patients. To increase blood flow, we dilated the distal ITA using a 10–20 mm long RA patch in 20 patients. In the remaining 15 patients, the spasm involved a long portion of the ITA; therefore, we shortened this portion and then anastomosed 4-5 cm long RA or GEA conduit in an end-to-end fashion to gain the appropriate length of ITA. If length of ITAs spasm was too long, we shortened the ITAs, and a RA or GEA tubular conduit was anastomosed in an end-to-end fashion to gain the appropriate length of ITA.

Results: There were no postoperative mortality and morbidity. Myocardial enzyme analyses showed no evidence of myocardial ischemia. The left and right ITAs had diameters of 1.1 ± 0.40 mm and 1.2 ± 0.21 mm, respectively. After harvesting, the ITAs bled into the cab for 1 min. for calculation of blood flow. The mean blood flows of left and the right ITA was 23 ± 9 mL/min. and 29 ± 11 mL/min., respectively. On comparing the diameters and flows of the left and right ITAs, no significant differences were found ($P > 0.05$). The mean blood flow significantly increased ($P < 0.0001$) to 74 ± 22 mL/min. on the right ITAs and to 53 ± 14 mL/min on the left ITAs. The mean length of the ITAs was significantly increased from 9 ± 2.1 cm to 14 ± 1.9 cm after RA or GEA conduit anastomoses ($P = 0.001$).

Conclusion: Increased blood flows and diameters were successfully facilitated using the RA patch, as a result of ITA dilatation. When ITA spasm is refractory to vasodilators, surgeons should keep in mind that the RA can be used as a biological patch to increase the cross-sectional area of ITAs during CABG. In addition, in case there is a need to shorten ITA grafts, the length can be easily and safely extended using RA or GEA conduits. This study showed that our techniques for extension and release of ITA spasm using RA and GEA are feasible. We recommend these additional options to existing methods while performing total arterial revascularization.

ID: 215

Topic: Cardiology » Coronary Artery Disease - CABG Surgery

Presentation Type: Oral

IS THERE ANY DIFFERENCES IN MAJOR CARDIAC AND CEREBRO-VASCULAR EVENTS BETWEEN COMPLETE AND INCOMPLETE REVASCULARIZATION AFTER CABG AMONG PATIENTS WITH MULTI-VESSEL DISEASE ?

Rezan Aksoy

*Kartal Kosuyolu Heart Training and Research Hospital, Istanbul, Turkey***Corresponding Author (rezanaksoy@gmail.com)**rezanaksoy@gmail.com***Abstract Text**

Objective: This study sought to assess major cardiac and cerebro-vascular events(MACCE) among patients with multivessel disease undergoing coronary artery bypass graft(CABG) by comparing complete with incomplete revascularization strategies.

Methods: This retrospective study included 313 patients (male; 80%, n:252) with isolated CABG between January 2011-2012. The patients were randomly assigned either incomplete(n:110, mean age: 57.7±10.5) or complete(n:203,mean age:60.0±9.0) revascularization strategies. We compared the two groups with respect to demographic data and the imaging findings of echocardiography and coronary angiography, preoperative data and postoperative MACCE.

Results: There were no significant differences between the groups compared to preoperative demographic data and imaging of echocardiography ($p > 0.01$). Cardiopulmonary bypass time(CPB) and cross clamp time were found statistically differences between two groups($p < 0.001$). Also length of stay(LOS) hospital(days) (group 1:7,4±3.1; group 2:8,3±6.3; $p:0.02$) and acute renal failure(group 1 n:0; group 2 n:7, 3,4% $p:0.05$) were found to be longer than group 1. Between the two groups there were no statistically differences for MACCE ($p > 0.01$) (table 1).

Conclusion: We found that, although the duration of CPB, LOS of hospital and acute renal failure were longer in the complete revascularization group, there was no difference in MACCE between the two groups.

Table 1: Operative findings and postoperative outcomes

Variables	Group 1 (n:110)	Group 2 (n:203)	P value
Bypass time (min), mean±SD	65.1±24.1	102.5±34.0	<0.001*
Cross clamp time (min), mean±SD	40.6±18.5	69.8±29.1	<0.001*
Need of inotrope, n (%)	3 (2.7)	14 (6.9)	0.12
Need of IABP, n (%)	2 (1.8)	9 (4.4)	0.23
Reoperation for bleeding, n (%)	5 (4.5)	11 (5.4)	0.74
Infection, n (%)	2 (1.8)	9 (4.4)	0.23
Acute renal failure, n (%)	0	7 (3.4)	0.05*
Prolonged intubation, n (%)	3 (2.7)	5 (2.5)	0.89
Atrial fibrillation, n (%)	2 (1.8)	5 (2.5)	0.71
Malign ventricular arrhythmia, n (%)	1 (0.9)	1 (0.5)	0.66
CVE, n (%)	1 (0.9)	0	0.35
Mortality, n (%)	1 (0.9)	5 (2.5)	0.31
MAE, n (%)	9 (8.2)	22 (10.8)	0.45
LOS of ICU (days), median (ranges)	1 (1-13)	1 (1-41)	0.40
LOS of Hospital (days), mean±SD	7.4±3.1	8.3±6.3	0.02*

CVE: Cerebrovascular event, IABP: Intra-aortic balloon pump, ICU: Intensive care unit, LOS: length of stay, MAE: Major adverse event, SD: Standard deviation.

ID: 109

Topic: **Cardiology » Coronary Artery Disease - CABG Surgery**Presentation Type: **Oral****WHEN TO GO TO CATHLAB?****Aleksei Semagin, P.v. Kuznetcov, E.v. Ignatov, D.r. Tereschenko, O.p. Lukin***Federal State Institution "Federal Centre for Cardiovascular Surgery," the Ministry of Health of the Russian Federation, Astrakhan , Russia***Corresponding Author (voland420@gmail.com)**voland420@gmail.com, voland420@gmail.com, voland420@gmail.com, voland420@gmail.com, voland420@gmail.com***Abstract Text**

BACKGROUND: One of the most serious complications of CABG surgery remains perioperative myocardial infarction. Myocardial damage can be associated with both graft dysfunction and other causes, including inadequate protection and incomplete myocardial revascularization, as well as distal coronary embolism during surgical procedures.

The purpose of the study was to identify a set of factors that allow to suspect graft dysfunction, as well as to determine the necessary treatment strategy.

METHODS: In the period from 2011 to 2017, 7,489 CABGs were performed at the Federal Center for Cardiovascular Surgery of the Ministry of Health of the Russian Federation (Chelyabinsk). The study group consisted of 103 patients with perioperative myocardial damage, as well as a control group of 30 patients without myocardial damage. All patients with suspected myocardial damage underwent emergency coronary angiography. The permeability of the grafts of patients in the control group was confirmed by intraoperative flowmetry, they also monitored the level of troponin I after 1 hour, 6 hours, 12 hours, 24 hours and 48 hours after surgery.

RESULTS: According to the results of emergency coronary angiography, the patients were divided into 2 subgroups. The first subgroup consisted of 28 patients in need of repeated intervention: 20 patients underwent endovascular correction, 8 patients required repeated surgical intervention. In the second subgroup there were 75 patients who did not undergo additional surgical treatment, but 18 of them had angiographic defects of grafts. When analyzing the postoperative state of the patients of the first and second subgroups by criteria such as an increase in troponin I level in the first 24 hours, ischemic changes on the ECG, the appearance of new zones of hypo- and akinesia during echocardiography, there was no significant difference. Significant differences were obtained when comparing these subgroups with the control group for all criteria.

CONCLUSIONS: Based on the increase in troponin I level, pathological changes in the ECG and echocardiogram, it can be concluded that the myocardium is damaged. However, it is rather difficult to determine the cause of myocardial alterations. In order to accurately diagnose the genesis of damage and determine the subsequent treatment strategy, this complex group of patients requires urgent coronary angiography. Such factors as the occurrence of LBBB or Q wave on the ECG, lowering the left ventricular EF by more than 10% from baseline, pronounced cardiotoxic support, troponin I values exceeding the values obtained from patients in the control group, borderline flowmetry can be considered. In our opinion, an indication for emergency angiography is a combination of the above three signs, and if one of the factors is "questionable" flowmetry data, an angiographic study is absolutely necessary.

ID: 337

Topic: **Cardiovascular Surgery » Coronary Bypass Surgery**Presentation Type: **Oral****BILATERAL VERSUS UNILATERAL INTERNAL THORACIC ARTERY
REVASCULARIZATION IN PATIENTS WITH MULTIVESSEL CORONARY
ARTERY DISEASE**Oybek Mashrapov, **Abdusalom Abdurakhmanov**, Ilkhom Abdukhalimov*Republican Research Center of Emergency Medicine, Tashkent, Uzbekistan***Corresponding Author (docmashrap@yahoo.com)**docmashrap@yahoo.com, ab.abdurakhmanov@yandex.com, ababdurakhman@gmail.com***Abstract Text**

Objective: The bilateral internal thoracic artery (BITA) use for revascularization in patients with multivessel coronary artery disease showed advantages over single left internal thoracic artery (LITA) with saphenous vein grafts (SVG) use for coronary artery bypass grafting in such a complicated group of patients. However harvesting BITA can be associated with higher incidence of blood-loss, wound complications and major cardiac events (such as perioperative myocardial infarction, stroke and all cause death) in early postoperative period. We aimed to compare incidence of bleeding, wound complications and major cardiac events among patients underwent coronary artery bypass grafting procedure using BITA vs LITA harvesting.

Materials and methods: The study included 43 patients who underwent surgery in the department of cardiac surgery from October 2016 to December 2018 at the Republican Research Center for Emergency Medicine. All patients were divided into 2 groups: the first group consisted of 25 patients who underwent coronary bypass with the use of the left internal thoracic artery and venous grafts (LITA+SVG), the second group – 18 patients underwent CABG using both internal thoracic arteries for myocardial revascularization (BITA+SVG). The age of the patients ranged from 47 to 66 years (the average - 55 years). In both groups, all patients were male. **Results:** In the first group, 14 patients had stable angina, the remaining 11 patients had unstable angina. In the BITA+SVG group, all patients had unstable angina. All patients had also history of previous myocardial infarction. On coronary angio –18 patients had - 3x vascular lesion, and 7 had - stenosis of the left main and the right coronary artery (LITA+SVG). Among BITA+SVG patients 15 patients had - 3 vessel disease and 3 patients had a left and right main stem stenosis. The revascularization index was 3.1 for the patients of LITA+SVG group and 3.1 for the BITA+SVG group. In the early postoperative period, acute myocardial infarction, stroke and mortality were not observed in any case. The average blood-loss in drainage tube during first postoperative day was 280 ± 15 ml and 305 ± 23 ml for the LITA+SVG and BITA+SVG groups, respectively. It should be noted that in the first and second groups, were not observed any wound related complications.

Conclusion: this comparative study showed that BITA and LITA harvesting doesn't influence early postoperative period. Both methods accompanied by satisfactory results regarding to bleeding, wound healing and major cardio-cerebral events in patients with multivessel coronary artery disease.

ID: 490

Topic: Cardiovascular Surgery » Risk Management in Cardiovascular Diseases

Presentation Type: Oral

DOES PREOPERATIVE LOW SERUM IRON LEVEL PREDICT EARLY TERM OUTCOMES AFTER CARDIAC SURGERY

Mustafa Dađlı, İlyas Selim Yılmaz

University of Health Sciences Konya Education and Research Hospital, Konya, Turkey

**Corresponding Author (drmustafaaaa@gmail.com)*

drmustafaaaa@gmail.com, ilyasselim@yahoo.com

Abstract Text

OBJECTIVE

This study aimed to assess if preoperative low serum iron level impacts operative mortality, postoperative morbidities, post operative transfusion in patients undergoing cardiac surgery.

METHODS

Between January 2016 and December 2018 data of 174 consecutive patients undergoing cardiac surgery were retrospectively reviewed. 53 (30,4%) patients had preoperative low serum iron level. Propensity score matching was performed based on 11 preoperative risk variables to correct for confounding bias. 30 days mortality and follow up outcomes as primary end point, as well as major complications of cardiac surgery were compared.

RESULTS

Post operative acute kidney injury were higher in preoperative low serum iron level group (17,1% Vs 9,8%, P<0,01), but no differences in 30 days mortality and postoperative morbidities.

CONCLUSIONS

Post operative acute kidney injury was higher in patients with preoperative low serum iron level group undergoing cardiac surgery. Future studies should determine whether therapies aimed at treating preoperative low serum iron level would improve the outcomes of patients undergoing cardiac surgery.

ID: 470

Topic: Cardiovascular Surgery » Coronary Bypass SurgeryPresentation Type: **Oral****THE EVALUATION OF SIGNIFICANCY OF FURTHER MARKERS BEYOND ROUTINE RISK SCORING METHODS FOR CORONARY ARTERY BYPASS GRAFT SURGERY****Deniz Özsoy**, Ibrahim Burak Şeker, Ismail Haberal*İÜ Cerrahpaşa Kardiyoloji Enstitüsü, İstanbul, Turkey***Corresponding Author (sdenizozsoy@hotmail.com)**sdenizozsoy@hotmail.com, burakseker@hotmail.com, drhaberal@hotmail.com***Abstract Text****OBJECTIVE:**

The aim of this study is to evaluate the effectiveness of using preoperative and postoperative hematologic values in addition to routine risk scoring methods used for coronary artery bypass graft surgery

METHODS:

Retrospective analysis of 670 ischemic heart disease cases who underwent elective coronary artery bypass graft operation with no additional cardiac complaint and no additional surgical procedures.

RESULTS:

Overall 670 patients (age mean: 61,20± 9,54), 151 were female (age mean 61,58±9,46) and 519 were male (age mean 61,09±9,57). Atrial fibrillation (AF) was observed in 33 female and 118 male patients, Major Adverse Cardiac and Cerebrovascular events were observed in 13 female and 32 male patients, and mortality was observed for 9 female and 22 male patients. There was a statistically significant relation between high preoperative N/L ratio and AF and other adverse events after CABG surgery ($p<0.001$ and $p=0,001$, respectively). Relation between high preoperative RDW values and atrial fibrillation rates after CABG was statistically significant ($p=0,005$). There was a significant relation between the difference of postoperative and preoperative count of platelets and mortality rates following CABG ($p<0.001$). 1-unit (10^3 m^3) increase of platelet count on 7th postoperative day compared to preoperative; was parallel to decreased mortality rate by 3% ($p<0,001$). The findings showed that the increase of the difference between postoperative and preoperative platelet counts led to decreasing of major adverse cardiac and cerebrovascular event rates ($p=0,001$ and $p<0,001$; respectively).

CONCLUSION:

Over the last decade, despite of the decreased mortality rates of coronary artery bypass graft (CABG) surgery, morbidity rates increased. This leads to increased complication rates after surgery and worse life quality. European System for Cardiac Operative Risk Evaluation (EuroSCORE) is widely used for adult cardiac surgical practice to score the risk factors. The cardiovascular surgeons are in a never-ending search of additional and more reliable predictors. In our study ; high preoperative N/L ratio was associated with the higher rate of AF and other adverse events following CABG but it was not related with major adverse cardiocerebral events and mortality rates. 1-unit (10^3 m^3) increase of platelet count on 7th postoperative day or discharge day compared with preoperative one came out with a lesser mortality by 3 %. Platelet count after CABG is an independent indicator of the mortality rates.

Oral Presentations

Glimpse Into the Carotid Surgery

Date: 30.03.2019 Time: 09:30 - 11:00 Hall: 6

ID: 188

Topic: **Cardiovascular Surgery » Hybrid Cardiovascular Surgery**

Presentation Type: **Oral**

STAGED VERSUS SYNCHRONOUS APPROACHES TO THE SURGICAL TREATMENT IN CONCOMITANT CORONARY AND CAROTID ARTERY STENOSIS

Oybek Mashrapov, Abdusalam Abdurahmanov, Mustafa Obeid

Republican Research Center of Emergency Medicine. Tashkent, Uzbekistan, Tashkent, Uzbekistan

**Corresponding Author (docmashrap@yahoo.com)*

docmashrap@yahoo.com, ab.abdurakhmanov@yandex.com, mustafaobeid@yandex.com

Abstract Text

INTRODUCTION: there are still a lot of controversies regarding to preferable approach to surgical revascularization in patients with concomitant severe carotid artery stenosis and coronary artery disease. We aimed to compare immediate results of simultaneous and staged revascularization in patients with concomitant coronary and carotid artery stenosis.

MATERIALS AND METHODS: this retrospective research includes 45 patients, operated in the RRCEM at the periods 2014 - 2018 year. Patients were divided into two groups: the first group (simultaneous) – 20 patients – simultaneous carotid endarterectomy and coronary artery bypass grafting off-pump or on-pump; second group (staged) – 25 patients, staged carotid endarterectomy and coronary bypass grafting. Both groups were comparable by sex and age, males 14(70%) and 18(72%); middle age 67,2±3,5 and 64,3±2,5 years in simultaneous and staged groups respectively. Indications for simultaneous or staged approach based on significance of stenosis both in carotid and coronary artery basins and severity of symptoms. In postoperative period the incidence of main cerebro-vascular events (myocardial infarction, stroke, all cause death) and postoperative stay duration were assessed.

RESULTS: Basic indications for simultaneous approach were the need of myocardial revascularization with concomitant significant unilateral more than 70% symptomatic stenosis of carotid artery -12(60%) or bilateral symptomatic – 3(15%) and asymptomatic more than 50% stenosis of carotid artery 5(25%). A total of 13 patients (65%) of the simultaneous group had early postinfarction angina, in 5 (25%) cases the primary unstable angina and in 2 (10%) cases angina at rest refractory to medication were diagnosed. Patients included in simultaneous group underwent, carotid endarterectomy followed by off-pump coronary artery bypass surgery (19/95%), in one case (5%) because of unstable hemodynamics, coronary artery bypass grafting was performed on-pump. In the staged group, in all 25(100%) cases, the coronary bypass step was performed off-pump. The index of grafted vessels was 3.6 for the simultaneous and 3.4 for the staged group. In the early postoperative period, cerebral circulation disorders were observed in both groups and differed statistically not significant (1(5%) vs 1(4%); p=0,7). In simultaneous group one patient (5%) died from pulmonary complications, in the second group no mortality was observed. Other cardiovascular and cerebral complications (acute myocardial infarction, heart failure, transient ischemic attack or stroke) were not observed in any group. The average duration of the postoperative hospital period was 8,8±1,2 days for the patients operated simultaneously; patients of the staged group, stayed at hospital overall 15,2±1,5 days; due to two-time hospitalization.

CONCLUSION: We can conclude that simultaneous and staged approach in surgical revascularization among patients with combined carotid and coronary artery stenosis showed no difference regarding main cerebro-vascular and cardiac events or death. Mortality, observed in simultaneous group, can be explained by initially more complicated status of the patient. Staged approach accompanied with relatively longer postoperative in-hospital period.

ID: 483

Topic: **Cardiovascular Surgery » Peripheral Arterial Disease**Presentation Type: **Oral****EMERGENT CAROTID ARTERY SURGERY AFTER CAROTID ARTERY INTERVENTIONS****Hasan Erdem***Kartal Koşuyolu Yüksek İhtisas Eğitim Araştırma Hastanesi, İstanbul, Turkey***Corresponding Author (herdemkvc@hotmail.com)**herdemkvc@hotmail.com***Abstract Text**

Emergent Carotid Artery Surgery After Carotid Artery Interventions

Objective: The main cause of 10-20% of stroke is due to atherosclerotic carotid artery stenosis. Since 1950, carotid endarterectomy is the choice of treatment for symptomatic and asymptomatic carotid artery stenosis, though carotid artery stenting emerged as an alternative for revascularization nearly 35 years ago. Two decade ago, pooled data analyses revealed the best time for carotid endarterectomy as the first 14 days, for symptomatic carotid artery stenosis. Although there is still consensus for early surgical intervention for symptomatic carotid artery stenosis in the light of guidelines and publications, the question when to operate in the time frame of 14 days has not been answered yet and still actual. The high risk of recurrent stroke risk within 2 days in patients with symptomatic carotid artery stenosis is the main reason, which makes previously mentioned question actual. However, the perioperative risk of stroke for carotid endarterectomy in patients who are operated within two days is the main reservation of the early operation. In current study, we discussed our clinical results of patients who are operated urgently after the first episode of stroke.

Methods: Between 2017-2019, in our clinic, 5 (4 male, 1 female) patients underwent emergent carotid surgery, due to neurological complications after elective carotid artery revascularization procedures. In all patients, the decision for emergent carotid surgery was given due to newly developed and progressive neurological deficit encountered after the first intervention and all patients were operated within the first 2 hours.

Results: 4 patients were male and 1 was female. 2 patients were operated due to acute thrombosis secondary to carotid artery patchplasty and three patients were operated due to early thrombosis after carotid artery stenting. After emergent carotid surgery, 3 patients were discharged without any neurological deficit; however, in 2 patients mild aphasia and motor deficit was the case before discharge, which also subsided in two months follow-up period.

Conclusion: Emergent carotid surgery due to acute thrombosis of the carotid artery, which is evident clinically and radiological, after carotid interventions; may help to fix newly developed and progressive neurological deficits.

ID: 526

Topic: Cardiovascular Surgery » Diagnosis and Treatment of Carotid Artery DiseasePresentation Type: **Oral****SYMPTOMATIC CAROTID ARTERY STENOSIS: SURGERY VS. STENT IMPLANTATION****Ömer Faruk Çiçek, Gökhan Özdemir, Gözde Öngün, Hakan Akbayrak, Atilla Orhan, Mustafa Büyükaş***Selçuk University School of Medicine, Konya, Turkey***Corresponding Author (farux@hotmail.com)**farux@hotmail.com, noro.ozdemir@gmail.com, gongun68@hotmail.com, hakanakbyrak@yahoo.com, atilaorhan@gmal.com, mustafabuyukates@yahoo.com***Abstract Text**

Objective: The stroke is one of the major causes of permanent disability and death. Ischemic origin is the most common cause of stroke, moreover, carotid artery stenosis is responsible in about one third of these patients. The treatment options of carotid artery stenosis include endarterectomy and balloon angioplasty and/or stent implantation. In this study, we aimed to compare the demographic and perioperative characteristics of the patients with symptomatic carotid artery stenosis who underwent carotid endarterectomy and carotid artery stent placement.

Methods: In this study, twenty-eight patients who underwent carotid endarterectomy (n=9) and carotid artery stenting (n=19) were evaluated retrospectively. Either computed tomographic angiography or conventional digital subtraction angiography was used in decision-making processes of patients with symptomatic carotid artery stenosis between endarterectomy and stenting. The degree of stenosis was determined in accordance with the NASCET criteria. Patients with totally occluded carotid artery were not included in the study. All endarterectomy operations were performed under general anesthesia. Patch plasty with expanded polytetrafluoroethylene or autologous saphenous vein were performed in all patients following endarterectomy. Carotid stenting was carried out through the femoral artery. Patients who underwent stenting were already taking antiplatelet medications and continued after the intervention.

Results: There were no statistical differences between the groups in terms of patients' age, gender, concomitant hypertension, hyperlipidemia, diabetes mellitus, symptom characteristics, imaging techniques, side of lesions and degree of stenosis. One patient underwent revision for postoperative hematoma in the operation field following endarterectomy, however, there was no other complication in each two groups (p=0.32). The mean duration of intensive care unit stay in endarterectomy group was statistically significantly longer than in stent group (1.1 days vs. 0 days; P< 0.001). There was no statistically difference between endarterectomy and stent groups in terms of hospital stay (4.1±1.7 days vs. 4.5±3.1 days; p=0.71).

Conclusions: The clinical results of carotid artery stenting and endarterectomy are comparable even though the relatively small number of patients included in this study as a main limitation.

ID: 417

Topic: Cardiovascular Surgery » Diagnosis and Treatment of Carotid Artery DiseasePresentation Type: **Oral****IS MULTINODULAR GOITER A RISK FACTOR FOR CAROTID BODY TUMOR? ANOTHER REASON FOR A COMPREHENSIVE “NECK CHECK”****Rukiye Derin Atabey, Yigit Akcali***Erciyes University, Kayseri, Turkey***Corresponding Author (rukiyeatabey@hotmail.com)**rukiyeatabey@hotmail.com, yigitakcali@gmail.com***Abstract Text**

OBJECTIVE: Carotid body tumors (CBTs) are rare neoplasms of neural crest origin. Although the majority of tumors are benign, they are rarely at risk of malignancy. Therefore, early diagnosis and treatment of the disease is important. The association of some CBTs with other neoplasms has been described, but to the best of our knowledge, there is no literature presenting a series of CBT and multinodular goiter (MNG) comorbidity as in our study. We aimed to evaluate the coexistence of MNG in patients treated for CBT.

METHODS. The medical records of the patients with treated CBTs in last eight years at our Department were retrospectively reviewed. Thirteen (80%) women and 3 (20%) men with a mean age of 51.5 (\pm 14.5) were included in the study. Half of patients presented with a painless neck mass that was investigated by duplex ultrasound, CT angiogram, and arteriography (Figure 1). None of the patients had a family history of the tumor. The left side was more frequently involved (62.5%), along with two bilateral involvement (12.5%). The other symptoms of the patients were headache (31.2%), flushing (12.5%), tinnitus (6.2%), dysphagia (6.2%), and hoarseness (6.2%). Hormone blood tests (TSH etc.) and thyroid ultrasound were also included for the diagnosis of nodular goiter. Statistical analysis of the data was done by SPSS 22.0 package program. Values of $p < 0.05$ were considered statistically significant.

RESULTS. Complete surgical excision was performed in all the patients (Video 1). The median value of the largest tumor mass size was 26 mm (range, 14-70 mm) and the median value of the smallest tumor mass size was 18 mm (range, 10-50 mm). MNG was detected in 13 patients (81.25%) with euthyroid. In 13 (100%) of the female patients, MNG was detected and none of the male patients had MNG. The relationship between female gender and MNG was statistically significant ($p = 0.007$). Hypertension was detected in 2 (15.3%) of the 13 patients with MNG while 1 (33.3%) of 3 patients without MNG was found to have hypertension, and the difference was not statistically significant ($p = 0.675$). In 2 (15.3%) of 13 patients with MNG, the tumor mass was bilateral, whereas all non-MNG patients had unilateral localized tumor mass ($p = 0.550$). According to Shamblin classification, thirteen tumors (81.25%) were type II and three (18.75) were type III confirmed intraoperatively.

CONCLUSIONS. Although the relationship between them is not known yet, MNG is associated with a high risk of thyroid cancer. Similarly, in our study, we think that MNG, which has a high rate of association with CBT, may be a risk factor for CBT, which is rarely malignant, although it is mostly a benign tumor. Certainly, more extensive researches will be needed to support this thesis.

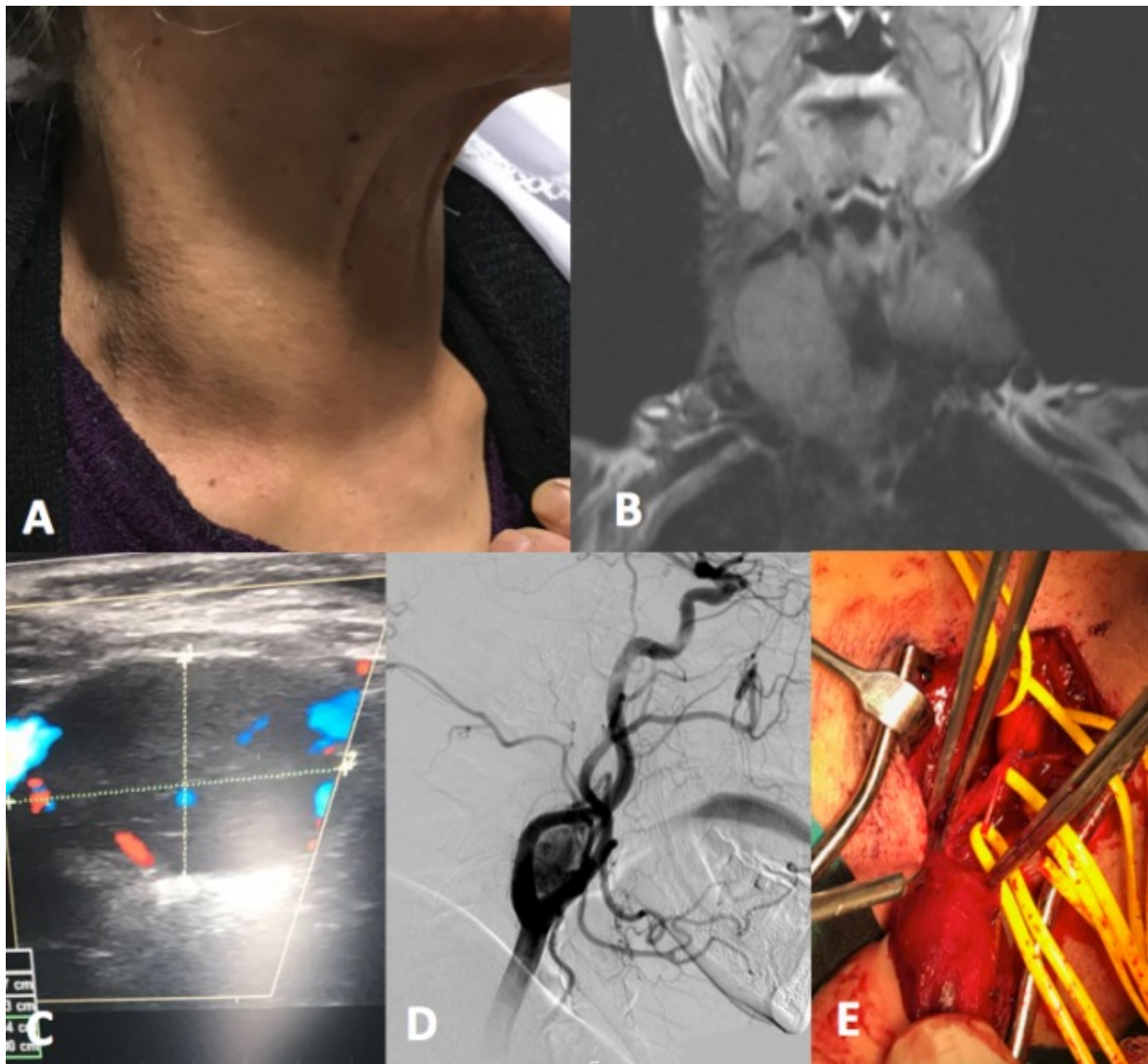


Figure 1. A 72-year-old female patient with concomitant MNG and CBT (A) and her MRA (B); A point-of-care duplex ultrasound of female patient with Type II CBT (C); A “lyre sign” on DSA of a 48-year-old female patient (D); An appearance of CBT in the surgical field during its excision (E). MNG, multinodular goiter; CBT, carotid body tumor; MRA, magnetic resonance angiography; DSA, digital subtraction angiography.

ID: 356

Topic: Cardiovascular Surgery » Diagnosis and Treatment of Carotid Artery DiseasePresentation Type: **Oral****CAS VERSUS CEA: RESULTS OF 642 PATIENTS****Enza Maria Ottoveggio***ASL Salerno, Roma, Italy***Corresponding Author (dottoressaottoveggio@libero.it)**dottoressaottoveggio@libero.it***Abstract Text**

CAS is now the gold standard, like CEA in stroke prevention. Our choice was CEA in asymptomatic patients with carotid stenosis > 70% and in symptomatic patients (SVS - ESVS - SICVE guidelines) for long time but after 10 experience's years we realized that CAS is superimposable to CEA for safety and durability of result. The aim of the study is firstly to compare the two methods in carotid stenosis patients. Additionally we targeted to define internal criteria for an appropriate therapeutic strategy in Personalized Medicine as well as to discuss place of a systematic filter in decision making.

Materials and Methods:

From April 2007 to December 2017 , 642 patients were treated at our UOC of Vascular Surgery for Carotid Stenosis. 466 with CEA (294 endarterectomy + patch and 172 endarterectomy by eversion) and 176 with CAS (174 Carotid WellStent + Emboshield filter and 2 Ideal Crystal + Emboshield filter). Asymptomatic patients were candidate for CAS in agreement with ACST-2Trial while symptomatic patients at CEA. The maximum age for CEA 82.

Results: at 30 days the technical success was 97.86% on 642 patients due to two re-stenoses in CAS for arbitrary suspension of medical therapy and a case of CEA patch infection.

Adverse events for CAS: 4 thromboembolises and 2 dissections in femoral access, while for CEA: a neck hematoma and two major strokes. The follow-up at 3 months, 1 year, 3 years, 10 years showed the persistence of the result. No death related to the procedure is done. Optimal Medical Therapy (OMT) has always been associated. Discussions / conclusions: CAS in agreement with the ACST-2Trial should be reserved for asymptomatic patients with stable plaque and with a maximum age of 75 years, since the fragility of access vessels and revascularization is greater at a later age. compromises endovascular navigation.

Personalized Medicine take a great consideration of age, patient' s general and local condicions and center's experience. In our center in 10 years our choice in first time was in favour of CEA, then, when our experience in endovascular procedures had grown up and we was encouraged by others group' s experience too, our gold standard choice became the CAS. This year the ratio between CAS and CEA is 4:1.

Regarding the use of the filter: in the CAS we use it in all patients systematically. About shunt in CEA: initially we used the shunt only in patients under general anesthesia, in those with recent stroke and in those who did not support clamping but actually we use it sistematically too.

ID: 30

Topic: Cardiovascular Surgery » Diagnosis and Treatment of Carotid Artery Disease

Presentation Type: Oral

GIANT EXTRACRANIAL CAROTID ARTERY ANEURYSMS

Hakan Parlar

SBU Derince SUAM, kocaali, Turkey

**Corresponding Author (hakanparlarcvs@gmail.com)*

hakanparlarcvs@gmail.com

Abstract Text

A 74-year-old woman was referred to our hospital with a pulsatile left neck mass and vertigo which had been diagnosed by Doppler ultrasonography before referral. Verification of the diagnosis of an extracranial aneurysm of the left proximal internal carotid artery was made by digital subtraction angiography. Open surgical repair was performed by resection of the aneurysm and interposition of a polytetrafluoroethylene (PTFE) tubular vascular graft. Extracranial carotid artery aneurysms are uncommon pathologies and still challenging to its diagnosis and treatment strategy. Awareness of this rare pathology in the differential diagnosis of head and neck masses would facilitate the diagnosis and prevent complications like cerebral thromboembolism. Surgical treatment is still regarded as a gold standard in the treatment of these cases. In this report, we presented a patient with an incidentally diagnosed aneurysm of extracranial internal carotid artery.

Oral Presentations

Controversial Issues in Coronary Surgery

Date: 30.03.2019 Time: 11:00 - 12:30 Hall: 6

ID: 459

Topic: **Cardiovascular Surgery » Coronary Bypass Surgery**

Presentation Type: **Oral**

SURGICAL REPAIR FOR ACUTE MYOCARDIAL INFARCTION INDUCED VENTRICULAR SEPTAL DEFECT: DOES TIME MATTERS?

Yunxing Xue, Qing Zhou, Jun Pan, Dongjin Wang

The Affiliated Drum Tower Hospital of Nanjing University Medical School, Nanjing, China

**Corresponding Author (albert_xue@163.com)*

albert_xue@163.com, qingzhou_gl@163.com, xykakashi@163.com, dongjinwang_gl@163.com

Abstract Text

Background: Ventricular septal defect (VSD) induced by acute myocardial infarction (AMI) is rare but lethal with a high mortality even received surgical repair. Time interval from onset to operation is possibly beneficial for patients. Our aim was to assess the association of time interval with surgical repair effects for patients with VSD following AMI.

Methods: From January 2003 to December 2017, 14 patients with VSD induced by AMI have received surgical therapy in our department. We retrospectively reviewed the patients' clinical manifestations, surgical methods, and outcomes. According to the time interval from AMI onset and operation, we divided into two groups, Group 1 (number=9) as more than one week and Group 2 (number=5) as less than one week. Comparing study was done and differences were analyzed.

Results: The mean age of the entire group was 65.5±3.3 years with male percentage of 78.6%(11/14). VSDs were anterior apical in 10 (71.4%) and posterior inferior in 4 (28.6%) patients. Average size of VSD was 15.8±5.8mm. Compared with Group 1, Group 2 revealed worse left ventricular function (LVEF 40.8±10.3% VS 30.4±2.3%, P=0.035), higher rate of urgent procedure (11.1% VS 100.0%, P=0.003). The cardiopulmonary bypass time and aortic clamp time was 203.9±52.3 and 152.4±44.8 minutes. All patients underwent concomitant coronary artery bypass graft surgery. The mortality rate was 14.3% (2/14), higher in Group 2 but no significant differences (20.0% VS 11.1%, P=1.000). Mechanical support (IABP and ECMO) were more common in Group 2, both preoperative (IABP, 22.2% VS 80.0%, P=0.091; ECMO, 0 VS 20.0%, P=0.357) and intraoperative period (IABP, 0 VS 60.0%, P=0.027; ECMO, 0 VS 40.0%, P=0.110). No resistant shunt and death was found during follow-up.

Conclusions: VSD following AMI is safer for more than one week, but surgical treatment is also acceptable for patients requiring urgent surgery due to hemodynamic instability. Mechanical assistive devices such as IABP and ECMO can improve perioperative success rate.

ID: 481

Topic: **Cardiovascular Surgery » Coronary Bypass Surgery**Presentation Type: **Oral****SINGLE-CENTER COMPARISON OF RESULTS OF PATIENTS WHOM UNDERWENT CORONARY ARTERY BYPASS GRAFTING WITH BEATING HEART (OFF-PUMP) TECHNIQUE VERSUS CARDIOPULMONARY BYPASS (ON-PUMP) TECHNIQUE**Gökhan Erol ¹, Hüseyin Sicim ¹, **Erdem Çetin** ², Furkan Burak Akyol ¹, Ufuk Mungan ³, Kaan Yurtseven⁴, Ertan Demirdaş ¹¹*Gulhane Training and Research Hospital , Ankara, Turkey*²*Karabük Training and Research Hospital , Karabük , Turkey*³*Akay Hospital, Ankara, Turkey***Corresponding Author (drgokhanerol@gmail.com)**drgokhanerol@gmail.com, drhuseyinsicim@gmail.com, erdem1978@gmail.com, akyolburak19@gmail.com, drumungan@gmail.com, kaanyurtseven.md@gmail.com, dr.ertandemirdas@gmail.com***Abstract Text****Introduction:**

Coronary artery bypass grafting (CABG) with cardiopulmonary bypass (on-pump CABG) was the gold standard procedure however off-pump coronary artery bypass (OPCAB) technique which does not require to stop the heart while the graft attachments are made has been standing out in the past 10-20 years due to the revealing of the adverse effects of CBP and the increasing risk factors (more advanced age and more comorbidities) of the patients whom the CABG is planned for. Studies showed that adverse effects of CPB including systemic inflammatory reaction initiated by extracorporeal circulation, mechanical blood trauma, impaired hemostatic, neurological, renal and gastrointestinal functions due to activation of multiple immunological cascades (complement system, cytokines). Furthermore, cannulation and cross-clamping of aorta which are used in on-pump CABG technique have been showed to may cause neurological changes or end organ damage as a result of microembolism. These unfavourable effects of CPB have orientated the surgeons to new approaches that allow making bypass without using CBP.

Due to this orientation to new techniques, OPCAB is becoming popular among surgeons. With the newly developed devices and new anesthesia techniques CABG surgery has become applicable to majority of the patients. In this study we aimed to analyze the results of the 1072 cases whom underwent on-pump or off-pump CABG operations in our clinic for coronary artery disease and compare them.

Material-Methods:

This study included 1072 patients whom underwent CABG surgery at Cardiovascular Surgery Clinics of Akay Hospital between November 2010 and May 2014. 475 of these patients had off-pump and 577 of them had on-pump CABG surgery. 429 of the patients were female while 643 were male.

Results:

Preoperative characteristics of the groups according to operation types was similar ($p>0.05$). When operative data was analyzed, operation times seemed to be shorter and number of bypass grafts, number of bypass grafts between right coronary artery and posterior descending artery were smaller in the OPCAB group and this difference was statistically significant ($p<0.05$). Comparing the postoperative data shows that OPCAB group has developed lesser postoperative atrial fibrillation (POAF), needed lesser intubation, re-exploration, vasopressor medications, positive inotropics, intraaortic balloon pump, transfusion and stayed lesser in hospital and intensive care units, had lesser drainage, morbidity and mortality rates. These differences were also statistically significant ($p<0.05$).

Conclusion:

In our study we founded that OPCAB group had better postoperative results including morbidity, mortality and costs. In conclusion, we think that using OPCAB technique when it is possible is safer in chosen patient populations who need CABG surgery.

ID: 479**Topic: Cardiovascular Surgery » Coronary Bypass Surgery****Presentation Type: Oral****THE BENEFITS AND SIDE EFFECTS OF CORONARY
ENDARTERECTOMY****Deniz Özsoy, Özgü Özcan, Ismail Haberal***İÜ Cerrahpaşa Kardiyoloji Enstitüsü, İstanbul, Turkey***Corresponding Author (sdenizozsoy@hotmail.com)**sdenizozsoy@hotmail.com, oozcan@hotmail.com, drhaberal@hotmail.com*

Abstract Text**OBJECTIVE:**

Main purpose of coronary artery bypass graft surgery (CABG) is to accomplish the complete revascularisation. Endarterectomy is unavoidable in cases such as diffuse coronary artery disease, multiple narrowing on the same coronary artery and cases not suitable for anastomosis because of the calcific plaques. In this study we compared patients underwent endarterectomy during CABG without any coexisting cardiac diseases (n=103) and patients who underwent isolated CABG who also didn't have any coexisting cardiac problems (n=104). Our aim is to present the causes of early postoperative morbidity and mortality in the endarterectomy group.

METHODS:

In this study we compared two groups of patients in our institute; the first group consisted of 103 patients underwent endarterectomy during CABG with no additional surgical procedure or coexisting cardiac disease, the second group consisted of 104 patients who only had isolated CABG without any additional cardiac disease. We gathered the preoperative and postoperative data from both groups retrospectively and compared them according to statistical methods.

RESULTS:

There was not a statistical difference between two groups in terms of preoperative variables. 72,8% were male and 27,2% were female of the patients who underwent coronary endarterectomy. 5 patients died after endarterectomy procedure and total mortality was 4,9%. 3 of them were female and 2 were male. Mortality rate of the control group was 2,9%. Mortality rate of women in the study was 10,7% and that of men was 2,5%. Difference between mortality rate according to gender was statistically significant ($p<0,05$). 2,9% of patients in endarterectomy group had peroperative MI, control group didn't have any. All patients who had peroperative MI underwent open endarterectomy to their LAD arteries. Requirement for intraaortic balloon pump was 8,7% in endarterectomy group (n=9) and 1% in control group. This difference was found to be statistically significant ($p:0,009$). Average CPB time for patients who underwent coronary endarterectomy was $179,68\pm 50,74$ and average aortic cross clamp time was $105,26\pm 34,67$. In only CABG group the average CPB time was $139,88\pm 46,96$ and aortic cross clamp time was $79,75\pm 31,52$. Both CPB and aortic cross clamp time were significantly longer in endarterectomy group compared to only CABG group ($p; <0,001, <0,001$)

CONCLUSION:

In our opinion; with appropriate indication, analysis of preoperative risks and managing possible peroperative and postoperative situations; coronary endarterectomy should be performed to achieve complete revascularisation in diffuse coronary artery disease

ID: 474**Topic: Cardiovascular Surgery » Coronary Bypass Surgery****Presentation Type: Oral****PROS AND CONS OF STERNAL TALON AND TITANIUM STERNAL PLAQUE FIXATION IN PATIENTS WITH DEHISCED STERNUM****Omer Tanyeli, Mehmet Işık***Necmettin Erbakan University Meram Medicine Faculty, Konya, Turkey***Corresponding Author (otanyeli@gmail.com)**otanyeli@gmail.com, drmisik@hotmail.com*

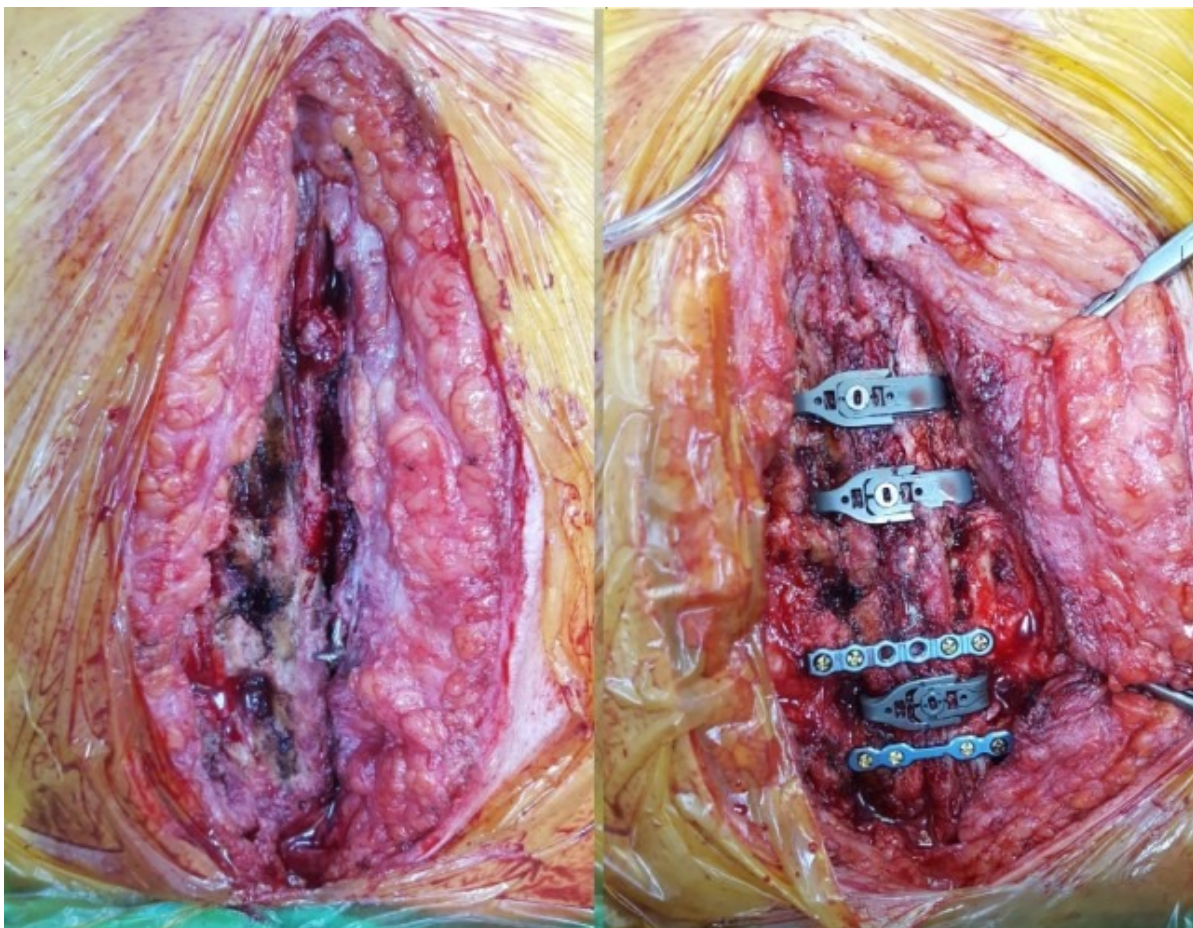
Abstract Text

OBJECTIVE: Sternal dehiscence is one of the most troublesome complications following cardiac surgery. Although it can be corrected by simple methods if detected earlier, treatment failure or delay in sternal dehiscence may result in mediastinitis, which is highly lethal. In this study, we aimed to investigate alternative sternal closure systems, mainly sternal talon and titanium sternal plaque.

METHODS: In between April 2015 and January 2018, patients with sternal dehiscence after any kind of open cardiac surgery were included in this study. These patients were retrospectively evaluated according to their demographic data, risk factors for sternal dehiscence, type of operations, techniques used for fixation of the sternum, mainly focusing on the sternal talon and titanium plaque fixation.

RESULTS: A total of 45 patients were taken into surgical correction because of sternal dehiscence. Thirty-four (75.6%) of the patients male, whereas 11 (24.4%) were female. Mean time interval after the first operation to sternal dehiscence was 68.5 days (1-780 days). Mean body-mass-index (BMI) was 31.52 kg/m² (22.03-43.69 kg/m²). Before the sternal fixation, mean CRP value was 64.24, whereas it was 75.55 before discharge. Confounding risk factors were IMA harvesting for coronary artery disease, diabetes mellitus, bronchial asthma, chronic pulmonary artery disease and advanced age. Mean post-operative ICU length-of-stay was 4.91 days (1-29 days), whereas hospital length-of-stay was 17.18 days (2-74 days). Early mortality rate was 6.67 % (3 patients). The first choice of operation was performed using simple closure and/or Robicsek closure. Apart from simple and Robicsek closure methods, sternal talon and/or titanium plaques were used in 24 patients (53.3 %). If the patients' sternum was intact with stable intercostal space, the choice of material was sternal talon. If the sternum was fractured and intercostal space was destructed, the choice of fixation was titanium plate fixation (Figure 1).

CONCLUSION: Sternal dehiscence is one of the most important complications of sternotomy following cardiac surgery. Accompanying comorbidities not only cause sternal dehiscence, but also limit recovery period. Ideal sternal closure should stabilize the sternum, be cost-effective and provide shortest hospital length-of-stay with minimal post-operative complications. Sternal reoperations should be evaluated as a kind of re-do cardiac surgery. In patients with intact intercostal spaces, sternal talon may eliminate serious complications, such as cardiac rupture mainly caused by dense adhesions. Sternal plaques are mainly effective in fragmented fractures without stable intercostal spaces. All patients should be individualized according to type of lesions.



ID: 407

Topic: **Cardiovascular Surgery » Coronary Bypass Surgery**Presentation Type: **Oral****THE RELATIONSHIP BETWEEN PREOPERATIVE VENTRICULAR DIAMETERS AND EARLY POSTOPERATIVE CARDIAC TAMPONADE****Safa Gode***Mehmet Akif Ersoy Thoracic and Cardiovascular Surgery Research and Training Hospital, Istanbul, Turkey***Corresponding Author (safagode@yahoo.com)**safagode@yahoo.com***Abstract Text**

Objective: Cardiac tamponade has an important role in heart surgery patients in terms of mortality and morbidity. In our study, we aimed to investigate the relationship between the development of early postoperative cardiac tamponade and preoperative left ventricular end diastolic diameter (LVEDD).

Methods: In this retrospective study, there were 20 patients that revised due to cardiac tamponade in early postoperative period between January 2016 and January 2018. In the same period, 103 patients who were operated and did not develop cardiac tamponade were selected by complete randomization method, thus non-tamponade group was created. All operation were performed by same surgery team. Cardiac tamponade was diagnosed clinically and supported echocardiographically. Computed tomography was performed to clarify the diagnosis of tamponade in three patients. Demographic data, clinical, echocardiographic and operative parameters were compared statistically between two groups.

Results: The mean age was 60.9 ± 7.79 in the cardiac tamponade group and 62.82 ± 9.92 in the non-tamponade group. LVEDD was 50.05 ± 5.45 mm in cardiac tamponade group and 46.34 ± 5.88 mm in non-tamponade group ($p = 0.009$). Therefore LVEDD was significantly higher in the cardiac tamponade group. Also, triglycerid level was significantly higher in cardiac tamponade group than non-tamponade group ($p=0.14$). There was no significant difference in terms of all other parameters in univariant analyses. The multivariate analysis was performed among the parameters that significantly differed in univariant analyses. Accordingly, there was no significant difference in terms of level of triglycerid; LVEDD was significantly higher in the cardiac tamponade group than non-tamponade group ($p = 0.007$). One patient passed away in the 7th day after the operation due to low cardiac output in the cardiac tamponade group. Also, three patients passed away due to pneumonia, sepsis and low cardiac output in the 17th, 34th and 9th days respectively in the non-cardiac tamponade group.

Conclusions: Increased LVEDD may be an additional risk factor in the development of cardiac tamponade in cardiac surgery patients besides the risk factors mentioned in the literature. In patients with large ventricular diameters, it may be necessary to be more careful in the early postoperative period for the development of cardiac tamponade.

Table : Univariant Analyses			
Tamponade group(n=20)	Non-tamponade group(n=103)	P	
Age, n±SS	60.9±7.7	62.8±9.9	0.415
Male, n %	11-%55	60-%61	0.807
Hypertension, n %	7-% 35	56-%57	0.113
Diabet,n %	8-% 40	44-%45	0.822
COPD, n %	3-%15	14-%14	0.867
Smoking, n %	10-%10	37-%37	0.447
BSA, kg/m ² n±SS	1.8±0.1	1.8±0.2	0.346
Preoperative antiplatelet,n-%	19-%95	96-%96	0.688
LDL,mg/dl n±SS	120.4±38.5	116.6±43.3	0.719
HDL, mg/dl n±SS	40±8	45.4±12.7	0.719
Total cholesterol, mg/dl n±SS	200±44	188.3±4	0.296
Triglycerid, mg/dln±SS	189±71.5	146.7±69.8	0.014*
Hemoglobin, mg/dl n±SS	13.6±1.8	14.5±3.3	0.284
Platelet, n-%	253.9±49.8	256±60.2	0.881
WBC, n±SS	9.4±1.7	8.7±1	0.793
Creatinin, mg/dl n±SS	0.9±0.2	1±0.6	0.482
LVESD mm	32.60±6	32.4±7.3	0.943
LVEDD mm	50±5.4	46.3±5.8	0.01*
RVEDD mm	47.3±6.3	46.7±5.9	0.66
RAD mm	38.4±4	36.6±4.8	0.122
LAD mm	37.7±5.3	37±4.8	0.539
ICU time, day	9.4±2.6	9.1±3.2	0.788
Entubated time, hour	9.4±2.6	9.1±3.2	0.789
Total drainage ml	835±542	799±536	0.785
CABG n %	12 %60	53 %53	0.896
AVR n %	3 %15	20 %20	
MVR n %	2 %10	3 %3	
AVR+CABG n %	1 %5	8 %8	
MVR+CABG n %	1 %5	8 %8	
AVR+MVR n %	1 %5	4 %4	
AVR+MVR+CABG n %	1 %5	3 %3	

ID: 444

Topic: **Cardiovascular Surgery » Coronary Bypass Surgery**Presentation Type: **Oral****OUR REPERFUSION STRATEGY IN THE PATIENTS WITH ACUTE MYOCARDIAL INFARCTION WHILE TERMINATING THE CARDIOPULMONARY BYPASS****Erhan Kaya, Amir Aghayev***Private Pendik Regional Hospital, Istanbul, Turkey***Corresponding Author (drerhankaya@yahoo.com)**drerhankaya@yahoo.com, amiragayev14@yahoo.com***Abstract Text**

Objective: The main principle of myocardial protection strategies in heart surgery is to reduce myocardial energy consumption. Prolonged ischemia and insufficient myocardial protection during operation might cause myocardial damage. Myocardial damage might be avoided with cardioplegia and hypothermia. In this study, we are reporting our reperfusion strategy with hypothermic, reduced calcium cardioplegia that given low pressure in the patient with recent myocardial infarction. In this study, we report our experience of patients who had recently myocardial infarction with low-pressure delivery of cold cardioplegia that include reduced calcium content.

Methods: The patients who were operated with diagnosed of acute myocardial infarction, between January 2007 and November 2008, were examined retrospectively. In this period, proximal anastomoses were performed under cross clamp in patients who were operated with the diagnosis of AMI. After the patient's temperature was decreased to 22°C and proximal anastomoses were completed, reperfusion was started by opening the cross clamp. Following reperfusion with 2 min with 20 mmHg; 2 min with 30 mmHg; 2 min with 40 mmHg pressure; rewarming was started. Cardiopulmonary bypass (CPB) was terminated when the patient was warmed and hemodynamical stability was gained. Postoperative follow-up data of the patients were examined.

Results: In the study period, 44 patients, who had operated with AMI, underwent reperfusion that we determined. The mean age of the patients was 56 and 66% were male. The mean number of distal anastomoses was 4, and 4 patients required intra-aortic balloon pump for hemodynamic stability. There was no surgical mortality, and one patient died on the 35th postoperative day.

Conclusions: Myocardial energy reserve is decreased in the patient with AMI. Myocardial tissue is highly sensitive and cannot respond to sudden changes. Increasing the energy delivery during the surgery and slowly increasing the need for myocardial energy supply can improve the outcome of the operation.

ID: 378

Topic: **Cardiovascular Surgery » Coronary Bypass Surgery**Presentation Type: **Oral****ON-PUMP BEATING-HEART CORONARY ARTERY BYPASS GRAFTING
IN PATIENTS WITH LEFT MAIN CORONARY ARTERY DISEASE****Daniil Borisov, Aleksandr Zotov, Aleksandr Troitskiy, Robert Khabazov***Federal Research Clinical Center for Specialized Types of Health Care and Medical Technologies, Moscow, Russia***Corresponding Author (dan-cer@inbox.ru)**dan-cer@inbox.ru, tired.romantic@gmail.com, dr.huyancer2@yandex.ru, dr.huyancer3@yandex.ru***Abstract Text****Background**

On-pump beating heart technique has been successfully used in high-risk patients (patients with unstable angina, acute myocardial infarction, decreased left ventricular ejection fraction, chronic kidney disease). However, the use of this technique in stable patients with left main coronary artery disease is not well thoroughly evaluated. This study aimed to evaluate the impacts of conventional coronary artery bypass grafting (CABG), on-pump beating-heart CABG and off-pump CABG for surgical revascularization on early and mid-term clinical outcomes in stable patients with left main coronary artery disease.

Methods

237 consecutive patients with significant left main stem stenosis (>50%) who underwent non-emergency, primary CABG from January 2014 to December 2017 were included in this study and divided into 3 groups: a conventional CABG group (cardiopulmonary bypass, aortic cross-clamping and cardioplegic arrest, n = 135), an OFF-PUMP group (off-pump CABG, n = 45) and an ON-BEAT group (on-pump beating-heart CABG, n = 57). There was no statistically significant difference among three groups with respect to age, history smoking, cerebrovascular disease, sex, hypertension, peripheral artery disease, body mass index, hyperlipidemia, unstable angina, number of diseased vessels, diabetes mellitus, arrhythmia. The early and midterm clinical outcomes were investigated and compared. Data is presented as the median and interquartile range.

Results

On-pump beating-heart technique showed better revascularization rates (comparing to off-pump technique). However, the need for blood product transfusion and length of hospital stay were significantly ($P < 0.001$) higher in the ON-BEAT group than in the conventional and off-pump groups. No significant differences were found regarding intensive care unit stay, 30-day mortality and morbidity rates including stroke, pneumonia, arrhythmia, intestinal complication and low cardiac output syndrome. There were no statistical differences in the freedom from cardiac events and mid-term survival.

Conclusion

On-pump beating-heart technique provides better myocardial revascularization (comparing to off-pump technique), but use of this technique in stable patients with left main coronary artery disease is limited by increased need for blood product transfusion and prolonged hospital stay.

Characteristic	Conventional CABG	Off-pump CABG	On-pump beating heart CABG	P-value	G1 vs G2, P-value	G1 vs G3, P-value	G2 vs G3, P-value
Number of anastomoses per patient	3,0 (3,0; 4,0)	3,0 (2,0; 3,0)	3,0 (3,0; 3,0)	<0,0001	0,0009	<0,0001	0,0389
Need for blood product transfusion	2 (1,5%)	0 (0,0%)	5 (9,1%)	0,009	1,000	0,023	0,0062
Hospital stay, days	8,0 (7,0; 11,0)	9,0 (8,0; 11,0)	9,0 (8,0; 12,0)	0,0098	0,717	0,0321	0,0081

ID: 371

Topic: Cardiovascular Surgery » Coronary Bypass Surgery

Presentation Type: Oral

PROLONGED MECHANICAL VENTILATION AFTER ON PUMP CORONARY ARTERY BYPASS: PREDICTOR FACTORS

Mazlum Şahn¹, Corç Baytaroğlu²¹Haseki Education and Reseach Hospital, Istanbul, Turkey²Özel Avcılar Hospital, Istanbul, Turkey

*Corresponding Author (mzlmshn@gmail.com)

mzlmshn@gmail.com, mzlmshn@gmail.com

Abstract Text

OBJECTIVE: The aim of this study is to determine the predictors of prolonged mechanical ventilation by examining the perioperative data of patients undergoing coronary artery bypass grafting (CABG) surgery.

METHODS: 492 patients who underwent CABG surgery between December 2014 and September 2017 were retrospectively reviewed. Patients with a mechanical ventilation requirement > 12 hours were included in Group 1 (n = 37), and those with <12 hours were included in Group 2 (n = 455).

For statistical analysis, Social Science Statistics Package for Windows (SPSS) version 20 was used. Categorical variables were presented as number and percentage and compared with the Chi-Square test. Continuous variables were presented as mean and standard deviation and compared with independent sample t test. Correlation analyzes were evaluated using Pearson correlation coefficient. When the two-way p value was <0.05, attention was paid to the statistical significance.

RESULTS: Only hypertension (HT) was found to be significantly higher in group 1 patients (p = 0.013). In Group 1, postoperative bleeding revision, intraaortic balloon pump (IABP) use, and high syntax 2 score were significantly longer than Group 2 (p <0.05). Acute renal failure, length of hospital stay, duration of hospital stay, mediastinitis and mortality were higher in patients who were intubated for more than 12 hours (p <0.05).

CONCLUSION: In our study, the presence of preoperative HT after CABG, postoperative bleeding revision, IABP use, and high syntax 2 score were found to be strong predictors of prolonged mechanical ventilation.

ID: 369

Topic: **Cardiovascular Surgery » Coronary Bypass Surgery**Presentation Type: **Oral****NEGATIVE CORRELATION BETWEEN BODY MASS INDEX AND CHEST TUBE OUTPUT AFTER CORONARY ARTERY BYPASS GRAFTING**Mehmet Aksüt¹, Ekin Can Çelik², Deniz Günay¹¹*Istanbul Kartal Kosuyolu Training and Research Hospital, Istanbul , Turkey*²*Şırnak State Hospital , Şırnak, Turkey***Corresponding Author (bbmaksut@yahoo.com)**bbmaksut@yahoo.com, ekincancelik@gmail.com, md.dnznny@gmail.com***Abstract Text**

OBJECTIVE: Obesity is a well-known and obvious threat for humanity but some contradictory outcomes have been encountered during previous medical research. Interestingly, obesity was recognized as a protective factor for some specific obesity related situations. We aimed to show the relation between increased Body Mass Index (BMI) and chest tube output after coronary artery bypass grafting (CABG).

METHODS: We retrospectively collected data of 421 patients underwent isolated CABG surgery between dates of December 2015 and December 2016. Patients with previously known coagulopathy, emergency operations and re-operations were excluded due to increased bleeding and increased need for blood transfusion rates. Additionally, we excluded off-pump CABG cases. Obtained BMI values were grouped into classes, determined by AHA and World Health Organization, which were; underweight (<20kg/m²), normal weight (20 – 25 kg/m²), overweight (25 - 30 kg/m²), obese (30 - 35 kg/m²) and severely obese (>35 kg/m²). Postoperative chest tube output volume corresponded drainage at first twenty four hours after CABG surgery.

RESULTS: Mean age was found 61, 6 (± 1, 06) years. Female to male ratio was found 40, 9/59, 6 (n=170/251). Mean ejection fraction of the patients was 55, 3% ± 10, 4. Only 7, 1% of the patients (n=30) underwent surgery under unstable hemodynamic circumstances like need for positive inotropic agents and/or need for intraaortic balloon pump support. Mean total perfusion duration was 80 ± 31 minutes and mean cross clamping duration was 59 ± 26 minutes. After CABG mean ICU stay was 2, 9 ± 2, 7 days, mean hospital stay was 9, 1 ± 5, 1 days. 27 patients (6, 4%) underwent re-sternotomy for bleeding. Early mortality rate after surgery (first 30 days) was 4, 5% (n=19). Patient population was divided into 2 groups as BMI below and above 30 kg/m² to coarsely evaluate the relation between BMI and chest tube output. 193 patients were in non-obese group and 136 patients were in obese group. Mean drainage amounts of non-obese and obese groups were 630 ± 360 milliliters and 463 ± 303 milliliters respectively. We ran independent t- test to evaluate the relation between BMI and chest tube output. It was statistically significant. We decided to evaluate the relation between drainage and five different BMI subgroups. ANOVA showed, statistically significant chest tube output difference between normal and obese groups, as well as severely obese group

CONCLUSIONS: In this study we showed that BMI is negatively correlated with bleeding after CABG surgery. This result may help surgeons at predicting bleeding after surgery in their daily practice. To increase the efficacy and validity of this concept, BMI should be included in future bleeding prediction systems.

Oral Presentations

Progress In Valvular Surgery

Date: 30.03.2019 Time: 13:15 - 14:15 Hall: 6

ID: 351

Topic: **Cardiovascular Surgery » Diagnosis and Treatment of Valvular Heart Disease**

Presentation Type: **Oral**

3-YEAR RESULTS OF THE IMPLANTATION OF A NEW FULL-FLOW MECHANICAL HEART VALVE PROSTHESIS MEDINZH-ST

Mihail Lepilin, Valerij Tsehanovich

Regional Clinical Hospital , Omsk, Russia

**Corresponding Author (mixei91@yandex.ru)*

mixei91@yandex.ru, mixei91@yandex.ru

Abstract Text

3-year results of the implantation of a new full-flow mechanical heart valve prosthesis MedInzh-ST

Mihail Lepilin, Valerij Tsehanovich

Regional Clinical Hospital of the Omsk, Regional Cardiovascular Center, Department of Cardiac surgery.

BACKGROUND. To present the results of evaluation of clinical and hemodynamic parameters of full-flow prosthetic aortic valve MedInzh-ST in the single-center prospective clinical study.

METHODS. Between August 2015 and December 2018, 62 patients (82% males) underwent isolated MedInzh-ST aortic valve replacement. The most common reason for surgery was degenerative valve disease (35%), followed by rheumatic valve disease (25%) and infective endocarditis (20%). Average age at implant was 58.2 years. Stenosis was observed in 56% (mean gradient- 58 mm Hg), insufficient grade 3-4 in 26%. 67 percent of patients before surgery had a higher functional class of heart failure. 46 patients were examined after 3,6,12 months after surgery.

RESULTS. Operative mortality in patients undergoing surgery for implantation of the prosthesis MedInzh-ST is not revealed. The 30-day period after the operation was recorded 1 death for a reason not related to the function of the valve. Mean transaortic gradient at discharge was $12,1 \pm 3$ mmHg, mid-term period to $10,3 \pm 3,4$ mmHg. Most patients after aortic prosthetics in the mid-to-late postoperative period switched to the I and II functional class of heart failure according to the NYHA classification (80%), 20 % of patients remained in the third functional class.

There were no cases of hemolysis, thrombosis, thromboembolism, neurological complications during the follow-up.

CONCLUSIONS. Clinical and hemodynamic parameters in the near and mid-term postoperative period make it possible to evaluate the functioning of the full-flow mechanical prosthesis MedInzh-ST in the aortic position.

ID: 217

Topic: **Cardiovascular Surgery » Diagnosis and Treatment of Valvular Heart Disease**

Presentation Type: **Oral**

THE EFFECT OF TRANSFUSION ON HOSPITALIZATION TIME IN PATIENTS WITH ISOLATED VALVE REPLACEMENT

Mehmet Kalender

Kocaeli Derince Training and Research Hospital, Kocaeli, Turkey

**Corresponding Author (ka97084@yahoo.com)*

ka97084@yahoo.com

Abstract Text

Introduction

Although there are increasing numbers of reports advocating transfusion related rise in postoperative mortality and morbidity, blood product transfusion is almost inevitable during open heart surgery. Blood transfusion in cardiac surgery patients may cause mortality although under specific conditions it is a life saver. In this particular report we have studied perioperative transfusion and hospital stay duration in isolated heart valve replacement procedure applied patients. . In our study, we examined the effect of blood product transfusion on hospitalization time in patients who underwent isolated valve operation.

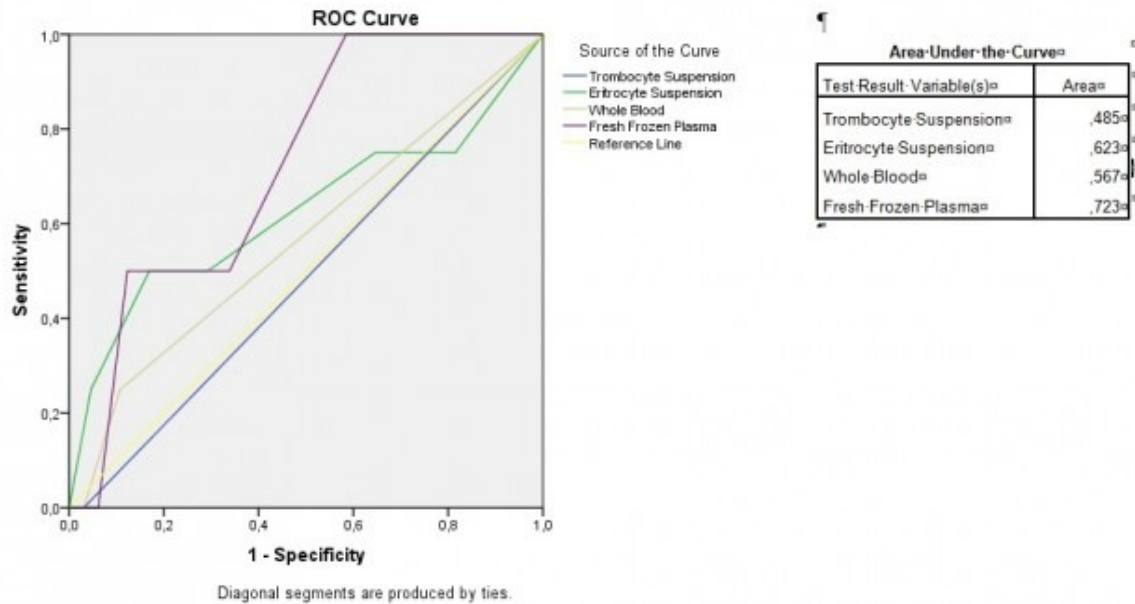
Materials and Methods

From October 2012 to October 2018 isolated valve replacement operation applied 69 patients (34 female) included to study. Redo operated patients, infective endocarditis patients and in hospital mortality observed patients were excluded. Target hematocrit levels during cardiopulmonary bypass were (HTC) 20-25% and post cardiopulmonary bypass target hematocrit levels were 25-30%. During postoperative follow up if patients had symptoms due to anemia transfusion provided. Otherwise postoperative target lowest hemotocrit level was 26%. Fresh frozen plasma used either for volume expansion and correction of coagulopathy. Correction of anemia we have only used erythrocyte suspension. Planned ICU stay was 2 days and inwards follow up was 5 days.

Results

A total of 137 patients participated in this study. Of those 35 were male (50.7%). Mean age of study group was 60.65±10.86 years ranging 33-86 years. We observed mortality in 4 (5.8%) patients during follow up. Mean ICU stay was 5.01±3.71 days (range 1-18 days) and mean postoperative inward follow up was 6±2.92 days (range 1-18 days) Perioperative 0.5 pack or more transfusion of fresh frozen plasma 50% specifically and 76.4% sensitivity to expect increased hospital stay. Perioperative 0.5 pack of Erythrocyte Suspension has 78.6% specifically and 81.8% sensitivity to expect increased hospital stay.

Perioperative transfusion has negative effect on hospital stay. As such necessary precautions should be taken to avoid transfusion.



ID: 313

Topic: **Cardiovascular Surgery » Heart Valve Repair**Presentation Type: **Oral**

LEFT VENTRICLE RESTORATION IN END STAGE ISCHEMIC DILATED CARDIOMYOPATHY

Zivojin Jonjev

Institute for Cardiovascular Diseases of Vojvodina, Sremska Kamenica, Serbia

**Corresponding Author (jonjevz@gmail.com)*

jonjevz@gmail.com

Abstract Text

Objective:

Patients with end stage ischemic dilated cardiomyopathy (IsDCM) exhibit extensive remodeling of the left ventricle, and significant mitral and tricuspid regurgitation. We investigated if implantation of the artificial mitral valve with preservation of the native mitral valve could be used as a method combined with tricuspid annuloplasty and complete myocardial revascularization in end stage IsDCM.

Materials and Methods:

There were 31 patients (26 males, 5 females) with end stage IsDCM (NYHA III/IV). All patients had significant mitral and tricuspid regurgitation, mean ejection fraction below 30% ($25.6 \pm 3.1\%$), and mean left ventricle end-diastolic internal diameter greater than 7.0 cm (7.3 ± 0.3 cm) with coaptation depth of the mitral valve significantly greater than 1.1cm (STS "risk of mortality" score= $22.04 \pm 1.5\%$;

Euroscore II=7.04 ±1.02). In addition to complete myocardial revascularization biological or mechanical artificial valve was implanted in 27 and 4 patients respectively. Modified De Vega tricuspid annuloplasty was performed in all patients.

Results:

There was no postoperative 30-day mortality. Significant reverse remodeling of the heart was achieved measured by decrease of the endsystolic sphericity index (84.2% vs 68.9%) and improved ejection fraction (26.6% vs 32.6%). Clinical status of the patient was significantly improved immediately after procedure, and was stable 12 month after surgery. Long term results showed survival rate after 5 years of 83.33%.

Conclusions:

Reverse remodeling of the left ventricle with implantation of the artificial mitral valve, suture annuloplasty of the tricuspid valve and complete myocardial revascularization could be successfully applied in patients with end stage IsDCM. Our method should not be recognized as a valve repair, but ventricular repair as well and could be used as a bridge to heart transplantation or even destination therapy in selective patients.

ID: 513

Topic: Cardiovascular Surgery » Diagnosis and Treatment of Valvular Heart Disease

Presentation Type: Oral

ADVANTAGE AND DISADVANTAGE OF THE SUPERIOR SEPTAL APPROACH FOR MITRAL VALVE SURGERY WITH SMALL LEFT ATRIUM

Birol Yamak¹, Serkan Ketenciler², Murat Ercişli³, Özerdem Özçalışkan¹

¹Gaziantep Medical Park Hospital, Gaziantep, Turkey

²SBU Okmeydanı EAH, İstanbul, Turkey

³Adiyaman University, Adiyaman, Turkey

**Corresponding Author (birolyamak@gmail.com)*

birolyamak@gmail.com, ketencilers@hotmail.com, mercisli@gmail.com, ozerdemoz@gmail.com

Abstract Text

Objective: Left atrial approach for mitral valve surgery is the main entrance way to reach left atrium inside. But, mitral valve accessibility is an important issue in patients with deeper thorax and small left atrium cavity. Surgical exposure may be insufficient for small left atrium with left atrial approach. The alternative way to reach left atrium is superior septal incisions. It created by two cardiotomy incisions, one is opening the right atrium wall and second one atrial septum incision that widened through left atrial dome. So mitral valve surgical exposure is well done. In this study, we present to superior septal approach to reach mitral valve surgery and concomitant additional procedures.

Methods: We evaluated totally 343 patients that had mitral valve surgery and/or additional procedures between 2001 and 2018. The patients had isolated mitral valve surgery and concomitant additional procedures like aortic or tricuspid valve surgery, coronary artery bypass grafting

added to study if the mitral valve exposure was by the superior septal approach. Transient and permanent rhythm disorders, early mortality examined at the postoperative period.

Results: Superior septal approach was used totally 343 patients, average age was 56.3 years, 158 patients male and 185 were female, 215 of them were isolated mitral valve surgery, remind of them were 128 patients had concomitant procedures like aortic or tricuspid valve surgery, coronary artery bypass grafting and other procedures. In the early postoperative period, transient rhythm disturbances were seen 10 % of the patients. Permanent rhythm disorders was also seen but not higher than classical left atrial approach procedure. Hospital mortality was 3.7.

Conclusions: Superior septal approach is an alternative way to reach mitral valve for the patient with small left atrium and deeper thorax cavity. It is easy and safe method to enhance mitral valve visibility if it performed properly. We consider that it reduces operative durations and not increase the rate of permanent rhythm disorders unlike the classical method.

ID: 499

Topic: Cardiovascular Surgery » Diagnosis and Treatment of Valvular Hearth Disease

Presentation Type: Oral

LONG-TERM THERAPEUTIC RESULTS AFTER SURGICALLY TREATED INFECTIVE ENDOCARDITIS

Adrian Molnar, Diana Sacui, Emese Kovacs, Ruxandra Beyer, Catalin Trifan

Heart Institute, Cluj-Napoca, Romania, Cluj-Napoca, Romania

**Corresponding Author (adimolnar45@yahoo.com)*

adimolnar45@yahoo.com, diana_sacui27@yahoo.com, emekovacs@yahoo.com, anda_bogdan@yahoo.com, catalin_trifan2000@yahoo.com

Abstract Text

Background: This study analyses the impact of surgery for infective endocarditis (IE) and its effects on the long-term prognosis.

Methods: A total number of 218 patients were operated for IE in our service during a ten-year period (between January 1st, 2008 and September 30th, 2017). The medical records of all patients were retrospectively reviewed for the demographic data, co-morbidities, and risk factors. Before operation, lesion extension was appreciated by echocardiography (trans-thoracic and/or trans-esophageal), and secondary systemic lesions were evaluated by CT-angiography. The main indications for surgery were progressive congestive heart failure, untreatable sepsis, peripheral or central emboli, and echocardiographic evidence of large, friable vegetation -progressive congestive heart failure. In the last five years, the indication for emergency operation was established according to the latest European Society of Cardiology (ESC) guidelines. All reachable patients who agreed to participate in this study were clinically and echocardiographically assessed for a minimum of 6-months period after intervention.

Results: Patients' age ranged between 11 and 84 years, with an average of 55.4 ± 14.3 (SD) years. Early post-operative mortality was 11%, and we tried to identify the independent predictors for it among the risk factors. In the group of patients who survived the first 30 days after intervention and agreed to participate in the study (N =169), long-term (minimum 6 months) survival was 95.3%. We also analyzed the independent predictors of survival.

Conclusions: Early (emergency or urgency) surgery for IE provides a good chance for a cure and a satisfactory long-term survival. The advances in pre- and post-operative management of IE patients, as well as in surgical techniques and prosthetic valves seem to further improve the long-term results.

ID: 324

Topic: Cardiovascular Surgery » Diagnosis and Treatment of Valvular Heart DiseasePresentation Type: **Oral****A CASE OF RECURRENT PNEUMONIA DUE TO LEGIONELLA PNEUMOPHILA FOLLOWING AN EPISODE OF COMPLICATED INFECTIVE ENDOCARDITIS**Nazmi Gultekin¹, Emine Kucukates¹, Samet Solmaz¹, Ilker Inanç Balkan², Ahmet Yıldız¹, Ismail Haberal¹¹Istanbul University Cardiology Institute, Istanbul, Turkey²Istanbul University Cerrahpasa Medical Faculty, Istanbul, Turkey

*Corresponding Author (nngultekin@yahoo.com)

nngultekin@yahoo.com, eates2002@yahoo.com, solmazsamet7@gmail.com, ilkerinancbalkan@hotmail.com, dryildiz@yahoo.com, doktorhaberal@hotmail.com

Abstract Text

Objective: Legionella pneumophila infection can cause Legionnaires' disease, a recurrent form of pneumonia. Extrapulmonary manifestations of Legionella infections include myocarditis, pericarditis, and endocarditis(1,2). We present a rare case of pneumonia caused by Legionella pneumophila with a possible etiologic link to a recently recovered culture-negative infective endocarditis.

Case Report: A 53-year-old male patient that often travels abroad was admitted to our unit with high fever, excessive sweating, weakness, edema, ascites, orthopnea, hepatomegaly, venous fullness, and crepitant rales up to the middle zones in both hemithorax. The patient has been under follow up with diabetes mellitus and ascending aorta dilatation for three years in our clinic. He underwent coronary angiography at another center, in April 2018. In TTE and TEE examination, in the mitral valve, vegetation that adhering on both leaflets was observed that it was 2.5x2 cm in the amorphous structure, but not clear in diameter that enters and exit into the left ventricle. It had caused third degree of mitral regurgitation(Figure 1 A-C, Video 1,2). Blood cultures were obtained in endocarditis protocol and remained negative for seven-day incubation period. He was accepted as infective endocarditis and treated empirically with vancomycin, ceftriaxone, gentamicin in combination. Routine therapy was given for heart failure. He was unresponsive to anti-bacterial treatment. Consequently he underwent surgery for mitral valve replacement, tricuspid annuloplasty and aortic valvuloplasty due to refractory fever and heart failure, on 10 May 2018(Figure 2-A). Blood cultures were repeated and extirpated mitral valve with operation sent microbiological examination. Both of them microorganisms did not grow. We could not detect the agent of infective endocarditis. On the postoperative 12th day, the patient who had shortness of breath was revised and the hematoma was evacuated. After 10 days, pleural effusion of him was drained with pleurocan device. The patient's complaints persisted and fixation of persistent opacity was detected on the chest X-ray and thorax CT was performed on the PA chest X-ray appearance. Decortication was performed on 10.08.2018 with Video-Assisted Thoracoscopic Surgery (VATS) operation on left pleural thickening. The patient's complaints persisted. The patient's symptoms were thought to be related to amlodipine in the form of anasarca edema and weight gain and this drug have been removed from therapy. The patient rapidly recovered and was sent home with routine treatment. Afterwards, the patient, who was in good condition until 25.10.2018, applied to the department of infectious diseases with recurrent pneumonia table showing cough, side pain severe dyspnea, fever, cough and side pain after new travel abroad(Figure 2 B). Urinary antigen test for Legionella pneumophila serogroup 1 was detected positive and Levofloxacin / Piperacillin/tazobactam was administered. Partial improvement was observed and he was discharged home with oral antibiotherapy (Cefixime 400 mg). Currently, the patient is alive in good condition.

Conclusion: We can retrospectively presume that the previous episode of complicated endocarditis may also have been related to Legionella which was neither included in etiological work-up nor in the empirical treatment.

Oral Presentations

Valve Surgery In Different Patient Groups

Date: 30.03.2019 Time: 14:15 - 15:15 Hall: 6

ID: 380

Topic: **Cardiovascular Surgery » Diagnosis and Treatment of Valvular Heart Disease**

Presentation Type: **Oral**

EUROSCORE IS THE ONLY PREDICTOR FOR EARLY MORTALITY AFTER AORTIC VALVE REPLACEMENT IN MIDDLE AGED RHEUMATIC PATIENTS.

Sameh Sersar¹, Essam Hassan²

¹Mansoura University; Egypt, Mansoura, Egypt

²Tanta University; Egypt, Tanta, Egypt

**Corresponding Author (sameh001@yahoo.com)*

sameh001@yahoo.com, sameh001@yahoo.com

Abstract Text

Introduction and aim of the work:

Emergency AVR is a strong predictor of early mortality in some meta analyses. Euroscore can give a good idea about the mortality after cardiac surgeries. We aimed to review our experience in AVR and determine the early mortality predictors.

Patients and Methods:

We collected the data of two hundreds of rheumatic patients who had surgical standard AVR in 2 centres in Saudi Arabia in the last 2 years. Median sternotomy and cardiopulmonary bypass were used. We used 15 types of AV prostheses.

Results:

Our study included 200 cases including 120 mechanical AVR. There were 130 males and 70 females. Twenty cases were redo. 8 were 2nd redoes. We used 15 different prostheses. F up Echoes were done in ICU, on discharge and 1 month after discharge. Nine patients died in the early postoperative period(6 months). Statistical analysis showed Euroscore as the only significant predictor of early mortality.

Conclusion

Euroscore is a good predictor for risk stratification for cases of AVR in rheumatic patients.

ID: 468

Topic: **Cardiovascular Surgery » Diagnosis and Treatment of Valvular Heart Disease**

Presentation Type: **Oral**

CLINICAL EXPERIENCE OF AORTIC VALVE SURGERY IN AORTITIS PATIENT

Jun Pan, Yunxing Xue, Dongjin Wang

The Affiliated Drum Tower Hospital of Nanjing University Medical School, Nanjing, China

**Corresponding Author (xyxkakashi@163.com)*

xyxkakashi@163.com, albert_xue@163.com, dongjinwang_gl@163.com

Abstract Text

Background: Aortic valve surgery is complicated in patients with aortitis diseases. High incidence of perivalvular leak and secondary redo surgical treatment urges more attention to perioperative treatment of this type of disease. This clinical research retrospectively analyzed the type of lesions, surgical procedures, and follow-up results of aortic valve surgery in aortitis patient.

Method: From January 2010 to December 2018, 17 patients with aortitis disease were treated in our center. Among them, there were 9 males and 8 females with an average age of 55.5 ± 6.4 years. Eight patients (42.8%) were diagnosed as arteritis and 9 patients (57.2%) were diagnosed as Behcet's disease. The mean preoperative aortic regurgitation was 3.5 ± 0.8 (0-4) and aortic stenosis was 0.4 ± 0.7 (0-4). The average diameter of ascending aorta was 44.0 ± 17.0 (29-70) mm, and the mean preoperative EF was 46.7 ± 7.0 (31-55)%. In patients with vascular inflammatory disease, aortic valve replacement is performed specifically. The annulus suture is inserted from the outside of the vessel wall, the spacer is placed outside the vessel wall, and the felt strip is reinforced on the outside of the annulus.

Results: There were 2 cases of aortic valve replacement, 10 cases of aortic valve root replacement (Bentall), and 5 cases of aortic valve repair. The average cardiopulmonary bypass time was 259.1 ± 99.1 min, and the mean aortic clamp time was 183.4 ± 76.6 min. Perioperative mortality was 17.6% (3/17), with an average follow-up of 37.3 (5-90) months, and 1 patient died during the follow-up period (7.1%, 1/14). The incidence of redo surgery was 14.3% (2/14). One patient underwent redo Bentall procedure for a pseudoaneurysm of the root. One patient underwent redo aortic valve replacement for aortic valve prolapse after a surgical aortic valvuloplasty.

Conclusion: Cardiac surgery with aortitis is more common, but most are not diagnosed. Behcet's disease aortic valve replacement has a high proportion of secondary interventions, and the preferred root replacement (Bentall) surgery. For patients with complex vascular inflammatory disease / Behcet's disease, special surgical techniques can be used to reduce the risk of prosthetic valve detachment.

ID: 311

Topic: **Cardiovascular Surgery » Research**Presentation Type: **Oral****AN ASSESSMENT OF THE 100 MOST FREQUENTLY CITED ARTICLES REGARDING BICUSPID AORTIC VALVE IN THE LITERATURE****Tugra Gencpinar¹, Serdar Bayrak¹, Cagatay Bilen², Sibel Buyukcoban¹, Volkan Hanci², Gokmen Akkaya¹***¹Dokuz Eylul University Faculty of Medicine, İzmir, Turkey**²Ege University Faculty of Medicine, Izmir, Turkey***Corresponding Author (tugra01@yahoo.com)**tugra01@yahoo.com, sibelbuyukcoban@yahoo.com, cagataybilen86@hotmail.com, isik.ceren@hotmail.com, akkayagokmen@gmail.com, volkan.hanci@deu.edu.tr***Abstract Text****An assessment of the 100 most frequently cited articles regarding bicuspid aortic valve in the literature**

Objective: In this study, we aimed to evaluate 100 articles pertaining to bicuspid aortic valve (BAV) which are the most frequently cited in the literature.

Methods: The study was performed by 'advanced mode' of the search engine server "Institute for Scientific Information (ISI) Web of Science (WOS)". For this aim "TS=bicuspid or TI=bicuspid" words were reviewed. The search was carried out in 14.06.2018 then the 100 most cited articles were determined. Total and annual cite count for each article and information about the authors and the journals were determined via WOS and PubMed.

Results: The mean cite count of the 100 most cited articles was measured as 238,10±227,48. The annual cite counts of the studies were varying from 4 to 185 and the mean value was calculated as 20,93±25,25. When focus of the the 100 most cited article about BAV was considered, the first three steps were consisted of clinical (41%), pathology (15%) and genetics (15%) respectively. There was no statistically significant difference between the continent of the corresponding author and overall and annual cite counts and the journal's continent and overall and annual cite counts ($p>0,05$).

Conclusion: This study has the feature of to be the first study which identified and analyzed the 100 most cited article regarding BAV. The majority of these studies are based on clinical evaluation of the BAV. We investigated an increase in studies concerning percutaneous transcatheter interventions over the last five years.

Keywords: Bicuspid aortic valve, citation analysis, first 100, aortic aneurysm, aortic stenosis

ID: 94

Topic: **Cardiovascular Surgery » Diagnosis and Treatment of Valvular Heart Disease**

Presentation Type: **Oral**

THE ADVANTAGES OF SUTURELESS AORTIC VALVE AT THE MINIMALLY INVASIVE SURGERY

Bilal Perçin¹, Hakan Saçlı²

¹*Sakarya University Research and Training Hospital, Sakarya, Turkey*

²*Sakarya University Medical Faculty, Sakarya, Turkey*

**Corresponding Author (bilalpercin@gmail.com)*

bilalpercin@gmail.com, mdhakans@yahoo.com

Abstract Text

Objective: It is aimed to evaluate the advantage of use of sutureless aortic valves between classic median sternotomy and mini-sternotomies at the aortic valve replacement surgery.

Method: Between January 2016 and December 2018, 46 patients with isolated aortic valve stenosis who were candidates for aortic valve replacement with the appropriate indications were randomized. The patients were operated by same surgical team. Group 1 were operated via classic median sternotomy. Mini sternotomy was used in group 2 patients. Three patients who had needed more than aortic valve intervention or replaced other than sutureless valve were excluded from the study. The patients were compared in terms of x-clamp time, total CPB time, extubation time, intensive care unit stay, hospital stay.

Results: Group 2 had a shorter x-clamp and CPB times than group 1. It was not statistically significant ($p>0.5$). But group had the advantage of shorter intubation time, shorter intensive care unit stay and shorter hospitalization time. All three parameters were statistically significant ($p<0.5$).

Conclusion: The use of sutureless aortic valves has the potential to simplify the procedure, by avoiding the need to suture the aortic valve to the annulus through a small incision and limited surgical field. It is likely that reduction in operative times using sutureless prostheses, may record further improvements in results, particularly in critically ill patients at the highest operative risk. Sutureless aortic prostheses will be increasingly used to facilitate the advantages of the minimally invasive approach without the detrimental caveats of increased cross-clamp and CPB durations and with short intensive care unit and hospital stay.

Keywords: Sutureless aortic valve, sternotomy, minimally invasive.

Table1

	Group1	Group2	P value
Extubation time (hr)	8±4	4±2	<0.5
ICU Stay (day)	2±5	8±4	<0.5
Hospital stay (day)	7±3	3±2	<0.5

ID: 162

Topic: **Cardiovascular Surgery » Diagnosis and Treatment of Valvular Heart Disease**

Presentation Type: **Oral**

PREMATURE STRUCTURAL DEGENERATION OF THE TRIFECTA AORTIC BIOPROSTHESIS IN MID-TERM FOLLOW-UP: A LARGE SINGLE-CENTRE EXPERIENCE

Hassan Kattach

University Hospital Southampton, Southampton, United Kingdom

**Corresponding Author (hassan_kattach@yahoo.co.uk)*

hassan_kattach@yahoo.co.uk

Abstract Text

Background

A cluster of aortic bioprosthetic valve failures, most of which were Trifecta bioprostheses, was observed in a single institution in the UK. This study was performed to assess if the cluster represents a significant failure of this valve model.

Methods

We conducted a retrospective analysis of all bioprosthetic aortic valve replacement operations (isolated or with concomitant procedures) performed in our institution between 2011–2016 inclusive. Patient-related and valve-related risk factors for early valve failure were analysed. In addition, a comparison of the performance of Trifecta with Perimount Magna Ease (PME) bioprostheses was performed.

Results

A total of 2807 bioprosthetic aortic valve replacements were performed (1728 (62%) men, mean age 74.6±3.5 years, mean follow-up 4.2±4.3 years). Of these, 837 were Trifecta valves. 15 (1.8%) patients suffered premature failure requiring re-intervention. Mean failure size was 21.8±1.8mm. At the time of failure, 10/15 (66%) of the failed valves had significant regurgitation and the average peak gradient was 60 ± 26mmHg. One of the failed valves had severe patient-prosthesis mismatch. Mean time to failure was 3.8±1.7 years. When compared with PME, Trifecta patients were older (72±10 vs. 75±8 years, p<0.001), had higher incidence of hypertension (p=0.005), more patients had additional bypass grafting, whereas PME patients had more concomitant mitral and tricuspid valve surgery and major aortic surgery. No difference between the two models in patient-prosthesis mismatch. Trifecta patients had 15 failed valves (1.8%) while PME had no failures (p=0.002). There was no difference in the incidence of endocarditis between the two models, or the total mortality.

Conclusion

The Trifecta valve had a low – but higher than other models – incidence of structural valve failure (1.8%) over a follow-up period of 4.2 years. Multicentre studies/ registries are required to determine if these data are observed in other institutions.

ID: 335

Topic: **Cardiovascular Surgery » Diagnosis and Treatment of Valvular Heart Disease**

Presentation Type: **Oral**

COMPARISON OF VASCULAR COMPLICATION RATES BETWEEN TAVI AND SURGICAL AVR

Mehmet Ali Yeşiltaş, Sadiye Deniz Özsoy

Istanbul University Institute of Cardiology, İstanbul, Turkey

**Corresponding Author (dr.maliyes@gmail.com)*

dr.maliyes@gmail.com, sdenizozsoy@gmail.com

Abstract Text

Treatment protocols for severe aortic valve stenosis include aortic valve replacement (AVR), balloon valvuloplasty, transcatheter aortic valve replacement (TAVI), and medical follow-up. Since the success rates are high among the well adapted AVR and the lately popular TAVI, the choice between these treatment options are very important.

This study shows the short(1 month) and mid(6 months) term mortality and morbidity rate differences retrospectively between two groups of patients who applied to our hospital during january 2014-october 2018 period. The first group consists of 54 patients whom underwent mid-high risk AVR operations at Istanbul University-Cerrahpasa, Institute of Cardiology, Department of Cardiovascular Surgery. The second group consists of 57 patients whom underwent TAVI at the Cardiology Department.

Patients who underwent AVR had %3,7 postoperative cardiac arrhythmias, while the %17,5 of patients from the TAVI. Mortality rate was %9,3 in the AVR group and %5,3 in the TAVI group. The mortality rate was not statistically different between the groups. There were no significant difference between the groups in the means of neurological incidents. TAVI group had more vascular complications(%17,9 to none).

In order to prevent the vascular complications in the TAVI group, preoperative peripheral vascular examination should be done thoroughly. There seems to be no mortality difference between these groups in the 6 month follow-up but studies should be made with more patients and long term results.

ID: 42

Topic: Cardiovascular Surgery » Diagnosis and Treatment of Valvular Heart DiseasePresentation Type: **Oral****AORTIC VALVE REPLACEMENT FOR PAPILLARY FIBROELASTOMA****Ali Ahmet Arıkan¹, Oğuz Omay², Fatih Aydın³, Muhip Kanko², Sibel Gür², Emir Derviş⁴, Cansu Eda Yılmaz⁵, Bahar Müezzinoğlu⁵**¹*Derince Eğitim Araştırma Hastanesi, Kocaeli, Turkey*²*Kocaeli University Medical Faculty, Department of Cardiovascular Surgery, Kocaeli, Turkey, Kocaeli, Turkey*³*Eskişehir State Hospital, Department of Cardiology, Eskişehir, Turkey, Eskişehir, Turkey*⁴*Kocaeli University Medical Faculty, Department of Cardiology, Kocaeli, Turkey, Kocaeli, Turkey*⁵*Kocaeli University Medical Faculty, Department of Pathology, Kocaeli, Turkey, Kocaeli, Turkey***Corresponding Author (dr_aarikan@hotmail.com)**dr_aarikan@hotmail.com, oguzomay@gmail.com, drfatihaydin@gmail.com, muhipkanko@yahoo.com, gursibell@gmail.com, emirdervis@hotmail.com, swmliorfoz@hotmail.com, bmuezzin@kocaeli.edu.tr***Abstract Text**

Aortic Valve Replacement for Papillary Fibroelastoma

Abstract:

Background and aim of the study:

Cardiac surgery is indicated for symptomatic patients with papillary fibroelastomas (PFE) on aortic valve. The valve is commonly spared during tumor excision. Rarely, aortic valve replacement (AVR) is needed. We present a case requiring AVR for aortic valve PFE (avPFE) with a systematic review of literature to investigate risk factors for failure of aortic valve sparing techniques in avPFE cases.

Methods:

A sixty-three years old woman with an aortic mass is treated with AVR. A shave excision and valve repair is not attempted. Pathologic diagnosis was consistent with PFE.

To detect avPFE cases treated with AVR a systemic review of literature using PubMed database is performed. This review consists of data collected from 41 cases described in 34 articles. Patients treated with AVR for aortic PFE with and without concomitant aortic valve disease are enlisted. Age, gender, tumor size, tumor localization, affected cusps, symptoms, additional cardiac pathologies and operative features are analyzed.

Results:

25 patients underwent AVR without structural disease on aortic valves. 16 had concomitant valve disease. 58% of patients with normal valvular function were female. 55% of the patients with normal functioning aortic valve had a tumor greater than one centimeter. A smaller proportion is described in literature for female gender and tumor size.

Conclusion:

Female gender and larger tumors can be predictors of valve replacement in avPFE surgery.

This report is published in Journal of Cardiac Surgery with the DOI: <https://doi.org/10.1111/jocs.13154>

ID: 559

Topic: Cardiology » PI for SHD - Transcatheter Aortic Valve Replacement

Presentation Type: Oral

PREDICTORS OF ACCESS SITE BLEEDING AND BLOOD TRANSFUSION IN AORTIC STENOSIS PATIENTS AFTER TRANS-CATHETER AORTIC VALVE REPLACEMENT

Kamil Gülşen

*Health and Science University Bagcilar Training and Research Hospital , Bahçelievler, Turkey***Corresponding Author (kamilgulsen2000@yahoo.com)**kamilgulsen2000@yahoo.com*

Abstract Text

Background: Access site bleeding is a frequent complication after trans-catheter aortic valve replacement (TAVR) procedure. It was demonstrated in the literature that post-procedural bleeding and blood transfusion is related with increased mortality after TAVR. In clinical practise, to know high risk patients regarding access site bleeding is important to take some measures. In this study, to seek predictors of access site bleeding and blood transfusion after TAVR procedure was aimed in a single centre population.

Method: We evaluated totally 151 consecutive eligible patients who underwent TAVR procedure between 2013 and 2018 in our centre. Access site bleeding was diagnosed when a need of an additional intervention due to bleeding or sustained compression needed to stop bleeding or a hematoma occurred in place of access site. Demographic finding and pre-procedural serum creatinine and haemoglobin levels were noted. Patients who needed blood transfusion after the procedure during hospitalisation were identified. The obtained data were studied with proper statistical methods.

Results: In this study totally 151 consecutive patients mean age 78.3 +/- 7.4, 76 (% 50.3) female were evaluated. Access site bleeding occurred in 38 (25,1 %) out of 151 patients while blood transfusion needed in 67 (44 %). In univariable logistic regression analysis only body mass index predicted access site bleeding (OR 1,125 [CI 1,031-1,227 p= 0,008]) In multivariable logistic regression analysis (Age, female gender, creatinin level, body mass index was put in the model) only body mass index emerged as an independent predictor of access site bleeding (OR 1,128 [CI 1,030-1,235 p= 0,01]) For the blood transfusion, only pre-procedural hemoglobin level was a predictor in univariable regression analysis

(OR 0,550 [CI 0,425-0,712 p<0,0001]). In multivariable logistic regression analysis (Age, female gender, STS score, pre-procedural creatinin level, pre-procedural hemoglobin level, body mass index was put in the model) only pre-procedural hemoglobin level emerged as an independent predictor of blood transfusion (OR 0,497 [CI 0,370-0,666 p <0,000]).

Discussion: In our study population, body mass index is an independent predictor of acces site bleeding while pre-procedural hemoglobin level is an independent predictor of blood transfusion.

ID: 564

Topic: **Cardiology » Cardiac Imaging - Echocardiography**Presentation Type: **Poster****COMPARISON OF THE IMPACT OF MITRAL VALVE REPLACEMENT WITH COMPLETE AND PARTIAL PRESERVATION OF SUB-VALVULAR APPARATUS ON LEFT VENTRICULAR FUNCTION****Fulya Avci Demir**, Mehdi Eskandari, Max Baghai, Ranjit Deshpande, Mark J. Monaghan, Olaf Wendler*King's College Hospital, London, United Kingdom***Corresponding Author (fulyaavcidemir@gmail.com)**fulyaavcidemir@gmail.com, mehdi.eskandari@nhs.net, max.baghai@nhs.net, ranjit.deshpande@nhs.net, mark.monaghan@nhs.net, olaf.wendler@nhs.net***Abstract Text**

Background: Preservation of the posterior mitral leaflet apparatus (MVR-P) has a favourable outcome on left ventricular function in patients who undergo mitral valve replacement (MVR). However, there is a paucity of data on the impact of complete preservation of the sub-valvular apparatus (MVR-C) on LV function. Global longitudinal strain (GLS) has an emerging role in assessment of left-ventricular function. In this study, we sought to investigate the impact of MVR-C as opposed to MVR-P on GLS.

Methods: 48 selected patients who underwent MVR between January 2012 and December 2017 and had available baseline and three-month follow up echo were entered the study (29 MVR-P and 19 MVR-C). The percentage change in left-ventricular ejection fraction (EF) and GLS before and 3 months after the operation were calculated for each patient. Independent sample T-test was used for comparison between the two groups.

Results: Mean age was 60.4(+/-14.6) and 57.6 (+/-14.1) in MVR-P and -C patients respectively (p=0.50). There was no difference in gender (p=0.53), underlying mitral valve pathology (p =0.1), history of diabetes (p=0.34), hypertension (p=0.45), smoking (p=0.49), atrial fibrillation (p=0.25), coronary artery disease (p=0.61). Baseline echo parameters including EF [53.9% (+/-9.7) vs 56.7% (6.5+/-), p= 0.26] and GLS [-19.1 (+/-3.7) vs -17.0 (+/-4.6), p=0.09] were not statistically different for MVR-P and MVR-C respectively. Relative change in EF was similar between the groups (MVR-P: -7.9% +/- 13 vs MVR-C: -3.1 % +/-10, p= 0.39). In contrast, the mean GLS for the MVR-C group improved (2.2% +/- 32), whereas it decreased in the MVR-P group (-20.2% +/- 20.2, p= 0.02).

Conclusion: MVR with complete preservation of the sub-valvular apparatus shows favourable impact on the longitudinal function of the heart at 3 months. Further studies are required to investigate the long-term results of this surgical approach.

Oral Presentations

Heart Valve Surgery: Techniques and Outcomes

Date: 30.03.2019 Time: 15:15 - 16:15 Hall: 6

ID: 487

Topic: Cardiovascular Surgery » Heart Valve Repair

Presentation Type: Oral

BEATING HEART TRICUSPID VALVE REPLACEMENT REDUCES MORTALITY AND MORBIDITY IN HIGH RISK PATIENTS WITH TRICUSPID ANNULAR PLANE SYSTOLIC EXCURSION (TAPSE) LESS THAN 15 MM WHO UNDERWENT ISOLATED TRICUSPID VALVE SURGERY

Kıvanç Atılğan¹, Gökhan Arslan², Gökhan Erol², Celal Selçuk Ünal³, Ertan Demirdağ²

¹University of TOBB Medine Faculty , Ankara, Turkey

²Gulhane Training and Research Hospital, Ankara, Turkey

³Karabük Training and Research Hospital , Karabük, Turkey

*Corresponding Author (kivancatilgan@gmail.com)

kivancatilgan@gmail.com, drgokhanarслан@gmail.com, drgokhanerol@gmail.com, drselcukunal@yahoo.com, dr.ertandemirdas@gmail.com

Abstract Text

Introduction: Tricuspid valve surgery has been an ignored subject for a very long time. Although tricuspid valve replacement (TVR) is a very simple technique, cardiac surgeons usually tend to refrain from valve replacement and prefer to perform ring or non-ring annuloplasty in patients with organic tricuspid lesion. Because, valve replacements in left heart have much more satisfying results than the ones in right heart. Despite these reasons, tricuspid valve replacement is sometimes inevitable. It gets important to consider the options to reduce mortality and morbidity in high risk patient groups when TVR is inevitable. Tricuspid annular plane systolic excursion (TAPSE) is an important parameter to assess right ventricular systolic function and determine right ventricular systolic disfunction. TAPSE is the most commonly used method for these purposes due to its easy obtainment and simple appliance to clinical practice.

Methods: This study included patients with isolated tricuspid valve insufficiency whom underwent TVR surgery at Akay Hospital Cardiovascular Surgery Clinic between the years of 2006 - 2012. The patients with TAPSE \geq 15 mm or the history of coronary artery bypass grefting surgery was excluded. In our clinical practice, TAPSE measurement has been applied to all patients whom planned to undergo TVR surgery since 2006. All included patients was divided into two clinical subgroups: In 13 patients cardioplegic arrest was performed (Group A) and in 16 patients the patients on-pump beating heart procedure was used (Group B). In-hospital mortality was defined as a death occurring for any reason in the hospital within 30 days of the admission date.

Results: The clinical characteristics of the groups were as follows: Group A (n=13; 5 males; mean age = 55.42 \pm 11.6 years) and Group B (n=16; 6 males; mean age = 57.92 \pm 8.43 years). When preoperative data was compared, only expected mortality rate according to EUROSCORE II risk assesment was higher in patients in Group B. Furtermore the mortality rate of this group was found to be higher than expected.

Logistic regression analysis showed that beating heart with CPB tecnique (odds ratio [OR] 0.43, 95% confidence interval [CI] 0.22–0.76, P=0.001) was independently associated with beating heart with CPB tecnique occurrence after correction for age, female gender and CPB time.

Conclusion:

In conclusion, the low morbidity and mortality rates which are observed in our study suggest that TVR surgery with beating heart with CPB technique is applicable and safe. However we think further studies which are conducted multicentrically and with larger sample sizes are required.

ID: 314**Topic: Cardiovascular Surgery » Heart Valve Repair****Presentation Type: Oral****MITRAL VALVE REPAIR IN BARLOW'S DISEASE: THE RESTORATION TECHNIQUE****Živojin Jonjev**, Mirko Todić, Strahinja Mrvić, Bogdan Okiljević, Olivera Vlahović, Slavica Majdevac*Institute for Cardiovascular Diseases of Vojvodina, Sremska Kamenica, Serbia***Corresponding Author (jonjevz@gmail.com)**jonjevz@gmail.com, jonjevz@gmail.com, jonjevz@gmail.com, jonjevz@gmail.com, jonjevz@gmail.com,
jonjevz@gmail.com***Abstract Text****Objective:**

Patients with end stage ischemic dilated cardiomyopathy (IsDCM) exhibit extensive remodeling of the left ventricle, and significant mitral and tricuspid regurgitation. We investigated if implantation of the artificial mitral valve with preservation of the native mitral valve could be used as a method combined with tricuspid annuloplasty and complete myocardial revascularization in end stage IsDCM.

Materials and Methods:

There were 31 patients (26 males, 5 females) with end stage IsDCM (NYHA III/IV). All patients had significant mitral and tricuspid regurgitation, mean ejection fraction below 30% ($25.6 \pm 3.1\%$), and mean left ventricle end-diastolic internal diameter greater than 7.0 cm (7.3 ± 0.3 cm) with coaptation depth of the mitral valve significantly greater than 1.1cm (STS "risk of mortality" score= $22.04 \pm 1.5\%$; Euroscore II= 7.04 ± 1.02). In addition to complete myocardial revascularization biological or mechanical artificial valve was implanted in 27 and 4 patients respectively. Modified De Vega tricuspid annuloplasty was performed in all patients.

Results:

There was no postoperative 30-day mortality. Significant reverse remodeling of the heart was achieved measured by decrease of the endsystolic sphericity index (84.2% vs 68.9%) and improved ejection fraction (26.6% vs 32.6%). Clinical status of the patient was significantly improved immediately after procedure, and was stable 12 month after surgery. Long term results showed survival rate after 5 years of 83.33%.

Conclusions:

Reverse remodeling of the left ventricle with implantation of the artificial mitral valve, suture annuloplasty of the tricuspid valve and complete myocardial revascularization could be successfully applied in patients with end stage IsDCM. Our method should not be recognized as a valve repair, but ventricular repair as well and could be used as a bridge to heart transplantation or even destination therapy in selective patients.

ID: 28

Topic: **Cardiovascular Surgery » Heart Valve Repair**Presentation Type: **Oral****RECONSTRUCTIVE SURGERY OF THE MITRAL IN IT IS ISOLATED
REGURGITATION.****Rustem Tuleutayev, Ualikhan Imammirzayev, Bakhytzhan Momynov, Timur Ibragimov, Zhenis
Koshkinbayev, Nazym Nurollaeva***National Scientific Center Of Surgery Named after A.N. Syzganov, Almaty, Kazakhstan***Corresponding Author (rustemtuleutayev@gmail.com)**rustemtuleutayev@gmail.com, ualikhan-88@mail.ru, bakhytzhan.momynov@gmail.com,
ibragimovteimyr@mail.ru, doctor_zhenis@mail.ru, ibragimovteimyr@mail.ru***Abstract Text****Objectives:**

The objectives of this study were to evaluate the early and long-term results of reconstructive operations with severe isolated mitral regurgitation.

Patients and methods:

Between January 2010 and January 2018 41 patients with isolated mitral valve regurgitation performed surgical intervention in the department of cardiac surgery at the NSCS named after A. N. Syzganov. The mean age of the patients was 46±3,4 years (range 19–70 years). Among them nineteen (46%) were men and twenty-two (54%) were women. 2 patients (5,7%) of lethal outcomes in the immediate postoperative period. Preoperative diagnosis was performed by echocardiography. 22 patients in the postoperative period underwent follow-up examination. The mean time of the observation was 1075 days.

Result:

Mitral valve reconstruction was performed by cardiopulmonary bypass and aortic occlusion for the all patients. The average duration of cardiopulmonary bypass was 150 min, aortic occlusion was 105 min. All patients discharged from the hospital with improvement. minimally invasive multicomponent plastics of MV – 6 (14,6%) patients, Alfieri 3, Potts 2, Woller 1, Carpentier 3. support ring 26 patients. Only one patient, mitral regurgitation NYHA functional class II, in one patient, mitral valve replacement was performed after 37 months according to the long-term results in patients who have undergone echocardiography.

Conclusion:

At the same time, long-term results demonstrate a good efficiency of plastic correction of the mitral valve with a pronounced regurgitation. Plastic correction of mitral regurgitation has clear advantages in terms of survival rate, freedom of repeated operations and thromboembolic complications provide a better quality of life unlike mitral valve replacement.

ID: 203

Topic: **Cardiovascular Surgery » Heart Valve Repair**Presentation Type: **Oral****3 PLEDGETED SUTURES FOR REPAIR OF ISCHEMIC MITRAL VALVE REGURGITATION IN PATIENTS UNDERGOING CABG SURGERY**

Seymur Musayev, Emin Gurbanov, Farid Huseynov, Seymur Mammadov, Reshad Mahmudov

*Central Hospital for Oilworkers, Baku, Azerbaijan***Corresponding Author (emin405@hotmail.com)**emin405@hotmail.com, emin405@hotmail.com, emin405@hotmail.com, emin405@hotmail.com,
emin405@hotmail.com***Abstract Text****BACKGROUND:**

The surgical techniques for the management of ischemic mitral regurgitation (IMR) at the time of CABG surgery have been constantly evolved. We developed and evaluated short- and mid-term surgical outcomes of ischemic mitral valve repair using 3 pledgeted sutures.

METHODS:

Between April 2014 and November 2017, 37 patients (60.4±8.3 years) with moderate to severe MR (grade 3.5±0.5) underwent CABG with mitral annuloplasty using 3 pledgeted sutures which was placed on posterior annulus on each of P1, P2 and P3 segments. The etiology of mitral regurgitation was ischemic in all the patients. The patient's echocardiographic studies were performed during and within 3 months and 1 year after surgery.

RESULTS:

In-hospital mortality was 2.7%, survival at 3 month and 1 year was 91.9% and 89.2%, respectively. Intraoperative TEE indicating 0-1+ MR was achieved in 33 patients, of which 30 patients had same degree of MR at discharge with TTE. Leaflet coaptation was 0.7±0.2 cm. Follow up TEE on 32 patients at 1 year showed zero to trivial MR in 9 patients, grade 1+ MR in 17 patients, 2+ MR in 4 patients, and 3-4+ MR in 2 patients. Size of left atrial decreased from 54±7 to 48±8 mm (P<0.001). Patients with severe annular dilatation (27.5%) had a greater recurrence rate (P <0.001). All patients were free of endocarditis and thromboembolism.

CONCLUSIONS:

Repair of ischemic mitral valve regurgitation using 3 pledgeted sutures during the CABG surgery is feasible which achieve immediate valve competence and has long-term durability. This approach is probably more applicable for patients with lesser degree of annular dilatation and has time and cost saving benefits.

ID: 391

Topic: **Cardiology » Diagnosis and Treatment of Valvular Hearth Disease**Presentation Type: **Oral****LATE TERM RESULTS OF CONCOMITANT SURGICAL INTERVENTION FOR MILD TO MODERATE FUNCTIONAL TRICUSPID REGURGITATION IN PATIENTS UNDERGOING MITRAL VALVE REPAIR****Nuray Kahraman Ay***Bezmialem Vakif University, İstanbul, Turkey***Corresponding Author (drnuraykahraman@hotmail.com)**drnuraykahraman@hotmail.com***Abstract Text****OBJECTIVES:**

Tricuspid valve is often has been neglected in open heart surgery. Late-onset functional tricuspid regurgitation after mitral valve surgery is an important cause of morbidity and mortality. In this study, mitral repair and accompanying tricuspid annuloplasty and mitral repair alone procedures were evaluated and compared in patients with mild to moderate tricuspid regurgitation as well as severe mitral regurgitation.

METHODS:

105 patients with severe mitral regurgitation and mild to moderate tricuspid regurgitation were included in this study that underwent operation between the 2012 and 2018 years in Cardiovascular Surgery Department of Bezmialen Vakif University Medical Faculty. The study included 68 (64.7%) patients who underwent tricuspid ring annuloplasty with mitral repair (TRA group), and 37 (35.2%) patients underwent mitral repair alone (nonTRAgrou). Late survival and severity of postoperative tricuspid regurgitation were evaluated during follow-up period.

RESULTS:

Median follow- up period for non- TRA and TRA groups were 28.7±21.6 and 29.9±18.9 months respectively (p.0.77). There was no significant difference between two groups in regard to late survival rates: 94.1% in TRA and 86.4% in non-TRA group (Logrankp: 0.214). Severe late tricuspid regurgitation occurred in 7 (18.9%) of non- TRA group patients, and in 1(1.4%) of TRA during late postoperative follow- up period. The freedom from severe tricuspid regurgitation rates during late postoperative period in TRA group and non- TRA group was 98.5% and 81.1%, respectively, (Logrankp:0.002). Late functional status of patients in TRA group was found better and statistically significant (p: 0.019).

CONCLUSIONS:

We thought that surgical intervention for mild to moderate tricuspid regurgitation in patients undergoing mitral repair may prevent the development of a progressive tricuspid regurgitation in the long term and provide a better functional capacity.

Keywords: Mitral repair, functional tricuspid regurgitation, tricuspid annuloplasty

ID: 472

Topic: **Cardiovascular Surgery » Diagnosis and Treatment of Valvular Heart Disease**

Presentation Type: **Oral**

MECHANICAL MITRAL VALVE THROMBOSIS UNDER TREATMENT WITH APIXABAN AS AN ANTICOAGULANT

Ibrahim Uyar

Tepecik Training and Research Hospital, İzmir, Turkey

**Corresponding Author (druyar@yahoo.com)*

druyar@yahoo.com

Abstract Text

Mechanical Mitral Valve Thrombosis Under Treatment with Apixaban as an Anticoagulant

Objective

The objective was to evaluate the treatment strategy for isolated mechanical mitral valve thrombosis diagnosed in a patient using apixaban as an oral anticoagulant.

Method

A 68 years old male patient, who had undergone aortic and mitral valve replacement and tricuspid valve repair 7 years ago was admitted to the emergency department with NYHA Class IV symptoms. He developed severe shortness of breath in the last weeks. TTE revealed severe left atrial thrombus and mechanical mitral valve thrombosis with a peak gradient of 40 mmHg and a mean gradient of 20 mmHg. Anamnesis of the patient revealed that 6 months ago the patient replaced warfarin treatment with 5 milligrams of apixaban without the guidance of a medical specialist. The patient underwent emergency reoperation immediately. Surgical exposure revealed left atrial thrombus and complete immobilization of both mechanical mitral valve leaflets due to thrombotic material located in both sides of the leaflets pivots . After excision of all the thrombi, the mechanical valve was replaced with a size 29 bi-leaflet mechanical valve prosthesis. No postoperative bleeding was observed . Length of stay in the intensive care unit was 7 days. LMWH was used until a protective dose of warfarin was achieved. He was discharged on the 14th day with NYHA Class I symptoms and transmitral gradient of 7/4 mmHg.

Result

Warfarin is still the recommended treatment of mechanical valve replacement. New generation oral anticoagulants have been started to be used in several clinical conditions. However, in mechanical valve replacement, they are still accepted as contraindicated with Class III indication in guidelines. Apixaban inhibits Factor Xa and Prothrombinase activity whereas Vitamin K antagonists inhibit Factors 2, 7, 9, 10 and Protein C and S. It was considered to diagnose isolated thrombosis of the mitral mechanical valve without affecting the mechanical valve in aortic position. Although having more resistance to thrombosis at an aortic position may be explained by higher transaortic flow rate.

Conclusion

Replacement of warfarin with new generation oral anticoagulants without scientific evidence may have detrimental effects on human life. Warfarin is still the first line treatment modality with Class I indication for mechanical valves. Patients treated with new generation oral anticoagulants can be operated with rigorous surgical strategies despite a high risk of bleeding.

Oral Presentation

Date: 30.03.2019 Time: 13:30 - 14:30 Hall: 4

ID: 168

Topic: **Cardiology » Cardiovascular Nursing**

Presentation Type: **Oral**

HOPELESSNESS LEVELS AND SELF-CARE BEHAVIORS OF PATIENTS WITH HEART FAILURE

Meral Gündoğan Gelik, Şule Ecevit Alpar

Marmara University, Health Sciences Institute, Istanbul, Turkey

**Corresponding Author (meral_gndgn@hotmail.com)*

meral_gndgn@hotmail.com, salpar@marmara.edu.tr

Abstract Text

OBJECTIVE:

In patients with heart failure, respiratory distress, fatigue, decreased exercise tolerance, and nutritional changes lead to hopelessness in these patients. Patients' adaptation to disease is increasing if hope is maintained. Patients who feel hopeless are reluctant to participate in the treatment of their disease. This becomes more important in chronic diseases requiring active participation in treatment. This study was designed as a cross-sectional and descriptive study to determine the relationship between hopelessness levels and self-care behaviors of patients with heart failure.

METHODS:

The study sample consisted of 200 patients in cardiology clinics in a training and research hospital in Istanbul between June and December 2017. The data were collected by Patients Information Form, Beck's Hopelessness Scale and The European Heart Failure Self-Care Behaviors Scale-12. NCSST 2007 program for statistical analysis.

RESULTS:

The mean age of the patients was 61.01±13.24 and 72.5% male, 74.5% married, 66.4% for hypertension and 64.5 % diabetes mellitus, 40.5% in class IV according to New York Heart Association (NYHA) Classification and mean left ventricular EF measurements were determined as 26.40±9.40. According to the results of the study, total hopelessness score average of patients was 11.56±4.18. Hopelessness sub scale score averages on the other hand were as follows: future thoughts and expectations 2.87±1.47; loss of motivation 5.75±1.72; and hope 2.94±1.94. Self-care behavior score average was 41.80±6.96. When the relationship between Beck's Hopelessness Scale mean scores and The European Heart Failure Self-Care Behaviors Scale-12 score was examined; Significant positive correlation was found between self-care behavior score and total hopelessness ($r=0.509$; $p=0.001$; $p<0.01$), future thoughts and expectations ($r=0.462$; $p=0.01$; $p<0.01$), motivation loss ($r=0.433$; $p=0.001$; $p<0.001$) and hope ($r=0.359$; $p=0.001$; $p<0.001$).

CONCLUSIONS:

High levels of hopelessness of patients negatively affect self-care behaviors. It is recommended to organize training programs where patients can learn how to cope with despair in order to increase their self-care behaviors.

ID: 213

Topic: **Cardiology » Cardiovascular Nursing**Presentation Type: **Oral****BEING ON THE THORN: SENIOR NURSE AND NEW NURSE EXPERIENCES IN THE CARDIOVASCULAR SURGERY CLINIC****Eda Ayten Kankaya, Aylin Durmaz Edeer, Özlem Bilik***Dokuz Eylül University Nursing Faculty , İzmir , Turkey***Corresponding Author (edayten@gmail.com)**edayten@gmail.com, ozlemdeuhf2011@gmail.com***Abstract Text****Objective:**

To evaluate the experiences of nurses in the process of adaptation to the cardiovascular clinic.

Methods:

Research is a phenomenological research from qualitative research methods. The data were collected in the cardiovascular surgery clinic of a university hospital between November-December 2018. The study included four nurses working in the clinic for less than a year and five nurses working in the clinic for at least five years. The data were collected face to face using a semi-structured in-depth interview form and voice recorder. Interviews were conducted in a quiet environment and continued approximately forty minutes. Written interviews were coded using inductive content analysis, concepts and main themes were composed.

Results:

The mean age of the nurses was 31.22±5.62 and all nurses (n = 9) were female. The mean time of nurses in clinical practice is 82.44±73.29 months. All the nurses who were forced to give nursing care were divided into eight themes. These themes include: excessive nursing care burden, long working hours, communication problems, inadequate physical conditions, insufficiency in the number of health care professionals, failure to plan time, burnout and stress. All nurses were asked about facilitators to provide care. The themes identified were: mastery of the clinic, nursing students, instructions, friend support, training booklets. Nurses who had more than five years of experience were asked about the difficulties of working with new nurses. Themes related to this question are: lack of information about drugs, deficiencies in planning and implementation of care, generation gap, and dependence on nursing roles. The difficulties experienced by the nurses with less than one year experience working with experienced nurses: lack of information, feeling psychological pressure, communication problems, fear.

Conclusions:

All nurses have many difficulties in the cardiovascular surgery clinic. A significant part of these difficulties are related to the process of adaptation to the clinic.

Key words: Cardiovascular Surgery Clinic, Experience, Nurse

ID: 427

Topic: Cardiology » Cardiovascular Nursing

Presentation Type: Oral

THE EVALUATION OF SELF CARE AFTER DISCHARGE FOLLOWING VARICOSE VEIN SURGERY

Burcu Şahbaz¹, Sema Koçaşlı², Atike Tekeli Kunt¹

¹Ankara Numune Eğitim ve Araştırma Hastanesi, Ankara, Turkey

²Ankara Yıldırım Beyazıt Üniversitesi, Ankara, Turkey

*Corresponding Author (burcu_sahbaz@hotmail.com)

burcu_sahbaz@hotmail.com, skocasli@yahoo.com.tr, atikemd@gmail.com

Abstract Text

The Evaluation Of Self Care After Discharge Following Varicose Vein Surgery

BACKGROUND:

Varicose veins, although mostly considered a cosmetic problem, usually result in a poor quality of life and even severe morbidity due to ulcers of the lower extremity. Recently catheter based minimally invasive techniques have evolved in the management of chronic venous insufficiency. Postoperative early mobilization, compression stockings, elevation of the extremity are suggested to be important factors that have effect on success of the surgery. The present study aims to evaluate the self care after discharge following varicose vein surgery.

METHODS:

Ninety eight patients scheduled for catheter-based minimally invasive varicose vein surgery were included. At the day of surgery a form that includes questions about the social and demographic data, medical history and life style of the patients were filled and collected. Additionally a self care agency scale is also filled and collected. One month after the surgery the patients were called and a questionnaire that includes questions about selfcare after discharge were filled.

RESULTS:

All patients completed the study. The mean age of the patients were 35±10, 75% of the patients were female. Our results revealed that 60% of the patients did not wear the compression stockings continuously, 55% of patients did not elevate their extremities and 75% of the patients did not perform their exercises.

CONCLUSION:

We conclude that self-care of the varicose vein patients following surgery after discharge is insufficient. Training of these patients during the discharge from the hospital is very important.

ID: 319

Topic: Cardiovascular Surgery » VAD

Presentation Type: Oral

INVESTIGATE THE EFFECT OF PSYCHODRAMA ON THE QUALITY OF LIFE OF PATIENTS WITH VENTRICULAR ASSIST DEVICE DUE TO HEART FAILURE.

Dilek Akbaş

Ege University , Izmir, Turkey

**Corresponding Author (dilek0712@gmail.com)*

dilek0712@gmail.com

Abstract Text

This study was conducted to investigate the effect of psychodrama on the quality of life of patients with ventricular assist device due to heart failure.

The study, which lasted for 3 hours a week, started with 6 members and continued with the number of members that changed for the first seven weeks, continued with 3 members from the 8th week onwards and was completed in 16 weeks.

The mapping, role-changing and mirroring techniques of the psychodrama method are used. To measure the effectiveness of the study, we used The Satisfaction with Life Scale, Body Image Quality of Life Inventory and the Left Ventricular Dysfunction Questionnaire as data collection tools. Pre-test and post-test scales were analyzed with Wilcoxon signed-rank test at $p < 0.05$ significance level.

No statistically significant differences were found in the statistical analyzes ($p > 0.05$). It can also be considered that this may be due to the limitation of the number of samples. However, at the end of the process, they shared that acceptance of their illnesses began and their awareness increased. In this study, it was concluded that the psychodrama method has a positive effect on the quality of life of patients living with ventricular assist devices.

New Developments in The Diagnosis and Management of Cardiovascular Diseases

ID: 169

Topic: **Cardiology » Percutaneous Coronary Interventions**Presentation Type: **Poster**

A NEW INFLAMMATORY MARKER: ELEVATED EOSINOPHIL TO LYMPHOCYTE RATIO ASSOCIATED WITH PRESENCE AND SEVERITY OF ISOLATED CORONARY ARTERY ECTASIA

Mücahid Yılmaz¹, Yusuf Çekici², Nevzat Gözel³, Mehmet Nail Bilen¹, Özlem Seçen¹, Pınar Öner¹, Suat Demirkıran⁴, Orkun Eroglu¹, Hidayet Kayañççek⁴, Hasan Korkmaz³

¹Elazığ Education and Research Hospital, ELAZIĞ, Turkey

²Dr. Ersin Arslan Education and Research Hospital, Gaziantep, Turkey

³Firat University School of Medicine, ELAZIĞ, Turkey

⁴Elazığ Medical Park Hospital, ELAZIĞ, Turkey

*Corresponding Author (mucahid.yilmaz@hotmail.com)

mucahid.yilmaz@hotmail.com, yusufcekici78@gmail.com, drngozeel@hotmail.com, nail.bilen@mynet.com, ozllemsecen@hotmail.com, drpinaroner@hotmail.com, doctorsuat23@gmail.com, erogluorkun23@gmail.com, dr.hidayet@hotmail.com, hkorkmaz23@hotmail.com

Abstract Text

Objectives: The pathophysiology of isolated coronary artery ectasia (CAE) involves atherosclerosis, and inflammation. It has been known that eosinophils and lymphocytes play a significant role in inflammation, atherosclerosis and endothelial dysfunction. There are many studies explored the relation between isolated CAE and systemic inflammation. However, there is no data about relationship between eosinophil to lymphocyte ratio (ELR) and isolated CAE. We aimed to investigate the relationship between ELR value and isolated CAE.

Patients and Methods: All cases who underwent coronary angiography from January 2009 and June 2018 investigated retrospectively. Of 16240 cases, 232 cases with isolated CAE (141 males) and 240 control subjects (130 males) with normal coronary angiography (NCA) that atherosclerosis risk factors-matched were enrolled into this study. Baseline demographical and laboratory data were gained from the hospital database. The severity of isolated CAE was determined according to the Markis classification, vessel count and diffuseness of ectasia.

Results: Patients with angiographic isolated CAE had significantly elevated WBC (Wight blood cell) count, eosinophil count and ELR value when compared to the patients with NCA [8.11±1.75 103/mm³ vs 7.49±1.80 103/mm³, p<0.0001; 0.22 (0.13 -0.32) 103/mm³ vs 0.19 (0.12-0.28) 103/mm³, p=0.02; 0.11 (0.06-0.17) vs 0.08 (0.05-0.12), respectively] (Figure 1, Table I). ELR value for the Markis I was significantly higher than the Markis IV (p=0.04) and for the three-vessels isolated CAE was significantly higher than the one-vessel isolated CAE (p=0.04) (Figure 2, Table II and Table III). Additionally, ELR value for the diffuse ectasia (Markis class 1, 2, 3) was significantly higher compared to the focal (Markis class 4) ectasia (p =0.02) (Table IV) . Last, in receiver operating characteristics analyses (ROC), it was determined that an ELR >0.099 measured in isolated CAE patients at application had a predictive specificity of 60.3% and sensitivity of 56.5% for isolated CAE (area under the curve: 0.604, 95% confidence interval [CI]: 0.553–0.655, p<0.0001) (Figure 3).

Conclusion: Patients with isolated CAE have higher blood eosinophil count and ELR. Furthermore, ELR value significantly correlated with severity of isolated CAE. These findings showed, especially ELR, may play an important role in the aetiopathogenesis of isolated CAE.

Key Words: Eosinophil count, eosinophil to lymphocyte ratio, isolated coronary artery ectasia, inflammatio

	Isolated CAE (232)	NCA (247)	P value
Sex, n (male/ female)	141/91	130/117	0.07
Hypertension, n (%)	72/232 (31.0)	64/247 (25.9)	0.21
Hyperlipidemia, n (%)	82/232 (35.3)	71/247 (28.7)	0.12
Diabetes mellitus, n (%)	50/232 (21.6)	49/247 (19.8)	0.64
Smoking, n (%)	79/232 (34.1)	76/247 (30.8)	0.44
Age, (year)	56.0 (53.0-60.0)	55.0 (52.0-59.0)	0.15
Platelet, (10 ³ /mm ³)	257.0 (223.0-296.75)	250.0 (209.0-292.0)	0.10
Glucose, (mg/dl)	100.0 (89.25-110.30)	99.0 (90.0-109.0)	0.25
Triglycerides(mg/dL)	133.5 (100.25-190.25)	131.7 (95.0-152.0)	0.09
Low density lipoprotein cholesterol, (mg/dl)	115.0 (92.0-134.25)	112.0 (88.0-125.0)	0.06
Total cholesterol, (mg/dl)	186.0 (160.0-213.5)	185.2 (161.0-203.0)	0.65
HDL cholesterol, (mg/dL)	42.0 (36.0-49.0)	47.0 (40.9-55.2)	<0.0001
Eosinophil, (10 ³ /mm ³)	0.22 (0.13 -0.32)	0.19 (0.12-0.28)	0.02
Lymphocyte, (10 ³ /mm ³)	2.05 (1.62-2.54)	2.18 (1.80-2.90)	0.002
ELR	0.11 (0.06-0.17)	0.08 (0.05-0.12)	<0.0001
Hemoglobin, (g/dl)	14.4 (13.6-15.1)	14.1 (13.5-15.0)	0.09
Hematocrit, (%)	43.1 (41.0-45.5)	42.0 (41.0-45.0)	0.07
White blood cell, (10 ³ /mm ³)	8.11±1.75	7.49±1.80	<0.0001 [#]
Urea, (mg/dl)	30.0 (25.0-36.0)	29.2 (23.7- 35.0)	0.10
Creatinine, (mg/dl)	0.67 (0.54-0.78)	0.66 (0.55-0.77)	0.50
Sodium, (mmol/L)	140.0 (138.0-142.0)	140.0 (138.0-142.0)	0.36
Potassium, (meq/L)	4.3 (4.0-4.6)	4.3 (4.1-4.6)	0.40
Calcium, (mg/dl)	9.21± 0.49	9.27± 0.47	0.23 [#]

ELR: Eosinophil to lymphocyte ratio

[#]Normality of the distribution was evaluated by the Kolmogorov-Smirnov test and the Mann-Whitney *U* test applied to compare for continuous variables except from white blood cell and calcium.

Markis classification	Noun (%)	Eosinophil counts	Lymphocyte counts	ELR value
Type I	51 (21.98)	0.25±0.12	1.93±0.79	0.15±0.10
Type II	38 (16.38)	0.24±0.12	1.98±0.60	0.14±0.09
Type III	41 (17.67)	0.21±0.13	2.15±0.94	0.11±0.07
Type IV	102 (43.96)	0.23±0.13	2.29±0.73	0.11±0.08

All over p values for eosinophil and lymphocyte counts >0.5

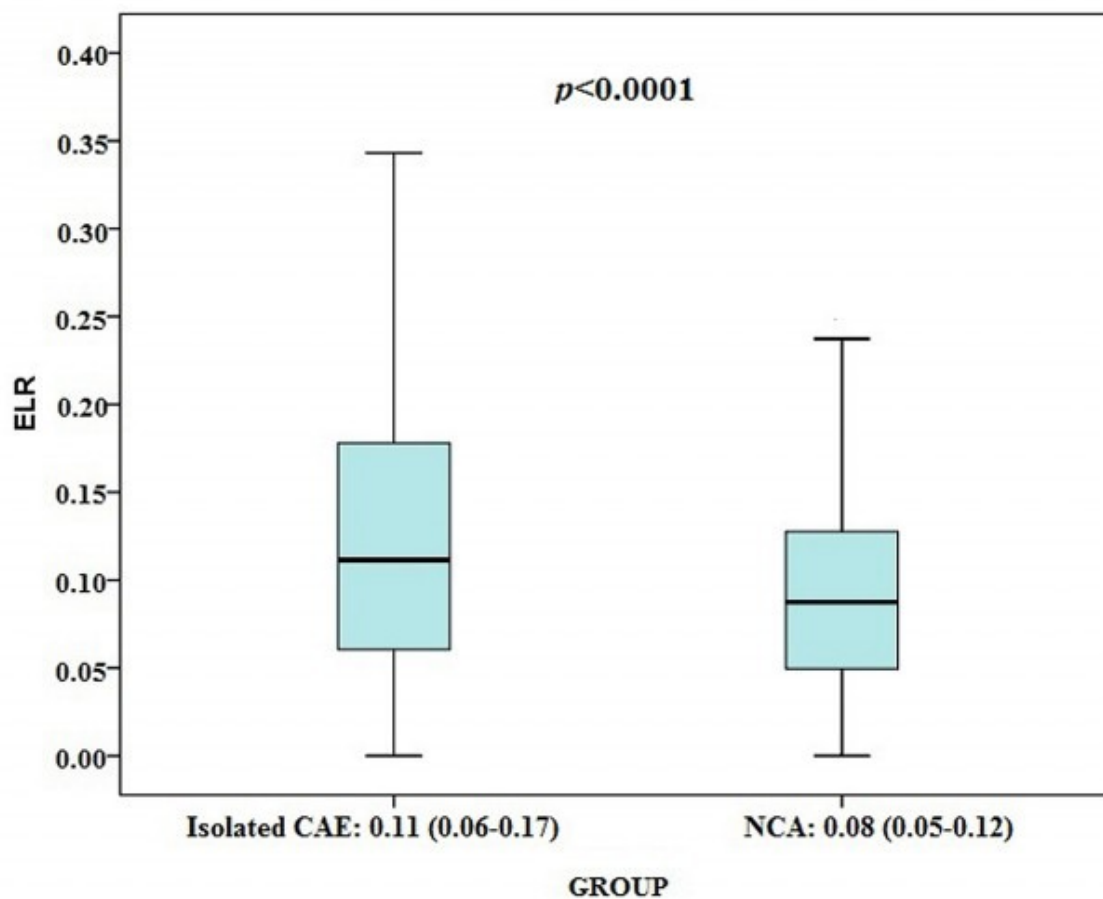
P value for ELR (Between Markis Type I and Markis Type IV) : 0.04

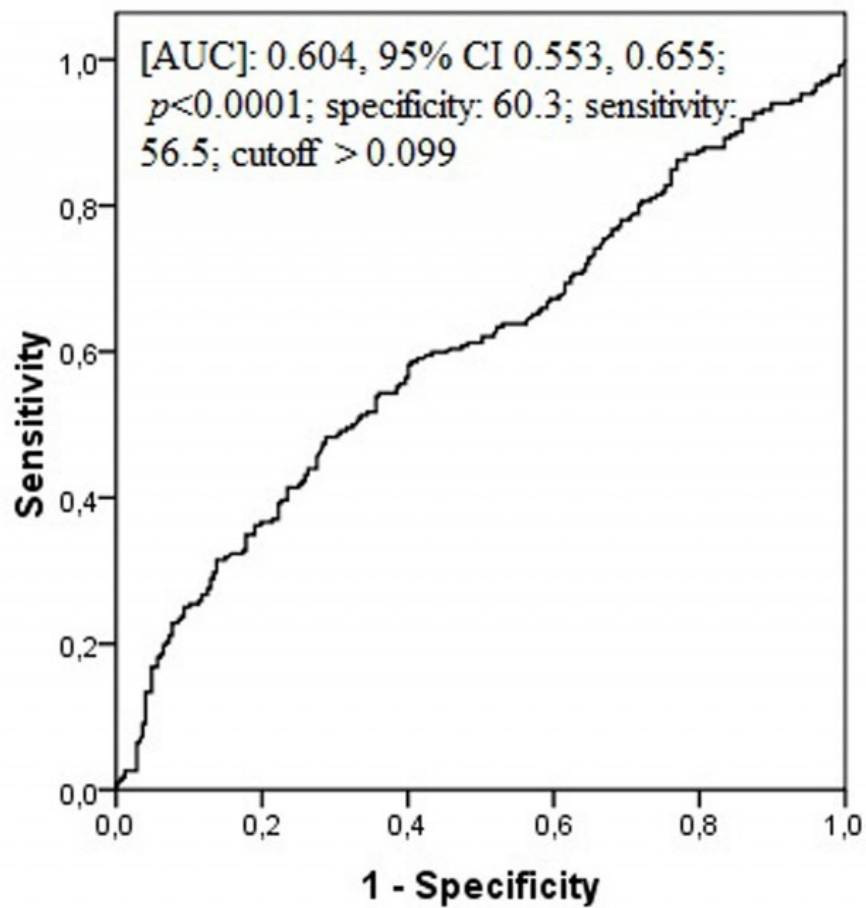
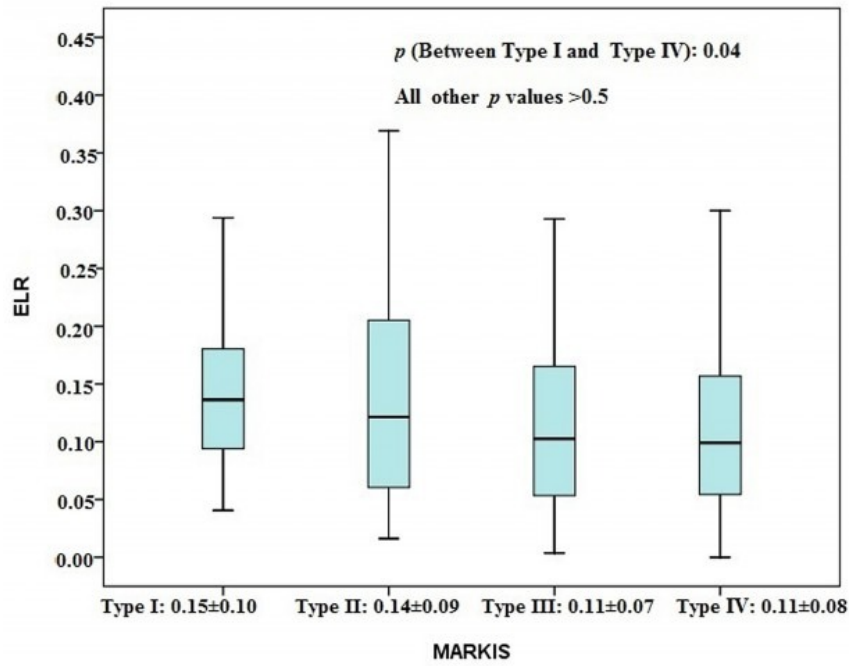
	Noun	Eosinophil counts	Lymphocyte counts	ELR value
One vessel	135	0.22±0.12	2.23±0.81	0.11±0.07
Two vessels	42	0.26±0.14	2.05±0.59	0.14±0.10
Three vessels	55	0.24±0.12	1.96±0.79	0.14±0.09

All over p values for eosinophil and lymphocyte counts >0.5

P value for ELR (Between One vessel and three vessels) : 0.04

	Focal ectasia (n=102)	Diffuse ectasia (n=130)	P value
Eosinophil counts	0.20 (0.12-0.32)	0.22 (0.14-0.33)	0.54
Lymphocyte counts	2.21 (1.81-2.67)	1.93 (1.55-2.36)	0.001
ELR	0.10 (0.05-0.15)	0.12 (0.06-0.18)	0.02





ID: 541

Topic: **Cardiology » Chronic Stable Angina Pectoris**Presentation Type: **Poster****RIGHT CORONARY ARTERY ECTASIA AND ANEURYSMAL DILATATION PRESENTING AS ACUTE CORONARY SYNDROME****Osman Yesildag, Alper Kepez, Halil Atas***Marmara University Medical School, İstanbul, Turkey***Corresponding Author (osmanyas@superonline.com)**osmanyas@superonline.com, alperkepez@yahoo.com, dratashalil@gmail.com***Abstract Text**

64 year-old male admitted to our outpatient clinics with the complaint of chest pain starting one week ago and localized substernal region, radiated to left arm ulnar side. He stated his chest pain increased with exertion and diminished with resting. It was learned from his medical history that he smoked cigarettes for 24 years and quit it 4 years ago. He had no diabetes but systemic hypertension was present for 10 years and hyperlipidemia for 5 years. His family history was negative concerning coronary artery disease and stroke.

On physical examination: BP: 145/85 mm Hg, Pulse rate: 75/min. Lung fields were clear. It could not be detected any pathologic findings with cardiac auscultation. No murmur was heard. There was abdominal obesity. Abdominal examination did not show hepatomegaly and ascites. Peripheral pulses were felt patent with palpation.

On laboratory examination: Hb A1c: %5.9, Total Cholesterol: 254 mg/dl, HDL-C: 47 mg/dl, LDL-C: 169 mg/dl, Hb: 16.3 g/dl, Hct: %47.6, PLT: 244.000 /ml, Glucose: 93 /ml, BUN: 17 mg/dl, Creatinine: 0.88 mg/dl, AST: 22U/l, ALT: 27U/L, CK: 167U/L, uric acid: 6.72mg/dl, CK-MB: 3.9 ng/ml (0.6-6.3), Troponin-T hs: 15.29 ng/ml (0-14), NT-proBNP: 58.7 pg/ml (0-125), CRP: 5.29mg/ml (0-5) p.a. Chest X-ray was normal. ECG showed non-specific ST-T wave changes on lateral chest leads. Treadmill stress test was negative with submaximal heart rate. It was shown inferior lateral myocardial ischemia with myocardial perfusion scintigraphy.

Coronary angiography showed aneurysmal dilatation and ectatic changes in the midportion of right coronary artery (Figure 1-2). The length of this segment was measured as 30 mm and its diameter as 8 mm. It was more than 1.5 times larger when compared to the normal segment of right coronary artery. We found an ectatic segment at the proximal part of left anterior descending artery less than right coronary artery (Figure 3-4). Severe stenosis (%85) was present at the ostial region of the first diagonal artery on left coronary angiography. We proposed the patient to open this tight stenotic lesion but he refused to do so. Therefore we gave him medical therapy. These are antiaggregant drugs such as clopidogrel and aspirin, 40 mg rosuvastatin as primary prophylaxis, metoprolol 50 mg and ramipril 5 mg.

Coronary artery ectasia (CAE) is defined as local or generalized aneurysmal dilatation of the coronary arteries. Coronary artery ectasia was defined as 1.5-2-fold, aneurysm as >2-fold luminal dilatation of the adjacent normal segment. Coronary artery aneurysm (CAA) has been defined as coronary artery segment exceeding the diameter of the normal adjacent coronary segment by 1.5 times and involving less than a third of the total length of the vessel. The CAE has been defined as a diffuse dilatation exceeding more than a third of the coronary artery length, with the diameter of the ectatic segment 1.5 times greater than that of the adjacent normal segment. They have found that CAA more commonly coexists with CAD than CAE. Although the pathophysiology of CAE remains largely unknown, it was supposed to represent a variant of coronary atherosclerosis. Ectatic coronary arteries, even without the presence of coronary stenosis, are subject to thrombus formation, vasospasm, and spontaneous dissection.

In conclusion coronary artery ectasia/aneurysm may lead to exercise induced ischemia, especially in the diffuse form as in our patient and should be treated like coronary artery disease.

Figure-1

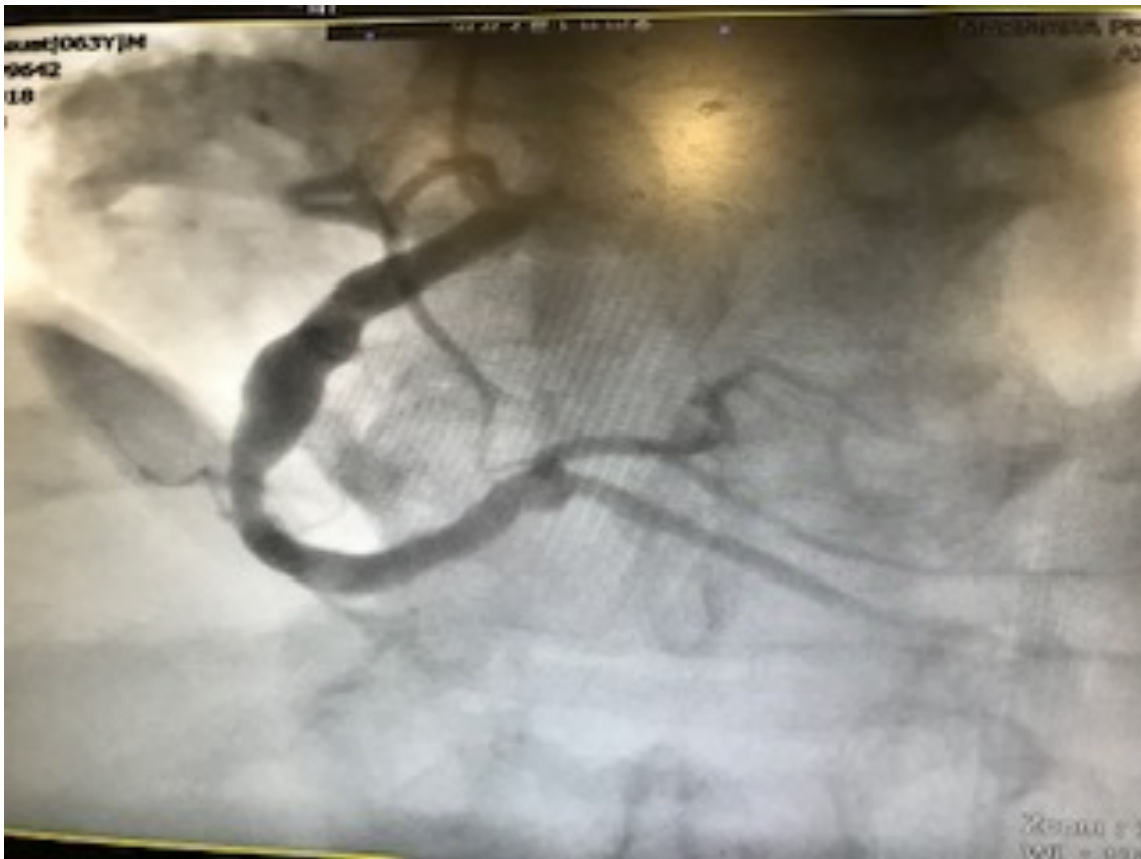

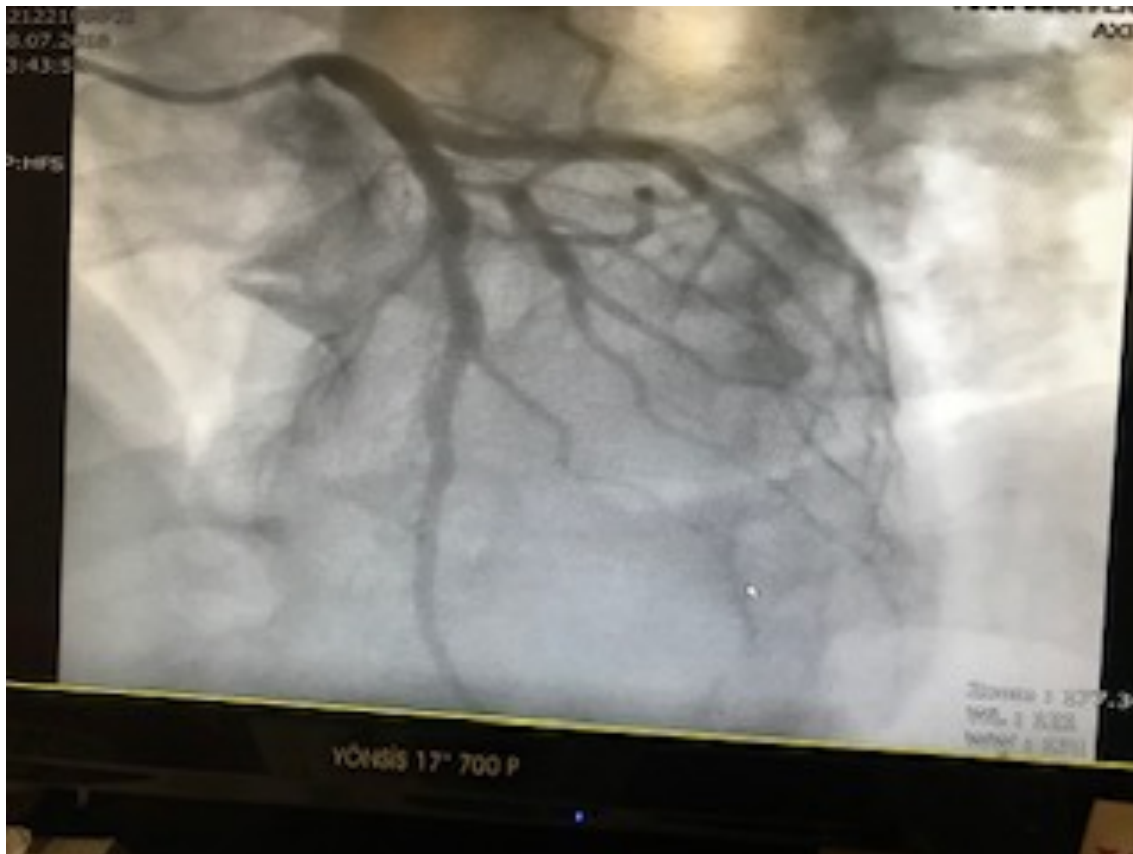
Figure-2

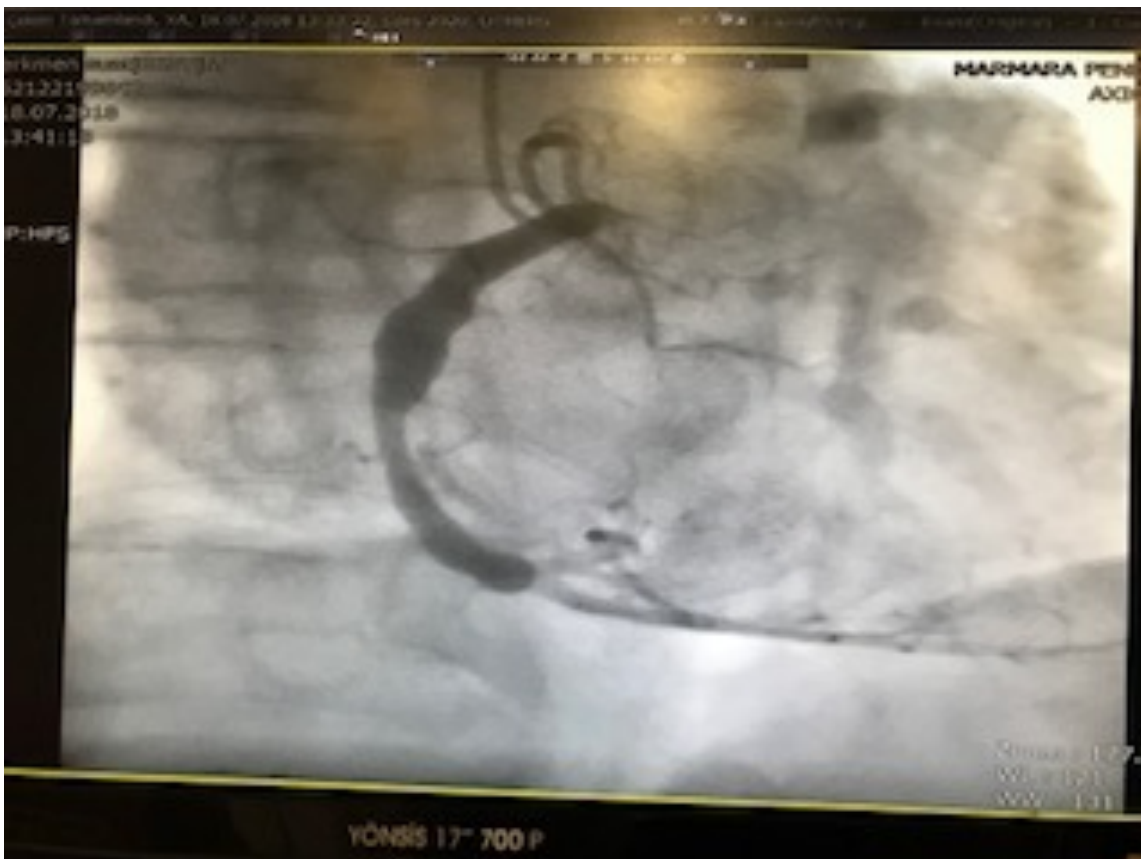

Figure-3

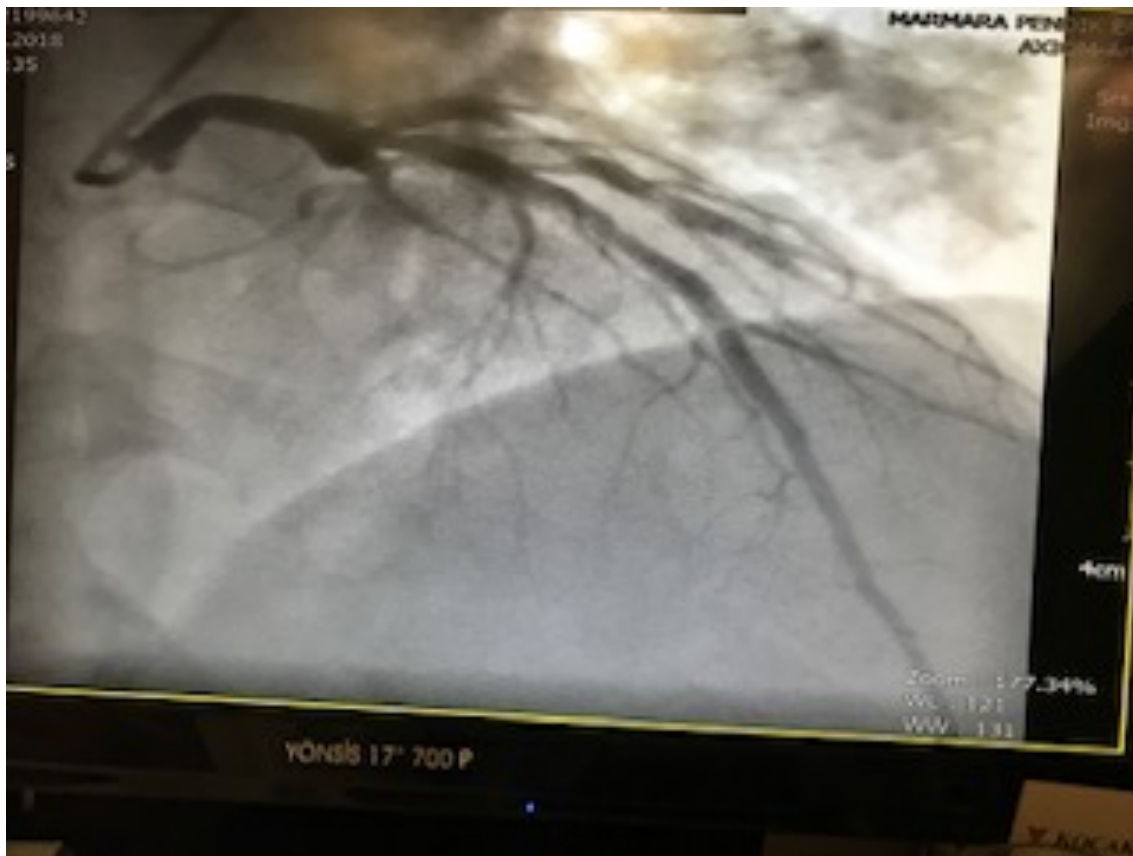

Figure-4



ID: 264

Topic: **Cardiology » Chronic Stable Angina Pectoris**Presentation Type: **Poster****CORONARY ARTERY FISTULA ORIGINATED FROM INTERMEDIATE ARTERY TO RIGHT ATRIUM AND CONCOMITANT MITRAL VALVE PROLAPSUS WITH SEVERE REGURGITATION****Sinan Varol, Ertuğrul Okuyan***Health Sciences University, Bagcilar Training and Research Hospital, Istanbul, Turkey***Corresponding Author (sinanvarol@gmail.com)**sinanvarol@gmail.com***Abstract Text**

Introduction: Coronary fistulas are very rare anatomical structures that originate from the coronary artery and drain into any cardiac chamber or great vessel. The prevalence has been reported as 0.002% in the general population (1). In patients who underwent coronary angiography, prevalence of coronary fistula found as 0.2% (2).

Case Report: 70 years old male admitted to our clinic with mild exertion dyspnea and fatigue. He has hypertension. No history of coronary artery disease or myocardial infarction were present. Physical examination was normal. Electrocardiography showed negative T waves on inferior leads. Transthoracic echocardiography showed mitral valve prolapse of 6 mm on both leaflets. Severe eccentric mitral valve regurgitation was exists. Mitral valve was structurally normal. Coronary angiogram revealed large coronary fistula originated from intermediate artery. It was draining into the right atrium. Because of severe mitral regurgitation, the patient was referred for surgical correction.

Discussion: Coronary fistulas are rare conditions that cause ischemia or exertional dyspnea. Therapeutic options include medical follow up, percutaneous coil embolization or surgical repair. Mitral valve prolapse with significant mitral insufficiency was reported with some case reports (3). In current literature, no information exists if coronary steal syndrome and coronary ischemia a contributor of mitral disease or if coil embolization improves valve functions. In our case, because of no segmental wall motion abnormality or chordal abnormality exist in echocardiography, we thought that valve condition are not related with coronary ischemia or steal. **Conclusion:** Coronary fistulas are rare. Many variations exists based on origin, tortuosity, diameter of fistula, presence of an ectatic segment, draining cavity and concomitant structural defects. The therapeutic decision should be made after careful assessment.

References:

1. Loukas M, Germain AS, Gabriel A, John A, Tubbs RS, Spicer D. Coronary artery fistula: a review. *Cardiovasc Pathol.* 2015;24(3):141–8.
2. Aoyagi S, Fukunaga S, Ishihara K, Egawa N, Hosokawa Y, Nakamura E. Coronary artery fistula from the left circumflex to the coronary sinus. *Int Heart J.* 2006 Jan;47(1):147-52. PubMed PMID: 16479050.
3. Gan H, Liu Y, Liu L, He Y, Zhang S. Coronary artery fistula between the left circumflex artery and right atrium : Multimodal imaging. *Wien Klin Wochenschr.* 2018 Dec;130(23-24):738-739. doi: 10.1007/s00508-018-1409-x. Epub 2018 Nov 12. PubMed PMID: 30421284. Images:

Fig-1:

Coronary angiogram obtained from left caudal view shows coronary fistula originated from intermediate artery and courses over left anterior descending (LAD) artery and after an ectatic segment (double asterisk (**), draining (asterisk (*)) into right atrium (arrows).

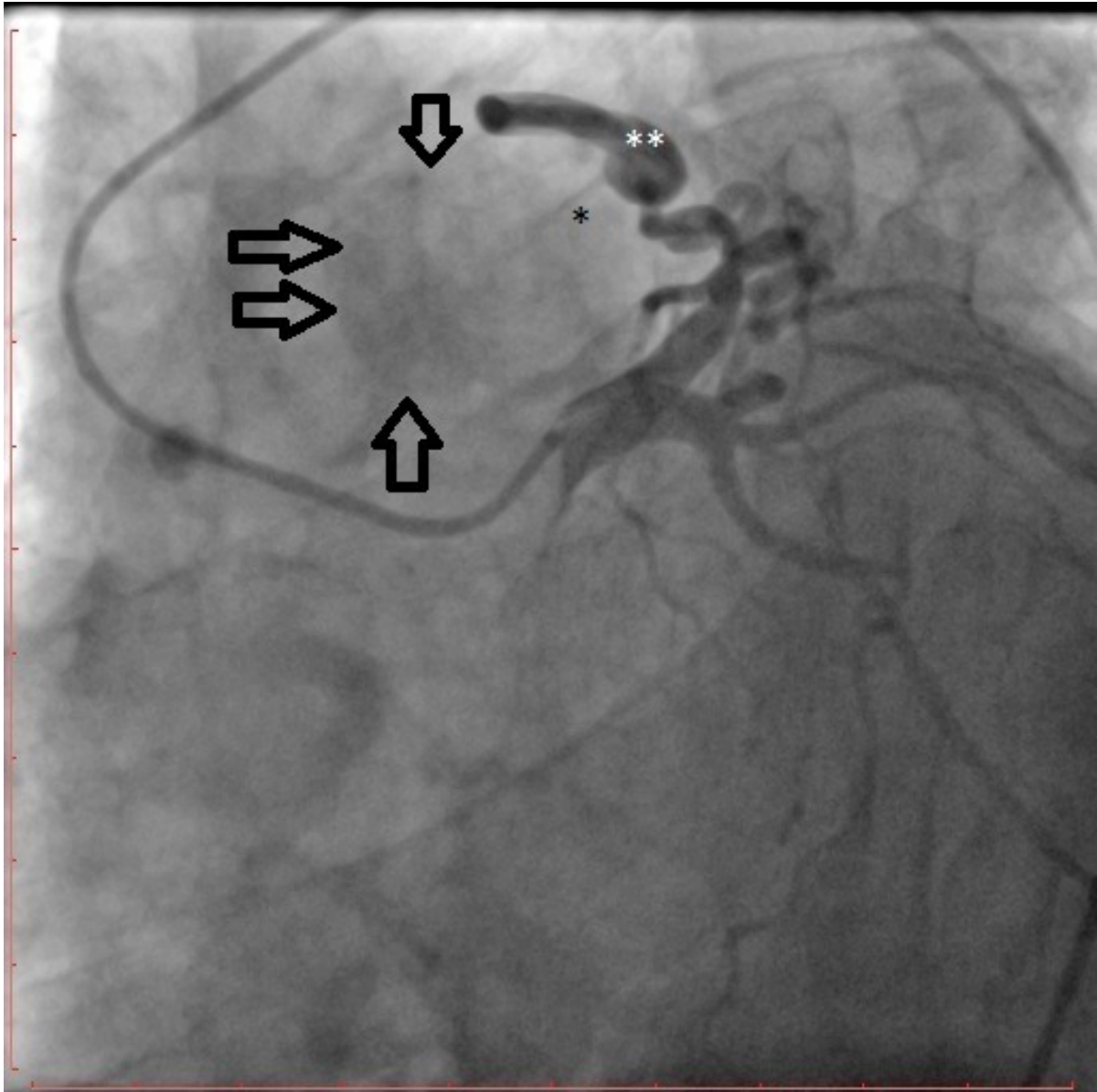


Fig-2.

Right caudal view demonstrated fistula origin (arrow), ectatic segment (double asterisks (**)) and flow (asterisks (*)) of coronary fistula.

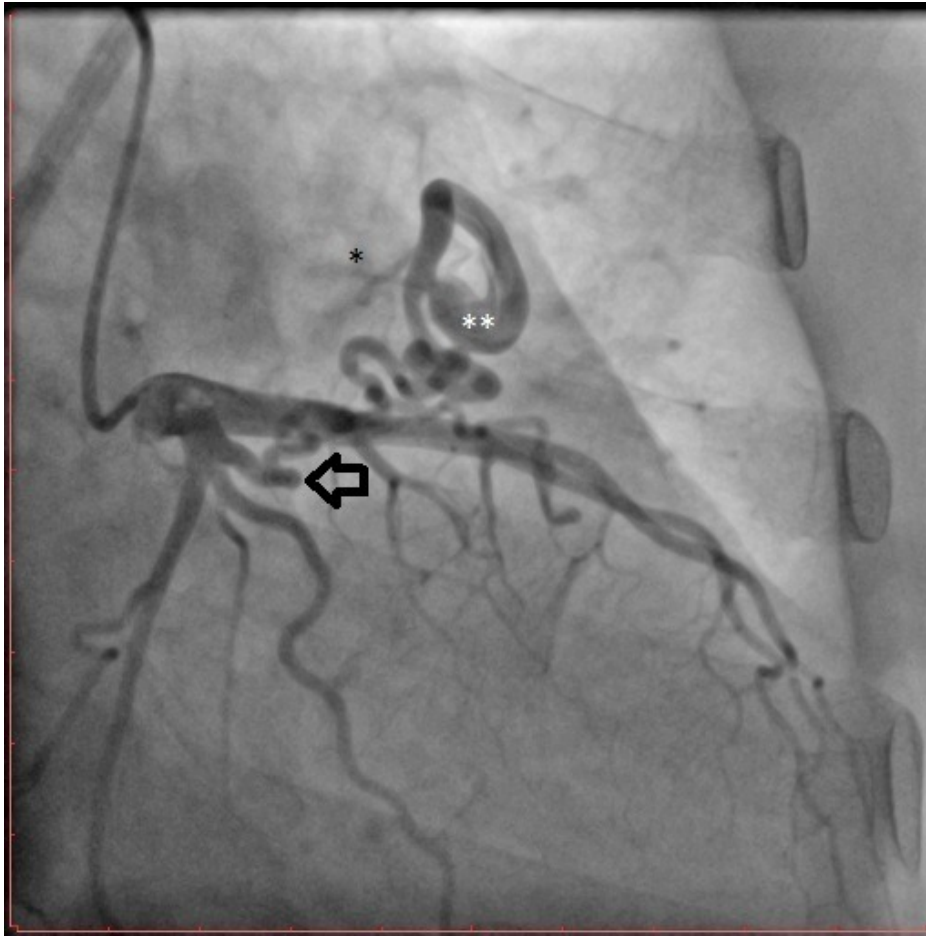
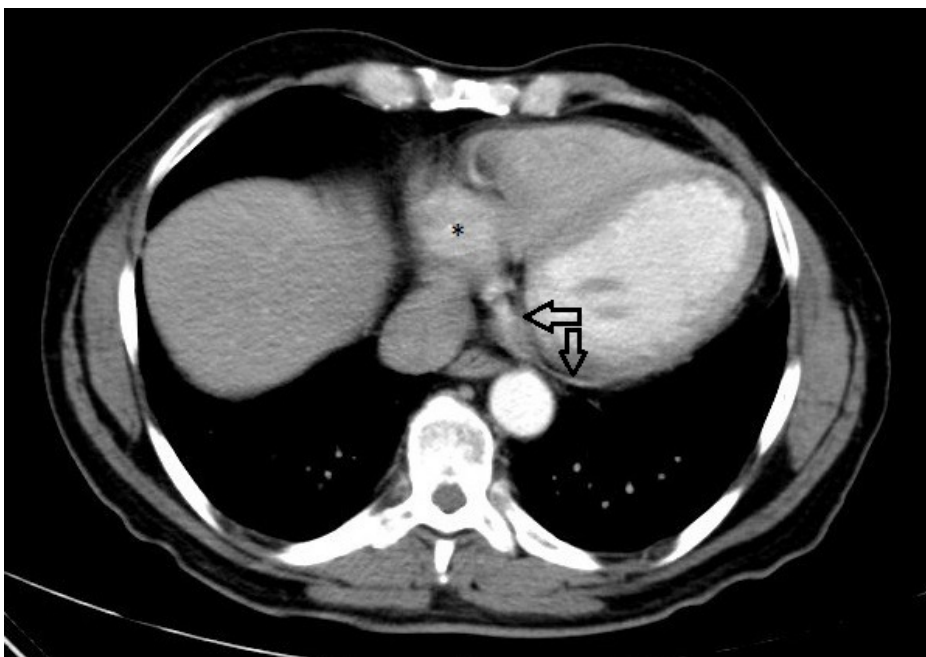


Fig-3. Thorax CT with contrast revealed coronary fistula tract to the right atrium (arrows).



ID: 16

Topic: **Cardiology » Chronic Stable Angina Pectoris**Presentation Type: **Poster****THE IMAGING OF A RARE CAUSING OF ANGINA PECTORIS;
THORACIC OUTLET SYNDROME****Gokay Taylan, Hanefi Yekta Gurlertop, Caglar Kaya***Trakya University, Edirne, Turkey***Corresponding Author (taylan1091@hotmail.com)**taylan1091@hotmail.com, yektagurlertop@trakya.edu.tr, caglarkaya2626@gmail.com***Abstract Text**

THE IMAGING OF A RARE CAUSING OF ANGINA PECTORIS; THORACIC OUTLET SYNDROME

In the evaluation of angina pectoris, the most important symptom of coronary artery disease, many differential diagnoses should be ruled out. The thoracic outlet syndrome is a rare cause of angina pectoris that develops as a result of external pressure to the upper extremity and the vascular structures leading to the upper extremity (the most common adventuriant fibrous bands), especially in patients with a history of previous thoracic trauma or operation. Noninvasive tests (Adson's test, Halsted test, Roos test, hyperabduction test) can be diagnosed or found suspicious cases as an invasive (angiography, venography) can be shown as a compression finding.

CASE: A 63-year-old man, TA: 130 / 80mmHg, has no physical examination, ECG: NSR V5-6 T negativity. Risk factors include smoking, HT, CAD (coronary by-pass operation). Echocardiographic examination revealed EF %50 septum basal hypokinetic + 1 mitral regurgitation. Coronary angiography was performed with the complaint of angina pectoris under medical treatment. Coronary angiography weren't revealed ischemia-induced coronary artery lesion. In the procedure, the image taken at the standard angiography position during left internal mammarian artery imaging showed severe stenosis after internal mammarian artery distinction in the left subclavian artery. The arms were visualized in the neutral position to exclude the thoracic outlet syndrome and the left subclavian artery flow was completely normal. Thus, the diagnosis of Thoracic Outlet Syndrome was made by invasive method.

DISCUSSION: Considering that angiographic imaging of the left subclavian artery may cause a severe stenosis in the standard position, it would be appropriate to prevent additional unnecessary endovascular operation to obtain additional images in the neutral position of the arms before planning the procedure for this stenosis, considering that it may be due to TOS. In addition, since patients with coronary artery by-pass grafting and left internal mammarian artery use may develop severe ischemia due to TOS, noninvasive tests or invasive subclavian arteries may be performed in patients who are decided to be operated.

ID: 386

Topic: **Cardiology » PI for SHD - Others**

Presentation Type: **Poster**

SUCCESSFUL TREATMENT OF LARGE ARTERIOVENOUS FISTULA BETWEEN THE CORONARY TO PULMONARY SYSTEM FEEDING BY TWO CORONARY ARTERIES

Mustafa Demir¹, Atila Iyisoy²

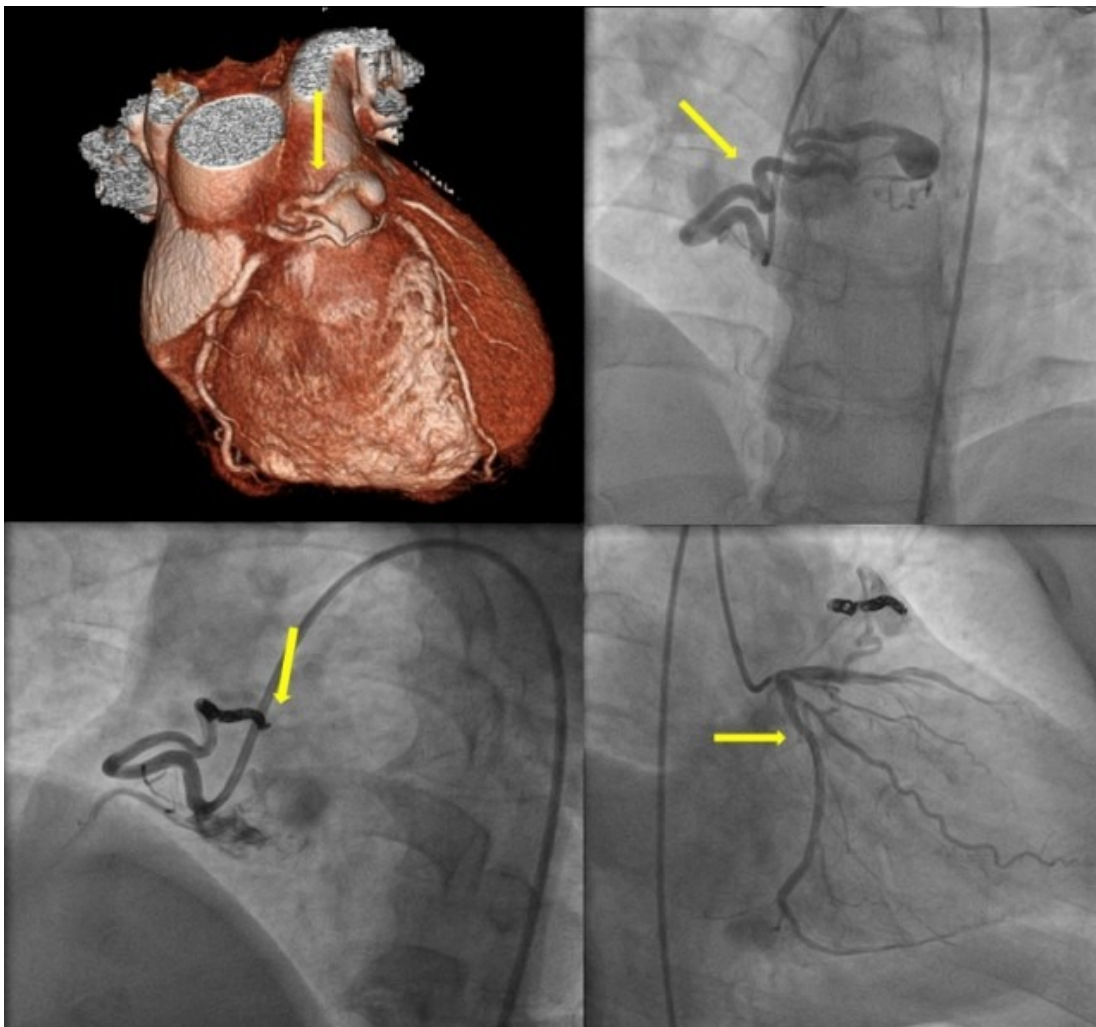
¹*Clinic of Cardiology Tekden Hospital, Denizli, Turkey*

²*Department of Cardiology, Gülhane Training and Research Hospital, Ankara, Turkey*

**Corresponding Author (mstdemir@gmail.com)*

mstdemir@gmail.com, aiyisoy@hotmail.com

Abstract Text



Objective:

Congenital coronary artery fistula (CAF) is a rare coronary artery anomaly of termination. Coronary artery fistulas are present in 0.002% of the general population, but today as a result of increased frequency of cardiac imaging, the prevalence is higher (nearly 0.25%). The first successful coil embolization of CAFs was performed in 1982. Catheter-based interventional techniques have become the procedure of choice in the current era and have emerged as an acceptable alternative to surgery. Herein, we report a case of large arteriovenous fistula between the coronary system to pulmonary system feeding by two coronary arteries, who underwent successful transcatheter closure of CAFs.

Case:

Forty-eight year old male without history of any cardiovascular disease was admitted to outpatient clinic because of atypical chest pain and fatigue during exercise. Physical examination was unremarkable. The ECG showed normal sinus rhythm. Transthoracic echocardiography (TTE) demonstrated a small jet flow in the main pulmonary trunk without definite identification of its source. To clarify this case, we performed Cardiac CT and it revealed a large arteriovenous fistula from the RCA and main pulmonary artery. The procedure was performed with puncture of the right femoral artery and use of a 7F introducer. A 7 Fr guiding catheter was used to cannulate the RCA, but it was seen that the fistula originated from the near side of the right coronary artery, originate from right sinus valsalva. We chose the guide wire of neo's Fielder FC (St. Jude Medical, St. Paul, MN, USA) because of good traceability and steerability. A micro catheter was advanced over the guide wire into the fistula, until the curved segment closer to the PA. Nine concerto helix detachable coil system were sequentially released inside the fistula until total blood flow obstruction was achieved (Figure 1). Then we displayed the left coronary system there is surprise for us because we showed other small branch originate from CFX feeding by pulmonary fistula. Due to the small size of the branch, was not considered closure and the procedure was terminated without any complications. We did not administer any antiplatelet or anticoagulant therapy after the procedure.

Results and Conclusions:

Coronary artery fistulae are rare cardiac anomalies and the first case was described in 1865. The location of the drainage site of a fistula has more clinical importance than the origin because drainage into low-pressure sites may result in increased tortuosity and caliber of the fistula. Although most patients have no symptoms, and findings are noticed incidentally at cardiac imaging (conventional catheter angiography or MDCT), some patients may have exertional dyspnea and fatigue. In this case, our patient had exertional chest pain and fatigue due to CAFs without atherosclerotic coronary artery disease. We therefore decided on transcatheter closure of the CAFs. After one day the procedure we discharged patient without any complications. Transcatheter closure of the CAF is feasible and safe in the anatomically suitable vessels. We can say that occlusion by transcatheter coil embolization for the CAF should be considered more often, because it is low cost with a short post-procedural hospital stay and minimal period of rehabilitation, low risk of myocardial damage, and advantage of avoiding a thoracotomy and cardiopulmonary bypass compared with traditional operation.

ID: 446

Topic: Cardiology » Percutaneous Coronary Interventions**Presentation Type: Poster****SUBCLINICAL HYPERTHYROIDISM DUE TO IODINE CONTAINING
CONTRAST MEDIA IN A CABG PATIENT**Mehmet Ali Yeşiltaş, **Ismail Yavuz Keleş**, Sadiye Deniz Özsoy*Istanbul University Cerrahpaşa Institute of Cardiology, İstanbul, Turkey***Corresponding Author (dr.maliyes@gmail.com)**dr.maliyes@gmail.com, yavuzkeles92@gmail.com, sdenizozsoy@gmail.com*

Abstract Text

Thyroid dysfunctions such as hypothyroidism and hyperthyroidism can cause complications in preoperative, peroperative and postoperative periods of all kind of non-thyroid surgeries. Preoperative thyroid function tests are not recommended in normal population. But if diagnosed before the surgery, these conditions can be optimized with medical treatment in order the reduce the morbidity and mortality of the patient.

56 year old male patient with history of diabetes, hypertension and hyperlipidemia refered to our department for CABG surgery after cardiology evaluation. Preoperative physical examination was normal. His laboratory workup revealed very low levels of TSH (0,032) and slightly above normal levels of T3 (4,55) and T4 (1,79). Patient had no history of thyroid surgery or any symptoms related to hyperthyroidism beforehand. We consulted the patient with department of internal medicine to learn whetever the patient was eligible for surgery. In order to find the cause of hyperthroidism and suppressed TSH they suggested USG of the thyroid gland and thyroid scinthigraphy with Tc-99m. They also suggested some laboratory tests to rule out auto-immune thyroiditis such as anti-tpo, anti-thyroglobulin and anti-TSH. All laboratory tests came as negative. We consulted patient with the radiology department for thyroid USG which revealed bilateral enlarged thyroid gland size. (right lobe 20mm, left lobe 26mm) After that we sent the patient to nuclear medicine department. Scintigraphy showed increased background activity in the thyroid gland. We discussed the patient with our colleagues from other specialties we mentioned above and came to a conclusion that this might be a result of exogenous iodine intake. We checked with the cardiology department about which contrast media was used during patient's angiography. They told us that patient was injected with omnipaque which contains iodine. With all this information we consulted the patient with internal medicine department once more for surgery. They recommended thyromazol 3x5 mg daily and said that patient can be operated when his T3 and T4 values fall back to the normal levels. After 5 days of thyromazol treatment patient was euthyroid and scheduled for surgery. We performed CABG with 3 coronary anastomoses with cardiopulmonary bypass. Patient extubated on the postoperative eighth hour and transferred to the wards at postoperative second day with no complications during intensive care period. Patient discharged at sixth postoperative day with a consultation note for internal medicine in order to adjust the thyromzaol treatment.

Thyroid hormone production depends on the amount of iodine intake. Exogenous iodine intake is generally well tolerated but dysfunctions can arise in susceptible patients due to many different factors. Contrast medias used in angiography studies are a common source of exogenous iodine. All contrast medias contain different amounts of iodine and each of their iodine content is far more greater than our daily iodine allowance. Although preoperative thyroid function tests are not recommended in patients without prior history of thyroid disease, if diagnosed before angiography we can choose a low iodine containing contrast media in order to decrease the risk of patient developing hyperthyroidism. This case report shows that patients without prior thyroid abnormalities can also benefit from preoperative/preangiographic thyroid function tests.

ID: 516

Topic: Cardiology » Percutaneous Coronary Interventions in Acute Coronary SyndromesPresentation Type: **Poster****PRIMARY PERCUTANEOUS CORONARY INTERVENTION IN ANOMALOUS OF HIGH ANTERIOR TAKEOFF RIGHT CORONARY ARTERY****Kahraman Cosansu, Harun Kilic***Sakarya University, Education and Research Hospital, Sakarya, Turkey***Corresponding Author (kahraman141@gmail.com)**kahraman141@gmail.com, harunkilic@sakarya.edu.tr*

Abstract Text

Background

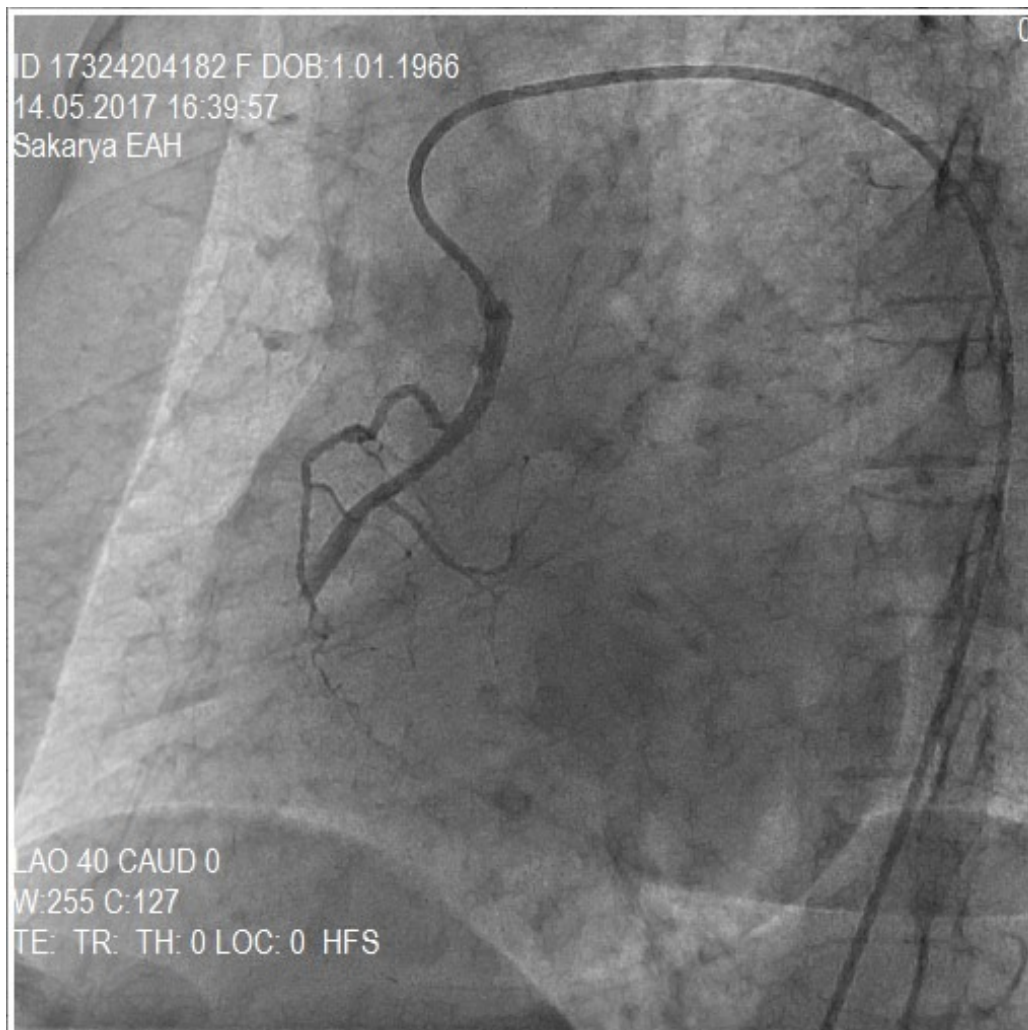
One of the very rare subtypes of coronary artery anomalies is anomalous right coronary artery (RCA) with high anterior takeoff. Various catheters are used for this anomaly which is quite difficult to cannulate in selective coronary angiography, but this increases the time and the cost of procedure. We presented the case in which the culprit lesion was high anterior takeoff RCA in the patient admitted to hospital with acute inferior myocardial infarction (MI), and in which a successful primary PCI was applied to a rare coronary anomaly.

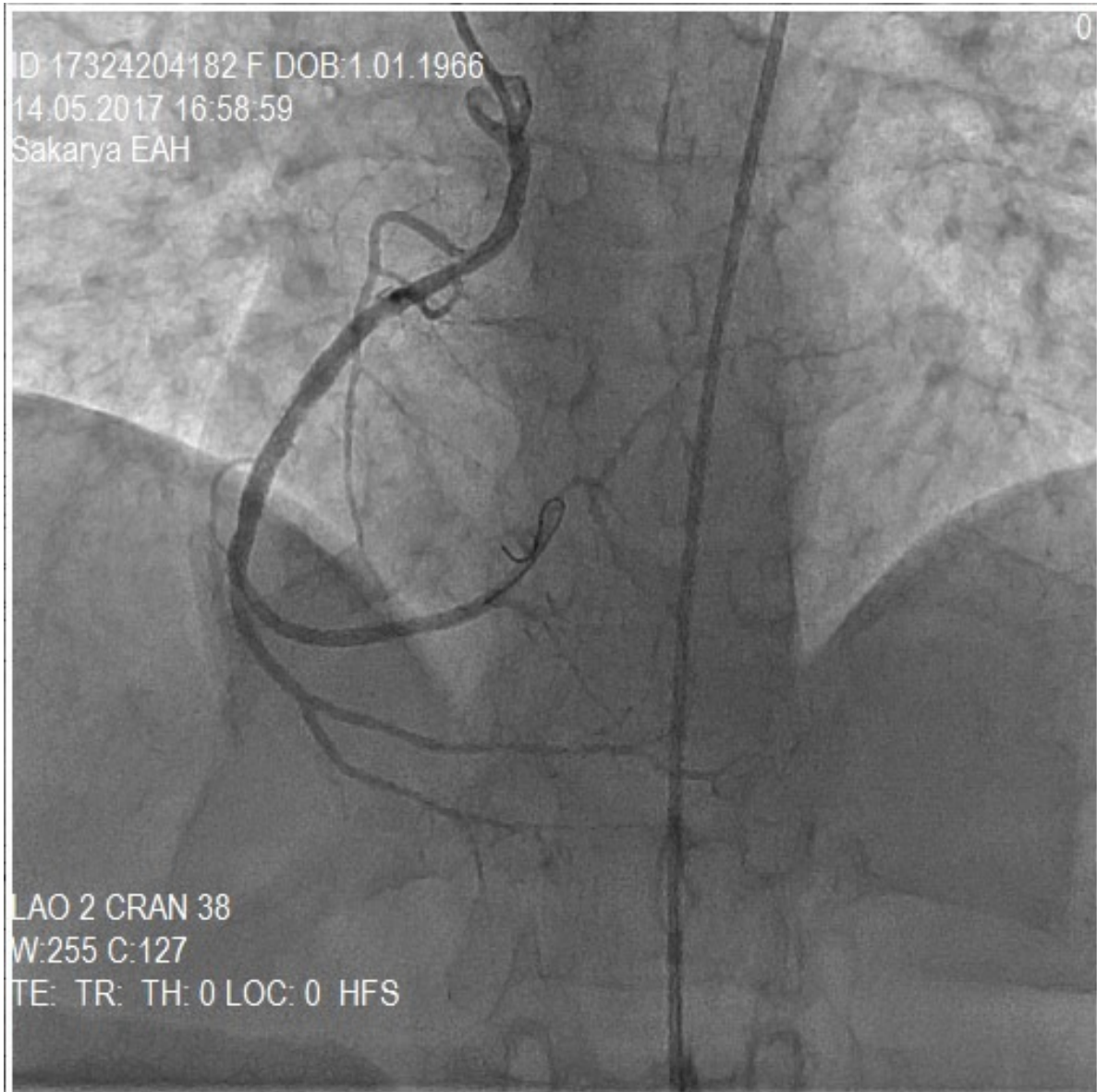
Case Report

51 year old female patient with typical anginal pain in last 3 hours was admitted to our hospital. There were no risk factors for coronary artery disease except smoking. There was ST elevation in the inferior leads and reciprocal ST depression in leads D1-AVL on admission electrocardiography. The patient was taken to the catheter laboratory for primary PCI with the diagnosis of acute inferior MI. RCA could not be displayed with Judkins guiding catheters of different sizes and then despite the use of, respectively, Amplatz left-2 and right-1-2 guiding catheters, cannulation still was not achieved. The cannulation was tried by giving small opaque doses with Amplatz left-1 catheter and retract it slowly back. Finally, the cannulation and adequate back-up was provided when the Amplatz-1 guiding catheter was in an abnormally high catheter position. In the imaging, high anterior takeoff of RCA was determined and RCA in the mid-region totally (Figure 1). RCA lesion was passed through by 0,014 inch floppy guidewire and after predilatation by 2.0x20 mm balloon and 3.0x24 mm everolimus eluting stent was implanted (Figure 2). There was no complication during the procedure and two days later the patient was discharged uneventfully.

Conclusion

In cases when the RCA cannot be cannulated, high anterior takeoff RCA should be kept in mind and the cannulation can be tried by giving small opaque doses with AL catheter in high positions. Also, this method can contribute to the reduction of morbidity and mortality by reducing procedure time and the amount of opaque.





ID: 276

Topic: Cardiology » Percutaneous Coronary Interventions**Presentation Type: Poster****TEMPORARY BLINDNESS AFTER CORONARY ANGIOGRAPHY****Abdi Sağcan, Hamed Moghanchi, Murat Tümüklü, Mustafa Zungur, Cevad Şeküri***Kent Hospital, Izmir, Turkey***Corresponding Author (abdi.sagcan@kenthospital.com)**abdi.sagcan@kenthospital.com, hmoghanchi@yahoo.com, mmurat.tumuklu@kenthospital.com, drzungur@yahoo.com, csekuri@hotmail.com***Abstract Text**

BACKGROUND AND AIM: Coronary angiography is the current gold standard for the diagnosis of ischemic heart disease and therefore the prevalence of percutaneous coronary procedures such as angiography and angioplasty is high. The prevalence of temporary blindness after X-ray contrast media is low and it is usually seen after cerebral angiography.

Cerebrovascular complications of coronary angiography and PCI are rare and usually include transient ischemic attacks (TIA) or stroke and affect approximately 0.4% of all patients undergoing PCI. These complications occur more often in some specific groups of patients: in the elderly, in female patients, in patients with diabetes mellitus type 2, in those with diffuse atherosclerosis, in patients undergoing coronary artery bypass grafting, in patients with peri-procedural complications (artery dissection) and in patients with no-reflow who often require intra-aortic counterpulsation. Cortical visual impairment following administration of a contrast agent occurs in 0.3-1.0% of patients undergoing angiography of the cerebral arteries. In the case of coronary angiography the rate is 0.21-0.45% [4]. This is a very rare complication given the widespread and frequent use of coronary angiography throughout the world. Patients at risk of cortical visual impairment include those after previous coronary artery bypass grafting and patients with renal failure. The exact mechanism leading to the onset of cortical visual impairment remains unknown. The most likely explanation of this phenomenon is an increase of permeability of the blood-brain barrier and a direct neurotoxic effect of contrast agents

Case report: A 76 years old male patient with hyperlipidemia, DM, CABG with history of cardiac arrest was referred for coronary angiography by his physician. Coronary angiography was performed through the right femoral artery with a 6 F vascular sheath and Judkins diagnostic catheters and was preceded by local anesthesia with 1% lignocaine solution.

The procedure lasted 40 min and the patient remained hemodynamically stable for the whole time. Approximately 400 ml of a nonionic, hypo-osmolar contrast agent was used for the procedure. The patient did not have a history of previous procedures with contrast medium administration. During coronary angiography the patient reported no visual impairment. Three out of four grafts were open and medical follow up was planned.

2-3 hours after the coronary angiography the patient underwent neurological and ophthalmological consultation. Apart from binocular blindness there were no other abnormalities. Urgently performed diffusion MRI of the head (without contrast medium) and carotid vertebral doppler revealed no acute changes. Visual impairment resolved completely on the first day after the coronary angiography.

The pathophysiology of transient cortical visual impairment is not clear. Most likely, the blood-brain barrier becomes damaged, which allows the contrast agent to express a direct neurotoxic effect on nerve cell membranes in the occipital lobes.

The risk factors also include renal failure and coronary bypass from the internal mammary artery (the origin of the internal mammary artery from the subclavian artery close to the origin of the vertebral artery may favor the passage of a large amount of contrast agent to the left vertebral artery during bypassography of the left internal mammary artery)

ID: 318

Topic: **Cardiology » Percutaneous Coronary Interventions**Presentation Type: **Poster****SINGLE SHOT FOR THE CORONARIES: SINGLE CORONARY ARTERY**Çağlar Kaya¹, Gökay Taylan¹, Yücel Uzun², Bilal Geyik²¹Medicine Faculty of Trakya University, Edirne, Turkey²Clinic of Lüleburgaz Medikent Hospital, Kırklareli/Lüleburgaz, Turkey^{*}Corresponding Author (caglkaya2626@gmail.com)

caglkaya2626@gmail.com, taylan1091@hotmail.com, uzuny1973@hotmail.com, bgeyik@gmail.com

Abstract Text

A 68-year-old male patient was admitted to emergency room 2 hour after onset of chest pain. He had histories of diabetes mellitus, hypertension and smoker. First evaluation his BP was 105/70 mmHg, his heart rate was 91 bpm, respiratory rate was 24/min, and oxygen saturation was 96%. On physical examination, there were no abnormality. Electrocardiogram (ECG) showed normal sinus rhythm with 75 heart bpm, and ST segment depression at II, aVF, and V3-6 leads (Figure 1). He was referred to the Coronary Intensive Care Unit with a diagnosis of non-ST elevation myocardial infarction. After 300 mg acetylsalicylic acid, 600 mg clopidogrel and 5000 IU unfractionated heparin load, a coronary angiography was performed and the whole coronary system originated by a single trunk from the Right-Anterior sinus of Valsalva (Figure 2). Angiography revealed %50 stenosis in LMCA, 40% stenosis in the proximal LAD, 50% in the om1, %80 in the CX. The distal RCA is filled with collaterals. There was 99% stenosis in the RCA ostial and diffuse stenosis in the whole RCA

A single coronary artery (SCA) is a coronary anomaly in which all coronary vessels originate from the single ostium in the aorta and feed the whole heart. SCA is usually asymptomatic, but this anomaly can lead to stable angina pectoris, acute coronary syndromes and sudden cardiac death. Especially some cases, in which a coronary artery traverses between the pulmonary artery and aorta, are very important for sudden death. SCA with atherosclerosis is a rare condition in coronary anomalies. Presenting ECGs are usually atypical. In our case, although inferior ischemia was a possible Inferior Myocardial Infarction, it was presented as extensive St depression. Coronary artery anomalies are seen more frequently with the increase in the frequency of angiography and can be seen with various lesions as in this case. Here, we present a rare case with a single coronary artery anomaly presenting with acute coronary syndrome.

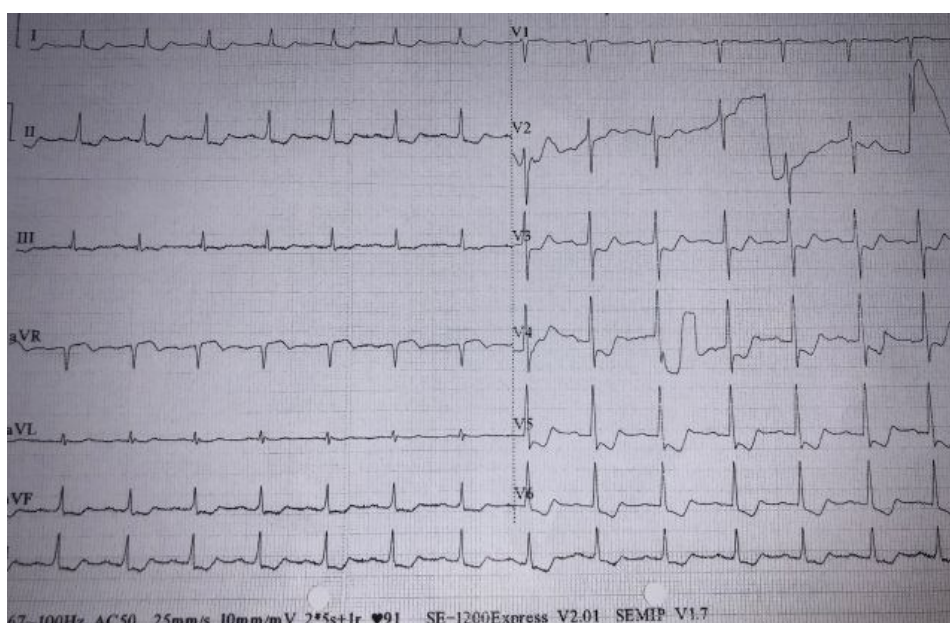


Figure 1: ECG shows ischemic findings before the angiography.

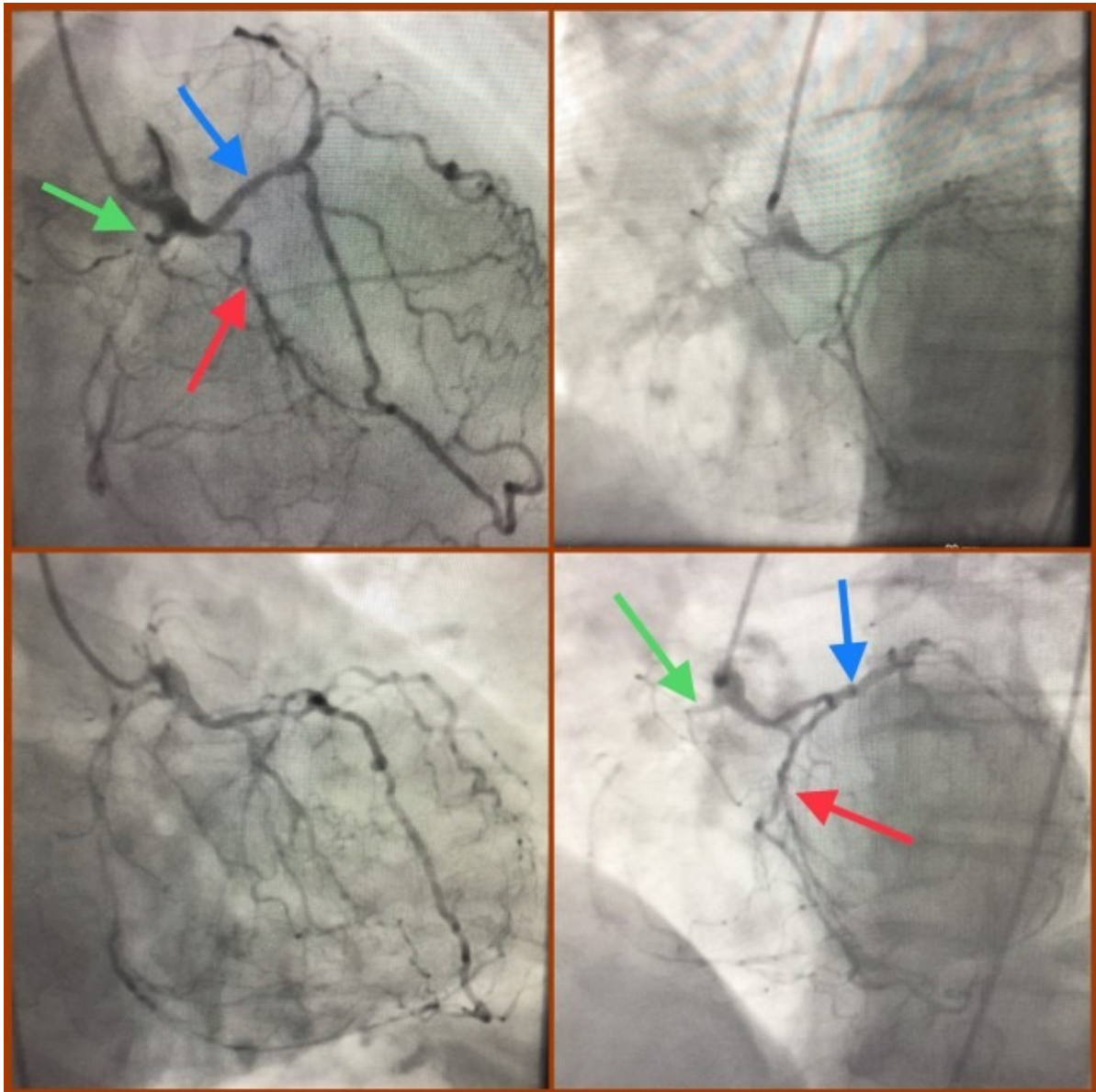


Figure 2: Coronary Angiography (Single Coronary Artery)

Green Arrow: Right Coronary Artery

Red Arrow: Circumflex Coronary Artery

Blue Arrow: Left Anterior Descending Artery

ID: 148

Topic: Cardiology » Percutaneous Coronary Interventions in Acute Coronary SyndromesPresentation Type: **Poster****A RARE CORONARY ARTERY ANOMALY: WOVEN CORONARY ARTERY****Müjgan Gürler¹, Muzaffer Kahyaoglu²***¹Abant İzzet Baysal University Faculty of Medicine, Bolu, Turkey**²Kartal Kosuyolu Heart and Research Hospital, Istanbul, Turkey***Corresponding Author (drmgurler@gmail.com)**drmgurler@gmail.com, koronerr@hotmail.com***Abstract Text**

67 years old male patient presented to the emergency room because of chest pain. His vital signs were heart rate 85 bpm; arterial blood pressure 145/80 mmHg and pulse oxygen saturation 98%, respectively. Physical examination was unremarkable. Electrocardiography showed ST segment elevation in anterior derivations. After giving ASA, clopidogrel and unfractionated heparin, the patient was taken coronary angiography laboratory. Coronary angiography revealed thin channels in right coronary artery (RCA) and it was described woven coronary artery (Figure A, Video 1). On anteroposterior cranial view of RCA, it was detected multiple thin channels and septal collaterals by conus artery of RCA (Figure B, Video 2). Medical treatment was decided for RCA lesion. Left system coronary angiography revealed occluded left anterior descending artery (LAD). After passing wire, it was detected LAD proximal lesion (Figure C). 3.0*24 mm drug eluting stent was implanted then was performed post-dilatation by 3,5*13 mm non-compliant balloon and TIMI 3 flow was achieved (Figure D, Video 3). The patient was discharged from the hospital successfully.

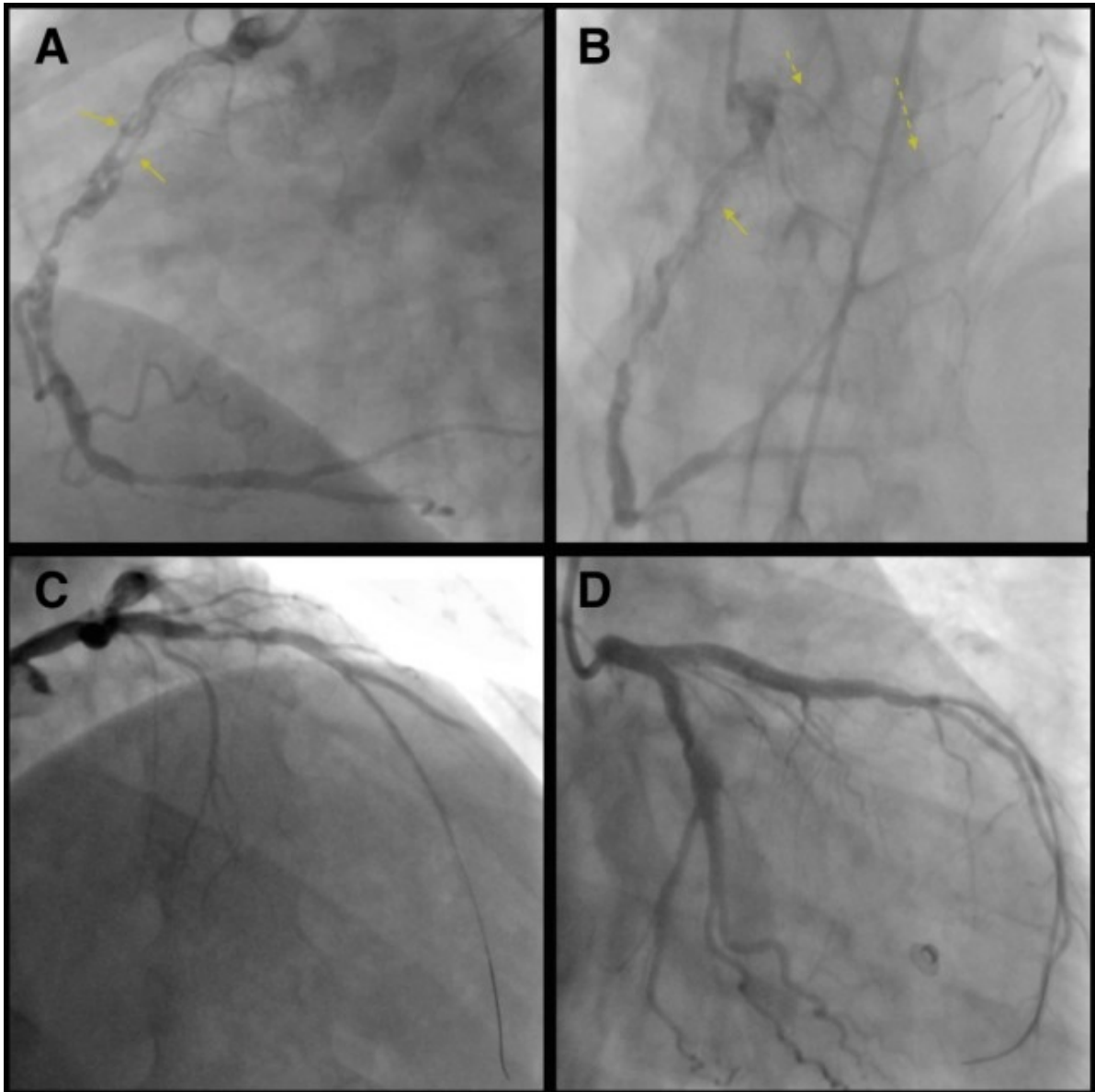
**FIGURE LEGENDS:**

Figure A: On left oblique view of RCA, it was described woven coronary artery (arrow) with multiple thin channels.

Figure B: On anteroposterior cranial view of RCA, it was showed woven coronary artery (arrow) and septal collaterals by conus artery of RCA (dotted arrow).

Figure C: It was detected LAD proximal lesion after wiring.

Figure D: After stenting, TIMI 3 flow was achieved. LAD: Left anterior descending artery , RCA: Right coronary artery

SUPPLEMENTARY MATERIALS:

Video 1, for Figure A

Video 2, for Figure B

Video 3, for Figure D

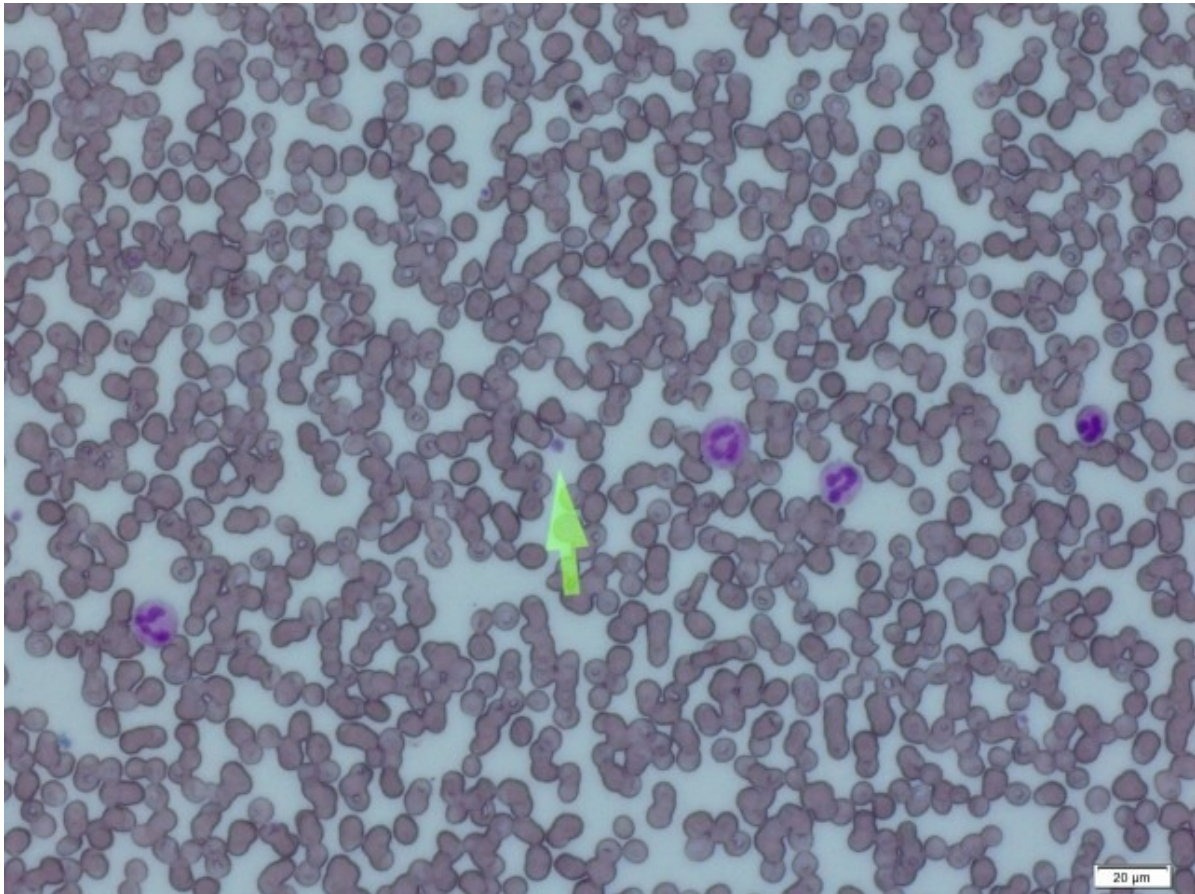
ID: 100

Topic: Cardiology » Percutaneous Coronary Interventions in Acute Coronary SyndromesPresentation Type: **Poster****SEVERE THROMBOCYTOPENIA ASSOCIATED WITH LOW DOSE OF INTRACORONARY TIROFIBAN**Yaşar Turan, **Vahit Demir**, Siho Hidayet*Bozok University, Faculty of medicine, Yozgat, Turkey***Corresponding Author (yasar044@yahoo.com)**yasar044@yahoo.com, dr.vdemir@hotmail.com, shhidayet@hotmail.com***Abstract Text**

Introduction: Glycoprotein IIb/IIIa inhibitors (GPI) are frequently used for the treatment of acute coronary syndromes and percutaneous coronary interventions to prevent platelet aggregation and thrombus formation. Tirofiban, a specific and nonpeptide GPI, competitively inhibits the platelet fibrinogen receptor and may lead to thrombocytopenia. The mechanism is thought to be drug-dependent antibodies. Herein, we report a case of tirofiban-induced severe thrombocytopenia after the administration of the initial dose of tirofiban.

Case: A 74-years-old male patient was admitted to the emergency department with a complaint of chest pain. The patient was scheduled for coronary angiography with the diagnosis of non-ST-segment elevation myocardial infarction (NSTEMI) after pretreatment with aspirin and clopidogrel, 5,000 IU of intravenous unfractionated heparin. The angiography showed 85% occlusion of left anterior descending coronary artery (LAD) mid segment and a 70% stent restenosis in the proximal segment of the circumflex coronary artery (Cx). After predilatation, a 2.75x16 mm drug eluted Cre8 stent (CID, Saluggia, Italy) was implanted to LAD. After the decision of percutaneous coronary intervention (PCI) for the stent restenosis in Cx, tirofiban via intracoronary route at a dose of 10 mcg/kg was administered. The instent stenosis was dilatated with a 3.5x12 mm non-compliant balloon. After a few minutes, the patient had the complaints of nausea, abdominal pain and chills. Due to suspicion of allergic reaction, all the medications were discontinued immediately. A contrast-induced reaction was thought and he was administered 2 ml of pheniramine maleate and 40 mg of methylprednisolone intravenously. A marked improvement was observed in the patient, after the treatment. He had no prior treatment history with tirofiban, therefore tirofiban terminated while other medications were continued. The patient was stable on the rest of the day. Before the intervention, his platelet count was 200x109/L. Twelve hours after PCI, the control hemogram showed severe thrombocytopenia with a platelet count of 16x109/L, declining to 9x 109/L 1 hour later, upon repeat testing. Areas of petechiae and ecchymoses were observed around the sternum, on hands and legs. Review of the peripheral smear of blood sample confirmed the lack of platelets with no clumping (Fig- 1). The antiplatelet drugs and enoxoparin were immediately stopped, and the patient was transfused with 4 units of platelets. No major bleeding complication was occurred, and the platelet count increased to 46x109/L after the transfusion, to 55x109/L on the next day and continued to improve. The patient did demonstrate neither any evidence of bleeding related adverse events, nor hemodynamic instability and he was discharged on the 5th day with the treatment of aspirin 100 mg, clopidogrel 75 mg, metoprolol 50 mg, ramipril 2.5 mg, and atorvastatin 20 mg once daily. His platelet count was 299x109/L on the 10th day control.

Conclusion: There are different patterns of GPI-induced thrombocytopenia and the clinical features of our case may be compatible with anaphylactic type. In severe cases, intravenous corticosteroids for anaphylactic symptoms and platelet transfusions for worsening thrombocytopenia may be helpful. This case emphasizes the importance of awareness of the life threatening thrombocytopenia associated with even low dose of tirofiban use.



ID: 250

Topic: **Cardiology** » **Percutaneous Coronary Interventions**

Presentation Type: **Poster**

**IS THE EF REDUCTION IN ONCOLOGY PATIENTS ALWAYS
DEPENDENT ON CHEMOTHERAPEUTIC AGENTS?**

Mehmet Inanir, Emrah Erdal

Bolu Abant Izzet Baysal University, Bolu, Turkey

**Corresponding Author (mdmehmetinanir@yahoo.com)*

mdmehmetinanir@yahoo.com, dr.emraherdal@gmail.com

Abstract Text

OBJECTIVE AND METHODS

A 61-year-old male patient; In February 2016, he received chemotherapy treatment for 8 months with the diagnosis of rectal adeno CA. Low EF levels were evaluated by the cardiology outpatient clinic and low EF (EF 25-30%) was thought to be related to chemotherapeutic agents. Therefore chemotherapeutic agents were interrupted for a while. However, the patient was referred to the cardiology outpatient clinic. Coronary angiography was planned in order to exclude ischemic cardiomyopathy on the basis of high coronary artery disease risk factors and echocardiographic examination and segmental wall motion defects.

Physical examination: Consciousness open, cooperative orientation. TA: 165/92 mm Hg. Nb: 88 min / rhythmic, ral present in the basals lungs, apical beat prominent, S1 +, S2 + were observed. All pulses are palpable.

ECG: Sinus rhythm, LBBB, deep S waves.

ECHO: LVEF: 25-30% segmentar wall motion defect. End diastolic diameter: 6.2 cm), Mild Mitral Regurgitation, Mild Tricuspid Deficiency, PABs: 45 mm Hg

Laboratory: Normal

Family history: Diabetes mellitus and hypertension at the father are available. The mother has also hypertension.

Curriculum vitae: 2 DM for 7 years, 10 pack years of smoking, inferior MI in 2014: RCA; 2.75 * 26 mm BMS stent implanted. EF: 55% inferior areas mild hypokinetic.

In February 2016, he was diagnosed with rectum adeno ca after colonoscopy due to bloody diarrhea. It's being operated. (liver metastasectomy + operative rectum adenocarcinoma).

The patient was given 6 courses of Xelox (oxaliplatin + capecitabine).

Second line chemotherapeutic (TC) agents due to relapse CA (folfiri and bevacizumab) in January 2017.

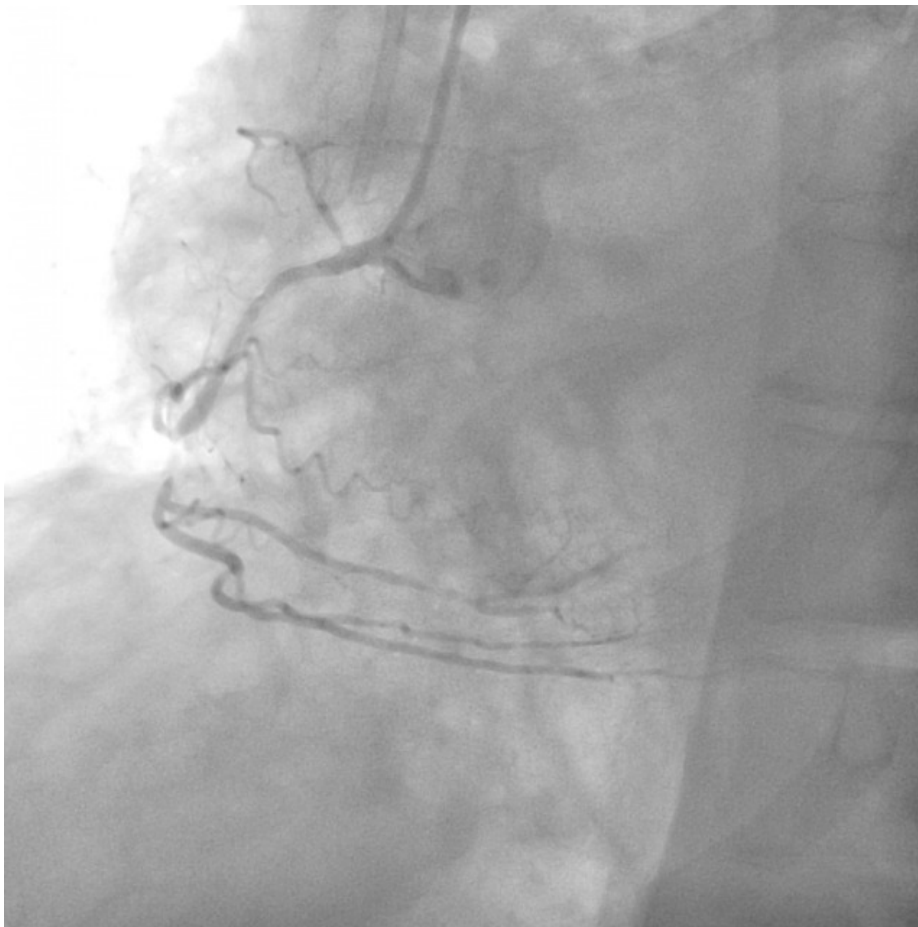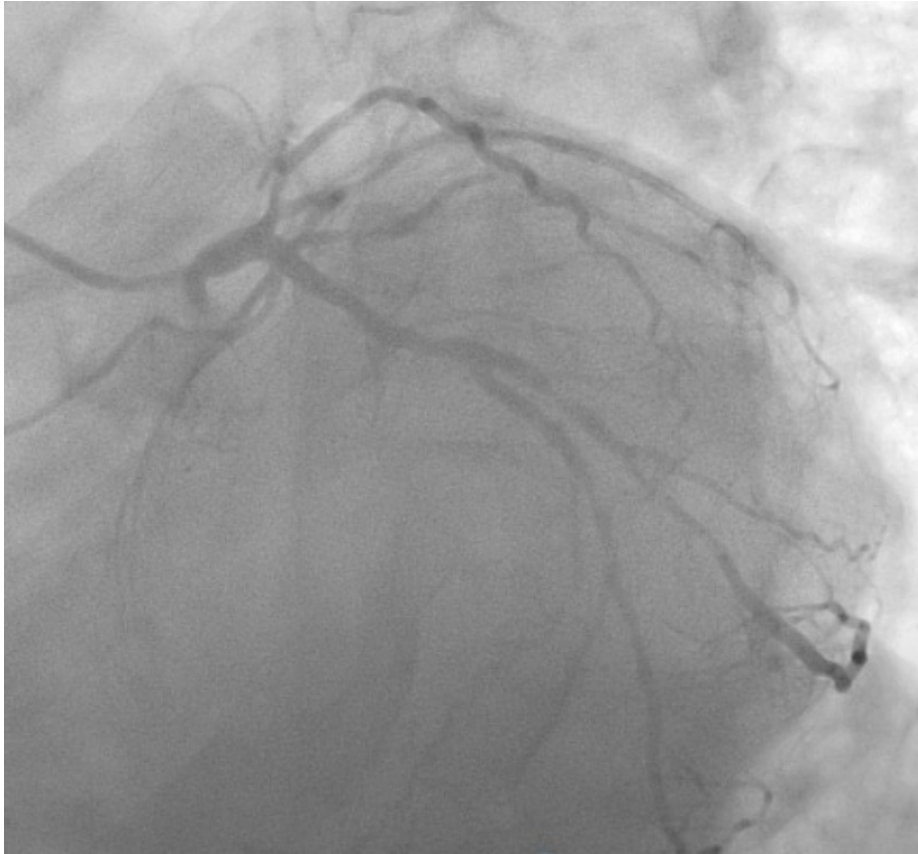
RESULTS

In the coronary angiography performed in May 2017, LAD had a total occlusion (distal to weak retrograde filling), and RCA and CX showed critical stenosis. PCI was applied to RCA and CX critical lesions. The patient continued the routine chemotherapy protocol. In the control echocardiographic control performed 7 months later, EF was evaluated as 40-45%. LV diameters were reduced and systolic functions were improved.

DISCUSSION

Chemotherapeutic agents have cardiac toxic effects. 2016 ESC Cancer Treatment Cardiovascular Toxicity Guide is mentioned in detail about KT agents.

The incidence of EF abortion due to bevacizumaba ranged between 1.6-4%. Although chemotherapeutic agents in the left ventricular systolic dysfunction occur in patients receiving chemotherapy, it is thought that; Coronary artery disease should not be missed in individuals with high risk factors especially for coronary artery disease.



ID: 450

Topic: **Cardiology » Percutaneous Coronary Interventions**Presentation Type: **Poster****SUCCESSFUL TREATMENT OF TRAPPED AND STRIPPED STENT IN THE OTHER STENT****Taner Sarak***Kırıkkale University Faculty of Medicine, Kırıkkale/Merkez, Turkey***Corresponding Author (tansara@ttmail.com)**tansara@ttmail.com***Abstract Text**

Objective: Stent stripping is serious complication encountered during percutaneous coronary procedures(PTCA). The incidence rate is around 1%. This complication can lead to serious consequences such as the need for emergency coronary artery bypass surgery, myocardial infarction or death. Different techniques and devices are used to retrieve the stripped stent. Sometimes it cannot be retrieved and it is necessary to push it forward, to crush or implant it in its place. This presentation describe a trapped and stripped stent in the other stent in a patient with non ST elevation myocardial infarction(NSTEMI).

Methods, Results: A 43 years old male recently have typically chest pain and high troponin I values admitted the hospital with the diagnosis of NSTEMI. Coronary angiography revealed 80-85% stenosis in the intermediary coronary artery(ICA), 90% proximally and 70% distally stenosis in the left anterior descending artery(LAD), 30% stenosis in the right coronary artery. We decided stent implantation for ICA and LAD lesions. We deployed 2,5mmx28mm drug eluting stent (DES) stent for ICA lesion, 2,25mm x32mm for distally and 2,5mmx32mm proxymally DES stent for LAD lesions. Then we decided there was a dissection like image in front of the proximal stent and attempted a bare metal stent (BMS) (EphesosII-AlviMedica) for this dissection. We used stent-viz to true position for stent deployment and we saw that dissection like image was in the proximal stent.Then we decided pull back the BMS and use a NC balloon for post-dilatation. When we pulled back BMS trapped in the proximal stent and stripped off from the balloon. We attempted to insert balloon over guidewire through to stent but guiding catheter and guidewire dislodged. We attempted to cross the guidewire near the undeployed stripped stent but we could not. And we saw a trombus over the stripped stent and the patient complained chest pain. We applied additional doses of unfractionated heparin and started Gp IIb/IIIa inhibitory infusion. Then we used a 0.014 hydrophilic guide wire and passed through the undeployed stripped stent. Finally we insert a 2,0mm x 15mm balloon and inflated 18 atm, then stent was deployed and succsesfully achieved TIMI 3 flow with no thrombus. Patient discharged fifth day with no chest pain and any complications.

Conclusions: Total stent and gudewire loss a serious complication during PTCA and we treated this complication rewiering the stripped stent and inflating a balloon over this guidewire.

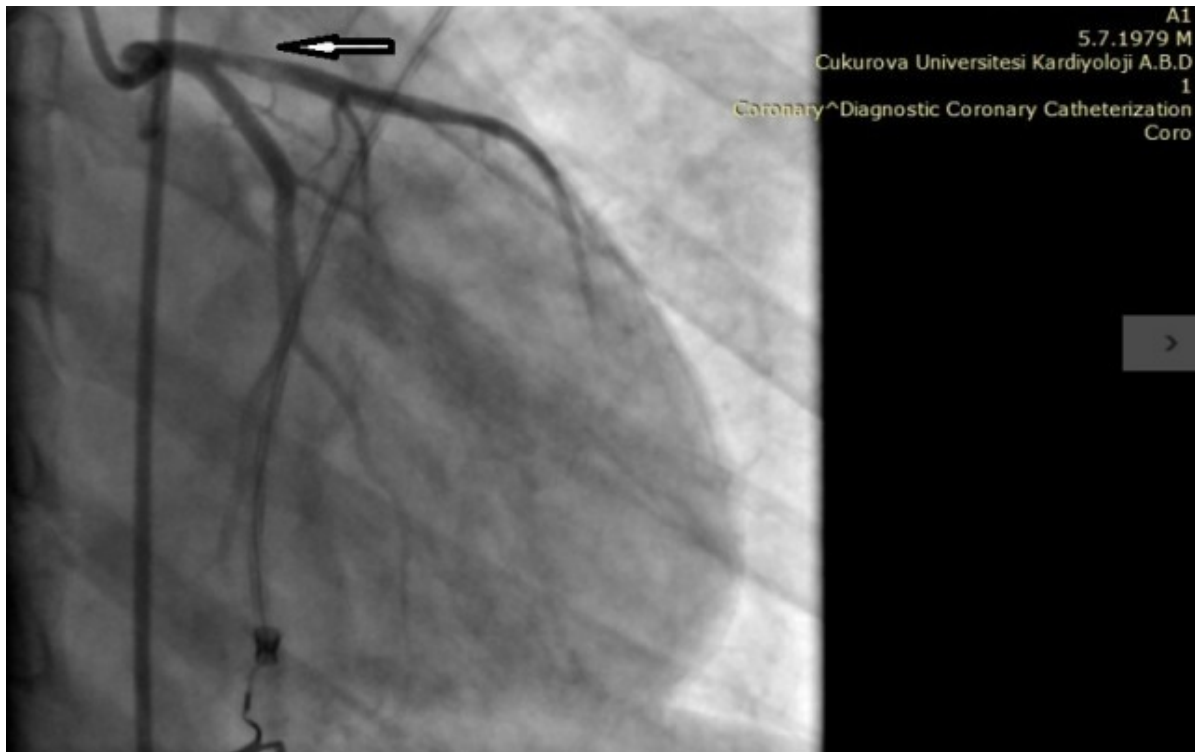ID: 317

Topic: Cardiology » Percutaneous Coronary Interventions in Acute Coronary SyndromesPresentation Type: **Poster****ACUTE ANTERIOR MYOCARDIAL INFARCTION IN THE 12TH WEEK OF PREGNANCY: A SUCCESSFUL STEPWISE TREATMENT**Rabia Eker Akilli, **Caglar Ozmen**, Omer Tepe, Caglar Emre Cagliyan*Cukurova University, Adana, Turkey***Corresponding Author (rabiaekerakilli@gmail.com)**rabiaekerakilli@gmail.com, caglarozm@hotmail.com, omer.tepe@windowslive.com, cemrec76@hotmail.com***Abstract Text****Objective:**

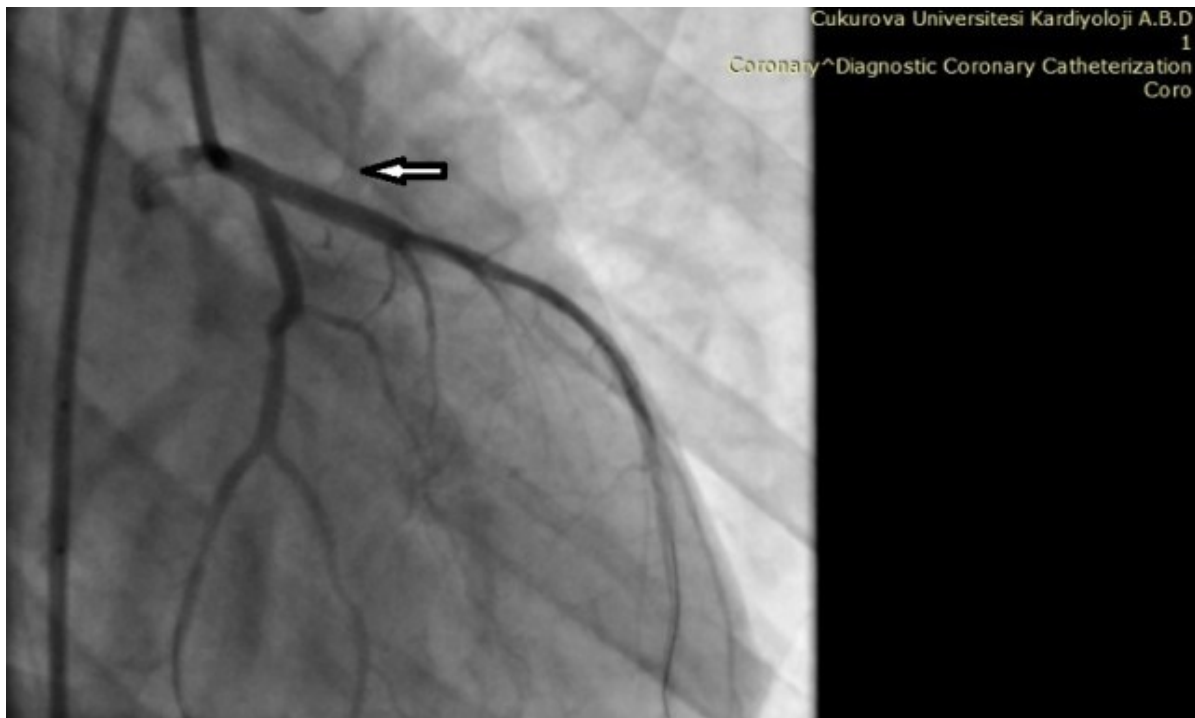
In pregnancy, the incidence of acute myocardial infarction ranges from 3 to 100 of every 100,000 deliveries. In cases of AMI during pregnancy, thrombus without atherosclerotic disease occurs at a rate of 21% . The risk of AMI increases during pregnancy due to hormonal and hemodynamic changes, including hypercoagulability and the increase in progesterone levels, which can lead to degeneration of the connective tissue in the intima and media layers of the coronary arteries.

Case:

A 36-year-old patient who had no history of systemic disease other than smoking was admitted to our clinic at 12th gestational week with cardiac arrest. Electrocardiography revealed ST segment elevation in the D1, aVL and V1-V6 leads. The patient was taken to the catheter laboratory and primary percutaneous coronary intervention was planned with femoral arterial approach at the second hour of cardiac arrest. The patient's abdomen was covered with lead shielding to protect the fetus from radiation. Coronary angiography showed a large thrombus obstructing the left anterior descending artery in the ostial segment while other coronary arteries were normal (Figure 1)



. After 18 hours from the intracoronary loading and iv maintenance tirofiban treatment, coronary angiography was planned (tirofiban bolus dose: 25 mcg/kg IC, infusion dose: 0.15 mcg/kg/min IV for up to 18 hr). During the procedure the patient's ST-segment elevation regressed and TIMI I-II flow was observed and angiography was terminated. The patient was taken to the cath. laboratory after 18 hours following tirofiban infusion. In control angiography, it was observed that the thrombus persisted in LAD ostium with TIMI II flow and 3.0x18 mm drug-eluting stent was implanted to the ostium of the LAD with success (Figure 2)



. 4 days later pregnancy was terminated due to procedure and treatment. She was asymptomatic in follow-up of 3 months. Family planning recommended because of the risk of subsequent pregnancies. As a conclusion, AMI has a high risk of maternal and fetal complications in pregnancy. Coronary angiography and concerns about ionized radiation exposure should not delay this potentially life-saving intervention. PCI is recommended in cases with continuing ischemia and infarction when a large myocardial area is at risk and the angiographic lesion is eligible. Most importantly, a multidisciplinary approach and monitoring in the critical care setting is essential for this special population.

ID: 539

Topic: Cardiology » Percutaneous Coronary Interventions in Acute Coronary SyndromesPresentation Type: **Poster****IATROGENIC AORTIC DISSECTION DURING PERCUTANEOUS CORONARY INTERVENTION****Mustafa Dağlı, Turgut Uygun***University of Health Sciences Konya Education and Research Hospital, Konya, Turkey***Corresponding Author (drmustafaaaa@gmail.com)**drmustafaaaa@gmail.com, drmustafaaaa@gmail.com***Abstract Text**

A 70 year-old male complaining of unrelieved chest pain for 2 hour was admitted to the Emergency Hospital.

After definitive diagnosis, a percutaneous coronary anjiyography was implemented, an acute coronary and in the abdominal aorta aortic dissection was found. Cardiologist immediately send to CT. It was seen in the arcus aorta suspicious dissection and aortic dissection including iliac arteries under diaphragm.

Cardiologist sent cardiovascular surgery to our hospital by urgently sending the patient. In the hospitalization, the patient's blood pressure was 190 mmhg. The pulse is lowered to 70 min. The patient was given intensive antihypertensive treatment.

In Our hospital, consulting with the cardiologist and decided to perform stenting of the right arm for acute coronary LAD proximal total occlusion. Two stents were placed in the LAD proximal lesion. Ticagrelor started.

CT was reviewed again. The abdominal aorta under the renal arteries was stenosis and this level was detected at reentry. This iatrogenic aortic dissection required emergent surgical intervention. Emergency endovascular supplies were provided. After challenging process maneuvers, the rupture site of the abdominal aorta was closed with endovascular covered stent and then the stent was placed in the right and left iliac arteries. Close monitoring of the lesion in the arcus aorta was decided.

Renal functions were closely monitored. Control CT was taken 5 days after the procedure. The patient was decided to be in close follow-up. The patient was discharged on the 6th day after the procedure.

Acute aortic dissection during cardiac catheterization is a very rare complication. (overall incidence, 0.02%) and occurs more frequently in the emergency setting of AMI (0.19%) than in an elective setting (0.01%). The incidence is generally higher during PCI (overall 0.03%) than during diagnostic procedures (<0.01% in elective settings).

This complication is extremely dangerous and is a life-threatening event; therefore, it is crucial to prevent a catheter-induced aortic dissection during PCI. In particular, the operator should be aware of the possibility of dissection during aggressive manipulation of guide catheters.

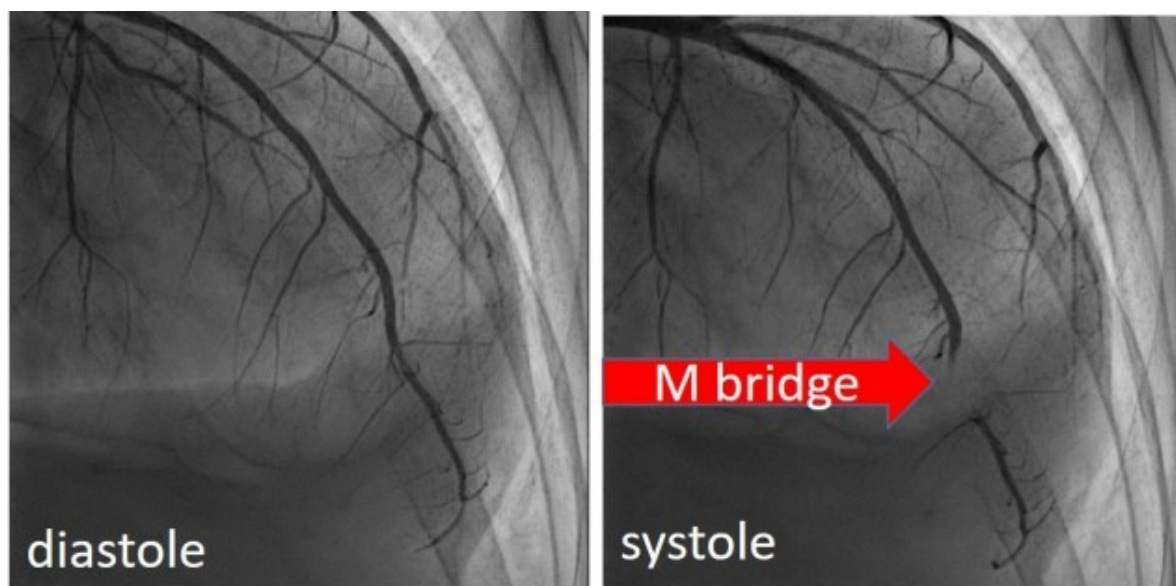
ID: 306

Topic: **Cardiology » Percutaneous Coronary Interventions**Presentation Type: **Poster****SEVERE MYOCARDIAL BRIDGING AS A CAUSE OF CHRONIC ISCHEMIA LEADING TO HEART FAILURE****Hakki Şimşek, Lezgin Dursun, Ali Evsen***Dicle University Heart Hospital, Diyarbakır, Turkey***Corresponding Author (dr.hsimsek@hotmail.com)**dr.hsimsek@hotmail.com, lezgingdursun893@hotmail.com, ali_evsen@hotmail.com***Abstract Text**

Muscle bridges (MBs) are structures consisting of heart muscle tissue which pass above the coronary arteries and their branches. Contraction of myocardial bridge fibres leads mainly to coronary insufficiency in young people.

CASE A 58-year-old male patient who had no history of previous cardiac disease admitted to our emergency department with complaint of shortness of breath. He was hospitalized in our coronary intensive care unit with the diagnosis of hypertensive pulmonary edema. The patient has history of chest pain which occurred especially in effort, lasted approximately 15-20 minutes. Physical examination revealed a diastolic murmur of 2/4 in the mesocardiac focus and bilateral crepitan rales without any finding in other systems. Arterial pressure 200/110 mmHg. Electrocardiogram: sinus rhythm 100 beats / min, QS pattern in V1-2 and T negativity in D1-AVL and left anterior hemibloc. Transthoracic echocardiography showed moderate aortic regurgitation and EF 38% had septoapical and apexed hypokinesia. Hs-trop was increased but CKMB was normal, another parameters are natural. On coronary angiography LMCA: Normal, CX: normal, RCA: normal, LAD: In the mid region, MBs was observed, which resulted in complete discontinuation of the current in the systole (Figure)

Although MBs are usually associated with a benign prognosis, being in many cases asymptomatic and only found by chance, their presence has also been considered a cause of angina, malignant arrhythmia, myocardial infarction, sudden death and also heart failure as in our case.



ID: 191

Topic: **Cardiology » Peripheral Arterial Diseases**Presentation Type: **Poster****POSTSPLENECTOMY PARADOXICAL EMBOLISM-CASE REPORT****Ahmet Seyda Yilmaz***Rize State Hospital, Rize, Turkey***Corresponding Author (ahmetseydayilmaz@gmail.com)**ahmetseydayilmaz@gmail.com***Abstract Text**

A case report

A 64-year-old woman admitted to the emergency service with accelerating pain, weakness, and swelling of left arm and shortness of breath. On physical examination, we noted that left arm was white and insensate below the shoulder associated with complete loss of brachial and radial arteries pulse. Urgent thorax computed tomography (CT) angiography demonstrated the acute cut off at the left subclavian artery and massive bilateral pulmonary embolism (PE). The coincidence of venous and arterial thromboembolism raised suspicion for paradoxical embolism (PDE). To evaluate further, echocardiography performed with agitated saline and slightly minimal transition from the right atrium to the left atrium through patent foramen ovale (PFO) was detected and also demonstrated enlarged right ventricle and atrium with increased pulmonary artery pulse. Eventually, diagnoses were acute left subclavian arterial occlusion and massive pulmonary embolism. The patient was taken to the operation room immediately and subclavian embolectomy was performed. . Due to this emboli was second and secondary to the venous system, warfarin therapy was planned for long-life.

One month ago without sequelae, cerebral infarct had been learned in the history of the patient. Brain diffusion MRI (magnetic resonance imaging), out of the center, one month ago showed the ischemic area of an antero-parietal region of the brain. After this ischemic stroke, she was under the treatment of clopidogrel 75 miligram (mg) per day. It was also noted that she had splenectomy due to the spleen enlargement 2 years ago. Serum trombotic level was in normal interval.

Because of multiple embolisms, we assessed hypercoagulative factors that would be related with prone to the thromboembolic occurrence. Factor 5 Leiden mutation, methylene tetra hydro folate reductase 677 and 1298 (MTHFR) mutations did not exist. Protein C and S activities, antithrombin 3 activity and each coagulation cascade factors (Factor 2-13) were at normal levels. Homocysteine level was 20,6 micromole per liter (reference interval: 0,0-12,0 micromole per liter) which means the patient has hyperhomocysteinemia

Discussion

Paradoxical embolism defines emboli of venous vasculature source transversing through an intracardiac or pulmonary shunt into systemic circulation. The defect of interatrial, interventricular or arterio-pulmonary layer provide tunnel clot to pass into arterial circulation originating venous system. PE was not foreground and found incidentally despite it was bilateral and massive. It is thought that PE usually would make flow reverse across a PFO from right atrium to left atrium via increased right side pressure^{1,2}. Our patient had acute pain and pulseless of the left arm. As reported previously 25 to 30 % patients experienced cryptogenic ischemic stroke have PFO³.

Recent studies did not showed a significant benefit of PFO closure for the secondary prevention of ischemic stroke against the medical therapy in recurrent events. Therefore antiplatelet drugs or systemic anticoagulants are recommended for this patient populations. In our patient we planned warfarin therapy for long-life⁷. Should we choose medical therapy or PFO closure in our patient? This answer needs further study.

As a result, hyperhomocysteinemia and splenectomy are hypercoagulative conditions. Patients candidate for splenectomy can be observed for hypercoagulable status and PFO with other risk factors.

ID: 433

Topic: **Cardiology » Cardiac Imaging - Cardiac MRI**

Presentation Type: **Poster**

**APICAL LEFT VENTRICULAR LIPOMA PRESENTING AS SYNCOPE:
EVALUATION BY MAGNETIC RESONANCE IMAGING**

Ersin Sarıcam

Medicana Ankara Hospital, Ankara, Turkey

**Corresponding Author (saricamersin@yahoo.com)*

saricamersin@yahoo.com

Abstract Text

Objective: Cardiac lipomas are benign tumors of the heart. They are usually asymptomatic. Symptoms depend upon the location within the heart. Syncope in the cardiac tumors has been noticed by 9.7%. We have reported a patient with left ventricular apical lipoma presented with syncope.

Methods: A 76 years old female patient was referred to our institution complaining of syncope. In physical examination, heart sound were normal, no cardiac murmur. The electrocardiography showed normal sinus rhythm. Transthoracic echocardiogram was performed. We saw a hyperechoic mass in echocardiography. After then, cardiac magnetic resonance imaging was performed and was seen compatible of lipoma. That mass was continuing mobile towards left ventricular outflow tract arising left ventricular apex in cardiac magnetic resonance imaging (video).

Results: Surgery therapy was performed and the mass was excised. The pathology examination demonstrated compatible with lipoma.

Conclusions: Cardiac lipomas are benign tumors of the heart, but they can be symptomatic according to the location within the heart. Diagnostic modality of choice is cardiac magnetic resonance imaging. The treatment of the symptomatic cardiac tumors are surgical resection.

ID: 316

Topic: Cardiology » Cardiac Imaging - Echocardiography

Presentation Type: Poster

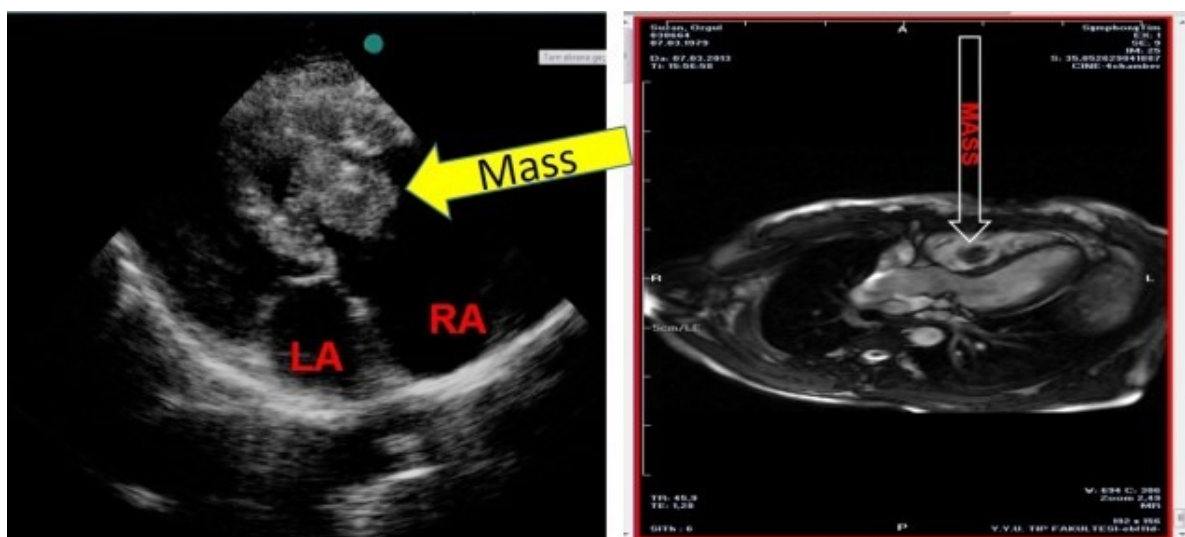Libman-Sacks Endocarditis leading to severe tricuspid valve stenosis**Hakkı Şimşek¹, Fatih Öztürk², Lezgin Dursun¹, Ali Evsen¹, Nizamettin Toprak¹**¹Dicle University Heart Hospital, Diyarbakır, Turkey²Yuzuncu Yıl University, Van, Turkey^{*}Corresponding Author (dr.hsimsek@hotmail.com)

dr.hsimsek@hotmail.com, fatihozturk2488@gmail.com, lezginDursun893@hotmail.com,
ali_evsen@hotmail.com, ntoprak@dicle.edu.tr

Abstract Text

Systemic lupus erythematosus (SLE) is an inflammatory disease with multiple organ involvement. Libman-Sacks (verrucous) endocarditis is the characteristic cardiac valvular manifestation.

A 23 year old female patient referred to our emergency clinic due to various symptoms such as fever, fatigue and shortness of breath that continued for 5 days. Physical examination displayed as following: body temperature: 38°C, blood pressure: 100/70 mmHg, heart peak pulse: 89 pulse/minute and rhythmic and malar rash. On cardiac examination diastolic murmur detected. Transthoracic Echocardiography (TTE) revealed severe tricuspid stenosis led by mass with a diameter of 19 x 27 mm end left ventricular Ejection Fraction 58%. All culture results remained negative. Because of malar rash she was consulted by a rheumatologist and SLE was diagnosed. We could not differentiate thrombus and vegetation with cardiac MR. The mass was considered to be thrombus and thrombolytic therapy was applied (tpa 100 mg/24 h). However control TTE and transesophageal echocardiography was not detect any change in the dimension of the mass. The patient was consulted by cardiovascular surgery and surgical treatment was decided. Histological findings of the tricuspid valve were consistent with Libman-Sacks endocarditis. The features are of bland vegetation consistent with Libman-Sacks endocarditis. After one month control TTE detected mild tricuspid insufficiency and no mass.



ID: 104

Topic: **Cardiology » Cardiac Imaging - Echocardiography**Presentation Type: **Poster****A CASE REPORT OF THE RECURRENCE OF A RARE CARDIAC LOW-
GRADE FIBROMYXOIDSARCOMA AND MORTALITY: AS
CARDIOVASCULAR CLINICIANS, WHAT STAGE ARE WE AT WITH
HEART CANCER?****Emre Özdemir, Mustafa Karaca***Izmir Atatürk Education and Research Hospital, Izmir, Turkey***Corresponding Author (emreozdemir27@yahoo.com.tr)**emreozdemir27@yahoo.com.tr, mustafakaraca99@hotmail.com***Abstract Text****Introduction:**

The incidence of primary cardiac tumors is 1/1000 at autopsy and 1.5/1000 on echocardiography but general population data are not well-known. It has been stated that 75% of cardiac tumors are benign and 25% are malignant forms. Metastatic tumors of the heart are 30 times more common than primary tumours. The case is here presented of a patient with a rare sarcoma of the heart, a myxofibrosarcoma, which resulted in mortality four months after the pathological diagnosis.

Case:

A 72-year old female presented at the cardiology polyclinic with dyspnea. A systolic murmur was detected in mitral focus on physical examination. TTE revealed a 4.5 x2.4 cm (Figure 1A) regularly-shaped tumoral mass on the left atrial side of the posterior mitral valve (Figure 1B). This tumoral mass caused a moderate mitral stenosis with a 1.4 cm² valve area (Figure 1C). Clinical diagnosis was myxoma and surgical excision was decided after heart team consultation. The tumoral mass was extracted together with the mitral valve because of valve invasion of the tumor. With the pre-diagnosis of hemangioendothelioma in the frozen section, the operation was successfully finished with mitral valve replacement. All operation material was sent to the pathology department. The tumor was seen to continue through the surgical margins on the paraffin sections. Immunohistochemical examination showed that the tumor cells were immunopositive for vimentin , focal positive for smooth muscleactin , CD34, CD31, and immunonegative for epithelial membrane antigen, CD68 , myogenic differentiation 1, desmin. The pathological diagnosis was made of low-grade fibromyxoid sarcoma (LGFMS), myxofibrosarcoma. CT was applied to the patient but no other tumor was observed. The patient was referred to oncology after this diagnosis. At 3 months postoperatively, the patient presented at the Emergency Department, again suffering from dyspnea. The patient was admitted to the intensive care unit and a diuretic infusion was started. TTE and TEE were performed and a giant mass with cystic areas was observed to fill the left atrium completely and was disrupting valve movements (Figure 2). After consultation with the cardiac team on the basis of the new findings, it was decided to re-operate when hemodynamic stabilization was obtained. On the 10th day of hospitalization, the patient was exitus due to hypotension despite inotrope infusion.

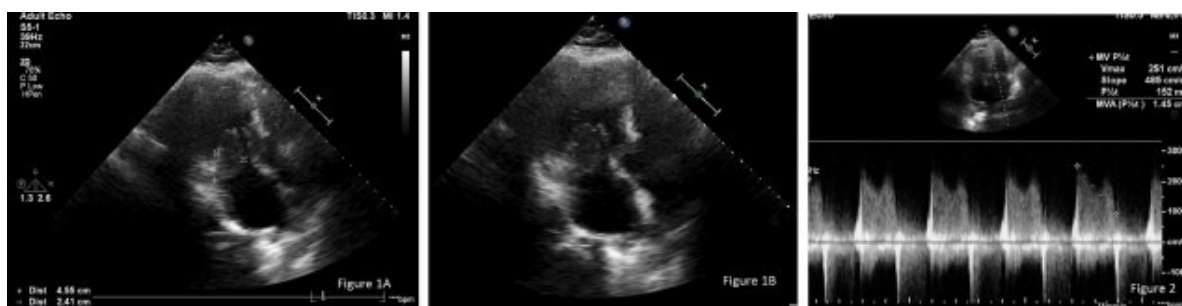

Figure 1; Dimensions is measured as 45 mm X 24mm (a); regularly-shaped tumoral mass is on the left atrial side of the posterior mitral valve (b); there is a moderate mitral stenosis with a 1.4 cm² valve area due to tumor (c)

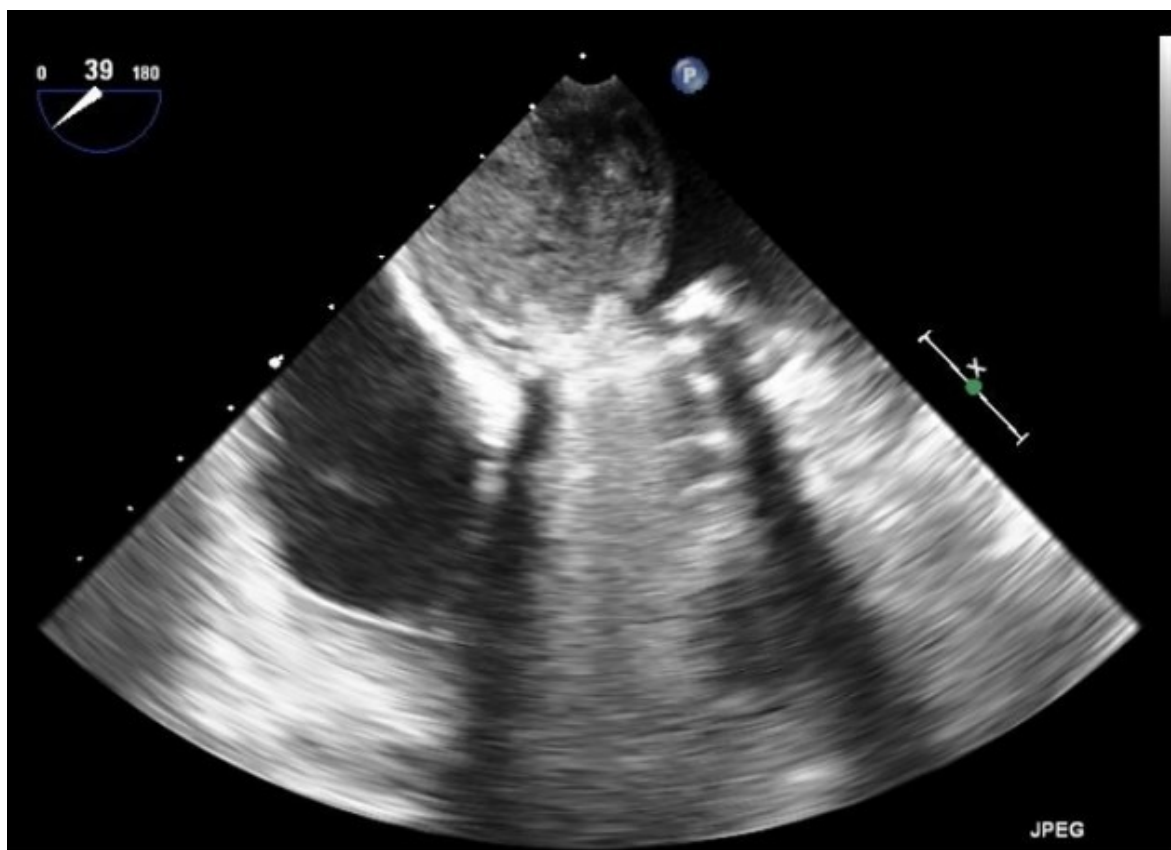


Figure 2 - There is a huge tumoral mass that totally filled the left atrium

Discussion:

Primary cardiac tumors are rare, with an incidence rate of 0.3%-0.7% of all recorded cardiac tumors. The most common sarcoma of the heart is angiosarcoma, and primary cardiac myxofibrosarcoma is much rarer. The main treatment is as much surgical resection of the tumor as possible, obtaining a negative surgical margin limit. Curative resection and adjuvant radiotherapy are recommended but the long-term efficacy is not well known.

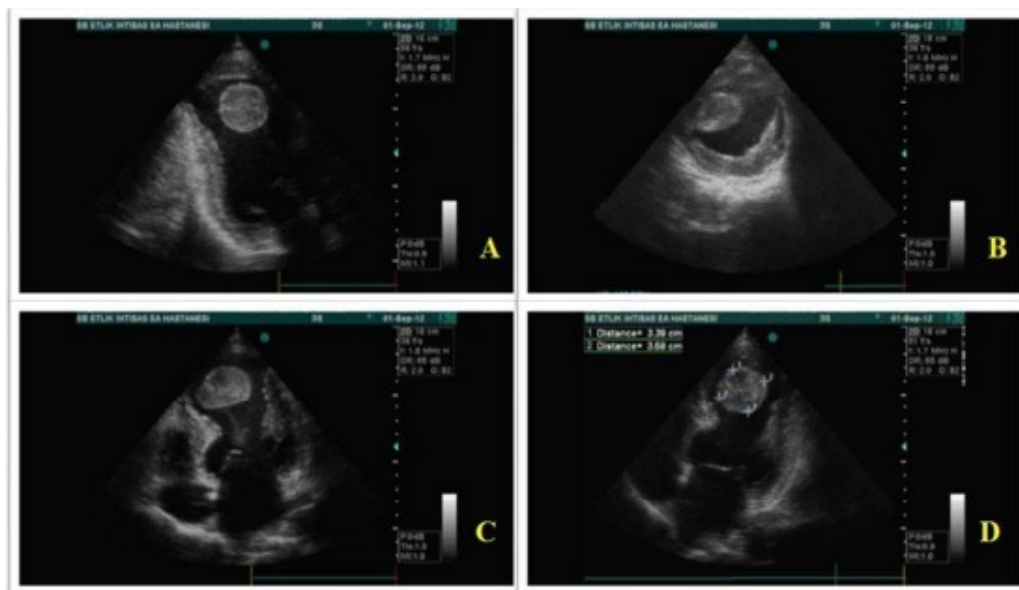
Conclusion:

Due to the rare frequency of cardiac malignant tumors, cardiologists and cardiovascular surgeons have little experience in the clinical evaluation of cardiac malignancies. The idea that a cardiac tumor is more frequently benign can cause malignant masses to be missed. With the perspective of an internal medicine specialist, the characteristics of each cardiac tumor must be evaluated with both clinical and imaging methods (MRI etc.) before cardiac surgery. Furthermore, perioperative frozen section evaluation by experienced pathologists can change the prognosis with a true diagnosis.

ID: 11

Topic: **Cardiology » Cardiac Imaging - Echocardiography**Presentation Type: **Poster****A HUGE MOBILE LEFT VENTRICULAR APICAL THROMBUS
PRESENTED WITH RECURRENT TRANSIENT ISCHEMIC ATTACKS IN A
PATIENT WITH PREVIOUS ANTERIOR MYOCARDIAL INFARCTION****Fatih Öksüz***Ankara Eğitim ve Araştırma Hastanesi, Ankara, Turkey***Corresponding Author (foksuz_42@hotmail.com)**foksuz_42@hotmail.com***Abstract Text**

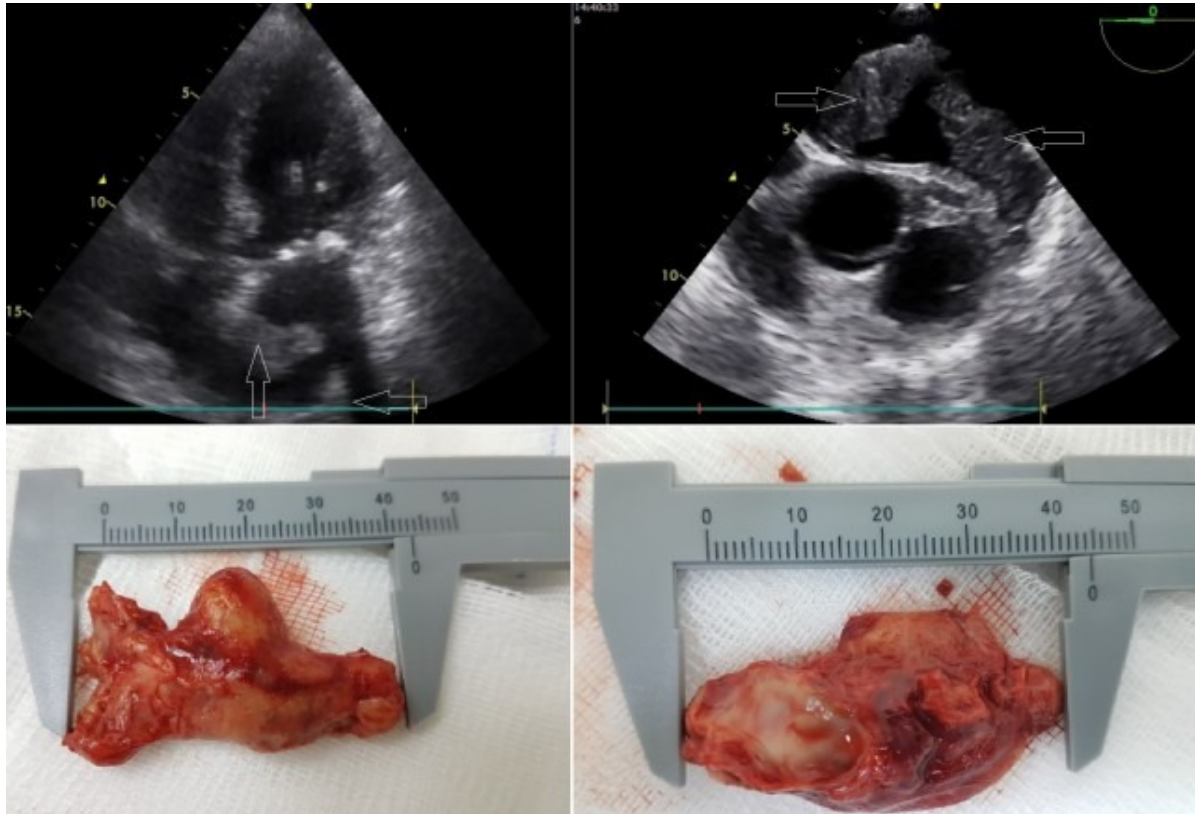
A 68-year-old man with a history of anterior myocardial infarction one year ago, was admitted to our emergency department because of transient weakness, clumsiness of the right upper extremity and motor aphasia. The onset of symptoms was approximately 30 minutes before the presentation into the emergency room. His symptoms had repeated three times during last three months. The ECG showed sinus rhythm, persisting ST-segment elevations associated with Q waves in the anterior precordial leads. The cerebral computerized tomography scan demonstrated chronic multiple embolic infarctions. Transthoracic echocardiography showed aneurysm in the apical portion of the left ventricle and a big, ball-like, protruding thrombus which was connected to the inferior wall in the left ventricular cavity. The view of protruding thrombus in the TTE apical two chamber view was shown in (Image A). The view of protruding thrombus in the TTE parasternal short axis view was shown in (Image B). The view of protruding thrombus in the TTE apical four chamber view was shown in (Image C). Mean size of thrombus was 3.4 cm x 3.7cm (Image D). Intravenous heparin was started to the patient immediately and because of the potentially high risk of distal embolization, an urgent surgery was performed including removal of thrombus and aneurysmectomy. Postoperatively, the patient gradually recovered without systemic embolism. Left ventricular thrombus is a common complication following myocardial infarction with or without left ventricular aneurysm or cardiomyopathy. The major concern for left ventricular thrombus is the potential for thromboembolism causing morbidity and mortality. It has been estimated that cardiogenic emboli are a source of transient ischemic attack (TIA) or stroke in 20% to 40% of all cases. The best technique to image left ventricular thrombus is transthoracic two-dimensional echocardiography. The sensitivity and specificity of this method are between 80 and 90%. A mobile ball-like thrombus is rare but carries a significantly higher risk of embolism. It has been reported that 27% of patients with all types of left ventricular thrombus had evidence of systemic embolization, and the incidence of embolization was significantly higher in patients with a mobile or protruding thrombus. The frequent inability to visualize the true left ventricular apex with transesophageal echocardiogram makes it a less appropriate test in this setting.



ID: 370

Topic: **Cardiology » Cardiac Imaging - Echocardiography**Presentation Type: **Poster****KISSING THROMBUS AT THE LEFT ATRIUM****Tuncay Güzel**, Bayram Arslan, Raif Kılıç, Mustafa Oylumlu, Hasan Kaya, Halit Acet, Faruk Ertaş*Dicle University, Diyarbakır, Turkey***Corresponding Author (drtuncayguzel@gmail.com)**drtuncayguzel@gmail.com, drbayramarslan@gmail.com, raifkcl@hotmail.com, dr.oylumlu@mynet.com, dr_hasankaya@yahoo.com, halitacet@gmail.com, farukertas@hotmail.com***Abstract Text**

A 66-year-old female patient had previously known heart failure and atrial fibrillation (AF). She was brought to the emergency department with complaints of dyspnea and confusion. Physical examination revealed a pansystolic murmur in apex in cardiac auscultation. Neurological examination revealed right hemiplegia. AF heart rate was 120 / minute in ECG. Cranial CT was consistent with ischemic SVO. The TTE showed a view consistent with the image of thrombus in the left atrium. The TEE showed an image consistent with the possible thrombus size of 47x30 and 49x28 mm. The patient was given a surgical decision at the cardiology council. In the pathologic examination performed after successful surgery, it was evaluated as a organized thrombus with myxoma appearance. As in this case, when a mass in the left atrium is detected, it should be kept in mind that thrombus may be present in patients with cerebrovascular symptoms.



ID: 159

Topic: Cardiology » Cardiac Imaging - Echocardiography

Presentation Type: Poster

THE GIANT TROMBUS IN THE LEFT VENTRICLE

Bayram Arslan, Barış Acun, Raif Kılıç, Mehmet Zihni Bilik, Tuncay Güzel, Faruk Ertaş, Halit Acet

Dicle University, Diyarbakır, Turkey

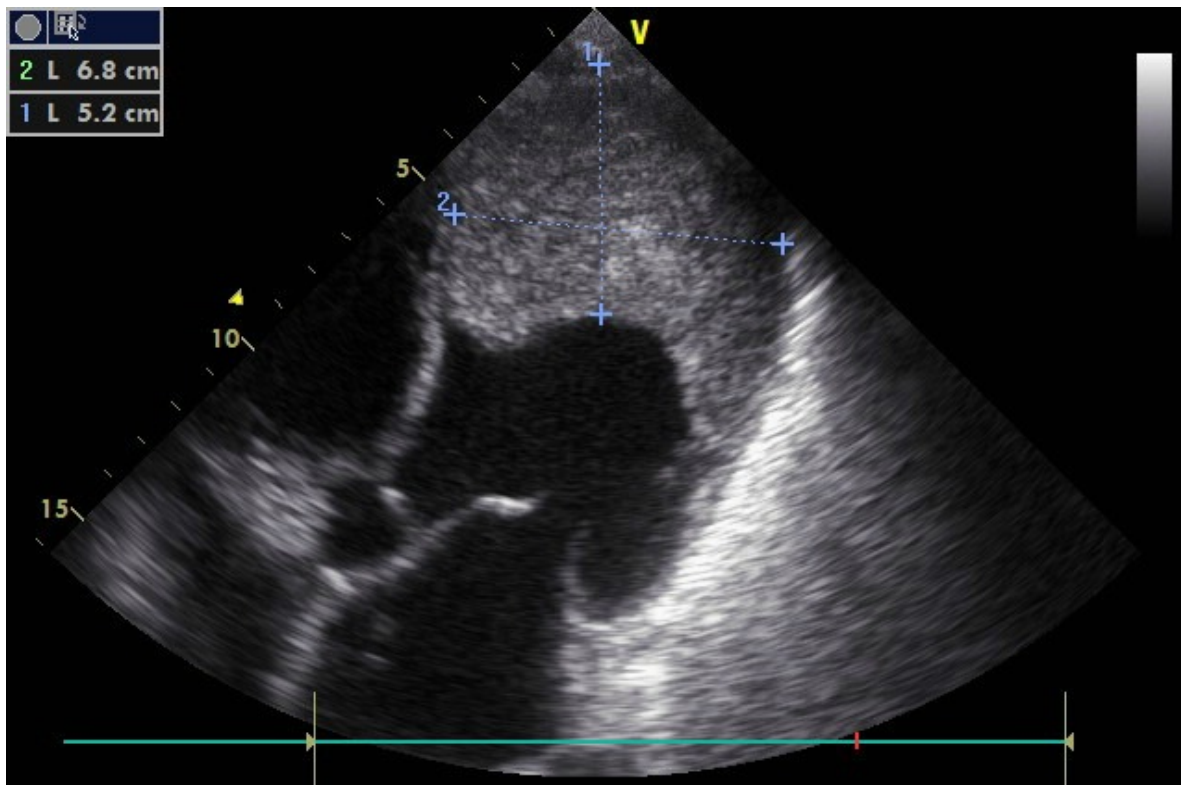
**Corresponding Author (drbayramarslan@gmail.com)*

drbayramarslan@gmail.com, acun.baris@hotmail.com, raifklc@hotmail.com, mzbilik@mynet.com, drtuncayguzel@gmail.com, farukertas@hotmail.com, halitacet@gmail.com

Abstract Text

A 24-year-old male patient with no known structural heart disease, presented to the emergency department with dyspnea and cough symptoms. The patient has a history of smoking and cannabis use for 10 years. On physical examination, respiratory sounds were decreased and rales were present in both lung basal zones. Heart sounds were tachycardic. There was no edema in both lower extremities. The drawn ekg; normal sinus rhythm, heart rate was 110 / minute, R wave loss in anterior leads and T wave negativity and ST segment depression in lateral leads were observed. In the echocardiographic examination; ejection fraction was 20%. All heart chambers were enlarged and left ventricular apex was observed as aneurysmatic. Inside the aneurysmatic segment, a 5.2x6.8 cm thrombus image observed which filling the big part of left ventricle. No significant pathology was found in the biochemical, hemogram and cardiac enzyme parameters. In this case; the

cardiomyopathy which is developed after cannabis use and the giant thrombus image in the left ventricular aneurysmal segment were demonstrative. We also considered that thrombus did not cause any embolic events in the patient is quite interesting.



ID: 174

Topic: Cardiology » Cardiac Imaging - Echocardiography

Presentation Type: Poster

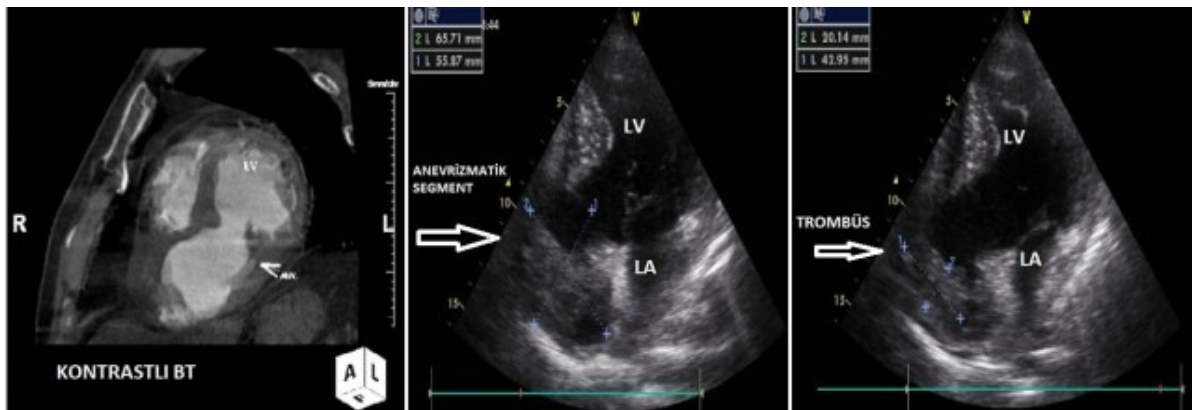
LARGEST ANEURYSM IN THE LEFT VENTRICLE

Tuncay Güzel, Bayram Arslan, Raif Kılıç, Hasan Kaya, Halit Acet, Faruk Ertaş

Dicle University, Diyarbakır, Turkey

*Corresponding Author (drtuncayguzel@gmail.com)

drtuncayguzel@gmail.com, drbayramarslan@gmail.com, raifkic@hotmail.com, dr_hasankaya@yahoo.com, halitacet@gmail.com, farukertas@hotmail.com

Abstract Text

A 70-year-old male patient with known lung cancer was admitted to the cardiology outpatient clinic with dyspnea and angina complaints during exercise. The patient had a smoking history of 60 packs / year. No additional pathology was found in physical examination and biochemical, hemogram and cardiac enzyme markers. The drawn ekg; normal sinus rhythm heart rate 80 / minute inferior leads were pathological q wave. In transthoracic echocardiographic examination; ejection fraction was 45%, aneurysm size 65x55 mm originating from the basal segment of the inferior wall and 42x20 mm thrombus in the aneurysm were observed. Left ventricular giant aneurysm was observed in contrast-enhanced thorax CT. Coronary angiography; Lad distal 80% stenosis, Cx widespread plaque, Cx OM2 70% stenosis, Rca 95% stenosis in the mid region, Rca is after acute margin branch total occluded. The patient was accepted as inoperable because of the 6-12 months survey of lung cancer. The patient was discharged after medical treatment was arranged.

ID: 21

Topic: **Cardiology » Cardiac Imaging - Echocardiography**Presentation Type: **Poster****CHOLECYSTATIC HEART****Ahmed Elgohari***Research Institute, Giza, Egypt***Corresponding Author (aabdelwahabelgohary@yahoo.com)**aabdelwahabelgohary@yahoo.com***Abstract Text**

Case Report:

A 31 year old, female patient with a history of cesarean section 2weeks ago. She was consulted to intensive care unit for sudden onset, severe lower abdominal pain with drowsiness. On examination, patient hemodynamic unstable, BP was 80/50,pulse was 120 b/m regular with episode of HR =35b/m , feverish , chest auscultation: was fine basal crepitation on one rib on back on both side, heart auscultation : was normal, abdominal palpation was tender, central venous pressure was elevated. ECG showed marked Sinus tachycardia. The patient underwent LAB investigations :show elevated WBCs(21,000), liver enzymes, bilirubin level especially indirect, elevated kidney function tests, marked elevated cardiac marker(ckmb , troponin) ,elevated ESR,CRP.

The echocardiography showed dilated left ventricle, impaired systolic function (EF:41%), global hypokinesia of all segment of LV and normal right ventricular functions.mild MR,normal others cardiac valves.no pericardial effussion,no intracardiac mass or vegetation.intact intracardiac septa. Partial oxygen and carbon dioxide pressures were normal at arterial blood gas, D-dimer level was at upper limit of normal values. Thorax x-ray was performed show mild cardiomegally. Abdominal U/A show: acute calcular cholecystitis ,small hematoma at site of cesarean section wound. Patient in ICU,continue on treatment as optimal antibiotic,positive inotropes(noradrenline),fluids,prophylatic anticoagulant.

At follow up, patient improved as kidney function tests, abdominal tenderness disappear, At third month follow up, control echocardiography revealed impressive recovery of left ventricle function mainly (EF:52%,with mild reduction in LV dimensions).

Discussion:

We know that inflammatory pathologies of neighboring organs of heart can eventuate with ECG changes which are evidence of inflammatory expansion to the heart. wall motion abnormality here in some cases with upper abdominal pain and dilated ,impaired systolic function LV are due to acute cholecystitis. In this case, we think that inflammatory expansion was great enough to cause a myocarditis scenario. We excluded the most possible diagnosis (per partum cardiomyopathy , acute coronary syndrome) with history,clinical and diagnostic tests and finally we diagnosed the patient with acute left ventricle myocarditis due to acute cholecystitis.

ID: 221

Topic: Cardiology » Cardiac Imaging - Cardiac CT

Presentation Type: Poster

MULTIMODALITY IMAGING OF HUGE CORONARY CAMERAL FISTULA

Bayram Arslan, **Tuncay Güzel**, Raif Kılıç, Faruk Ertaş, Halit Acet, Hasan Kaya, Mustafa Oylumlu

Dicle University, Diyarbakır, Turkey

**Corresponding Author (drbayramarslan@gmail.com)*

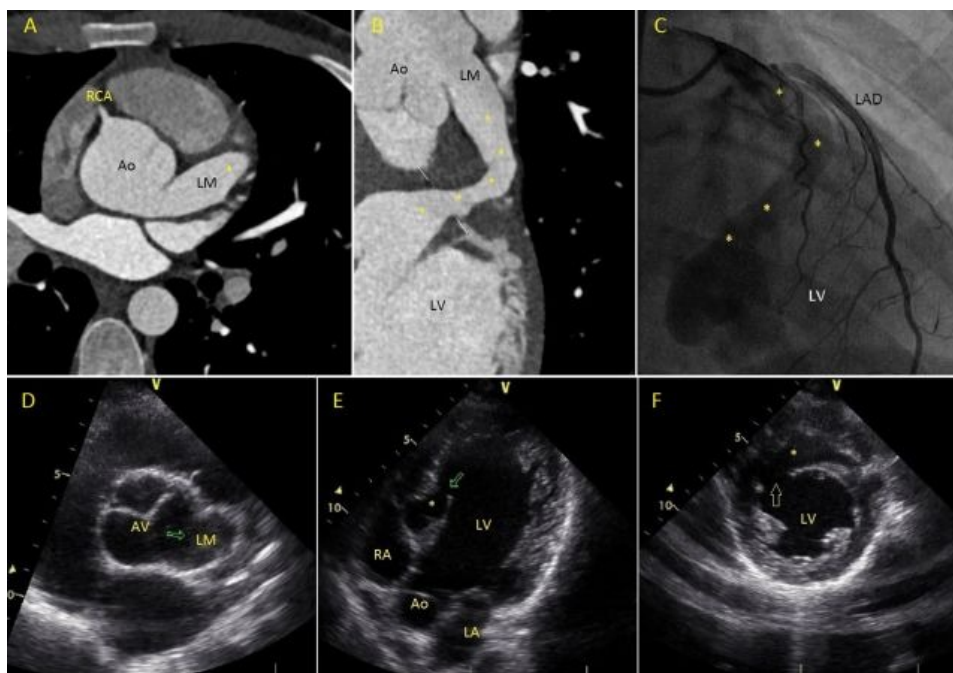
drbayramarslan@gmail.com, drtuncayguzel@gmail.com, raifkic@hotmail.com, farukertas@hotmail.com, halitacet@gmail.com, dr_hasankaya@yahoo.com, dr.oylumlu@yahoo.com

Abstract Text

A 23-year-old man was hospitalized with the complaint of exertion dyspnea. Physical examination revealed a third degree diastolic murmur best heard at the mesocardiac area. Electrocardiogram showed normal sinus rhythm. Transthoracic echocardiography revealed aneurysmatic dilatation of left main coronary artery (CA) in addition to the large coronary cameral fistula between left CA and left ventricle. The fistulae travels in the interventricular septum and drains into the left ventricular cavity (Panel D, E, F; Video 1) Coronary computed tomography and coronary angiography confirmed the huge fistula between left CA and ventricle (Panel A, B, C; Video 2). The maximum diameter of fistulae was 18 mm.

CA fistulas are reported in 0,1 - 0,2% of all patients undergoing selective coronary angiography. The major sites of origin of fistula are right coronary artery (55%), left coronary artery(35%), and both coronary arteries. The major sites of terminations are right ventricle (40%), right atrium(26%), pulmonary artery (17%), less frequently SVC, CS and least in left atrium and left ventricle (2%). Herein, we have reported a huge coronary cameral fistula that connects the left main CA to the left ventricle.

NOTE: This case was previously published in the Anatolian journal of cardiology.



ID: 184

Topic: **Cardiology » Diabetes Mellitus and Cardiovascular Disease**Presentation Type: **Poster****PERIPHERAL ARTERIAL DISEASE OF THE LOWER LIMBS IN ASYMPTOMATIC DIABETIC PATIENTS: PREVALENCE AND DETERMINING FACTORS****Maryam Mouadili***Centre Hospitalier Universitaire Mohammed VI Marrakech, Marrakech, Morocco***Corresponding Author (maryam.mouadili@gmail.com)**maryam.mouadili@gmail.com***Abstract Text**

Summary:

Background: peripheral arterial disease (PAD) of the lower limbs is an important predictor of cardiovascular disease; however it's still underdiagnosed over asymptomatic diabetic patients, free of cardiovascular disease.

Purpose: determining the prevalence and risk factors for PAD in an asymptomatic population of diabetic patients at low or intermediate risk factors of cardiovascular disease, with a free history of cardiovascular disease.

Methodology: this was a prospective study conducted over 14 months period from November 2017 to January 2018. A total of 309 diabetic patients were included from two diabetes centers. PAD was defined as an ankle-brachial index (ABI) less than 0,9.

Results: among the 309 patients, the ankle-brachial index (ABI) was < 0.9 in 98 (31,71%) patients considered to have PAD. The ABI was > 1.3 in 36 (11,35%) patients who had suspected medialcalcosis.

The average age of the PAD population was 56.2 years. Female gender predominated (57%). The mean duration of diabetes was 11yeras: 80% type II Diabetes.

PAD of the lower limbs was mild in 26 patients (26,53%) moderate in 49 (50%) and severe in 23 (23,46%)

Duplex Doppler commonly showed lesions of the femoral and tibial arteries.

Factors associated with PAD were advanced age (p <0.0001), age of diabetes > 6 years (p <0.0001), uncontrolled diabetes as assessed by HbA1c levels > 7% (p <0, 0001) and elevated fasting glucose levels (p = 0.039), Hypertension (p <0.0001) and dyslipidemia (p <0.0001).

For medialcalcosis, male gender was the only factor identified.

Conclusion: Primary prevention outpatient screening of asymptomatic diabetic patients with lower or intermediate cardiovascular risk can identify numerous patients with PAD. Advanced age, a mean duration of diabetes over 6years, uncontrolled diabetes, hypertension, and dyslipidemia were predictive factors for diabetic PAD of the lower limbs in our population.

ID: 27

Topic: Cardiology » Treatment of Hyperlipidemia

Presentation Type: Poster

EPICARDIAL FAT THICKNESS IS SIGNIFICANTLY INCREASED AND RELATED TO LDL CHOLESTEROL LEVEL IN PATIENTS WITH FAMILIAL HYPERCHOLESTEROLEMIA**Yurdaer Dönmez, Atilla Bulut***Sağlık Bilimleri University Adana City Research and Training Hospital, Adana, Turkey***Corresponding Author (yurdaerd@gmail.com)**yurdaerd@gmail.com, atilabulut@gmail.com***Abstract Text**

Background: Increased epicardial fat thickness (EFT) is accepted as a risk factor for cardiovascular diseases in some studies. There are conflicting results about the relation between plasma low density lipoprotein cholesterol (LDL-C) level and EFT. Also, the relation between EFT and familial hypercholesterolemia (FH) or non-FH is not clearly documented in the literature. Our aim was to investigate EFT in FH patients and to determine that which parameters were related to EFT increase.

Methods: A total of 225 subjects enrolled to our study. Subjects were separated as three groups: 75 non-FH (16 men, mean age 52.8±7.4 years), 75 FH (26 men, mean age 50.7±9.2 years), and 75 control subjects (25 men, mean age 52.9±9.4 years). Medical history assessment and complete physical examination was done. Routine laboratory tests and echocardiographic measurements were performed.

Results: Coronary artery disease frequency was significantly higher in the FH group compared to other groups ($p<0.001$). Alanine aminotransferase, total cholesterol, LDL-C, and triglyceride levels were significantly different between three groups ($p<0.05$ each-one). Control group had the lowest and FH group had the highest alanine aminotransferase, total cholesterol, LDL-C, and triglyceride levels ($p<0.05$ each-one). EFT values were highest in the FH group and it was significantly different than other two groups ($p<0.001$). LDL-C was found independently related to EFT in the linear regression analysis.

Conclusion: Epicardial fat thickness is increased in the FH patients. Also, LDL-C level is significantly correlated with increased EFT.

ID: 183

Topic: Cardiology » Treatment of Obesity and Diet in Cardiovascular Disease

Presentation Type: Poster

**LEFT VENTRICULAR DIASTOLIC DYSFUNCTION IN NORMOTENSIVE
NON DIABETIC PATIENTS WITH ABDOMINAL OBESITY.**

Maryam Mouadili, Cyriaque Mbauchy

Centre Hospitalier Universitaire Mohammed VI Marrakech, Marrakech, Morocco

**Corresponding Author (maryam.mouadili@gmail.com)*

maryam.mouadili@gmail.com, cyrmbauchy@hotmail.com

Abstract Text

Abstract

Background

Abdominal obesity is an independent risk factor for cardiovascular disease. The effect of abdominal obesity on myocardial function in young obese patients remains unknown.

Methods

To assess the influence of obesity on left ventricular function, 50 obese asymptomatic patients (mean body mass index (BMI) 35.8 ± 4.2 kg/m² and mean age 39.2 ± 2.4 years) without evidence of heart disease were evaluated by echocardiography.

Results:

Results showed that diastolic dysfunction was present in 21 (42%) of patients. Diastolic dysfunction was more common among female sex (68.18%) compared to male (50.17%). The mean left ventricular mass index was (103 ± 22 g/m²),

In conclusion, Diastolic dysfunction might be an early indicator of cardiac involvement in obesity.

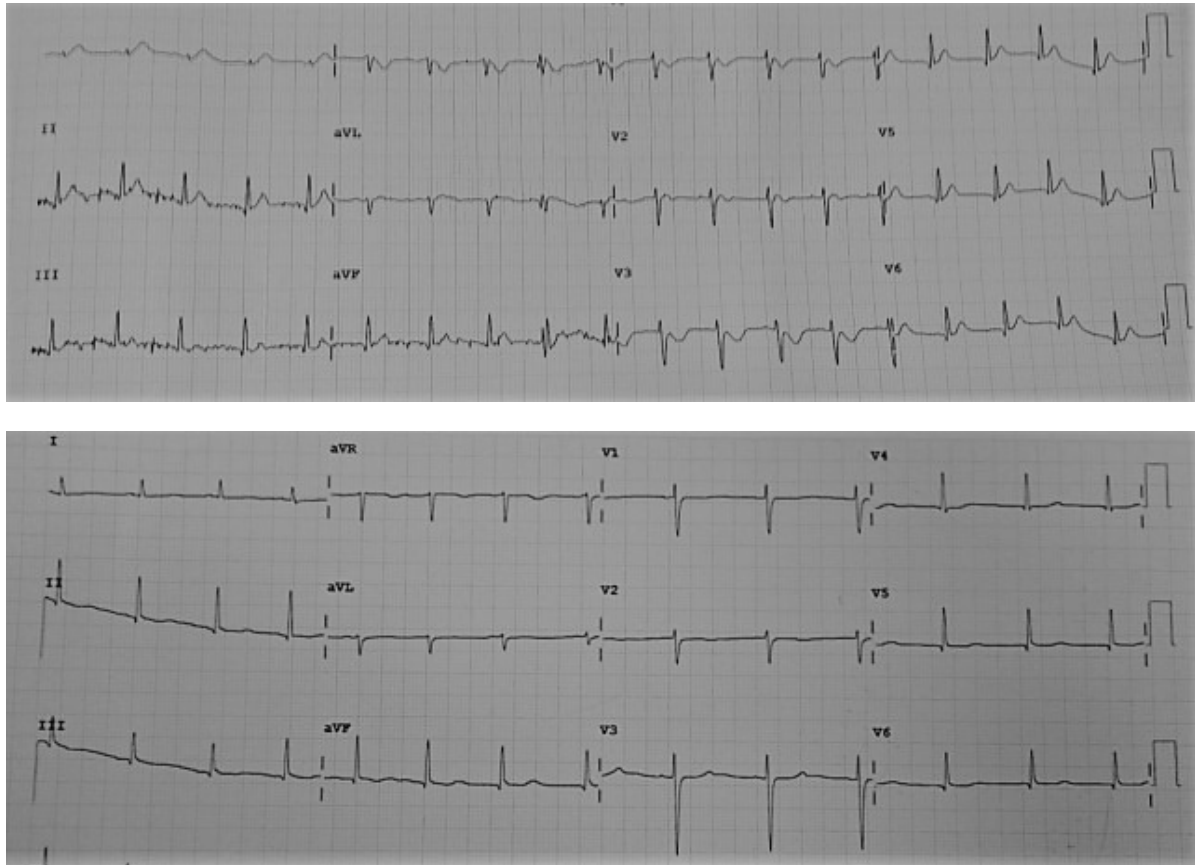
ID: 485

Topic: **Cardiology » Acute Heart Failure**Presentation Type: **Poster****REVERSIBLE LEFT VENTRICULAR SYSTOLIC DYSFUNCTION DUE TO 5-FLUOROURACIL-INDUCED CARDIOTOXICITY****Umut Kocabaş**, Nadire Küçüköztaş, Öykü Gülmez*Başkent University School of Medicine, İstanbul, Turkey***Corresponding Author (umutkocabas@hotmail.com)**umutkocabas@hotmail.com, nadire.kucukoztas@baskent.edu.tr, gulmezoyku@yahoo.com***Abstract Text**

Introduction: 5-fluoro-uracil (5-FU) and its pro-drug, oral form capecitabine which is converted to 5-FU inside tumour cell are widely used chemotherapeutics to treat gastrointestinal and breast cancers. Both 5-FU and capecitabine can induce several cardiac adverse effects such as acute coronary syndromes, heart failure and left ventricular systolic dysfunction, hypertension, arrhythmias and sudden cardiac death. We present a case of a patient with rectal adenocarcinoma and reversible left ventricular systolic dysfunction due to 5-FU cardiotoxicity.

Case: A 32-year-old woman who was operated due to rectal adenocarcinoma (T3 N2 M0) and receiving 5-FU adjuvant chemotherapy developed chest pain and shortness of breath approximately 36 hours after the beginning of first episode of 5-FU intravenous infusion therapy (total applicated dose 3500 mg). Her past medical history was unremarkable for cardiovascular diseases. Electrocardiography (ECG) showed sinus tachycardia and a heart rate of 115 bpm with T-wave inversion in leads V1-3 (**Figure 1**). Laboratory results revealed increased high-sensitive cardiac troponin-I (cTnI) (baseline cTnI: 15 pg/ml and after chemotherapy cTnI: 56 pg/ml, reference range: 0 – 15.6 pg/ml) and N-terminal pro-B-type natriuretic peptide (NT-proBNP) (NT-proBNP: 1832 pg/ml, reference range: 0 – 100 pg/ml) levels after chemotherapy. Transthoracic echocardiography (TTE) showed global left ventricular hypokinesis with an ejection fraction (EF) of 30% which was determined by the Simpson's method (**Movie 1**). After diagnostic work-up, the 5-FU therapy discontinued and the patient admitted to intensive coronary care unit (ICCU). Her chest pain and shortness of breath resolved after treatment with nitroglycerin, nifedipine, metoprolol, acetylsalicylic acid (ASA) and low-molecular-weight heparin. During ICCU follow-up, both cardiac troponin-I levels and ECG were normalised and ECG showed normal sinus rhythm without ischemic changes (**Figure 2**). Patient discharged with ASA, nifedipine, metoprolol and oral nitroglycerin therapy. TTE revealed progressive improvement and normalisation in the left ventricular systolic function with an EF of 45% at the 7th day control and %58 at the 21st day control (**Movie 2-3**). After normalisation of EF and left ventricular systolic function, capecitabine adjuvant chemotherapy was initiated instead of 5-FU therapy with the decision of cardio-oncology council. Left ventricular systolic function, EF values and cTnI levels were normal throughout capecitabine chemotherapy follow-up.

Conclusion: In our patient, mild cTnI elevation and left ventricular systolic dysfunction occurred after 36 hours of 5-FU intravenous infusion therapy. We did not consider type 1 or type 2 myocardial infarction due to absence of rise and/or fall of cTnI values. In the foreground, we thought of myocardial injury secondary to cardiotoxicity. Left ventricular systolic functions were normalized after discontinuation of 5-FU chemotherapy. Capecitabine treatment instead of 5-FU chemotherapy was completed with close cardiac follow-up and without any complication. Although current guidelines do not recommend capecitabine therapy in patients with cardiotoxicity and left ventricular systolic dysfunction due to 5-FU chemotherapy, we speculate that capecitabine treatment may be given with close cardiac follow-up in selected patients.



ID: 416

Topic: **Cardiology » Acute Heart Failure**

Presentation Type: **Poster**

A PULMONER EMBOLISM CASE ACTING AS AN ACUTE HEART FAILURE

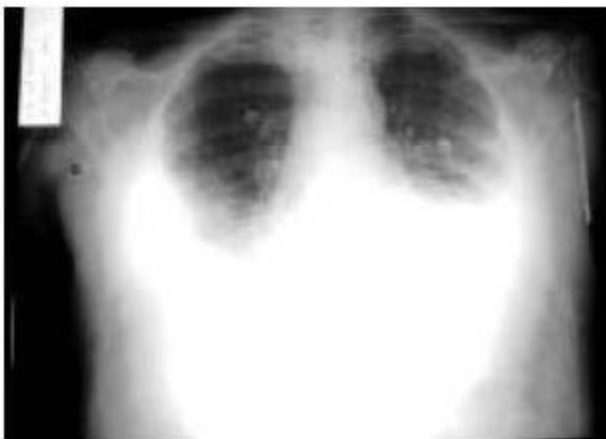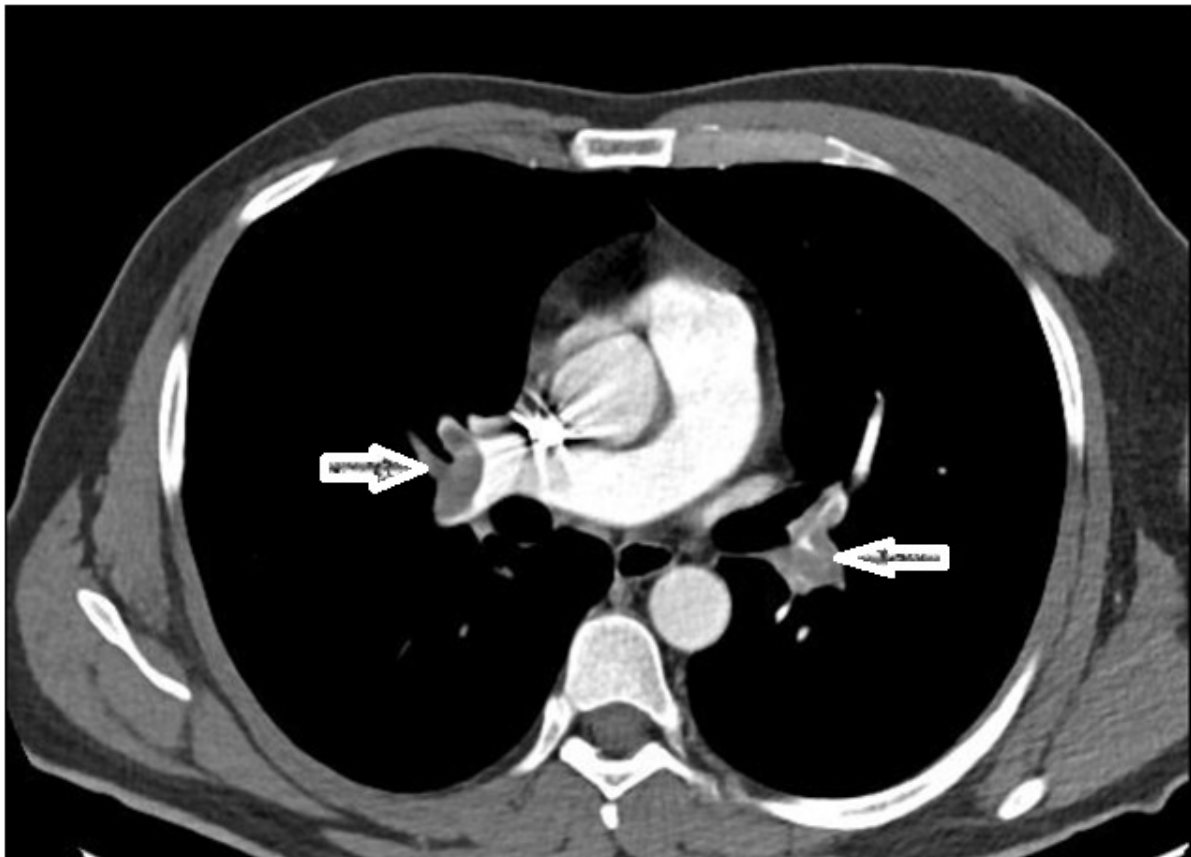
Fulya Avcı Demir¹, Konstantinos C. Theodoropoulos²

¹*Elmalı State Hospital, Antalya, Turkey*

²*King's College Hospital, London, United Kingdom*

**Corresponding Author (fulyaavcidemir@gmail.com)*

fulyaavcidemir@gmail.com, konstantinos.theodoropoulos@nhs.net

Abstract Text

Introduction: Symptoms of pulmonary embolism are non-specific and may mimic other common cardiopulmonary conditions. **Case:** Herein, we present a case of dyspnea secondary to PE, which was initially misdiagnosed as congestive heart failure based on her chest X-ray findings and the presence of bilateral transudative pleural effusion. A 68-year-old woman was admitted to our emergency department with increased dyspnea for 10 hours. She had palpitation and cough without any sputum. She was on anti-diabetic and anti-hypertensive therapy. Her medical history revealed no known coronary artery disease. On her physical examination, blood pressure was 100/60 mmHg, pulse rate was 116 bpm, body temperature was 36.6° C, respiratory rate was 22 bpm, and peripheral oxygen saturation (SpO₂) was 85%. Breath sounds were reduced at the basal segments on auscultation, and cardiac examination revealed tachyarrhythmia. A 12-lead electrocardiography (ECG) showed atrial fibrillation. Chest X-ray revealed an increased cardiothoracic ratio with bilateral pleural effusion (Figure 1). Arterial blood gas analysis showed a pH value of 7.37, partial pressure of carbon dioxide (PaCO₂) of 25.4 mmHg, partial pressure of oxygen (PaO₂) of 57.2 mmHg, bicarbonate (HCO₃) of 18.2 mEq/L, and arterial oxygen saturation (SaO₂) of 84%. Initially, she was consulted with the pulmonologist. The pulmonologist suggested thoracentesis for further fluid sample analysis. 1800-cc transudative fluid was evacuated. Laboratory findings were as follows: leukocyte count: 12,100/mm³ and C-reactive protein (CRP): 60.7 mg/L. Renal and hepatic functions were normal. However, troponin level increased (0.8 ng/mL). Based on the presence of dyspnea and bilateral transudative pleural effusion, the preliminary diagnosis was congestive heart failure. The patient was, then, consulted to the cardiologist. Transthoracic echocardiography (TTE) demonstrated an improved left ventricular systolic function with a dilated right ventricle (RV). There was mild tricuspid regurgitation with a calculated RV systolic pressure of 50 mmHg. There was no segmental motion defect. A new sample of blood was sent to the laboratory for D-dimer, which was found to be elevated. Therefore, thoracic computed tomographic angiography was

performed and it demonstrated extensive PE of both right and left main pulmonary arteries, extending distally into the lobar, segmental, and sub-segmental branches (Figure 2).The patient was hospitalized by the pulmonologist and treated with low-molecular weight heparin (LMWH) combined with overlap warfarin.Although Chest X-ray findings are usually non-specific in PE, it is helpful to exclude useful for excluding other causes of dyspnoea or chest pain.Conclusion:Pleural effusion occurs %20 to 50% of patients with PE.Pleural effusions associated with PE are usually small, unilateral, and exudative when analyzed.This report is a rare presentation of PE.Clinicians should be kept in mind that PE may present with distinct atypical clinical signs and symptoms.

ID: 181

Topic: **Cardiology » Diagnosis and Treatment of Valvular Hearth Disease**

Presentation Type: **Poster**

THE ASSOCIATION OF INFECTIVE ENDOCARDITIS AND LEGIONELLA PNEUMONIA IN A PATIENT

Nazmi Gultekin

Istanbul University Cardiology Institute, Istanbul, Turkey

**Corresponding Author (nngultekin@yahoo.com)*

nngultekin@yahoo.com

Abstract Text

The Association of Infective Endocarditis and Legionella Pneumonia in a Patient

The patient was followed in our institute for 3 years with the diagnosis of hypertension, diabetes mellitus and ascending aorta dilatation. In April 2018, coronary angiography was performed at the external center. After 10 days the patient was admitted to our institute with high fever, excessive sweating, orthopnea, edema, ascites, weakness, hepatomegaly, venous fullness, and crepitant rales up to the middle zones in both hemithorax. In TTE and TEE examination, it was observed that the vegetation was 2.5x2 cm in the amorphous structure, but not clear in diameter. Vegetation caused 3rd degree mitral regurgitation in the valve. (Figure 1). The patient was treated with vancomycin.seftriaxone, gentamycin as antibiotic therapy and routine heart failure therapy. On 10 May 2018, mitral valve replacement + tricuspid annuloplasty + aortic valvuloplasty was performed on the mitral valve due to fever and refractory heart failure. On the postoperative 12th day, the patient who had shortness of breath was revised and the hematoma was evacuated. After 10 days, pleural effusions were drained with pleurocan The patient's complaints persisted and fixation of persistent opacity was detected on the chest X-ray and thorax CT was performed on the PA chest X-ray appearance(Figure 2). Decortication was performed on 10.08.2018 with Video-Assisted Thoracoscopic Surgery (VATS) operation on left pleural thickening. The patient's complaints persisted . The patient's symptoms were thought to be related to amlodipin in the form of anasarca edema and weight gain and this drug has been removed from therapy. The patient rapidly recovered and was sent home with routine treatment. The patient, who was in good condition until 25.10.2005, applied to the department of infectious diseases with severe dyspnea, fever, cough and side pain. Legionella pneumonia was also found in the examinations and investigations(Figure 3). Levofloxacin + Tazocin was administered and partial improvement was observed. He was sent home with oral antibiotherapy (Surpax 400). Currently, the patient is in good condition alive

ID: 352

Topic: **Cardiology » Hypertrophic Cardiomyopathy**

Presentation Type: **Poster**

ASYMPTOMATIC BIVENTRICULAR HYPERTROPHIC CARDIOMYOPATHY

Hakkı Şimşek, Ali Evsen, Lezgin Dursun, Barış Acun, Nizamettin Toprak

Dicle University Heart Hospital, Diyarbakır, Turkey

**Corresponding Author (dr.hsimsek@hotmail.com)*

*dr.hsimsek@hotmail.com, ali_evsen@hotmail.com, lezgingdursun893@hotmail.com, acun.baris@hotmail.com,
ntoprak@dicle.edu.tr*

Abstract Text

A 23-year-old male patient who was asymptomatic admitted to hospital. He directed on cardiology outpatient clinic detection that diffuse ST depression and hypertrophy findings on shooting ECG.

He had no history of previous cardiac disease or hereditary disease.

Physical examination: S1, S2 (+), mild systolic murmur.

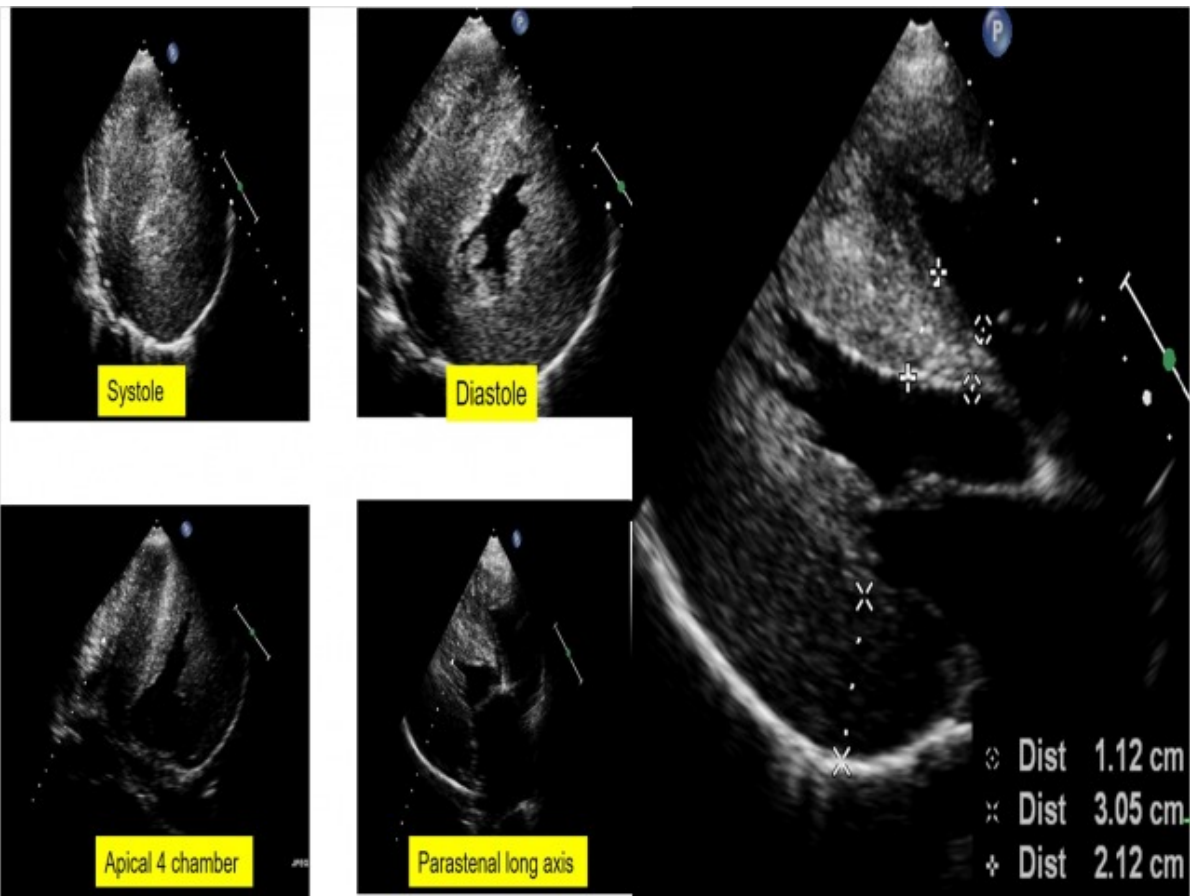
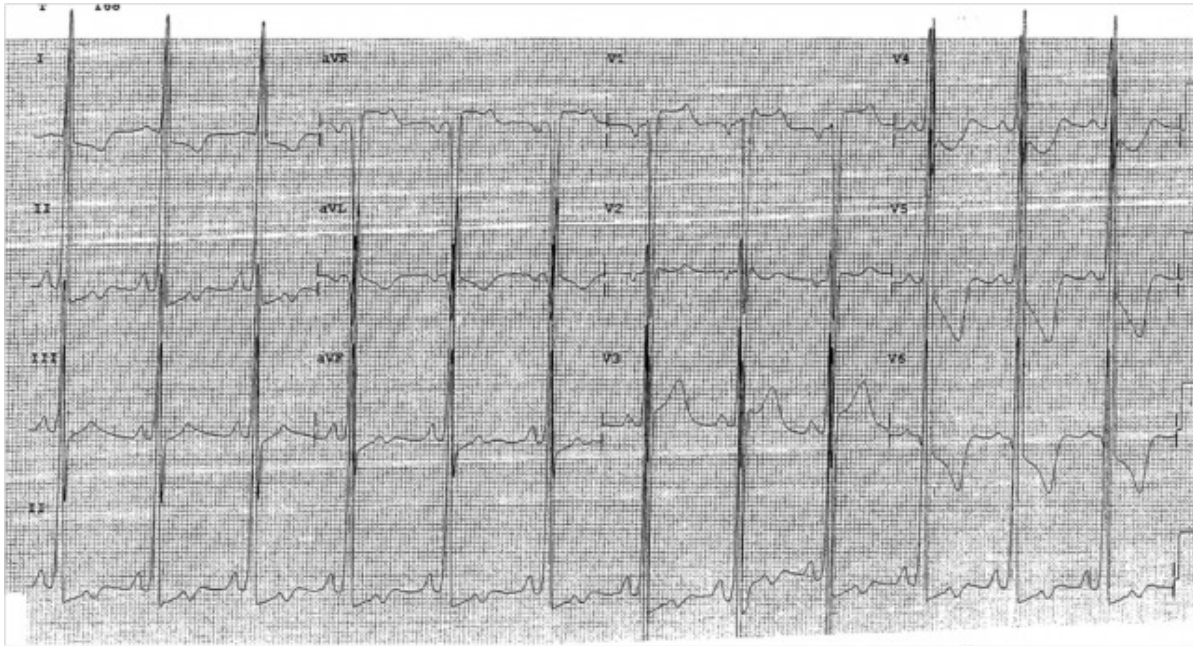
We monitorized in the exercise test that modified Bruce 15.3 METs, 65% of the target heart rate is reached

(chronotropic insufficiency) and no arrhythmia.

We monitorized in the 24-hour rhythm holter: sinus rhythm, heart rate 56-122 beat/minute on average 72 beat/minute, no ventricular extra systol and 55 single atrial extra systol one coupled atrial extra systol.

We monitorized on ECO: except left ventricular outflow tract diffuse hypertrophy, dilatation of left atrium and on systol obliteration of midcavity.

In conclusion, biventricular hypertrophic cardiomyopathy can be asymptomatic until adult age and only represent with ECG abnormalities.



ID: 502

Topic: Cardiology » Hypertrophic Cardiomyopathy

Presentation Type: Poster

SIMULTANEOUS SEPTAL ALCOHOL ABLATION AND PERCUTANEOUS CORONARY INTERVENTION IN A PATIENT WITH HYPERTROPHIC OBSTRUCTIVE CARDIOMYOPATHY**Rabia Akilli, Onur Sinan Deveci, Çağlar Özmen, Mustafa Demirtaş***Çukurova University, Adana, Turkey***Corresponding Author (rabiaekerakilli@gmail.com)**rabiaekerakilli@gmail.com, onurdeveci@yahoo.co.uk, caglarozm@hotmail.com, mustdemirtas@cu.edu.tr***Abstract Text**

A 65-year-old male patient was admitted to our clinic with complaints of breathlessness (NYHA class II-III) and chest pain for about 2 years. Medical history revealed hypertension for 15 years. Physical examination was normal except 3/6 systolic ejection murmur heard at all foci. On electrocardiography rhythm was sinus and left ventricular hypertrophy voltage criterion was determined. On echocardiography ejection fraction was (62 %), mild mitral regurgitation, significant left ventricular hypertrophy (interventricular septum (IVS) and posterior wall thickness were measured 22 mm and 15 mm respectively), significant left ventricular outflow tract (LVOT) gradient were observed (110 mmHg). Septal alcohol ablation decision was taken for the patient and coronary angiography was performed before the procedure. Coronary angiography showed 70-80% lesion in mid LAD, 70% lesion in Cx mid region was observed (Fig. 1). A gradient of 80 mmHg was detected in the LVOT after valsalva during the procedure. First septal branch was selectively catheterized and after the contrast injection echocardiography confirmed the target region. Septal ablation was applied with 4 cc alcohol injection. Transcatheter gradient decreased to 20 mmHg and the procedure was terminated with success (Fig. 1). A 3.0 mm x 26 mm drug-eluting stent was implanted to the patient's LAD lesion successfully in the same session. Control echocardiography revealed contrast enhancement persisted in the basal part of IVS and a maximum of 25 mmHg gradient at rest and a 42 mmHg gradient after valsalva were detected in LVOT (Fig. 2). The patient with stable general condition at follow-up was discharged with recommendations.

In this case, performing septal alcohol ablation and percutaneous coronary intervention at the same session has been shown to be effective and safe

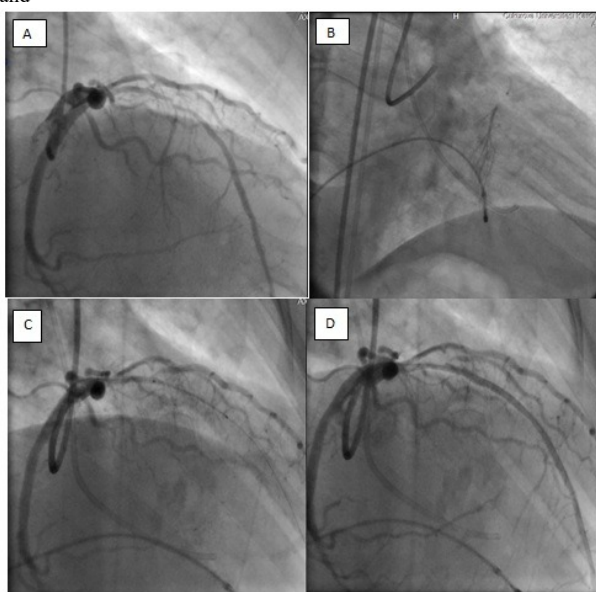


Figure 1: Angiographic and echocardiographic views of patient undergoing septal alcohol ablation and percutaneous coronary intervention at the same session

ID: 554

Topic: **Cardiology » Preventive Cardiology**Presentation Type: **Poster****EPIDEMIOLOGY OF CORONARY HEART DISEASE IN TURKEY****Serkan Ketenciler**¹, Aysun Perim Ketenciler², Ertuğrul Okuyan³¹*Okmeydanı Research and Education Hospital, Istanbul, Turkey*²*Arel University, Istanbul, Turkey*³*Health Science University Bagcilar Research and Education Hospital, Istanbul, Turkey***Corresponding Author (ketencilers@hotmail.com)**ketencilers@hotmail.com, aysunketenciler@arel.edu.tr, dreokuyan@hotmail.com***Abstract Text**

Epidemiology of Coronary Heart Disease in Turkey

Coronary heart disease (CHD) is the leading cause of mortality in all over the World also in Turkey. The treatment modalities of this disease have been more better time by time as paralel to technological healings last two decades. So mortality of the CHD has declined but prevalence of disease increased because of progressive population aging and immigration. In addition, unhealthy diet, sedentary behavior, smoking, obesity will robustly influence the progressive increase in the incidence of CHD in developing countries.

According to World Health Organization (WHO) datas, 17.9 million people die from cardiovascular diseases around worldwide in every year and this ratio covers 31 % of all deaths. In addition, a report that formed by WHO at 2018 named as noncommunicable diseases country profiles. It presents non-communicable diseases compose 89 % of the deaths occurred in Turkey in 2016. Cardiovascular diseases create 34 % of this ratio.

According to Turkish Statistical Institute datas in 2017, coronary heart disease formed to 39.7 % of the deaths related to cardiovascular system.

Prevalence of Chronic Diseases and Risk Factors Study in Turkey in 2011, angina pectoris was identified 6.4 % of the men and 9.8 % of the women according to the story or Rose questionnaire. History of the acute myocardial infarction was 2.3 % in men, 1.1 % in women. The frequency of coronary heart disease diagnosed by the doctor based on the declaration is 3.8 percent in males and 2.3 percent of women. Western Anatolia region (Ankara, Konya) is the region of Turkey with the highest rate of coronary heart disease for men (7.5 %). Western Black Sea (Zonguldak, Kastamonu, Samsun) and Central Anatolia (Kırkkale, Kayseri) are regions of Turkey with high frequency of coronary heart disease for women.

As we known that coronary heart disease continue to leading cause of the death in the large majority of the world also in Turkey. Although the management of the CHD are healing rapidly paralel to technological improvements, the preventive medicine and epidemiological studies are also so important to cope with disease. In this context, local or regional epidemiological studies are significant to recognize CHD and to identify which way to follow to prevent and to manage of it. So we consider that more local or regional epidemiological studies are needed in Turkey.

ID: 478

Topic: **Cardiology » Gene Therapy in Cardiovascular Disease**Presentation Type: **Poster****DYSPNEA WITH SEVERE RESPIRATORY ALKALOSIS IN ACUTE PERIOD AFTER TICAGRELOR USE****Hakkı Şimşek, Lezgin Dursun, Ali Evsen, Nizamettin Toprak***Dicle University Heart Hospital, Diyarbakır, Turkey***Corresponding Author (drhsimsek@gmail.com)**drhsimsek@gmail.com, lezgindursun893@hotmail.com, ali_evsen@hotmail.com, ntoprak@dicle.edu.tr***Abstract Text**

SEVERE DYSPNEA WITH RESPIRATORY ALKALOSIS IN ACUTE PERIOD AFTER TICAGRELOR USE

Ticagrelor, reversible and is a direct effective P2Y12 inhibitor. Bradycardia (4.4%) and transient shortness of breath (13.8%) have been reported as side effects in PLATO study. In our case, we will focus on the dyspnea, which causes serious respiratory alkalosis of the ticagrelor, which was started within the first 24 hours.

72-year-old patient, previously known Coronary Artery By-pass Graft Operation(CABGO) and DM history. He contacted to our outpatient clinic on a typical chest pain complaint that started a day ago. No known lung disease history. No signs of lung listening(rall and ronkus). The patient's basal electrocardiogram(IMAGE 1) in sinus rhythm Heart rate 84 beats / minute, pathological Q and 2 mm ST elevation in inferior leads, reciprocal available in D1-AVL leads. In echocardiography(ECHO);ejection fraction(EF) 40%(severe hypokinesia in the posterior and inferior walls), moderate mitral regurgitation and mild tricuspid regurgitation available. Arterial blood pressure was 135/85 mmHg. The respiratory rate was 15 and other vital values were constant. 300 mg ASA and 180 mg TICAGRELOR were applied to the patient and coronary angiography was performed: Successful percutaneous coronary intervention was performed in the Ao-Saphenous-RCA and Cx native artery. In the first 24 hours after the procedure, dyspnea occurred with tachypneal serious respiratory alkalosis. Ral and ronkus were not observed on physical examination. No orthopnea, respiratory rate 29 / minute, heart rate 99 beats/minute. Arterial blood gas(IMAGE 2); Ph: 7.55, mPCO2: 20 mmHg, HCO3: 25 mmol / liter, mPO2: 68 mmHg, saturation was 95% without oxygen. Posterior-anterior chest x-ray was natural(IMAGE 3). Echo and CT Torax Angiography were natural for pulmonary thromboembolism. His shortness of breath was attributed to ticagrelor and switch made with 600 mg clopidogrel 24 hours after the last Ticagrelor dose.

The patient's blood gas and tachypnea improved after 48 hours(IMAGE 4) and discharged with clopidogrel.

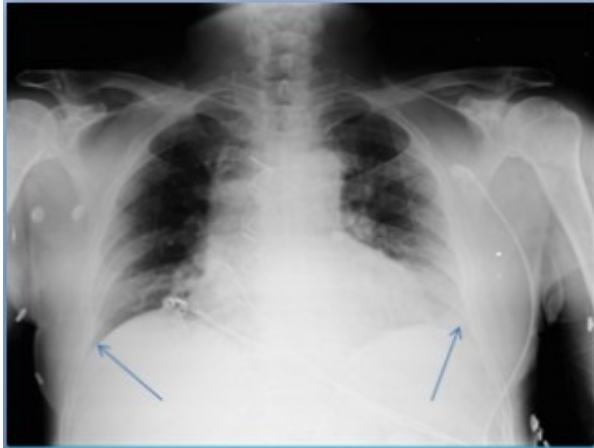

IMAGE 3:X-ray film of the patient

Parametre Adı	Sonuc	Birim
PCO2	35.3	mmHg
PO2	30.5	mmHg
pH	7.45	
Ca++	1.06	mmol/L
K+	3.8	mmol/L
Na+	131	mmol/L
Cl-	102	mmol/L
Hct	41.4	%
tHb	13.5	g/dl
cHCO3std	24.3	mmol/L
ctCO2	11.1	mmol/L
mCOHb	0.3	%
mGlucose	313	mg/dl
mHHb	39.4	%
mLactate	1.7	mmol/L

IMAGE 4:Blood gas after ticagrelor

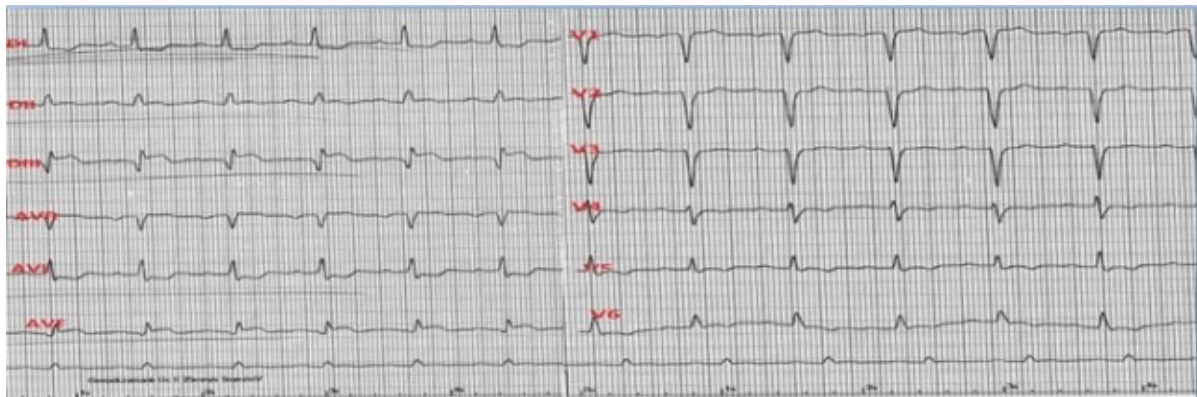

IMAGE 1:Baseline electrocardiography

Parametre Adı	Sonuc	Birim	Normal Değerler	Parametre Adı	Sonuc	Birim	Normal Değerler
PCO2	35.6	mmHg		mPCO2	20.6	mmHg	35 45
PO2	23.1	mmHg		mPO2	74.3	mmHg	80 100
pH	7.43			mpH	7.55		7.35 7.45
Ca++	1.07	mmol/L		mCa++	1.03	mmol/L	1.12 1.32
K+	3.5	mmol/L		mK+	3.4	mmol/L	3.5 4.5
Na+	133	mmol/L		mNa+	126	mmol/L	135 148
Cl-	105	mmol/L		mCl-	107	mmol/L	
Hct	41.2	%		Hct	43.5	%	
tHb	13.4	g/dl		mtHb	14.2	g/dl	11.5 17.4
cHCO3std	22.9	mmol/L		SO2	96.6	%	
ctCO2	8.2	mmol/L		cBE(m)	-1	mmol/L	
mCOHb	0	%		cBE(w)	-	mmol/L	
mGlucose	249	mg/dl		cHCO3std	22.7	mmol/L	
mHb	54.2	%		cHct	-	%	
mLactate	2.2	mmol/L	0.5 2.2	cO2SAT	-	%	
mMetHb	2.2	%		ctCO2	19	mmol/L	
mO2Hb	43.6	%		ctHb(est)	-	mmol/L	
				mBP	-	mmol/L	
				mCOHb	0.6	%	0.5 9.5
				mGlucose	264	mg/dl	50 110
				mHb	-	%	0 100
				mLactate	1.7	mmol/L	0.5 1.6

IMAGE 2:Arterial blood gas before ticagrelor

Arterial blood gas under ticagrelor

ID: 142

Topic: Cardiology » Preventive Cardiology

Presentation Type: Poster

PREDICTORS OF MORTALITY IN PATIENTS WITH FIRST EVER ISCHEMIC STROKE DURING LONG-TERM SURVEILLANCE

Tahir Bezin, Ruhan Özcan

Gebze State Hospital, Kocaeli, Turkey

*Corresponding Author (bezgintahir3@yahoo.com)

bezgintahir3@yahoo.com, ruhanozcan@yahoo.uk

Abstract Text

Aim: Stroke is a major debilitating disorder, has increased mortality. We aimed to study predictors of death in patients (pts) with first ever ischemic stroke during long term follow-up after index event.

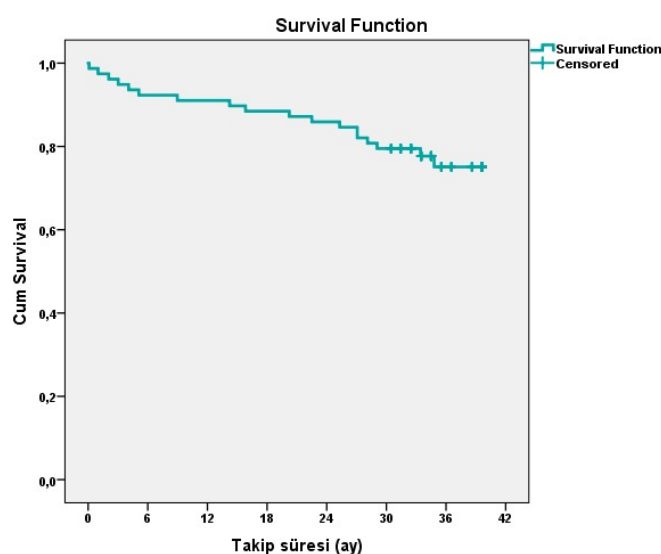
Materials and Methods: A total of 78 pts (female: 33(42,3%) diagnosed with first ever ischemic stroke admitted to the hospital were included in this prospective study. Patient survival was assessed by the telephone contact and national mortality record. Median follow-up duration was 33 months. There was neither recurrent ischemic nor hemorrhagic stroke.

18 pts were deceased during follow-up. 6 of them were female (p=NS). Pts those dead compared to survivors during follow-up were older (71,72±10,88 years vs. 64,42±11,21, p=0,02), higher incidence of atrial fibrillation (AF) [n=7 (41,2 %)], higher NLR [3 (2,2-5,3) vs. 2,3 (1,6-3,2), p=0,04], higher NT-pro BNP [90,1 ng/l (43,4-266,2) vs. 42,9 (11,7-93,6), p=0,03], higher TSH [1,7 mIU/l (1,2-3,1) vs. 1,1 (0,5-1,9), p=0,03] and lower Vitamin D levels [8,9 µg/l (2,8-12,4) vs. 12,4 (8,4-17,2), p=0,02].

Age [95% CI:1,01-1,12], OR:1,06, p=0,02] and D-dimer level [95% CI:1,097-2,18], OR:1,6, p=0,01] were found to be significant predictors of mortality in univariate logistic regression analysis. Only, AF was found to predict mortality in multivariate analysis [95 % CI:1,5-97,2), OR:12,2, p=0,02].

A cut off value ≥ 2.6 of NLR was found to predict death in stroke pts with 61,1 % sensitivity and 62,2 % specificity in ROC analysis Mean survival duration was 34,24±1,27 months. The last death was seen at the 34,8 month and cumulative survival rate was 75 %.

Discussion: Age, D-dimer and presence AF were significant predictors of death in ischemic stroke pts.



ID: 389

Topic: **Cardiology » Preventive Cardiology**

Presentation Type: **Poster**

NIVOLUMAB INDUCED TAMPONADE AND VITILIGO IN A PATIENT WITH MALIGNANT MELANOMA

Gokcen Atilboz Alagoz¹, Begum Yetis Sayin¹, Kubra Aydin¹, Selcuk Cemil Ozturk¹, Atike Tekeli Kunt², Seref Komurcu³

¹Memorial Ankara Hospital, Ankara, Turkey

²University of Health Sciences Ankara Numune Education and Research Hospital, Ankara, Turkey

³Anadolu Health Center, Ankara, Turkey

**Corresponding Author (gokcen_atilboz@hotmail.com)*

gokcen_atilboz@hotmail.com

Abstract Text

Objective: Malignant melanoma is known to be immunogenic. Immunogenic response is mainly mediated by T cells. Immunotherapy in malignant melanoma recently has been widely used and it is reported that it has significant effects on survival. In normal conditions immune checkpoints work as a negative controller on T cells and prevent autoimmunity. The most popular inhibitor receptors are Cytotoxic T-lymphocyte-associated antigen 4 (CTLA-4) and programmed cell death receptor-1 (PD-1). Nivolumab binds PD-1 and inhibits its activity. In this report we aimed to present a case admitted with several complications of Nivolumab.

Methods: A 62 year old female patient with metastatic malignant melanoma admitted to our clinic with massive pleural effusion, vitiligo and cardiac tamponade after 7th Nivolumab administration.

Results: After pericardiocentesis and corticosteroid treatment, the patient's condition improved rapidly.

Conclusions: It should be kept in mind that Nivolumab even though thought to be less toxic than chemotherapy, may cause severe complications.

ID: 393

Topic: **Cardiology » Preventive Cardiology**Presentation Type: **Poster****WHAT IS THE SIGNIFICANCE OF ELEVATED TROPONIN I IN CHILDREN AND ADOLESCENTS?****Tamer Yoldaş**, Utku Arman Örün, Vehbi Dogan, Mehmet Emre Ari*Dr. Sami Ulus Maternity, Children's Health and Diseases Training and Research Hospital, Ankara, Turkey***Corresponding Author (tameryoldas@gmail.com)**tameryoldas@gmail.com, utkuarman@gmail.com, vdogan86@yahoo.com, memreari@yahoo.com***Abstract Text**

Objectives: Troponin is a marker that displays cardiac injury quickly and accurately. In adults, troponin elevation is usually associated with coronary artery disease and requires urgent cardiac catheterization. In healthy children, myocardial injury is rare and may develop due to many different causes. Therefore, troponin elevation in children and adolescents usually does not require emergency cardiac catheterization. The aim of this study is to assess the most common causes of troponin elevation in children and adolescents and to show which diagnostic tests are helpful in assessing pediatric patients with elevated troponin.

Material and Methods: The patients who were diagnosed with troponin I elevation (> 0.06 ng /ml) at Dr. Sami Ulus Maternity, Children's Health and Diseases Training and Research Hospital between 2007-2016 were retrospectively evaluated. Patients undergoing cardiac surgery and patients with severe congenital heart disease were excluded from the study. The medical records of the patients were examined and age, gender, diagnostic tests and diagnosis were evaluated.

Results: During the study period, records of 632 patients were reached, 57 patients were excluded from the study because of heart surgery. Of the remaining 575 patients, 55% were male, 45% were female and the median age was 4 years (3 days to 17 years). The asphyxia (n: 75) was the most common cause in the newborn age group. The most frequent causes in other age groups are myopericarditis (n: 88), drug intoxications (n: 59), carbon monoxide poisoning (n: 54), myocarditis (n: 52), intensive inhalation β agonist use in acute asthma and lower respiratory tract infections (n: 49). Patients diagnosed with myocarditis and myopericarditis were admitted with the complaint of chest pain, and the diagnosis was made by history, physical examination, ECG and echocardiography findings.

Conclusions: Unlike adults, troponin I elevation may be associated with many cardiac and non-cardiac pathologies in children. The most common pathologies in cardiac etiology are myocarditis and pericarditis and can be diagnosed by history, physical examination, ECG and echocardiography. Cardiac catheterization is not necessary except for rare cardiac pathologies and does not alter prognosis.

ID: 182

Topic: **Cardiology » Preventive Cardiology**Presentation Type: **Poster****WHICH FACTORS COULD BE ASSOCIATED TO IATROGENIC ADVERSE EVENTS RELATED TO VITAMIN K ANTAGONIST? PROSPECTIVE SURVEY OF 150 PATIENTS****Maryam Mouadili***Centre Hospitalier Universitaire Mohammed VI Marrakech, Marrakech, Morocco***Corresponding Author (maryam.mouadili@gmail.com)**maryam.mouadili@gmail.com***Abstract Text**

Abstract

Introduction:

There is a major public healthcare problem related to the use of vitamin K antagonists VKA. Because of their narrow therapeutic index, they expose to two major risks: thrombosis and hemorrhage. These risks put the VKA at the top rank of the list of iatrogenic risks.

Methods:

We have conducted a prospective survey over a 23 months period. All the patients admitted in our cardiology consultation, who were recently put on anticoagulation therapy using VKA, were included. A follow up during a period of one year +/- 3 months (3 to 4 follow up consultations) was done, to detect adverse iatrogenic events related to health care practices of medical doctors and pharmacists and/or to the behavior of patients regarding their treatment.

Results:

150 patients treated with vitamin K antagonists were included in the survey. 68 of them (45,33%) presented an iatrogenic hemorrhagic 38% (57 patients) or ischemic event 7,33% (11 patients) during a follow up period of one year +/- 3 months. From amongst the 68 patients, 21 had a prescription of VKA that did not take into account their past medical history ($p=0,0003$). The prescription of an incorrect dose and/or administration frequency is more common in the group of patients that presented minimal hemorrhage ($p<0,0001$). The absence of intervention of the pharmacist regarding medical interactions, contra-indications and incorrect doses was observed in 72% of these patients with an iatrogenic incident ($p<0,0001$). Self-medication, the aleatory VKA use, the insufficient INR control, and the poor compliance to the treatment, rise the iatrogenic risk of vitamin K antagonists ($p<0,0001$).

DISCUSSION AND CONCLUSION

The beneficial effects of vitamin K antagonists treatment rely on the compliance of the prescribers to the recommendations' of use and of the biological testing follow up, especially in the elderly, as well as an efficient intervention of pharmacists whilst delivering the medication, and the implication of the patient in the therapeutical management by a thorough education.

ID: 127

Topic: **Cardiology » Preventive Cardiology**Presentation Type: **Poster**

EVALUATION OF LONG TERM CARDIAC SIDE EFFECTS OF ANTHRACYCLINE CHEMOTHERAPY BY CONVENTIONAL AND NON-CONVENTIONAL ECHOCARDIOGRAPHIC METHODS IN CHILDHOOD CANCER SURVIVORS

Tamer Yoldaş, Şule Yeşil, Selmin Karademir, Utku Arman Örün, Vehbi Dogan, Senem Özgür

Dr. Sami Ulus Maternity, Children's Health and Diseases Training and Research Hospital, Ankara, Turkey

**Corresponding Author (tameryoldas@gmail.com)*

tameryoldas@gmail.com, suleyesil@yahoo.com, selminkarademir@yahoo.com, utkuarman@gmail.com, vdogan86@yahoo.com, drsenemozgur@hotmail.com

Abstract Text

Objective: Anthracycline chemotherapeutic agents carry the well-recognized risk of cardiac toxicity. The aim of this study was to determine the long term effect of anthracycline chemotherapy on the biventricular function in childhood cancer survivors using tissue Doppler imaging (TDI) and 2D speckle tracking echocardiography (2D-STE).

Patients and Methods: The study included 45 survivors of childhood cancers and 50 healthy age matched control subjects. Cardiac function was prospectively studied with 2D echocardiography, TDI and 2D-STE after completion of treatment. The same analysis was performed on matched controls.

Results: There was no difference in age, gender, height and weight between the study and control groups. The mean anthracycline dose was 240 ± 106 mg/m² and the mean remission duration was 8.2 ± 5 years (1-20 years) in the study group. Conventional echocardiography showed similar ejection fraction, shortening fraction and left ventricle end-diastolic diameter in both groups. Mitral lateral and septal TDI studies showed systolic and diastolic dysfunction in the patient group. The global longitudinal and circumferential strain and strain rates were significantly lower in the patient group compared to the control group. Correlation analysis revealed a negative and significant correlation between total anthracycline dose and global longitudinal and circumferential strain and strain rates.

Conclusion: Subclinical systolic and diastolic dysfunction may not be detected by conventional echocardiographic methods which are frequently used in daily practice. Subclinical systolic and diastolic dysfunction may be detected more sensitively by echocardiographic methods such as TDI and 2D-STE in childhood cancer survivors.

ID: 198

Topic: **Cardiology » Diseases of Aorta**Presentation Type: **Poster****DILEMMA: INFERIOR STEMI OR AORTIC DISSECTION?****Cansu Ebren, Eser Durmaz, Zehra Lale Koldaş***Cerrahpaşa Faculty of Medicine, Istanbul, Turkey***Corresponding Author (cansuebren@yahoo.com)**cansuebren@yahoo.com, durmazeser@hotmail.com, lalekoldas@gmail.com***Abstract Text**

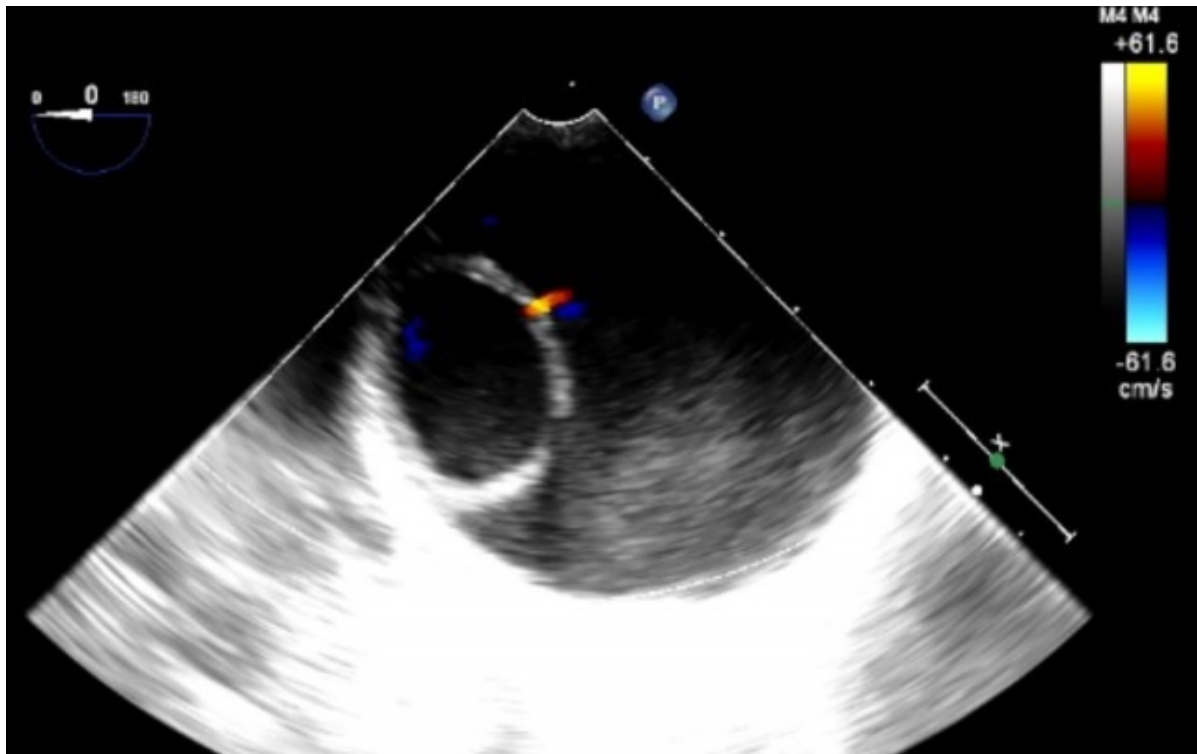
Dilemma: Inferior STEMI or Aortic Dissection?

Aortic dissection (AD) is a life threatening emergency clinical picture. In rare cases, myocardial infarction may develop as the dissection flap in the ascending aorta disrupts coronary blood flow and in the case of inappropriate anticoagulation or thrombolytic therapy for such undiagnosed patients, the mortality rate has been reported to be as high as 69-100%. In addition, the difficulties in the diagnosis delay the surgical operation that needs to be applied urgently. In this case, we discussed inferior myocardial infarction secondary to aortic dissection.

A 54-year old male patient without a history of chronic disease presented to the external center 6 months ago with acute coronary syndrome clinic. In his family history, his brother has a history of emergency operation due to aortic aneurysm and dissection. Applied to the patient coronary angiography revealed complete right coronary artery occlusion. When the lesion in the RCA is not passed through by floppy, intermediate and extrasupport wires 1.5x12 mm and 2x20mm balloons dilated with proximal to RCA. But distal flow couldn't be achieved. The patient was followed-up 10 days in CICU and was discharged with medical treatment. He was admitted to the hospital due to decompensated heart failure 5 months later, applied to transthoracic echocardiography revealed an aortic regurgitation and the ascending aorta was measured as 55 mm and 46 mm as descending aorta. The patient who was consulted with KVS was recommended to plan the operation after clinical recovery. In April 2018, he was hospitalized with decompensated heart failure. In the physical examination, the third heart sound and mesocardiac focus 3/6 diastolic murmur were heard. Intravenous diuretic treatment was started in the patient who had crepitanal ral in the bilateral lung, ascites in the abdomen, jugular venous fullness and 3+ pretibial edema. The LVEF value was 26% of the patient's entire heart was found in the gaps wide. Central mitral regurgitation and mild to moderate aortic regurgitation were detected in the patient's sinus valsalva 46 mm, ascending aorta 62 mm. Dissection with a diameter of 4.5-5 cm above the aortic root with a diameter of 0.8 cm upon monitoring suggestive view transesophageal echocardiography was performed. A dissection line extending from the aortic annulus to the descending aorta was seen. With color Doppler viewed transition between false lumen and true lumen in descending aorta. The patient who had old coronary angiography images was found to have inferior myocardial infarction secondary to type A aortic dissection. The patient underwent thoracoabdominal CT angiography. Continuous dissection from the aortic arch to iliac bifurcation view compatible with. The dissection flap extended to the left renal artery and proximal to the right renal artery. The patient was transferred to the KVS for operation.

Conclusion

The incidence of myocardial infarction in AD patients ranges from 1% to 5%. Type A aortic dissection usually occurs on the right sinus and retrograde to the aortic root, the right coronary artery more than the left main coronary artery. Therefore, patients develop mostly inferior STEMI. Both AD and acute myocardial infarction with acute chest pain initiation, changes in ECG and cardiac biomarkers make differential diagnosis difficult. As highlighted in the 2017 ESC STEMI Guideline, patients with suspected CT angiography should be performed and differential diagnosis should be made.



New Perspectives in CVS

ID: 385

Topic: **Cardiology » Arrhythmias and Antiarrhythmic Therapy**Presentation Type: **Poster**

DRAMATIC VISUAL IMPROVEMENT AFTER CABG SURGERY: CASE REPORT

Mehmet Ali Yeşiltaş, Sadiye Deniz Özsoy, Ismail Yavuz Keleş*Istanbul University Cerrahpaşa Institute of Cardiology, Fatih, Turkey***Corresponding Author (dr.maliyes@gmail.com)**dr.maliyes@gmail.com, sdenizozsoy@gmail.com, yavuzkeles92@gmail.com*

Abstract Text

Dramatic Visual Improvement After CABG Surgery: Case Report

Cabg is a surgery of choice in patients with acute coronary artery disease. Complications of the surgery, postoperative medical treatment and its adverse effects are well known. The term optic neuropathy refers to any disease of the optic nerve which can be caused by viral infections, vitamin deficiencies and genetic/traumatic/ischemic/toxic etiologies. 61 year old male patient underwent CABGx3 operation. Patient experienced atrial fibrillation on first postoperative day. The electrolyte values were normal, and his oxygenation was sufficient. Patients heart rate was 150 bpm. We used 5mg iv metoprolol for rate control and started 1 gram amiodarone infusion after giving 300mg of loading dose. Patient had daily 100mg of coraspin and 2x0,8 cc enoxaparin sodium for daily treatment. After taking approximately 600mg of amiodarone, patient complained about blur and loss of vision in his right eye. Patient had a %40 stenosis in his left internal carotid artery according to his preoperative doppler USG. So we considered a thromboembolic/ischemic accident or hemorrhagic event due to enoxaparin sodium. We consulted the patient with neurology department. Patient's eye movement's were normal, light reflex was present in both eyes. Pupils were isocoric, but loss of vision was increasing. We scheduled cranial MRI and BT for patient which were also normal. There were no hemorrhagic lesions in the cranial BT. There were no ischemic areas, damage of the optic nerve or bleeding in the sheath. Retinal artery flow was present. We consulted the patient with Ophthalmology department. Funduscopy examination revealed edema in the right central disc. Due to the fact that vision loss/blur happened at first postoperative day, we couldn't perform detailed funduscopy and visual field examination with automatic perimetry back then. Central vision loss was present. We reevaluated the patient and considered this to be toxic optic neuropathy which is one of the adverse effect of the newly administered amiodarone. At this time the patients rhytm was sinus and he had 900mg of amiodarone infusion. We stopped the amiodarone and ordered 3x20 mg of methylprednisolone. The advancement of visual loss stopped and it started to decrease at third postoperative day. At sixth postoperative day patient's visual field was almost back to normal but he was still experiencing blurry vision. Fundoscopy examination showed minimum edema at right central disc. Patient discharged with a seven day later control appointment. At postoperative thirteenth day patient had no complaints about his vision.

Optic neuropathy has vast etiologic factors. It can be unilateral or bilateral. If it is caused by an underlying factor, it should be treated. It may be reversible or irreversible. Differential diagnosis should be made with haste in order to prevent a reversible optic neuropathy to irreversible one. Atrial fibrillation after CABG surgery is a frequent complication and its treatment protocol includes amiodarone. Side effects of the amiodarone should be considered before use. Optic neuropathy due to amiodarone usually present bilaterally but we should note that it can present with unilateral symptoms. This case report shows that we should always keep in mind that medications we use for treatment has adverse effects and we should consider them before ordering them.

ID: 232

Topic: Cardiovascular Surgery » Thoracic and Thoracoabdominal Aortic Dissections and AneurismsPresentation Type: **Poster****SURGICAL TREATMENT OF LEFT VENTRICULAR PSEUDOANEURYSM AFTER MYOCARDIAL INFARCTION**Celalettin Günay, **Hüseyin Sicim**, Gökhan Arslan, Hakan Kartal, Bilgehane Savaş Öz*Gulhane Training and Research Hospital, Ankara, Turkey***Corresponding Author (celalettin.gunay@sbu.edu.tr)**celalettin.gunay@sbu.edu.tr, huseyinsicim@yahoo.com.tr, drgokhanarslan@gmail.com, hakhankartal@gmail.com, bilgehansavas.oz@sbu.edu.tr***Abstract Text**

INTRODUCTION: Left ventricular pseudoaneurysms are a rare complication of myocardial infarction which may cause serious morbidity and mortality. Although it is difficult to diagnose, it is possible to detect it by non-invasive methods. Left ventricular pseudoaneurysms have a risk of rupture of 30-45%. Surgical treatment option comes to the fore due to the risk of rupture. We report the successful treatment of late left ventricular pseudoaneurysm following MI in this case.

CASE REPORT: A 67-year-old male patient was admitted to the emergency department with complaints of chest pain one month ago. Coronary angiography was performed for myocardial infarction and stent implantation was performed for LAD. In the control echocardiographic images of the patient who was discharged without any complication, pseudoaneurysm was detected in the left ventricular apex. Echocardiography revealed an ejection fraction of 35%, left ventricular apical, hypokinetic and aneurysmatic. Aneurysmatic segment of the left ventricular apex was found in the patient with cardiopulmonary bypass due to high risk of rupture. Aneurysmal segment approximately 3 cm in diameter was resected with ventriculotomy.(Figure 1) The pouch was filled with organized thrombus material. The resected area was cleaned and repaired using teflon felt. The patient who was in need of positive inotropic support for five days postoperatively, was discharged with cure at the postoperative 12th day.

DISCUSSION AND CONCLUSION: Ventricular pseudoaneurysm is defined as the rupture of the myocardial wall with blood flow to a cavity of pericardium, thrombus or adhesions. Ventricular pseudoaneurysms may be a rare complication of postoperative cardiac surgery or transmural MI. The clinical presentation of left ventricular pseudoaneurysm is heart failure, embolism, arrhythmias and sometimes sudden cardiac death due to rupture. Some pseudoaneurysms are surprisingly stable and may remain unnoticed for years. In addition to echocardiography, cardiac computed tomography is a serious guide in the diagnosis. Surgical intervention should always be considered as the first choice in pseudoaneurysm cases because of the high risk of mortality in the conservative approach, and should remain a routine choice for high-risk patients.

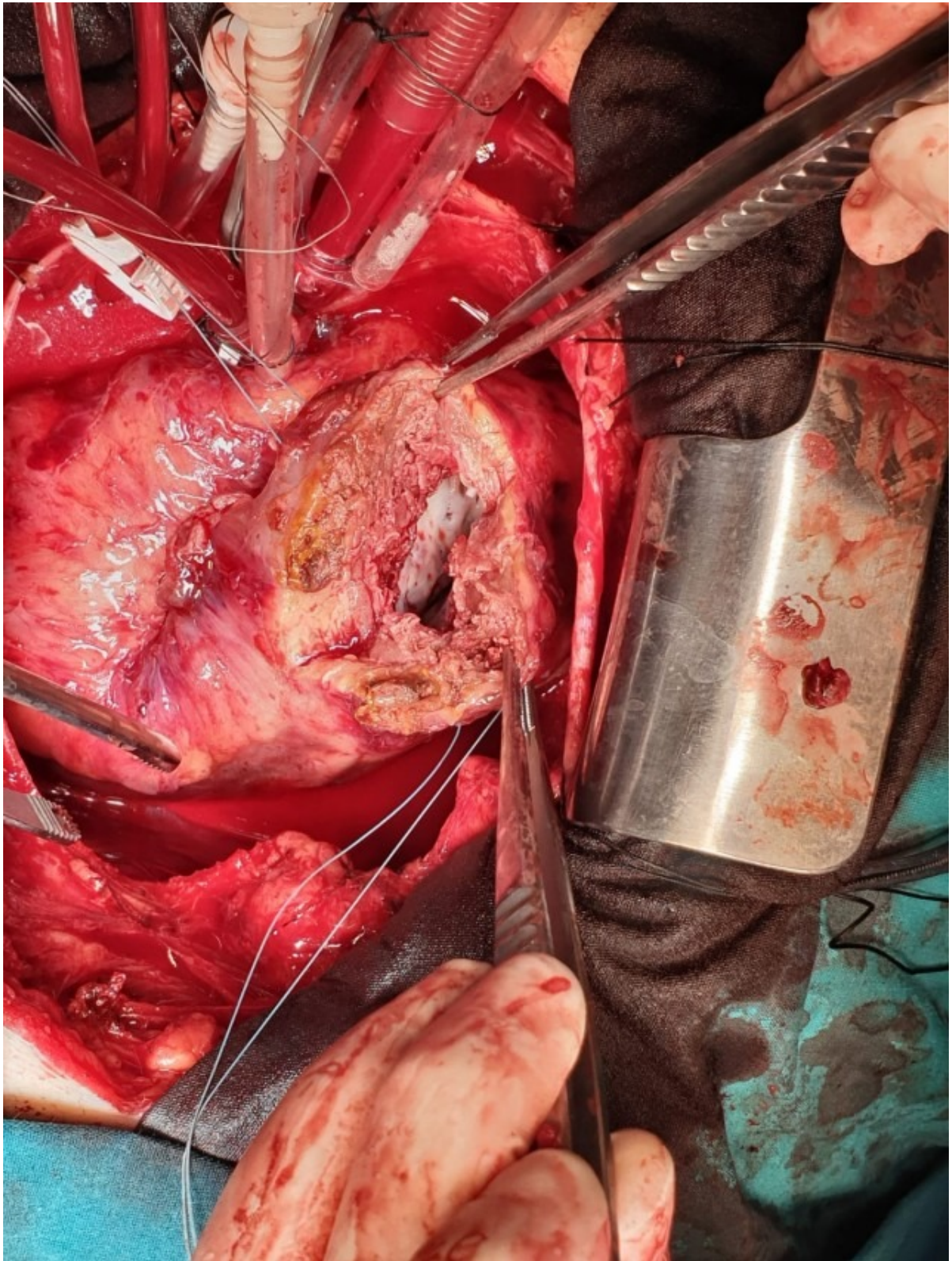


Figure 1. Ventriculotomy of the left ventricular apex

ID: 435

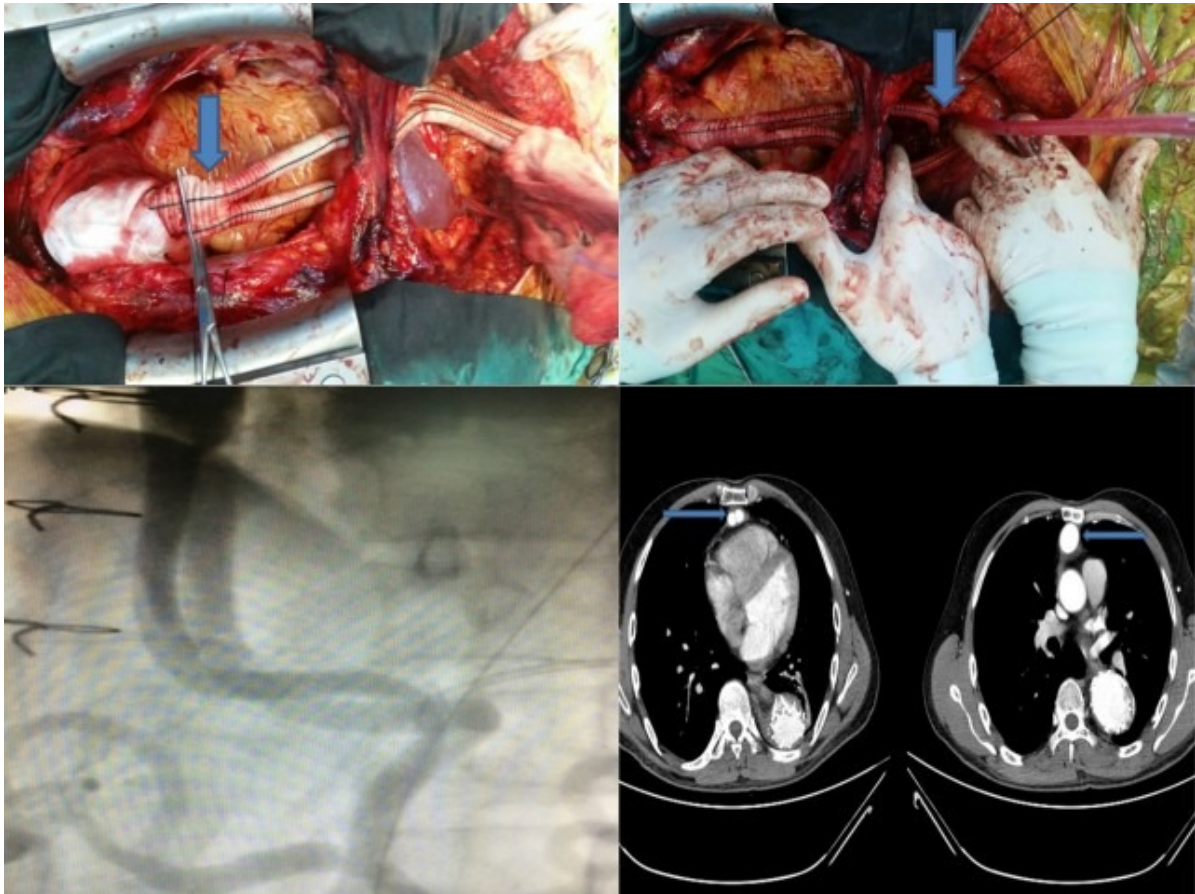
Topic: **Cardiovascular Surgery » Hybrid Cardiovascular Surgery**Presentation Type: **Poster****HYBRID APPROACH TO COMPLEX TYPE 3 DISSECTION: UNUSUAL EXTRAANATOMICAL BY-PASS + ENDOVASCULAR REPAIR OF THE THORACIC AORTA (TEVAR) + CHOLECYSTECTOMY****Sinan Demirtaş¹**, Nazım Kankılıç², Celal Yavuz³¹*Özel Bower Hospital, Diyarbakır, Turkey*²*Medical School of Harran University, Şanlıurfa, Turkey*³*Medical School of Dicle University, Diyarbakır, Turkey***Corresponding Author (sinandemirtas78@hotmail.com)**sinandemirtas78@hotmail.com, nfkan82@gmail.com, celalyav@hotmail.com***Abstract Text**

OBJECTIVE: Patients with complex type B aortic dissection are very difficult to treat. Many methods have been proposed so far in the treatment of these patients. With the emergence of hybrid techniques, patients with complex type B aortic lesions have become easier to treat. In this article, we shared the extraanatomical bypass + Endovascular Repair of the Thoracic Aorta (TEVAR) + cholecystectomy operation technique applied to the patient with complex type B aortic dissection.

METHODS: A TEVAR procedure was performed on a 36 year old male patient with type 3 aortic dissection (Celiac artery, superior mesenteric artery and renal arteries are coming out of true lumen). On the 5th postoperative day, he developed severe abdominal pain, nausea and vomiting. Contrast-enhanced tomography was performed due to these complaints. Tomography revealed a new tear from the distal part of the stent graft at the upper level of Celiac and Superior mesenteric artery (SMA) and true lumen was seriously narrowed. The patient was prepared for the operation. A proximal anastomosis was performed to the aorta with a Dacron graft by placing a side clamp on the aorta after the sternotomy (Picture). Then laparotomy was performed. SMA and Celiac arteries were found. The legs of the Dacron graft were passed through the pericardium and diaphragm (Picture). Distal anastomoses were performed to the SMA and Celiac artery (Picture). After anastomoses, the SMA and Celiac artery were ligated from the aorta outlet. In the exploration, the hydropic gallbladder was seen and excised at the same session. The TEVAR procedure was then applied to include Celiac and SMA. Angiography showed that Dacron graft worked well (Picture). Sternotomy and laparotomy were closed and the operation was completed. CT angiography was performed 1 year after the follow-up of the patient, and Dacron graft was open and TEVAR stent graft also provided aortic continuity (Picture).

CONCLUSION: We think that Extraanatomical Bypass + TEVAR procedures may be an alternative operation technique in complex type B dissection patients.

Keywords: Extraanatomical bypass, TEVAR, hybrid, cholecystectomy, aortic dissection



*Operation images and Control CT angiography after 1 year

ID: 189

Topic: **Cardiovascular Surgery » Hybrid Cardiovascular Surgery**Presentation Type: **Poster****OUR EXPERIENCE OF EMERGENT CASES: THE SURGICAL TREATMENT OF THROMBO-EMBOLUS IN TRANSIT.****Oybek Mashrapov, Abdusalom Abdurahmanov***Republican Research Center of Emergency Medicine. Tashkent, Uzbekistan, Tashkent, Uzbekistan***Corresponding Author (docmashrap@yahoo.com)**docmashrap@yahoo.com, ab.abdurakhmanov@yandex.com***Abstract Text**

INTRODUCTION: Blood clots of the main veins of the lower extremities are the main cause of pulmonary thromboembolism (PE). Pulmonary thromboembolism is recorded in 2-15% of autopsies. Mortality from pulmonary embolism exceeds that from myocardial infarction. Mortality in pulmonary thromboembolism reaches 30%, but adequate patient management with accurate diagnosis and on time appointment of optimal treatment can reduce this number to 2-8% (Bergqvist D. et al.). Floating blood clots in the path from the legs to the pulmonary arteries are a severe form of venous thromboembolism with high early mortality. The development of extracorporeal technologies and cardiac surgery techniques made it possible to perform surgery safely under the conditions of complete arrest of blood circulation. This is one of the conditions for the radical surgical treatment of a pulmonary artery developing as a result of a transient thromboembolism.

Aim of the study: Our surgical experience and prophylaxis of transient pulmonary thromboembolism are demonstrated in the study. **Materials and methods:** During the period from 2015 to 2018, 6 patients with pulmonary thromboembolism have been on surgery at the RSCOMP. All patients were female. The average age of patients was 56.2 ± 3.4 years old. All patients came to us at an early stage with deep vein thrombosis, mainly after the removal of uterine fibroids and inadequate hormone therapy. In all patients, hypochoic loose thromb were observed during the examination of the lower limb CDS, and the floating atrial right thrombus was visualized on the echocardiography. The complex prevention of pulmonary embolism including: a dynamic assessment of the embolism of a blood clot, adequate anticoagulant therapy to prevent the prolongation of thrombosis, thrombectomy from the right atrium and inferior vena cava clipping. All operations were performed under the conditions of artificial blood circulation with sternotomy access. After connecting the CPB pump, as a rule, the surgery is ended with a thromboembolectomy from the right atrium. On the next stage, inferior vena cava clipping was performed through the retroperitoneal access (using the original clip).

Results: Mortality rate was 0% during the hospital stay. In the long-term period of 18 months, mortality was also not noted. The inferior vena cava syndrome was developed in 2 patients. In 4 patients, postthrombotic syndrome was developed during long-term period.

Conclusions: Thrombo-embolectomy from the right atrium and inferior vena cava clipping prevents massive pulmonary embolism and prolongs the life of the patients. However it can aggravate the development and course of chronic venous insufficiency.

ID: 552

Topic: **Cardiovascular Surgery » Coronary Bypass Surgery**Presentation Type: **Poster****CONCOMITANT SURGICAL TREATMENT OF TIMOMA AND
CORONARY ARTERY DISEASE****Vedat Bakuy¹**, Aylin Özsancağ Uğurlu¹, Nadire Küçüköztaş², Umut Kocabaş¹, Hakan Altay¹, Seçkin Pehlivanoglu¹, Emin Pashazade², Gülay Eren², Deniz Süha Küçükaksu¹¹*Başkent University Faculty Of Medicine, Istanbul, Turkey*²*Başk, Istanbul, Turkey***Corresponding Author (vedatbakuy@yahoo.com)**vedatbakuy@yahoo.com, ao.ugurlu@baskent.edu.tr, n.kucukoztas@baskent.edu.tr, u.kocabas@baskent.edu.tr, h.altay@baskent.edu.tr, s.pehlivanoglu@baskent.edu.tr, e.pashazade@baskent.edu.tr, g.eren@baskent.edu.tr, ds.kucukaksu@baskent.edu.tr***Abstract Text**

In this case report we present a case diagnosed with timoma and had unstable angina. Coronary angiography was performed, left main coronary artery disease was revealed. In chest tomography a 15x10 cm solid mass covering all above the anterior pericardium was demonstrated and surgery was planned. Cardiopulmonary bypass with peripheral cannulation was prepared. Sternum was opened with oscillating saw and tumor body was extracted with meticulous dissection from jugulum to xiphoid process. Extended anterior pericardiectomy was done till the border of bilateral phrenic nerves with surrounding mediastinal tissue. Care was given to complete the resection in one piece in order not to spread any debris to surrounding tissue.

Coronary arteries were bypassed (Lima-AD, Ao-RCA, Ao-CxOM) on beating heart without cardiopulmonary bypass to avoid hematogenous spread and postoperative course was uneventful. Pathological evaluation revealed timoma (stage IIIb). On PET-CT exam no metastasis was demonstrated and surgical border lines were clear from tumor cells. As a result we can conclude that concomitant coronary artery bypass surgery and solid tumor mass removal can be safely achieved and satisfactory survival can be granted.

ID: 521

Topic: **Cardiovascular Surgery » Coronary Bypass Surgery**Presentation Type: **Poster****COMPARISON OF AND COLLOIDS AS PRIME SOLUTION IN CORONARY ARTERY BYPASS SURGERY****Resul Çalıř¹, Hürmet Aytekin¹, Türkan Kudsiođlu¹, Halil Türkođlu²**¹*Dr. Siyami Ersek Thoracic And Cardiovascular Surgery Training And Research Hospital, Istanbul, Turkey*²*Istanbul Medipol University Medical Faculty, Istanbul, Turkey***Corresponding Author (resulprf@gmail.com)**resulprf@gmail.com, hurmet.cinar@gmail.com, turkancoruh@gmail.com, hturkoglu@medipol.edu.tr***Abstract Text**

OBJECTIVE: Various crystalloids and colloids are used as prime solution during cardiopulmonary bypass (CPB). Hemodilution and decrease in colloid osmotic pressure due to the fluids used plays an important role in organ dysfunction in the postoperative period. It is discussed whether the side effects of CPB will be affected by the composition of the prime solution. In our study we compared intraoperative and postoperative hemodynamic and biochemical effects of crystalloids and colloids used as prime solution.

METHODS: The patients were randomized; Group I (n = 30) using ringer solution and Group II (n = 30) using 6 % HES (130/0,4) (Voluven, Fresenius) and Group III (n = 30) using 4 % gelofusine (GELOFUSINE, 30). In all groups, heart rate (HR), systolic arterial pressure (SAP), diastolic arterial pressure (DAP) measurements after anesthesia induction, before CPB, after CPB, postoperative 1st hour, postoperative 12th hour and postoperative 24th hour recorded. Hemogram, glucose, urea, creatinine, albumin, ALT, AST levels were followed. In addition, CPB durations, duration of operation, intraoperative and postoperative fluid and blood requirements, and hemorrhage and diuresis amounts were recorded.

RESULTS: There was no statistically significant difference between the groups in demographic data, crossing time, bypass time, operation time, HR, DAP, hemorrhage and diuresis amounts, intraoperative and postoperative fluid and blood replacements, and biochemical parameters.

Patients in Group I had a lower postoperative 1st hour SAP ($120,400 \pm 17,539$) than Group II ($130,533 \pm 14,569$) and Group III ($128,667 \pm 16,242$). Additionally Group III postop 1st hour hemoglobin ($10,147 \pm 1,273$) were significantly lower than Group I ($11,130 \pm 1,549$) and Group II ($11,023 \pm 1,180$) ($p < 0,010$).

CONCLUSION: We believe that we can use colloid solutions safely in coronary artery bypass surgery. We can say that %6 HES(130/0.4) may be an alternative to other colloids in patients who require a particularly high amount of colloid replacement, because they have particularly low molecular weight and the accumulation effect in the body is less and the elimination is easier.

ID: 501

Topic: **Cardiovascular Surgery » Coronary Bypass Surgery**Presentation Type: **Poster****UNEXPECTED MALIGNANCIES IN CARDIAC SURGERY**Tuğra Gençpınar, Şahin Karakılıç, **Reha Topak**, Öztekin Oto*Dokuz Eylul University Faculty of Medicine, İzmir, Turkey***Corresponding Author (tugra.gencpinar@deu.edu.tr)**tugra.gencpinar@deu.edu.tr, sahin.karakilic@deu.edu.tr, dr.rehatopak@gmail.com, oztekin.oto@deu.edu.tr***Abstract Text****OBJECTIVE:**

Since both cardiac disease and malignancy are widely prevalent, it is frequent to see patients facing both active cardiac disease and malignancy at the same time. Before performing cardiac surgery, in general, the staging of tumor, the assessment of the prognosis and the possibility of being able to improve survival are crucial. Furthermore, in presence of a very advanced stage of cancer, for which no therapy is judged suitable to prolong survival or improve quality of life, cardiac operation is contraindicated. However, there also might be unexpected malignancies recognized during the cardiac surgery. Here we present two patients who underwent cardiac surgery in which the patients had incidentally been found to have cancer.

METHODS:

Case 1: A 76-year-old male was admitted to our clinic with the operation plan for multivessel coronary artery disease due to chest pain. As a nodule was observed in the preoperative chest radiography, the patient underwent coronary artery bypass grafting and mass resection with wedge biopsy in the same session. The pathology report showed patient to have lung metastasis due to malignant melanoma. Postoperatively, no event was observed except prolonged drainage in the right chest tube. Once the drainage stopped, the chest tube was removed. On the postoperative day 15 the patient was discharged with a follow-up plan and was referred to the oncology clinic for the initiation of oncological treatment.

Case-2: A 63-year-old male patient with no smoking history presented with chronic dry cough for the past 6 months and shortness of breath upon physical activity for the past 1 month. Computed tomography with intravenous contrast agent showed massive pulmonary embolus located in the pulmonary artery. Patient underwent pulmonary endarterectomy with median sternotomy. Excised material was evaluated by pathological examination and revealed to be pulmonary intimal sarcoma. No event was encountered in the postoperative follow-up of the patient. Patient was discharged on postoperative day 10 and referred to the Oncology Clinic for medical treatment. RESULTS: In both cases, the malignancies had not been identified in the preoperative period. As a result of pathological evaluation of the samples collected intraoperatively, oncological treatments of the patients were initiated.

CONCLUSION:

Normally, tumor resection in the same session with open heart surgery requires serious preoperative preparation. Nevertheless, no complications were observed in the postoperative period in our cases, although patients had not undergone proper preoperative preparation.

ID: 336

Topic: **Cardiovascular Surgery » Coronary Bypass Surgery**Presentation Type: **Poster****OFF-PUMP CORONARY ARTERY BYPASS GRAFTING IN PATIENTS WITH LEFT VENTRICULAR DYSFUNCTION**Oybek Mashrapov, **Abdusalom Abdurakhmanov**, Mustafa Obeyd*Republican Research Center of Emergency Medicine, Tashkent, Uzbekistan***Corresponding Author (docmashrap@yahoo.com)**docmashrap@yahoo.com, ab.abdurakhmanov@yandex.com, mustafaobeyd@yahoo.com***Abstract Text**

Objective: coronary artery bypass grafting in patients with reduced left ventricular contractility associated with worse early outcome, high level of morbidity and mortality. The aim of this cohort study is evaluation of the immediate results of surgical treatment of patients with chronic ischemic heart disease with reduced left ventricular function (ejection fraction less than 35% according to EchoCG data).

Materials and methods: this cohort study included 89 patients with reduced left ventricular ejection fraction operated in our department during the period of December 2013 to January 2018. The mean age was 57.7 ± 6.8 years. All of those patients had congestive heart failure on admission (IV class NYHA) and at least one episode of myocardial infarction. Diabetes mellitus was diagnosed in 31 patients (34.8%), and obstructive pulmonary disease – in 12 (13.5%). The 35 patients (39.3%) had symptoms of angina of high functional class III and IV, and 49 (55.1%) and 5 (5.6%) respectively were operated with unstable angina or ongoing myocardial infarction. The function of the left ventricle was assessed by echocardiography: the average ejection fraction was $31.4 \pm 4.0\%$; the average left ventricle EDV - 223.8 ± 54.8 ml. The EuroSCORE perioperative risk of death was 5.7 ± 2.2 , which corresponds to the expected death rate of $7.9 \pm 4.5\%$. The average number of bypassed vessels was 2.48 ± 0.67 , 13 (14.6%) patients underwent endarterectomy from the coronary arteries due to their diffuse lesion.

Results: in early postoperative period died 3 patients (3.3%). The ejection fraction and the end diastolic volume of the left ventricle after surgery were $34.3 \pm 6.6\%$ and 168.5 ± 45.1 ml respectively. All patients in early postoperative period faced heart failure treated by inotrope infusion. In 45 (%) cases the rhythm disturbances and in 2 patients (2.2%) - cerebral circulation disorders were observed. During 30 day observation a significant increase in the cardiac index was noted (1.64 ± 0.29 l / m² / min before the intervention against 2.48 ± 0.55 l / m² / min).

Conclusions: off pump coronary artery bypass in patients with chronic ischemic heart disease complicated by left ventricular failure is an effective technique, with satisfactory mortality and morbidity in early postoperative period.

ID: 219

Topic: **Cardiovascular Surgery » Coronary Bypass Surgery**

Presentation Type: **Poster**

IS CORONARY ARTERY BYPASS GRAFTING DIFFICULT IN A PATIENT WITH DEXTROCARDIA AND SITUS INVERSUS?

Atilla Orhan¹, **Ufuk Özergin**²

¹*Selcuk University, Konya, Turkey*

²*Konya Farabi Hospital, Konya, Turkey*

**Corresponding Author (atillaorhan@gmail.com)*

atillaorhan@gmail.com, ufukozergin@gmail.com

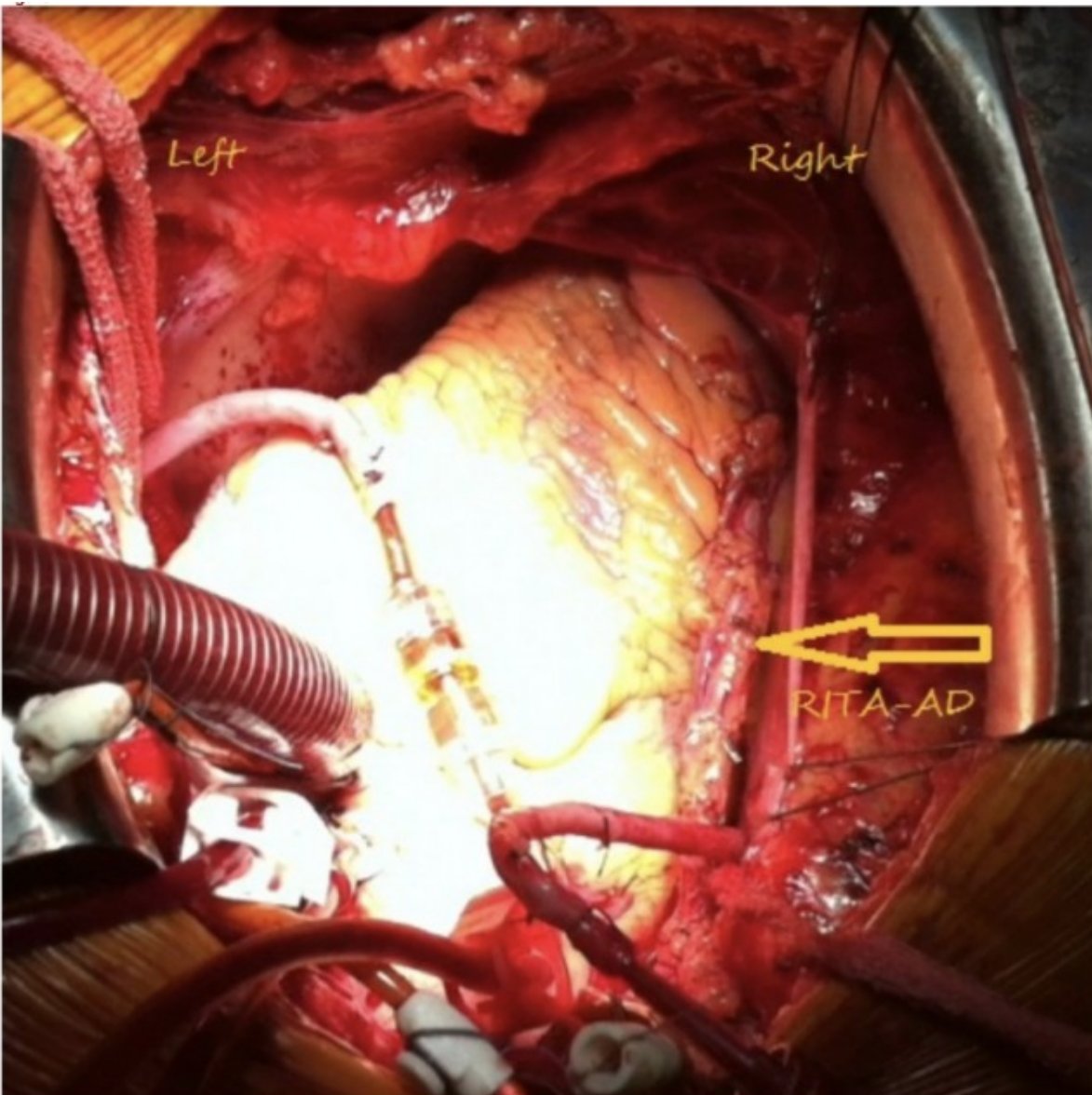
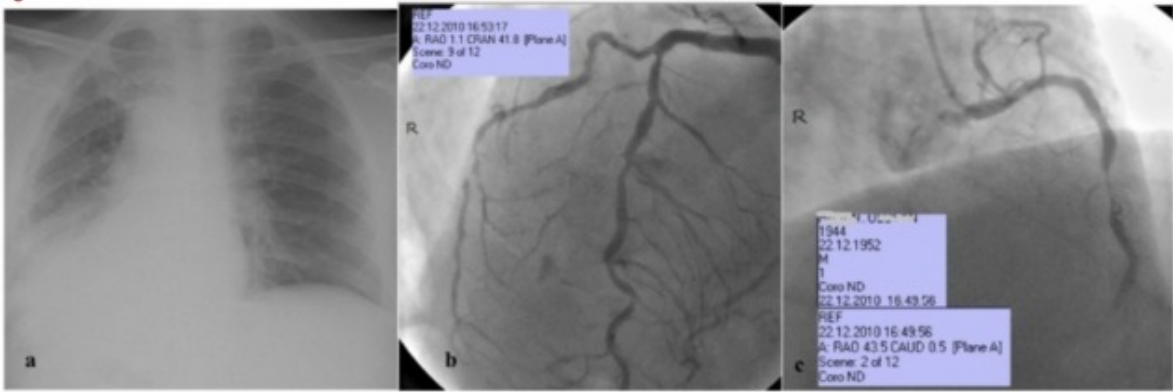Abstract Text

INTRODUCTION: Coronary artery bypass surgery (CABG) in dextrocardia with situs inversus (DSI) is a rare condition. In DSI, it is necessary to confront some difficulties in surgical management due to the reversed arrangement of the structures during surgery. We describe a patient who underwent CABG and has DSI.

CASE: A 58-year-old male patient with DSI admitted with stable angina requiring CABG (Figures 1a, 1b, and 1c). Preoperative work was made. In the operation, the first surgeon harvested the right internal thoracic artery (RITA) standing on the left side of the patient. The great saphenous vein (GSV) was also harvested simultaneously by the second surgeon. The first surgeon performed the other procedures of the operation on the right side of the patient. The vein grafts were anastomosed to the posterior descending, obtuse marginal, and diagonal coronary arteries, respectively. Finally, the RITA to LAD anastomosis was performed (Figure 2). After the operation, the chest was closed routinely. There were no postoperative complications. The patient was discharged on the 6th postoperative day.

CONCLUSION: Patients with DSI had no unusual difficulty in CABG procedure except for the mirrored anatomy. The surgeons performed all of the procedures, except the RITA harvest, while standing on the usual side of the patient and faced no difficulties.

Keywords: coronary artery bypass, dextrocardia, situs inversus, CABG



ID: 223

Topic: **Cardiovascular Surgery » Coronary Bypass Surgery**Presentation Type: **Poster****ISOLATED SPONTANEOUS TRUE BRACHIAL ARTERY ANEURYSM****Atilla Orhan¹, Ufuk Özergin²**¹*Selcuk University, Faculty of Medicine, Konya, Turkey*²*Konya Farabi Hospital, Konya, Turkey***Corresponding Author (atillaorhan@gmail.com)**atillaorhan@gmail.com, ufukozergin@gmail.com***Abstract Text****Introduction:**

True brachial artery aneurysms (BAA) are rare peripheral aneurysms. Usually, trauma or infection lies in the etiology. We present an isolated BAA without any etiological reasons.

Case:

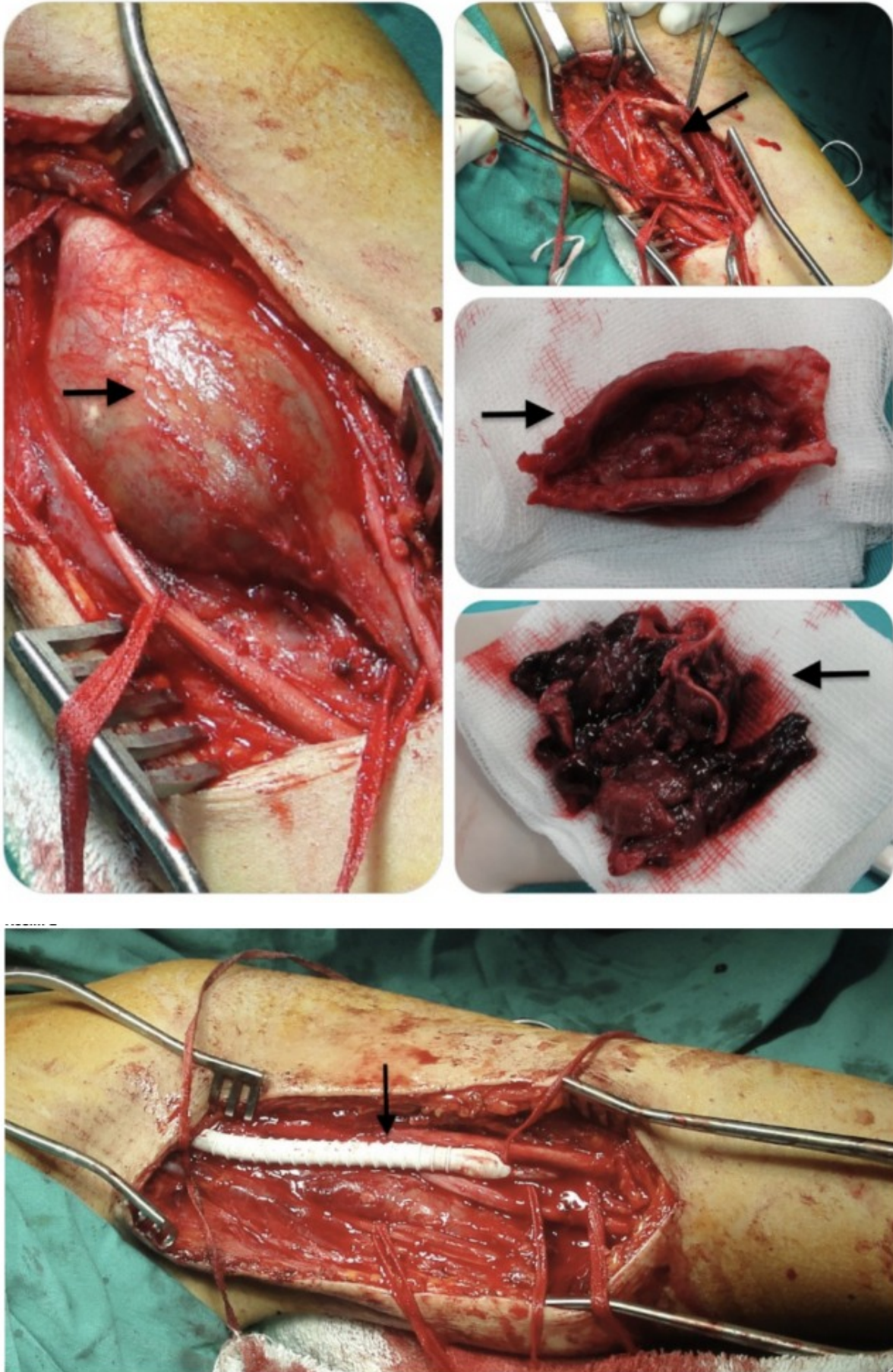
A 30-year-old woman presented with pain, swelling, and pulsatile mass in the left arm. There was no history of trauma, infection, or vasculitis. Physical examination revealed a 35 mm diameter, fusiform shaped pulsatile mass in the left brachial artery. There were left-arm pulses in the distal mass. Duplex Ultrasonography confirmed a 35x60 mm fusiform aneurysm with internal thrombosis.

In operation, an isolated aneurysm originating from the left brachial artery was explored (Figure 1). The aneurysm was resected, then the ringed ePTFE graft was interposed (Figure 2).

After revascularization, distal pulses were palpated. There was no problem in the postoperative 6 months follow-up.

Discussion:

True BAAs are rare conditions. Trauma, infection, endocarditis, intravenous drug use, and vasculitis lie in the etiology. In contrast to other peripheral aneurysms, trauma is predominant in the etiology of BAA rather than atherosclerosis. However, no etiological factor was found in our case. BAAs should be treated surgically because of the high risk of complications such as limb ischemia and embolism. Treatment options include surgical resection and revascularization. Although endovascular interventions can be applied in appropriate cases; The primary treatment modality in patients who have reached giant dimensions, which contains thrombus and compresses the structures such as nerves is surgery. Autogenous or non-autogenous grafts can be selected in revascularization. If there is no autogenous graft, ringed- ePTFE grafts should be chosen first to reduce the risk of kink.



ID: 187

Topic: **Cardiovascular Surgery » Coronary Bypass Surgery**Presentation Type: **Poster****FIVE YEAR EXPERIENCE OF OFF-PUMP SURGICAL
REVASCULARIZATION IN PATIENTS WITH MULTI-VESSEL
CORONARY DISEASE.****Oybek Mashrapov, Abdusalam Abdurahmanov***Republican Research Center of Emergency Medicine. Tashkent, Uzbekistan, Tashkent, Uzbekistan***Corresponding Author (docmashrap@yahoo.com)**docmashrap@yahoo.com, ab.abdurakhmanov@yandex.com***Abstract Text****INTRODUCTION**

Surgical revascularization in patients with multi-vessel coronary artery disease still raises many questions. The aim of the study was to analyze the single center results of off pump CABG in patients with multivessel coronary disease.

MATERIAL AND METHODS

This retrospective study analyzed 1020 patients with history of coronary artery disease who underwent off-pump CABG surgery in 2013-2018 years at the Republican Research Center for Emergency Medicine. The average age of the patients was $58,2 \pm 0,95$ years. Women were 309 (30.3%) and men - 711 (69.7%). Most patients (76.9%) had III Class NYHA, and 12.3% and 10.8% patients IV and II class respectively. 283 patients had concomitant diseases: diabetes mellitus and COPD. The majority of patients were diagnosed with unstable coronary artery disease (94.4 %); 5.6 % of patients underwent surgery based on emergency indications or with acute myocardial infarction.

RESULTS

The mean surgery duration was 210 ± 1.7 minutes. The mean amount of bypasses (bypass index) was $3,2 \pm 0,2$, in 840 (82,3%) cases LIMA was used as a preferred graft for LAD bypass, in 30 (3%) patients with concomitant carotid and coronary artery disease were performed simultaneous interventions. In 95 (9,3%) cases due to the haemodynamical instability we turned on-pump. Postoperative complications were observed in 112 (10,9%) patients. We lined out the prevalence of cardiac complications, such as heart failure and rhythm disturbances, observed in 87 (8,5%) and 53 (5,1%) patients respectively. Hospital mortality rate was 2.8% (29/1020). The cause of mortality in all cases was acute heart failure, due to the initial severity of the disease, and in 11 (1,07%) cases an acute myocardial infarction was diagnosed. The duration of stay of patients in the ICU after surgery was $2,4 \pm 0,5$. Duration of postoperative period was 7.8 ± 0.9 days. Operated patients improved exercise tolerance, all patients after surgery were in the second class of NYHA functional classification.

CONCLUSION

Off-pump Coronary artery bypass grafting can be safely performed with relatively low incidence of mortality and postoperative morbidity.

ID: 66

Topic: **Cardiovascular Surgery » Coronary Bypass Surgery**Presentation Type: **Poster****ANXIETY AND HEALTH-RELATED QUALITY OF LIFE AFTER CARDIAC SURGERY**Yalçın Guzelhan¹, Murat Ugurlucan², Didem Oztas², Ufuk Alpogut², Nilgün Bozbuga²¹*Istanbul Education and Research Hospital, İstanbul, Turkey*²*Istanbul University, İstanbul Faculty of Medicine, İstanbul, Turkey***Corresponding Author (didem_mls@hotmail.com)**didem_mls@hotmail.com, muratugurlucan@yahoo.com, didem_mls@hotmail.com, didem_mls@hotmail.com, didem_mls@hotmail.com***Abstract Text**

Objective: The aim of this study was to investigate the effect of elective cardiac surgery on health-related quality of life (HRQoL).

Materials and Methods: One hundred and eight (35 women and 73 men, mean age 62.3 ± 12.7 years) patients undergoing open heart surgery (69 pts coronary artery bypass grafting, 9 pts coronary artery bypass grafting plus valve replacement, 30 pts isolated valve replacement) enrolled in the study. Physical and mental domains of quality of life were measured using 36-item Medical Outcomes Short-Form Health Survey (SF-36) self-administered questionnaire and anxiety symptoms were assessed using the Spielberger State-Trait Anxiety Inventory (STAI). At baseline 108 patients filled out the SF-36 and STAI, 102 patients (94.4% of the series) at 6-month follow-up.

Results: It was found that significant improvement in three out of eight health domains: physical functioning ($p < 0.02$), role physical ($p < 0.01$), and social functioning ($p < 0.04$) at 6-month follow-up. The two STAI sub-scores, the State Anxiety Inventory and the Trait Anxiety Inventory were found high (≥ 40) both preoperatively and 6 months after postoperatively. Postoperatively there was not any statistically significant decreasing of the levels of anxiety.

Conclusion: This study suggests that the assessment of psychosocial factors, particularly the ongoing assessment of anxiety, could help in risk stratification and prediction of functional status and HRQoL patients after cardiovascular surgery. Furthermore the assessment of preoperative well-being should be integrated in routine care in order to identify and support patients with higher levels of anxiety.

ID: 77

Topic: **Cardiovascular Surgery » Coronary Bypass Surgery**Presentation Type: **Poster****STERNAL FORAMEN IN A PATIENT UNDERGOING EMERGENCY
REVASCULARIZATION****Elif Coşkun, Anıl Tekin, Ufuk Tütün, Levent Altınay***Bülent Ecevit Üniversitesi Tıp Fakültesi, Zonguldak, Turkey***Corresponding Author (drelfco@gmail.com)**drelfco@gmail.com, aniltekin@hotmail.com, ufuktutun@yahoo.com, laltinay@gmail.com***Abstract Text**

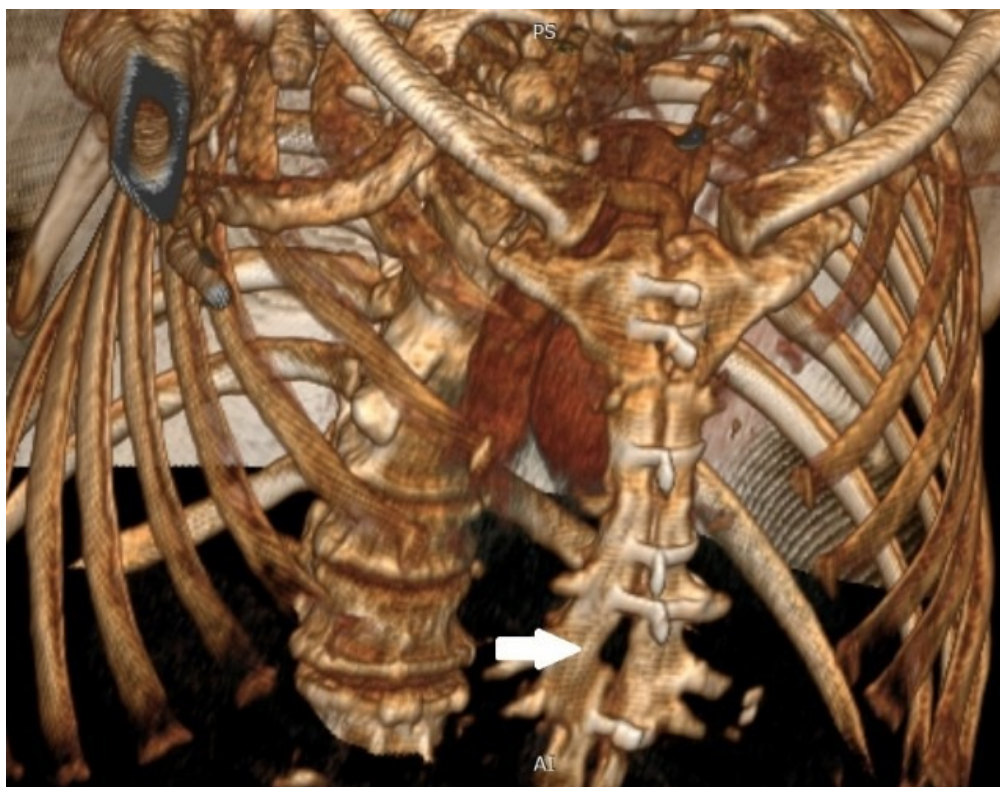
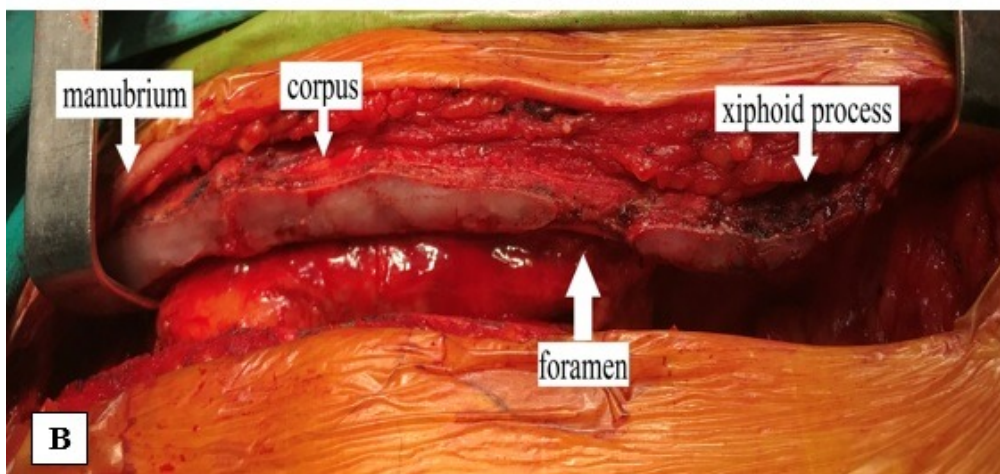
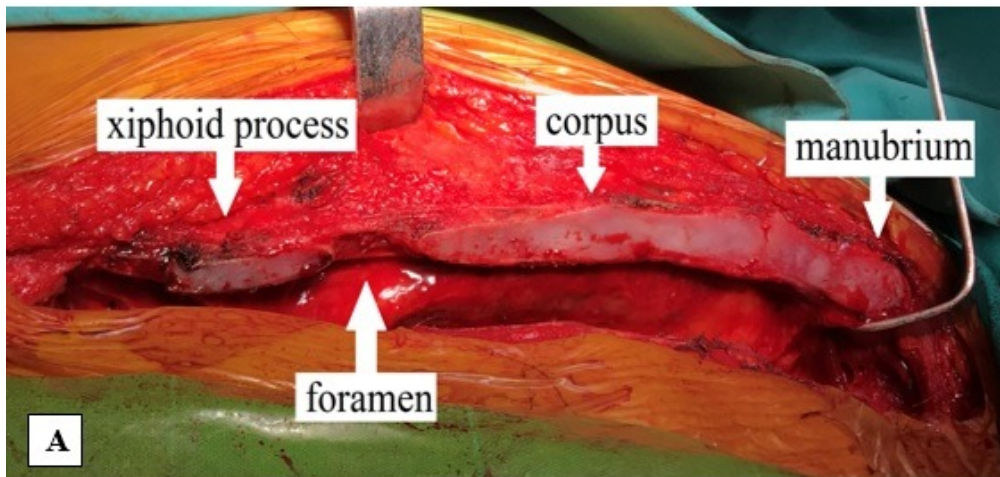
Introduction: The sternal foramen is an anatomical variation at the lower third of the sternum which carries the risk of life-threatening complications such as pneumothorax. It is usually asymptomatic and can be misinterpreted as acquired lesions. Sternum is close to the mediastinal structures, which leaves the lung, heart, and great vessels unprotected during invasive procedures.

Methods: A 61-year-old male patient was admitted to our emergency department with sudden-onset chest pain. The patient previously underwent urgent revascularization for acute coronary syndrome 3 months ago in our facility. Following median sternotomy, intraoperative sternal foramen was detected.

Results: During the exploration, no cortical integrity in the fourth and fifth intercostal spaces in the corpus region which is close to the xiphoid process was recognized. The sternal cortex terminated with smooth margins. Two sternal images were obtained due to sagittal and median incisions (Figure-1A and 1B). Using an appropriate imaging modality, surgery was continued. Five-vessel CABG was performed and the patient was intubated and transferred to the intensive care unit under the intra-aortic balloon pump and inotropic support. He was taken to the ward on postoperative Day 3 and discharged uneventfully on postoperative Day 7. Sternal foramen was detected with postoperative computed tomography (CT) in first month (Figure-2).

Conclusions: To the best of our knowledge, this is the first case of sternotomy who underwent open heart surgery for coronary heart disease and was diagnosed intraoperatively. It is of vital importance that surgeons and interventionists should recognize sternal foramen, which leaves the mediastinal structures unprotected and early precautions should be taken.

Keywords: Sternal foramen, anomaly, median sternotomy, revascularization.



ID: 53

Topic: **Cardiovascular Surgery » Coronary Bypass Surgery**Presentation Type: **Poster****OFF-PUMP CORONARY ARTERY BYPASS GRAFTING IN PATIENTS WITH LEFT VENTRICULAR DYSFUNCTION****Abdusalom Abdurakhmanov, Mustafa Obeid, Ilkhom Abdukhalimov***Republican Research Center of Emergency Medicine, tashkent, Uzbekistan***Corresponding Author (ababdurakhman@gmail.com)**ababdurakhman@gmail.com, ababdurakhman@gmail.com, ababdurakhman@gmail.com***Abstract Text****Objective:**

Coronary artery bypass grafting in patients with reduced left ventricular contractility associated with worse early outcome, high level of morbidity and mortality. The aim of this cohort study is evaluation of the immediate results of surgical treatment of patients with chronic ischemic heart disease with reduced left ventricular function (ejection fraction less than 35% according to EchoCG data).

Materials and methods:

This cohort study included 89 patients with reduced left ventricular ejection fraction operated in our department during the period of December 2013 to January 2018. The mean age was 57.7 ± 6.8 years. All of those patients had congestive heart failure on admission (IV class NYHA) and at least one episode of myocardial infarction. Diabetes mellitus was diagnosed in 31 patients (34.8%), and obstructive pulmonary disease – in 12 (13.5%). The 35 patients (39.3%) had symptoms of angina of high functional class III and IV, and 49 (55.1%) and 5 (5.6%) respectively were operated with unstable angina or ongoing myocardial infarction. The function of the left ventricle was assessed by echocardiography: the average ejection fraction was $31.4 \pm 4.0\%$; the average left ventricle EDV - 223.8 ± 54.8 ml. The EuroSCORE perioperative risk of death was 5.7 ± 2.2 , which corresponds to the expected death rate of $7.9 \pm 4.5\%$. The average number of bypassed vessels was 2.48 ± 0.67 , 13 (14.6%) patients underwent endarterectomy from the coronary arteries due to their diffuse lesion.

Results:

In early postoperative period died 3 patients (3.3%). The ejection fraction and the end diastolic volume of the left ventricle after surgery were $34.3 \pm 6.6\%$ and 168.5 ± 45.1 ml respectively. All patients in early postoperative period faced heart failure treated by inotrope infusion. In 45 (%) cases the rhythm disturbances and in 2 patients (2.2%) - cerebral circulation disorders were observed. During 30 day observation a significant increase in the cardiac index was noted (1.64 ± 0.29 l / m² / min before the intervention against 2.48 ± 0.55 l / m² / min).

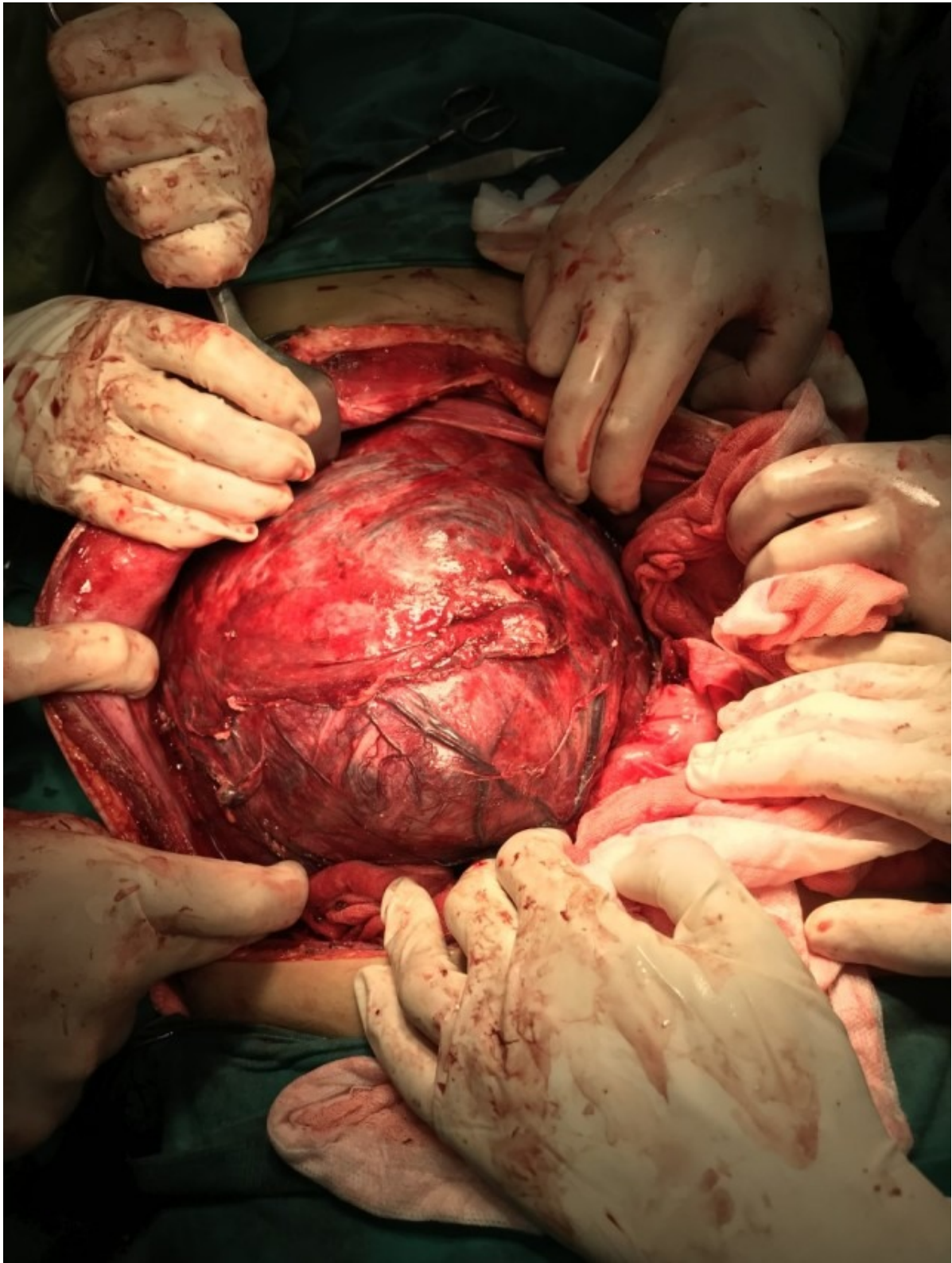
Conclusions:

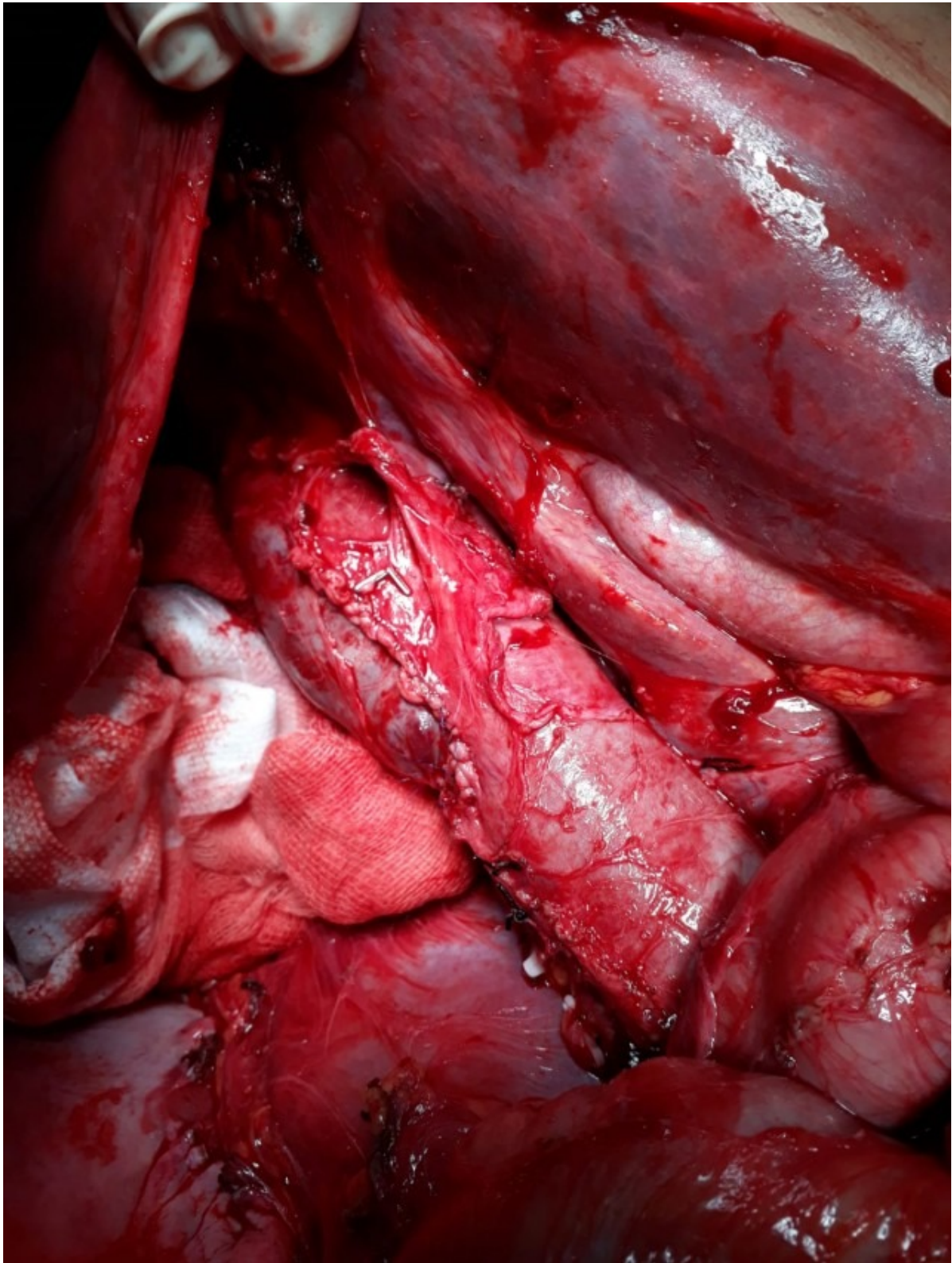
Off pump coronary artery bypass in patients with chronic ischemic heart disease complicated by left ventricular failure is an effective technique, with satisfactory mortality and morbidity in early postoperative period.

ID: 121

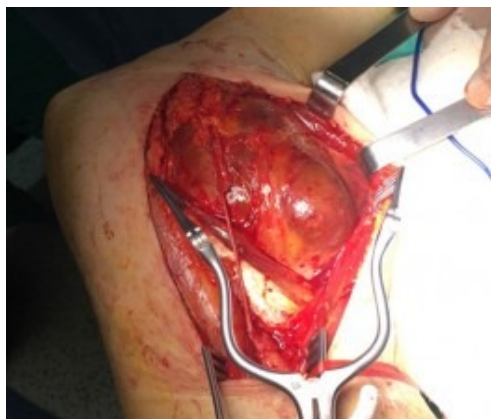Topic: **Cardiovascular Surgery » Peripheral Arterial Disease**Presentation Type: **Poster****REPAIR OF VENA CAVA INFERIOR DURING EXCISION OF THE INTRA-ABDOMINAL GIANT GANGLIONEUROBLASTOMA****Mustafa Karacelik**, Timuçin Kvc Sabuncu, Kamer Polatdemir, Kubra Evren Sahin, Aylin Goktay, Akgun Oral*SBU. Izmir Dr. Behcet Uz Children's Hospital, Izmir, Turkey***Corresponding Author (mkaracelik@hotmail.com)**mkaracelik@hotmail.com, timucin_sabuncu@yahoo.com, kamervarol@gmail.com, kubraevren@yahoo.com, goktaylin@hotmail.com, ak_oral@hotmail.com***Abstract Text**

A 16-year-old girl presented to our emergency department with sudden onset, non-localized abdominal pain and high fever with no complaints before. A mass (24 x 16 cm), which was thought to originate from the right adrenal gland, was detected in the right upper quadrant of the abdomen at the examination of ultrasonography and computerized tomography. Vena cava inferior (VCI) observed to be pushed medially by the mass. At joint surgery with pediatric surgery clinic, after median laparotomy, the tumor was seen completely filling the right upper quadrant and detected too compact structure. The tumor was dissected from the liver and VCI cautiously. During the repair, VCI has been repaired with digital compression without blocking the VCI. VCI flow relieved under pressure by separation of the tumor from VCI and it has come to normal dimensions diagonally. Postoperative period was uneventful. The patient was transferred to the oncology service for chemotherapy on the 5th day. A nodular type of ganglioneuroblastoma was detected in the pathology. Metastasis screening was negative by PET CT. Postoperative control abdominal CT was performed; a mass (52 x 34 mm) allowing partial flow was detected in the lumen of VCI at the level of a hepatic segment of the VCI. No distinction could be made in favor of tumor or thrombus. Subcutaneous low molecular weight heparin treatment was started. Surgical intervention for this tumor was not considered. Patient's ongoing chemotherapy was discharged with surgical recovery. The multidisciplinary approach to VCI invasion of this type of tumor can be done successfully





ID: 349

Topic: **Cardiovascular Surgery » Peripheral Artery Disease and Treatment**Presentation Type: **Poster****RUPTURED GIANT POPLITEAL ARTERY ANEURYSM AND ASCENDING AORTA ANEURYSM IN ELDER FEMALE PATIENT**Erdal Simsek, Muhammed Sefa Saglam, **Emre Külahaçioğlu**, Serhat Aydaş, Muhammed Selim Yaşar, Soner Yavaş*University of Health Sciences, Turkiye Yuksek Ihtisas Training and Research Hospital, Ankara, Turkey***Corresponding Author (erdaldr@yahoo.com)**erdaldr@yahoo.com, sefasaglam@gmail.com, emrekulahcioglu@gmail.com, serhataydas@hotmail.com, erdaldr@yahoo.com, drsoneryavas@gmail.com***Abstract Text**

Background: Popliteal artery aneurysms, even though the most common peripheral arterial aneurysm in the vascular system, rarely seen greater than 5 cm in diameter in the clinical setting. It has usually seen in male patients Conventional open surgical treatment is challenging due to the complex anatomy of the popliteal region and high complications ratio.

Case Report: Here, we present a case of an 84-year-old female patient, admitted with compression findings including the excruciating pain, difficulty in walking, having left popliteal arterial aneurysms 14x10 cm in size(Tomographic angiography), with the history of ascending aorta aneurysm without any prior smoking history. Because of venous compression caused by the aneurysm, infrapopliteal subcutaneous edema was notable (+++). Aneurysm was exposed and freed via a left medial popliteal incision in hunter canal (Figure 1). Popliteal artery was excised distally to an aneurysm whereas superficial femoral artery excised proximally. In the posterior segment of the pouch, a ruptured segment, approximately 2 cm in diameter. 8 mm ringed PTFE (politetrafluoroetilen) graft was interposed between the distal superficial femoral artery and superior popliteal artery via end to end anastomosis. Degenerated part of the popliteal vein secondary to mechanical compression resected and saphenous graft anastomosed via end to end fashion.

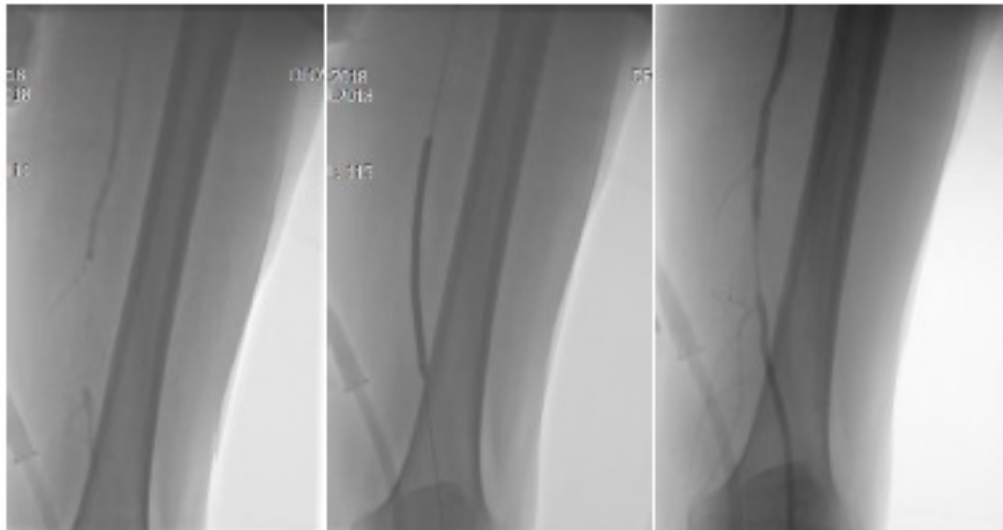
In the follow-up period, the anterior tibial artery and the posterior tibial artery was palpable. The patient was discharged safely with no further complaints on the third postoperative day.

Conclusion: Giant popliteal artery aneurysm is a rare entity with a minimal number of cases published so far. Compression issues and patient's characteristics should be meticulously considered in the treatment decision. The open surgical approach seems to comprise a reliable and adequate therapeutic strategy in patients ineligible for endovascular approach. Our case seems to be unique where giant ruptured aneurysm treated via open surgery in the patient with concomitant ascending aorta aneurysm.

ID: 406

Topic: Cardiovascular Surgery » Peripheral Artery Disease and Treatment**Presentation Type: Poster****THE DRUG-COATED BALLOON DOES NOT INFLATE IN THE ENDOVASCULAR PROCEDURE! WHAT IS THE PROBLEM? CATHETER, INDEFLATOR OR SOMETHING ELSE?****Osman Yaşar Işıkli, Hayati Taştan, Hakkı Kürşat Çetin***Karaman State Hospital, Karaman, Turkey***Corresponding Author (drosmay@gmail.com)**drosmay@gmail.com, hayatitastan@hotmail.com, dr.h.kursatcetin@hotmail.com***Abstract Text**

We wanted to present a patient who underwent endovascular treatment with TASC (The Trans-Atlantic Inter-Society Consensus Document on Management of Peripheral Arterial Disease) II Type A lesion. 73 years old male patient. He describes pain in the left leg by walking 50 meters. He's been smoking 1 pack a day for 30 years. After the local anesthesia, we performed intervention with seldinger technique from the right iliofemoral region. Using a 0.35inc x260 cm hydrophilic wire (Poseidon Brand), crossed the left common iliac artery of the aortic bifurcation level with the help of the internal mamary artery (IMA) catheter. Angiographic image was taken from left common and external iliac level. Left SFA(Süperficial Femoral Artery) was 100% obstructed from the 1/3 distal to the 8 cm popliteal artery of the Hunter channel. 7F X 65 cm long sheath(Terumo) was inserted from the right iliofemoral area. The lesion was passed using a 0.35x 135 cm (Rubicon) total occlusion transition catheter and 0.35 minx260 cm hydrophilic wire (Poseidon). Angiographic imaging was performed on the lumen of the left popliteal artery. 100% total occlusal region was dilated with 5x120 mm Perkütan transluminal anjioplasti (PTA) (Armada 35) for predilatation. DSA(Dijital Subtraksiyon Anjiyografi) image was taken from long sheatin lumen. 70-80% of the lesions were opened. Then, 6x150 mm drug-coated PTA (Luminor 35) was sent to the left SFA. Catheter Balloon is not inflated. We thought the catheter was wrong. We pulled the catheter back. But since the balloon was swollen outside, we thought the problem was the indeflator. We sent the balloon using the new indeflator. We inflated catheter by forced. Check DSA image received. The patient had no pain. Distal pulses were taken with doppler. We thought the catheter sheath was sent before he was taken. We immediately transferred the patient to the operating room. We performed a left inguinal incision with local anesthesia. We suspended the common femoral artery, superficial femoral artery, and deep femoral artery. We performed endarterectomy in SFA. First we performed distal embolectomy with fogarty catheter number 4. The catheter was not separated in the last 10 cm. We've expanded arteriotomy. With vascular clamp, we pulled out the foreign material (sheath). We're moving too fast when we send the drug-coated balloon. we touch only the tip of the drug-coated balloon. We may not recognize the transparent balloon sheath. We rely on assistants who prepare the catheters. Nevertheless, we must check and question the sheath.



PICTURE 1 :DSA

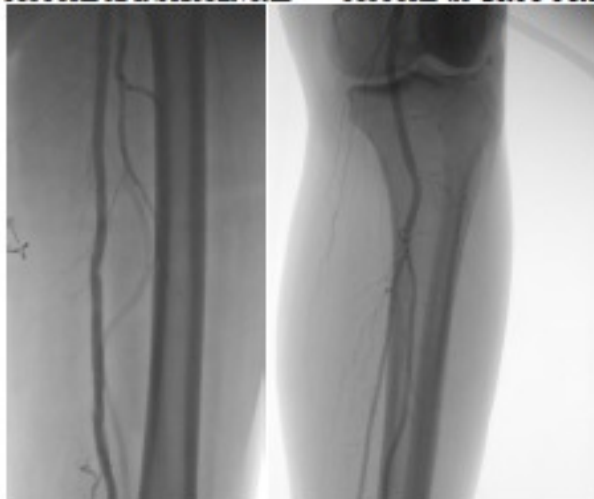PICTURE2 :PREDILATATION

PICTURE3A: AFTER DRUG COATED PTA



PICTURE 3B INFRAGENUAL

PICTURE 4A DRUG COATED PTA PROTECTIVE CASE 4B



PICTURE 5A/B AFTER THE OPERATION

ID: 225

Topic: **Cardiovascular Surgery » Peripheral Artery Disease and Treatment**Presentation Type: **Poster****A MORTAL COMPLICATION OF ARTERIOVENOUS HEMODIALYSIS
ACCESS: ACUTE HEMORRHAGE**Gökhan Arslan, **Hüseyin Sicim**, Hakan Kartal, Celalettin Günay, Bilgehan Savaş Öz*Gulhane Training and Research Hospital, Ankara, Turkey***Corresponding Author (drgokhanarslan@gmail.com)**drgokhanarslan@gmail.com, huseyinsicim@yahoo.com.tr, hakhankartal@gmail.com,
celalettin.gunay@sbu.edu.tr, bilgehansavas.oz@sbu.edu.tr***Abstract Text****INTRODUCTION:**

Acute hemorrhage through arteriovenous hemodialysis access can be a life threatening problem. Bleeding through arteriovenous fistula can be from aneurysms, stenosis and subsequent rupture, infection, trauma, suicide and, use of anticoagulants and antiplatelet drugs. We describe a 40-year-old male with an approximately 5 gm/dL drop in hemoglobin due to sudden bleeding from a ruptured prosthetic dialysis arteriovenous grafts in his left brachio basilic arteriovenous fistula.

CASE REPORT:

A 40-year-old man with a past medical history end-stage renal disease on hemodialysis (three days a week) through a left arm brachio basilic synthetic graft AV fistula (AVF) created approximately ten days ago presented to the emergency room (ER) with bleeding from his AVF. The patient's arterial blood pressure was 60/40 mmHg, heart rate was 130 / min Pulses were filiform and consciousness was confused. Initial labs were remarkable for Hgb 5 g/dL and Hct of 16.2%. Tourniquet on arm was strengthened, The patient was transfused 3 units of packed red blood cell and also crystalloid fluid. He was taken immediately into surgery. When the tourniquet was opened, it was observed that there was active bleeding from the synthetic graft anastomosis. Bleeding control was accomplished with vascular clamps. (Figure 1) The infected graft and tissues were completely removed. The fistula was ligated. The operation was terminated with any complications. The patient was discharged with full recovery at the postoperative 6th day after completion of antibiotherapy and dressing.

DISCUSSION AND CONCLUSION:

Patients with end-stage renal disease may lose blood from the AV fistula due to a variety of reasons. Vascular access site infection is considered to be the most challenging complication as acute hemorrhage and the major cause of morbidity and mortality among chronic hemodialysis patients. If evaluated to be at risk for rupture of fistula, a workup for associated access infection and surgical treatment should be considered and also patients should be taught simple techniques like putting direct pressure and tourniquet to minimize bleeding.

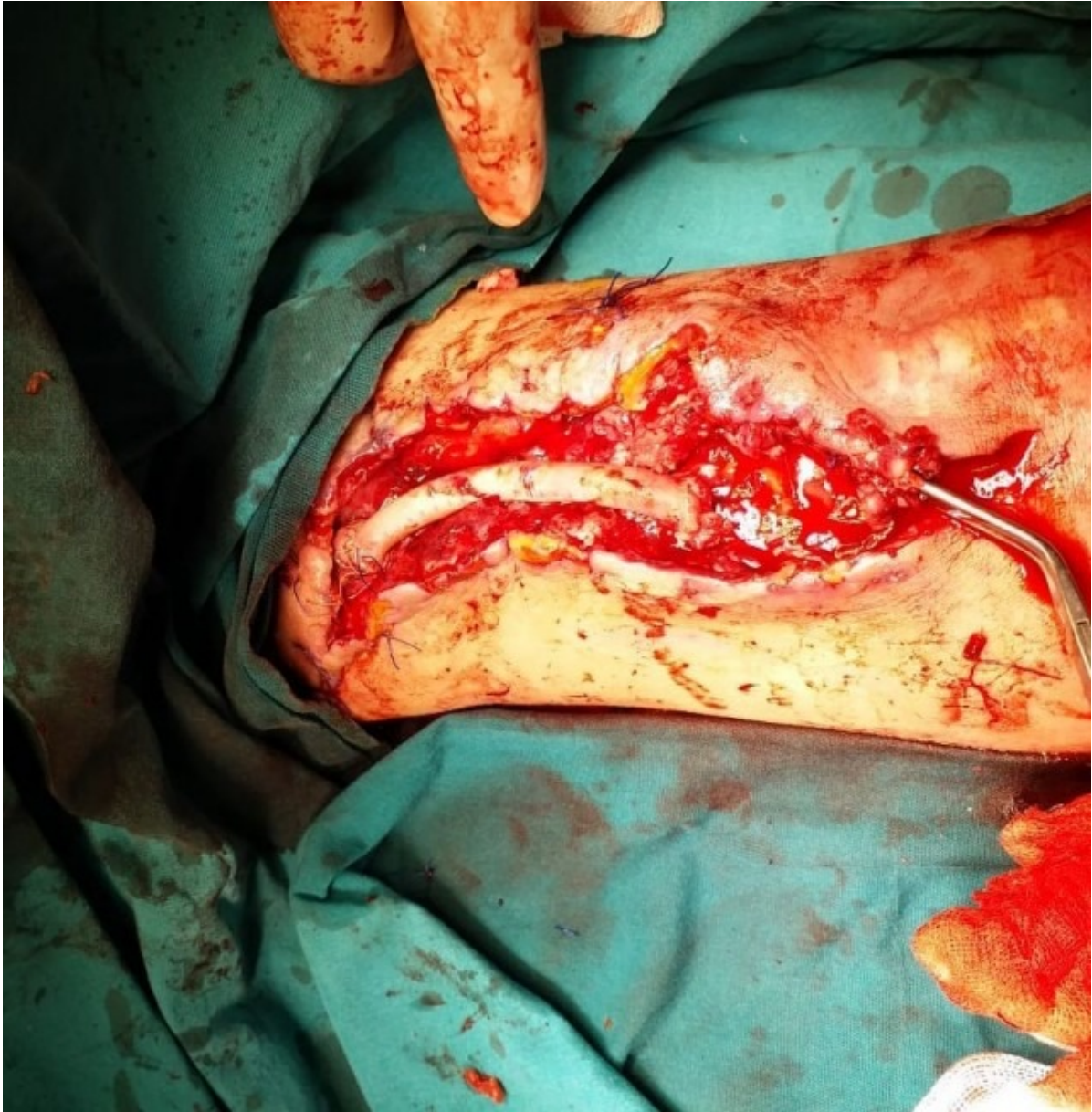


Figure 1. Ruptured brachio-basilic av fistula synthetic graft

ID: 229

Topic: **Cardiovascular Surgery » Peripheral Artery Disease and Treatment**Presentation Type: **Poster****TREATMENT OF GIANT FEMORAL ARTERY PSEUDOANEURYSM WITH THE HELP OF BALLOON CATHETER**Gökhan Arslan, **Hüseyin Sicim**, Hakan Kartal, Celalettin Günay, Bilgehane Savaş Öz*Gulhane Training and Research Hospital, Ankara, Turkey***Corresponding Author (drgokhanarslan@gmail.com)**drgokhanarslan@gmail.com, huseyinsicim@yahoo.com.tr, hakhankartal@gmail.com, celalettin.gunat@sbu.edu.tr, bilgehansavas.oz@sbu.edu.tr***Abstract Text****INTRODUCTION:**

Femoral pseudoaneurysms may develop secondary to iatrogenic injuries such as penetrating traumatic injury, mycotic degeneration, or transfemoral catheterization. Although the treatment approach varies according to the developmental pathway and the size of the aneurysm, surgical treatment comes to the fore. As the size of the pseudoaneurysm increases, the intervention becomes more risky. We have presented a case of a giant femoral pseudoaneurysm which used the Fogarty catheter to prevent serious complications during surgical intervention.

CASE REPORT:

A 69-year-old male patient presented to the emergency department with sudden swelling, pain, and bruising in the right groin. The patient had right femoropopliteal bypass 6 months ago. Physical examination revealed a pulsatile, ecchymotic mass with a diameter of 10x10 cm in the right inguinal region, a bad smelling discharge in the wound, and the right distal pulses nonpalpable. Doppler ultrasound showed that the patient had a synthetic graft with an occluded and a pseudoaneurysm of approximately 10x8 cm in the right inguinal region. The patient was immediately taken into operation. The former popliteal incision scar was opened firstly and plenty of hematoma was evacuated. A small incision was made in infected graft and the 7F fogarty catheter was advanced into the common femoral artery. (Figure 1) Pulsatile flow in the CFA with Doppler usg was observed. Considering that the catheter reached enough proximally, the catheter was inflated and the pulsatile flow with doppler usg was observed. While occlusion, an incision line was opened in the inguinal region and large thrombus was evacuated. It was observed that the proximal anastomosis line was separated secondary to infection. The infected graft was completely removed. Femoropopliteal bypass operation was performed with saphenous vein graft. Parenteral antibiotherapy was started after the operation. On the 18 th postoperative day, the patient was discharged with clean incisions and palpable distal pulses with healing.

DISCUSSION AND CONCLUSION:

Femoral artery pseudoaneurysm is a complication which is usually observed after invasive procedures. Treatment planning varies according to the size of the pseudoaneurysm. However, as mentioned in this case report, surgical treatment comes to the fore in the approach to giant pseudoaneurysms. The most important issue in the surgical approach is to take measures for bleeding control. As we mentioned in this case report, the use of fogarty catheter during the intervention of a risky giant pseudoaneurysm case helps to minimize all the risks that may cause morbidity and mortality by cutting the proximal flow.

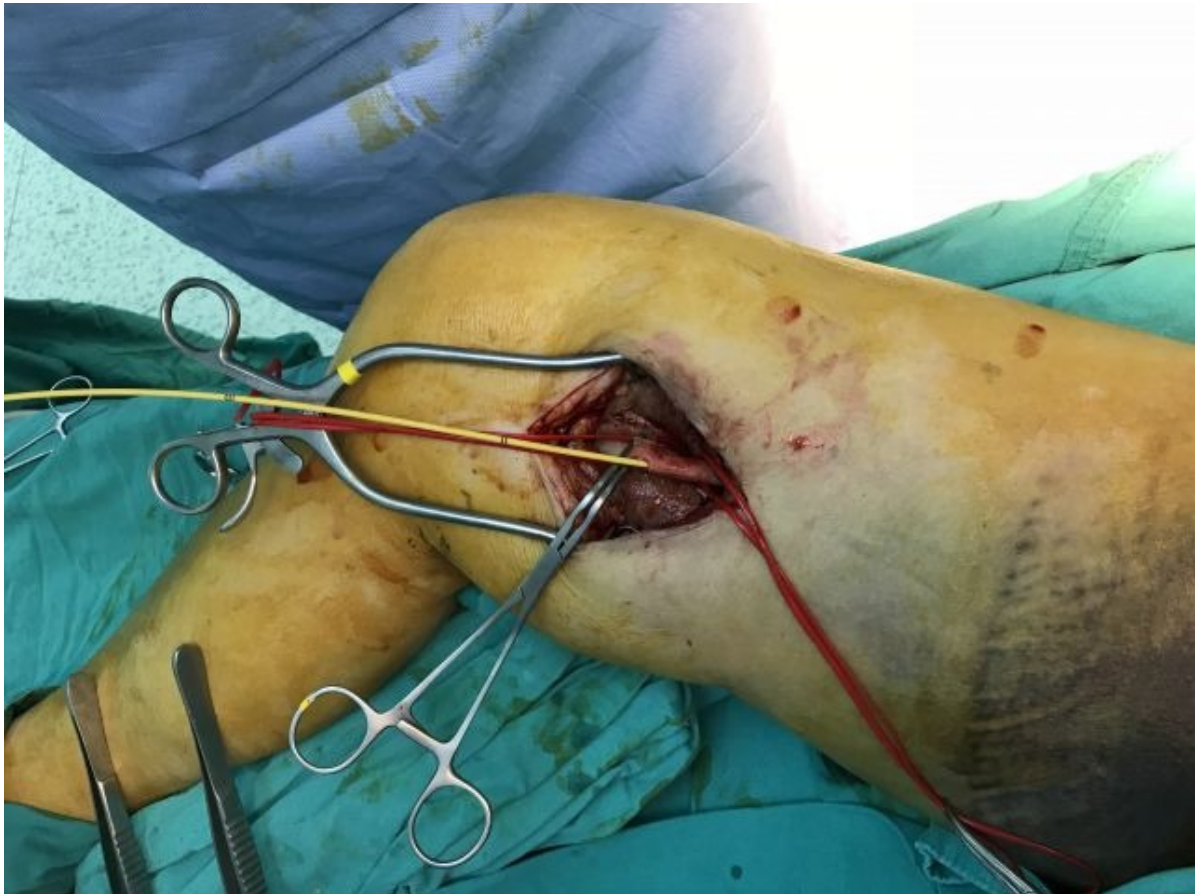


Figure 1. Balloon catheter inserted through synthetic graft

ID: 241

Topic: **Cardiovascular Surgery » Peripheral Artery Disease and Treatment**Presentation Type: **Poster****SURGICAL CLOSURE OF MULTICENTRIC TRAUMATIC ARTERIOVENOUS FISTULA BY INTRAOPERATIVE DSA CONTROL**

Gökhan Erol, Hüseyin Sicim, Emre Kubat, Murat Kadan, Kubilay Karabacak, Suat Doğancı, Cengiz Bolcal

*Gulhane Training and Research Hospital, Ankara, Turkey***Corresponding Author (drgokhanerol@gmail.com)**drgokhanerol@gmail.com, huseyinsicim@yahoo.com.tr, ekubat@gmail.com, mrtkdn@gmail.com, kubilaykarabacak@yahoo.com, suat_doganci@yahoo.com, bolcalc@yahoo.com***Abstract Text****INTRODUCTION:**

Traumatic arteriovenous fistulas are usually caused by unrecognized or untreated minor vascular trauma. It has been reported that this condition is commonly associated with gunshot wounds. In addition, it is stated that it may occur after sharp blade injuries and blunt injuries. Treatment decision in arteriovenous fistula depends on the size of the fistula and the ability to affect the cardiovascular system. In surgical approaches, surgical intervention is mandatory in cases where percutaneous fistula closure methods are not appropriate. In this case report, we presented the surgical closure of multicentric arteriovenous fistulas developed in the posterior tibial artery by performing intraoperative DSA control.

CASE REPORT:

A 27-year-old male patient had a multi-injury on his body 4 years ago due to a hand-made explosive. Fasiatomies were opened due to fracture and crush injury in the right leg region. There is no other known disease history. The patient was admitted to our clinic because of trill sensation in the right leg region. Physical examination revealed fasciotomy scars under the right knee and trill was palpated in the same area. CT angiography was performed. Multicentric av fistula foci were detected in the tibialis posterior artery. Surgical fistula closure was planned with intraoperative DSA support. The patient was in the prone position, and the popliteal fossa was explored with a vertical incision. The tibialis posterior artery was found and the fistula connection was detected in the region. (Figure 1) Arterography was performed with intraoperative DSA. There was still an escape from a different focus to the venous system. Under the DSA, the fistula with the focus of the fistula was also found. There was no leakage after the control. The operation was terminated without complications. The patient was discharged from the hospital on the fifth postoperative day.

DISCUSSION AND CONCLUSION:

Planning of the approach to traumatic arteriovenous fistulas in small vessels is very important. Difficulty in diagnosis can become complex due to difficult localization and difficulty in surgical access. Although developing percutaneous methods are very easy to treat, surgical intervention may be necessary in inappropriate cases. The most important issue in the surgical approach is the correct detection of the fistula focus and the fact that there may be more than one focus. It should be kept in mind that in cases where surgical intervention will be performed, DSA intraoperative guidance can be used to determine the fistula location, the number of fistulas and the control of the ligation.

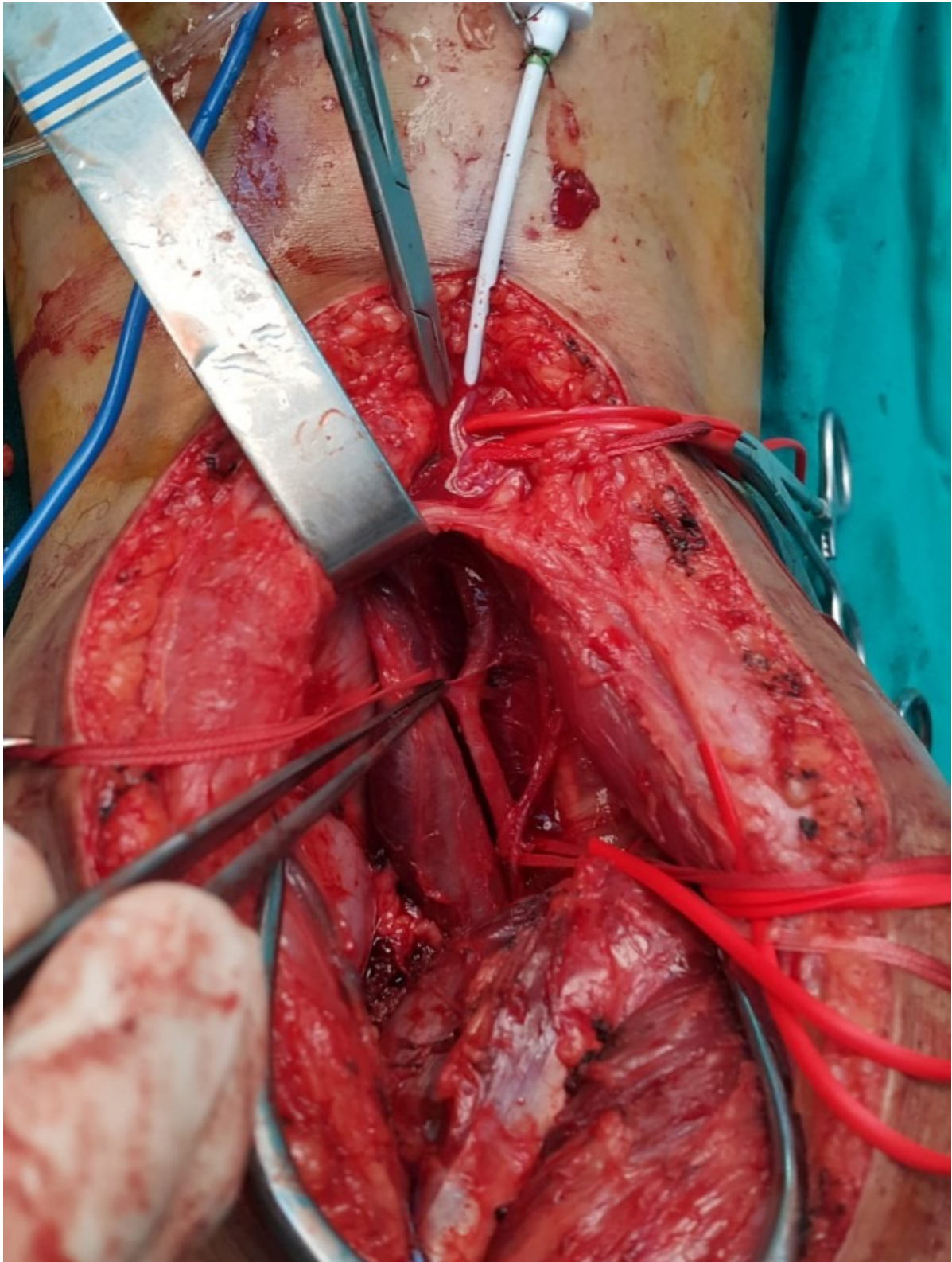


Figure 1. Fistula connection determined by DSA assistance

ID: 76

Topic: **Cardiovascular Surgery » Peripheral Artery Disease and Treatment**Presentation Type: **Poster****A VOLAR GANGLION CYST ON THE WRIST IMITATING THROMBOSED RADIAL ARTERY PSEUDOANEURYSM**

Elif Coşkun, Levent Altınay, Ufuk Tütün, Anıl Tekin

*Bülent Ecevit Üniversitesi Tıp Fakültesi, Zonguldak, Turkey***Corresponding Author (drelfco@gmail.com)**drelfco@gmail.com, laltinay@gmail.com, ufuktutun@yahoo.com, aniltekin@hotmail.com***Abstract Text**

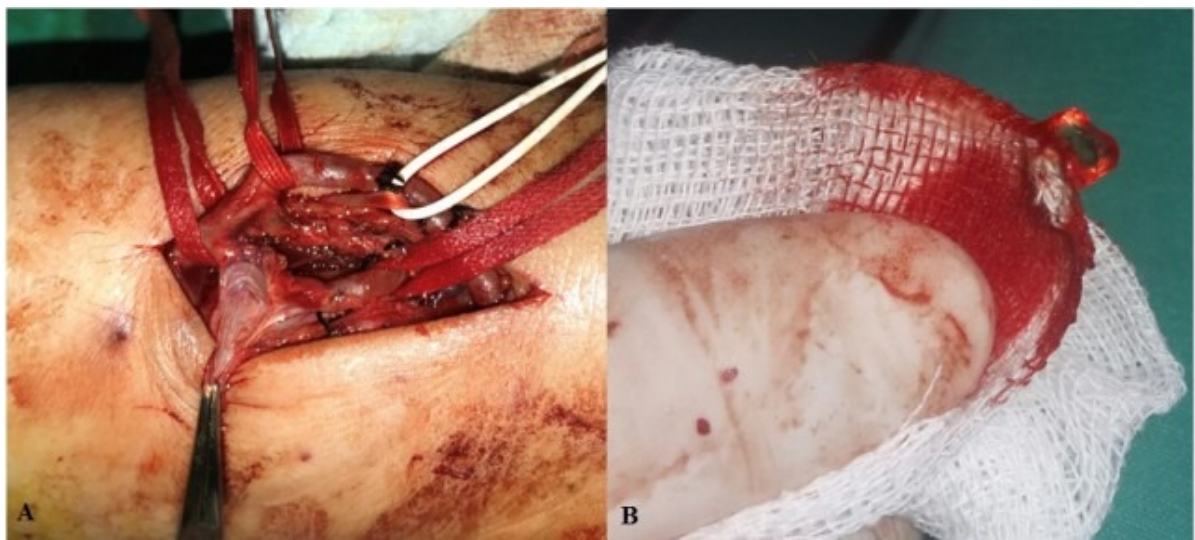
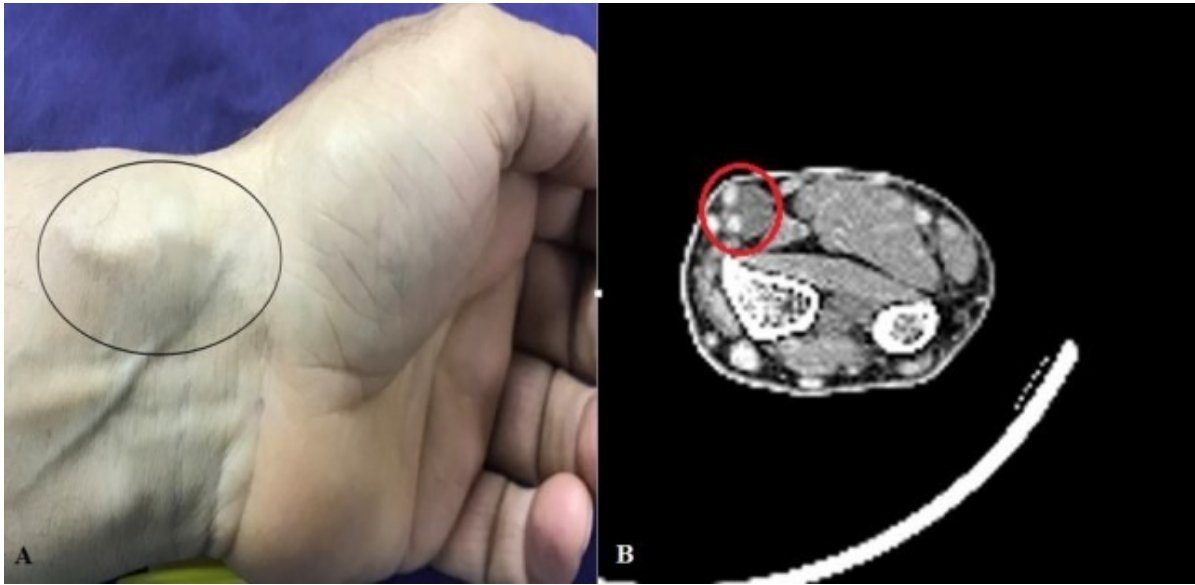
Introduction: Ganglion cysts are common soft tissue tumors. It can be challenging to differentiate a ganglion cyst from a pseudoaneurysm of the radial artery if the ganglion is located adjacent to the radial artery. In this report, we emphasize the importance of the complications after transradial arterial catheterizations and present our experience.

Methods: In his physical examination, there was a 2 x 2 cm swelling localized on his left wrist (Figure 1A). There was no difference in the skin temperature or color between the two upper extremities. The swelling was stiff and non-pulsatile. There was no motor deficit in his left hand. The Allen test of the left upper extremity was negative. In a recent upper extremity arterial Doppler ultrasonography, the swelling was suspected to be a 1.8 x 0.9 cm thrombosed saccular arterial aneurysm. In the computed tomographic angiography, a 3.5 x 0.9 cm thrombosed fusiform arterial pseudoaneurysm was observed adjacent to the radial artery bifurcation. (Figure 1B). Written informed consent was acquired. The patient was operated on under local anesthesia. The left radial artery was explored after performing an incision over the swelling. A capsule was observed inferior to the superficial palmar carpal branch of the radial artery (Figure 2A). A gelatinous and hyaloid material was drained from the capsule (Figure 2B). The drainage material and the capsule itself, which adhered to the artery, were excised and sent to the pathology laboratory in the preservation medium for histological evaluation. The operation was terminated after checking for any other possible vascular pathologies. A fibromyxoid degeneration in the arterial wall was reported after the histological examination. The patient was discharged after an uneventful postoperative period.

Results: A 57-year old male patient presented to the outpatient clinic with swelling in his left wrist causing pain and numbness in his fingers. The patient had undergone multiple cardiovascular angiographic interventions in the past. The first diagnosis was thrombosed radial artery pseudoaneurysm. The intraoperative diagnosis was the volar ganglion cyst.

Conclusion: The increasing rate of radial arterial catheterizations for percutaneous coronary interventions may lead to an increase in the rate of procedural vascular complications involving the radial artery. We think clinicians should know the diagnostic radiological techniques for these complications and recognize the other possible pathologies for the differential diagnosis.

Key words: Ganglion cyst, pseudoaneurysm, radial artery



ID: 547

Topic: **Cardiovascular Surgery » Risk Management in Cardiovascular Diseases**Presentation Type: **Poster****TRANSVERSUS ABDOMINIS PLANE BLOCK FOR POSTOPERATIVE PAIN AFTER ABDOMINAL AORTIC SURGERY****Incila Ali, Seray Türkmen, Nihan Altıntepe, Serkan Ketenciler, Mete Gürsoy, Nihan Kayalar***Okmeydanı Training and Research Hospital, Istanbul, Turkey***Corresponding Author (incilali@hotmail.com)**incilali@hotmail.com, drserayturkmen@yahoo.com.tr, nihanalntepe@gmail.com, ketencilers@hotmail.com, metegursoy35@gmail.com, nkayalar@hotmail.com***Abstract Text****Introduction:**

Transversus abdominis plane (TAP) block is a simple procedure that can be used as an adjunct for postoperative pain control in abdominal procedures such as gynecologic, urologic and rarely vascular surgery involving the T6 to L1 distribution. In this case we reported TAP block for acute severe postoperative pain in patients with aortobifemoral bypass.

Material and methods:

A 64 year old man underwent aortobifemoral bypass with midline laparotomy for Leriche's Syndrome. In Cardiovascular Intensive Care Unit (CV-ICU), the patient complained shortness of breath and severe abdominal pain. Patient was tachypneic with a rate of 25 to 26 breaths/min, and he became progressively lethargic. His oxygen saturation (SpO₂) was 91% on 6 L/min of oxygen by face mask.

Arterial blood gas (ABG) analysis showed hypoxemia (pH 7.45, pCO₂ 31 mmHg, HCO₃ 22 mmol/L, BE -1.6 mmol/L, pO₂ 57 mmHg). Chest radiography showed bilateral atelectasis. Continuous Positive Airway Pressure (CPAP) ventilation was initiated using a face mask (PSupport = 14 cm H₂O, PEEP = 5 cm H₂O), which markedly improved his ventilation and oxygenation. However, the patient was restless and he kept attempting to remove the CPAP mask.

Results:

To provide adequate analgesia without further compromising ventilation, we performed bilateral TAP blocks using US guidance. With the patient in the supine position, we exposed the lateral abdominal wall between the costal margin and iliac crests. The TAP was performed between the IO and TA muscles, where 15 mL of 0.25% bupivacaine with 5 mL of 2% lidocaine was injected. Within 10 minutes, the patient became less agitated and reported that his pain had been relieved (visual analog scale 0/10 at rest, 2/10 on movement). His CPAP ventilation treatment continued all day. Serial ABG analyses (pH 7.42, pCO₂ 37 mmHg, HCO₃ 22 mmol/L, BE -1.4 mmol/L, pO₂ 108 mmHg) and chest radiography showed improvement in his hypoxemia and basal atelectasis. He was weaned off the CPAP overnight, and by late morning, he maintained a SpO₂ of 95% to 96% on intranasal oxygen at 2.0 L/min. The patient did not need additional analgesic 24 hours after TAP block. He was discharged from the ICU the next day, then discharged home on the fourth postoperative day.

Conclusion:

Postoperative pain is a limiting factor for recovery after abdominal surgery. TAP may be a simple, safe and effective adjunctive option in this population.

ID: 498

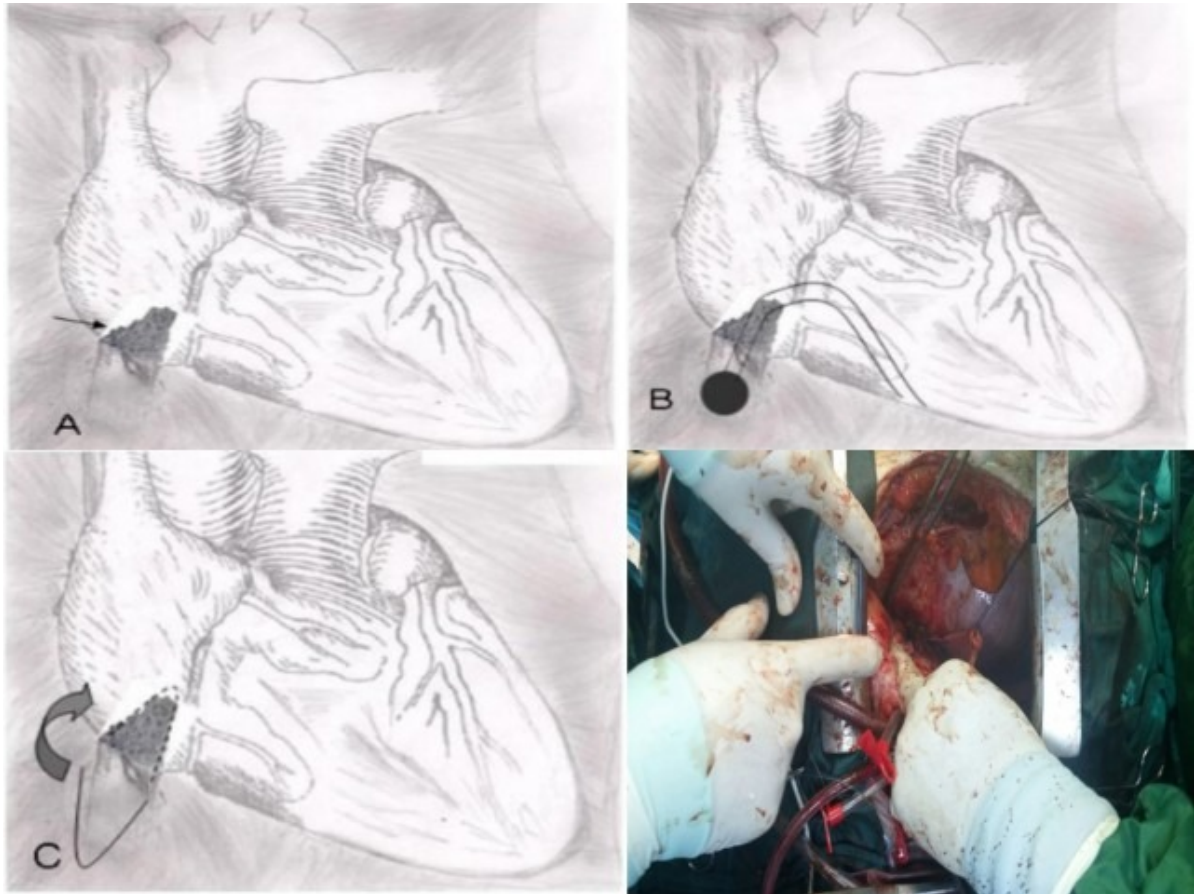
Topic: **Cardiovascular Surgery » Risk Management in Cardiovascular Diseases**Presentation Type: **Poster****REPAIR TECHNIQUE WITH PERICARDIAL CAVOATRIOPLASTY IN ATRIOCAVAL JUNCTION INJURY**Sinan Demirtaş¹, Nazım Kankılıç², Ahmet Çalışkan³, Oğuz Karahan⁴, Celal Yavuz⁵¹*Özel Bower Hospital, Diyarbakır, Turkey*²*Medical School of Harran University, Şanlıurfa, Turkey*³*Özel Reyap Hospital, İstanbul, Turkey*⁴*Medical School of Alanya Alaaddin Keykubat University, Antalya, Turkey*⁵*Medical School of Dicle University, Diyarbakır, Turkey***Corresponding Author (sinandemirtas78@hotmail.com)**sinandemirtas78@hotmail.com, nfkan82@gmail.com, drahmetcaliskan@hotmail.com, oguzk2002@gmail.com, celalyav@hotmail.com***Abstract Text****ABSTRACT**

OBJECTIVE: Severe complications may occur during open heart surgery. One of them is the injury of the inferior vena cava at the atrial junction. This injury can be in the form of partial injury or total rupture. This complication usually occurs during venous cannulation, in cases of redo cardiac surgery, or during air extraction from the ventricular apex. In this article, we shared our approach which can be used as an alternative surgical technique in this difficult complication.

METHODS: The 62-year-old patient who had undergone even bileaflet aortic valve replacement was referred to our clinic. The patient had severe aortic insufficiency and an abscess in the prosthetic valve. Sutureless aortic bioprosthesis valve replacement was performed to patient. In the operation, air intake from the venous line was seen after the removal of the air from the left ventricular apex. When venous air access and the cause of the bleeding were investigated, partial rupture was observed in the cavoatrial junction. Repair was performed with Teflon pledgetic sutures. However, the repair could not be done due to fragility of the tissues. In the repair performed with large tissue areas, the ostium of the inferior vena cava narrowed. Standard cardiopulmonary bypass was repeated with femoral vein and superior vena cava superior cannulation. Foley catheter was sent from the injury site at the atriocaval junction. Foley catheter was inflated into inferior vena cava. Thus the area of operation was rendered more bloodless. The pericardial tissue on the inferior vena cava was partially cut to fit the ostium of the inferior vena cava. It was sutured in the form of a flap over the ruptured segment (Picture).

CONCLUSION: This technique can also be used in total ruptures in the cavoatrial junction. In patients with total cavoatrial rupture, the pericardium around the inferior vena cava ostium is separated to fit the ostium margins. And the free ends of the separated pericardium can be anastomosed to the atrium. This technique does not cause narrowing in the inferior vena cava and is an effective method to prevent this complication. We suggest that pericardial flap cavosatrioplasty can be used safely in atriocaval junction injuries that may occur during cardiac surgery.

Keywords: Pericardial Cavoatrioplasty, atriocaval junction injury, complication



A. The appearance of rupture in the Cavoatrial junction (black arrow).B. Control of bleeding with foley catheter at the Cavoatrial rupture. C. Repair of the tear by turning the pericardial flap.

ID: 551

Topic: **Cardiovascular Surgery » Diagnosis and Treatment of Valvular Heart Disease**

Presentation Type: **Poster**

MITRAL VALVE REOPERATION DUE TO HEMOLYTIC ANEMIA

Vedat Bakuy, Umut Kocabaş, Hakan Altay, Seckin Pehlivanoglu, Emin Pashazade, Derya Mandacı, Gülay Eren, Deniz Süha Küçükaksu

Başkent University Faculty of Medicine, Istanbul, Turkey

**Corresponding Author (vedatbakuy@yahoo.com)*

vedatbakuy@yahoo.com, ukocabas@baskent.edu.tr, h.altay@baskent.edu.tr, s.pehlivanoglu@baskent.edu.tr, e.pashazade@baskent.edu.tr, d.mandaci@baskent.edu.tr, g.eren@baskent.edu.tr, dskucukaksu@baskent.edu.tr

Abstract Text

Seventy years old, female patient, who had hemolytic anemia due to mechanical prosthesis for 15 years, is presented in this report. Patient was diagnosed with deep anemia and congestive heart failure one year after mitral valve replacement and followed by medical therapy because of given high preoperative risk since admission to our institution. Echocardiographic assessment revealed a paravalvular leak (PVL) in posterior portion of prosthesis and reoperation was planned due to frequent heart failure admissions, severe systolic pulmonary hypertension (75 mmHg) and calculated high gradients in mitral prosthesis and native aortic valve. Subvalvular pannus and approximately two centimeters long PVL was observed in posterior border of mechanical valve during the operation. Valve was excised. Calcified posterior annulus was decalcified and 29 mm bioprosthesis (St.jude Epic) was implanted. Decalcification of aortic right cusp and resuspension of commissure between the right and the left cusps were done and leaflet augmentation to the right cusp was applied. Postoperative course was uneventful and the patient was discharged on eighth day.

PVL and anemia causes major morbidity after prosthetic valve replacement and may be an indication for reoperation. Especially when complete decalcification of annulus was not achieved, intensive follow up is mandatory and re-replacement of the valve must be evaluated for better long term prognosis.

ID: 362

Topic: Cardiovascular Surgery » Diagnosis and Treatment of Valvular Heart DiseasePresentation Type: **Poster****SURGICAL TREATMENT OF IMPLANTABLE CARDIOVERTER LEAD ENDOCARDITIS****Nur Dikmen Yaman, Zeynep Eyileten, Adnan Uysalel***Ankara University School of Medicine, Ankara, Turkey***Corresponding Author (nurdikmen@yahoo.com)**nurdikmen@yahoo.com, zeyileten@gmail.com, uysalel@gmail.com***Abstract Text**

Introduction

The era of cardiac pacing began in the 1960s. Since then, the use of pacemakers (PMs) has increased rapidly and now includes traditional PMs, implantable cardioverter-defibrillators (ICDs), and cardiac resynchronization therapy devices. Unfortunately, the progress in pacing therapy is associated with the development of infections, which constitute an increasing clinical challenge and reduce positive effects of treatment.

Case Report

We report a 54-year-old man with implantable cardioverter-defibrillators was admitted for evaluation of recurrent fever and chills. At referral, blood examination showed elevation of white blood cell count, C-reactive protein, and blood cultures were positive for *Staphylococcus epidermidis*. Echocardiography demonstrated oscillating masses in right atrium; the ventricular lead, however, had a thickened "sleeve-like" appearance, it revealed a vegetation on the tricuspid valve and mild regurgitation of tricuspid valve. The size of the vegetation was measured as 27x64 mm.

Antibiotic treatment decreased these values. The complete removal of the devices was attempted, because vegetation was still found in right atrium and on the lead.

Extirpation of the pacemaker lead and vegetation was performed under cardiopulmonary bypass. Through the right atriotomy, the tricuspid valve and ventricular lead were examined. The pacemaker lead was covered with white firm pseudoneointima on the lateral and inferior right atrial wall. On the tricuspid valve, pseudoneointima was absent and a 3x6 cm fragile vegetation was found. In the right ventricle, the lead was covered with firm white pseudoneointima. The tip of the lead was easily removed manually from the right ventricle. The lead was cut at the junction of the superior vena cava and the right atrium. The rest of the lead was removed through the left subclavian vein at the incision site of the generator on the left upper chest wall. The generator was also removed at the same site. The vegetation on the tricuspid valve was removed so as not to destroy the tricuspid septal leaflet and the fragile vegetation tissue could be entirely removed without damage to the leaflet. The right atrial wall was closed without any artificial material inside the right atrium. The postoperative course was uneventful and he received effective antibiotics for 4 weeks after the operation.

Extraction of the pacemaker device confirmed *S. epidermidis*.

Discussion

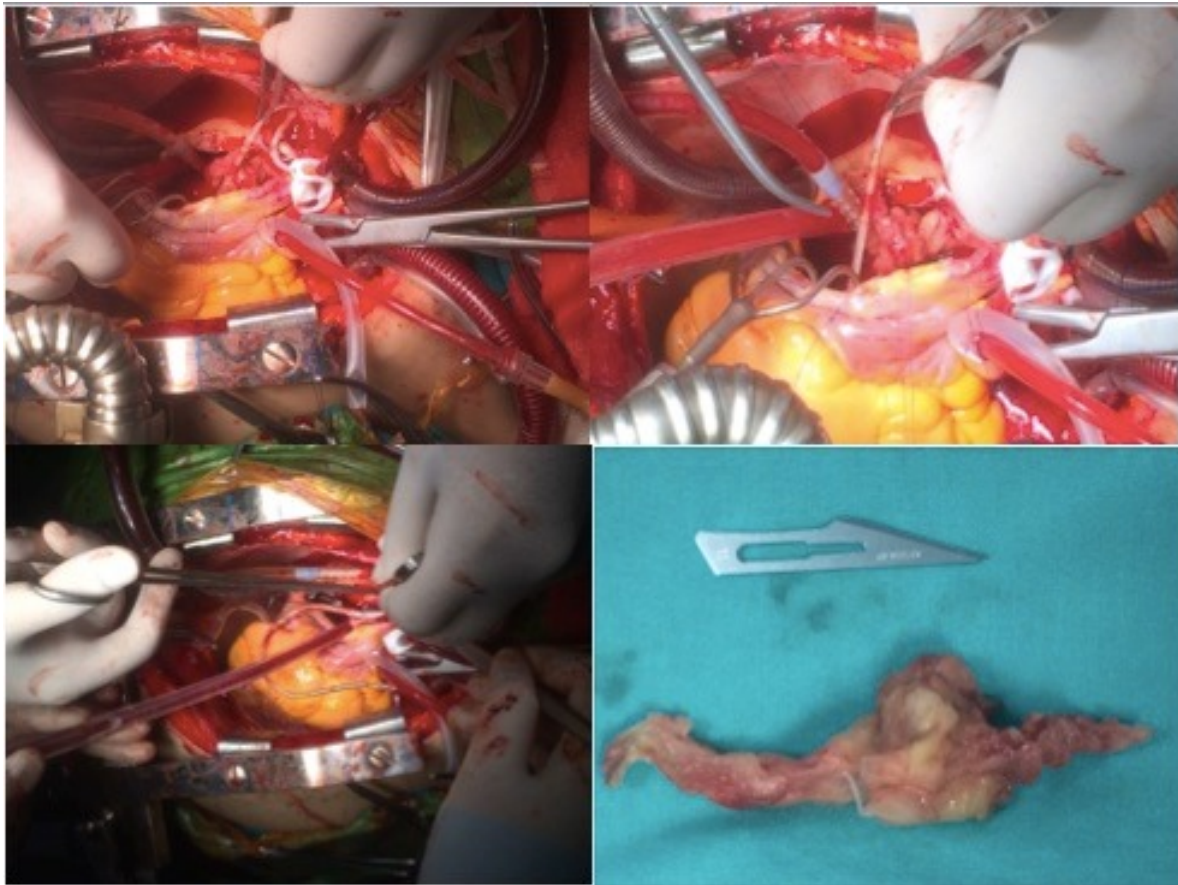
The incidence of cardiac device infections in patients with implantable cardiac electronic devices is estimated to range from 0.5% to 2.2%.

Blood cultures play an important role in the diagnostic process. According to literature, most frequently encountered pathogens include coagulase positive and coagulase negative Staphylococci (80%).

The size of vegetation and pacemaker dependency of patient should be considered in selecting the removal procedure. There is a risk of septic pulmonary embolism when the vegetation is large, and a risk of infection remaining in the heart cavities. Moreover, percutaneous lead extraction may be complicated by tricuspid valve laceration and incompetence and may need subsequent valvular annuloplasty.

Re-implantation of device should be at a new site or epicardially. Timing of re-implantation is still debated. Some authors recommend delaying re-implantation up to 6 weeks.

Some series have recommended 6 weeks of therapy after device removal. However, some authors have suggested 4 weeks should be adequate.



ID: 236

Topic: **Cardiovascular Surgery » Heart Valve Repair**Presentation Type: **Poster****SURGICAL TREATMENT OF SEVERE TRICUSPID VALVE
DEGENERATION WITH INTRACARDIAC LEAD ENDOCARDITIS**Cengiz Bolcal, **Hüseyin Sicim**, Gökhan Erol, Emre Kubat, Murat Kadan, Kubilay Karabacak, Suat Doğancı*Gulhane Training and Research Hospital, Ankara, Turkey***Corresponding Author (bolcalc@yahoo.com)**bolcalc@yahoo.com, huseyinsicim@yahoo.com.tr, drgokhanerol@gmail.com, ekubat@gmail.com,
mrtkdn@gmail.com, kubilaykarabacak@yahoo.com, suat_doganci@yahoo.com***Abstract Text****INTRODUCTION:**

Infective endocarditis, which can be seen as a very rare complication of pacemaker and ICD therapy, has high mortality potential. Risk factors for cardiac device endocarditis include many factors such as diabetes mellitus, malignancies, chronic conditions such as immunosuppressive therapy and local factors. Although there are cases where medical treatment has been reported to be successful, there is a consensus that the whole pacemaker system should be removed to ensure all infection eradication. In this case report, we presented the surgical treatment of advanced tricuspid valve degeneration secondary to very rare lead endocarditis.

CASE REPORT:

A 57-year-old male patient had a history of ICD implantation due to low ejection fraction. The patient receives hemodialysis treatment three days a week for chronic renal failure. The patient was not able to open a fistula due to the low ejection fraction. The patient has permanent dialysis catheter. The patient was admitted to the hospital due to fever and shortness of breath. Transthoracic and transesophageal echocardiography showed an ejection fraction of 15%, severe tricuspid regurgitation, and vegetation on the lead. Surgical intervention was decided. Due to the low ejection fraction, it was decided to perform operation in the heart. The right atrium was opened in the beating heart after the right thoracotomy. A vegetation was detected on the lead in the atrium. (Figure 1) The lead was cut out. The remaining skin part of the skin was removed. The tricuspid valve was completely degenerated and there was no valve tissue. Therefore, it was decided to perform valve replacement. Bioprosthesis tricuspid valve replacement was performed in the beating heart. Postoperative bilateral parenteral antibiotherapy was continued. No growth of any microorganisms was detected in the intra-operative vegetation tissues. He was discharged to the cardiology clinic with healing on day 10 postoperatively.

DISCUSSION AND CONCLUSION:

Infection endocarditis due to cardiac devices such as ICD and pacemaker is a very rare clinical condition. It is difficult to diagnose endocarditis using conventional imaging techniques such as transthoracic echocardiography. TEE may facilitate the diagnosis of pacemaker lead endocarditis, but sometimes it is not enough. Cardiac surgery is recommended that patients be treated with long-term antibiotic regimens before and after electrode removal. In our case, surgical treatment is inevitable in patients with lead endocarditis and severe tricuspid valve degeneration. The details of the surgical intervention are determined preoperatively and intraoperatively. As in our case, it should be kept in mind that tricuspid valve replacement may required as a surgical intervention.

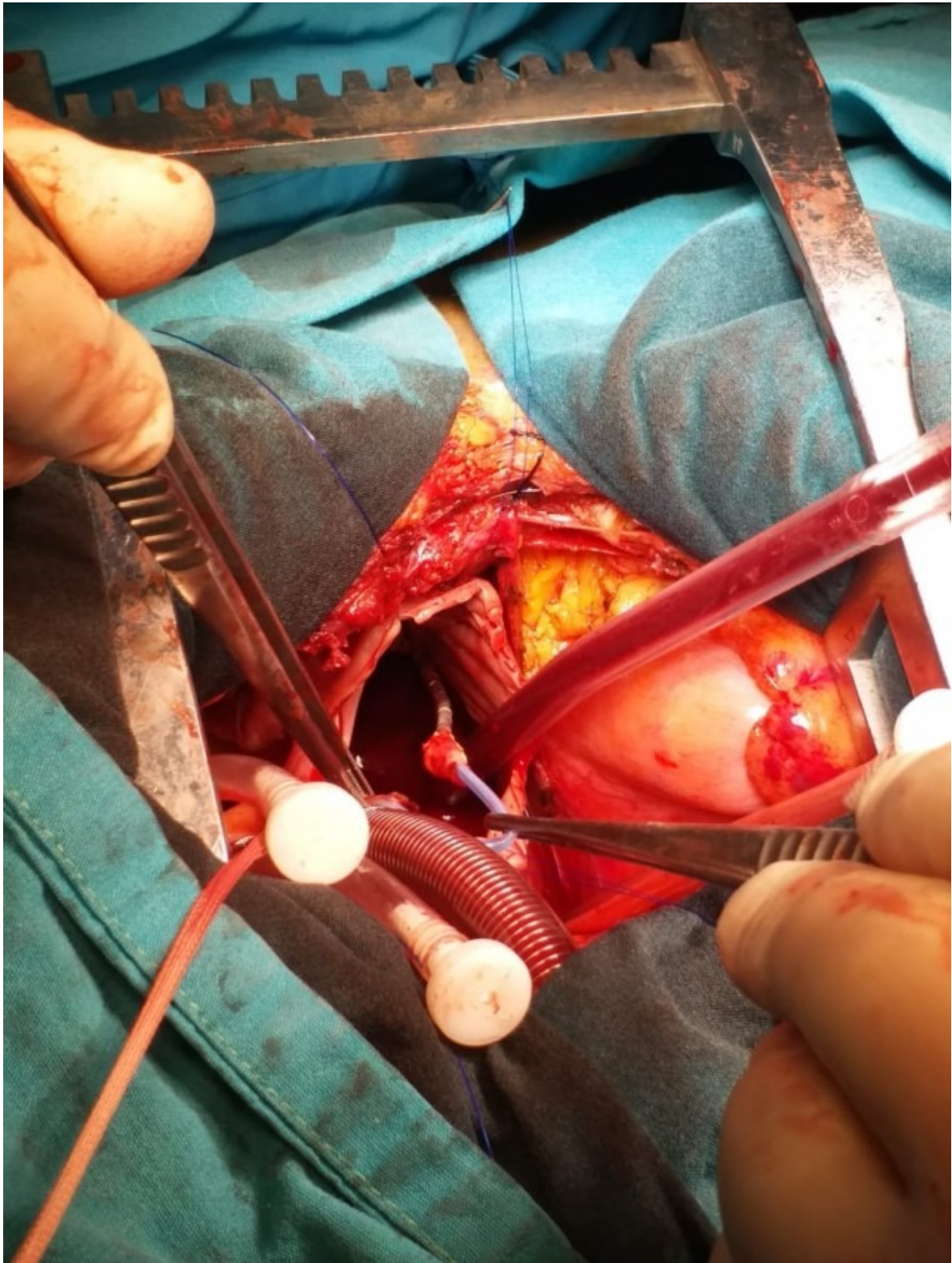
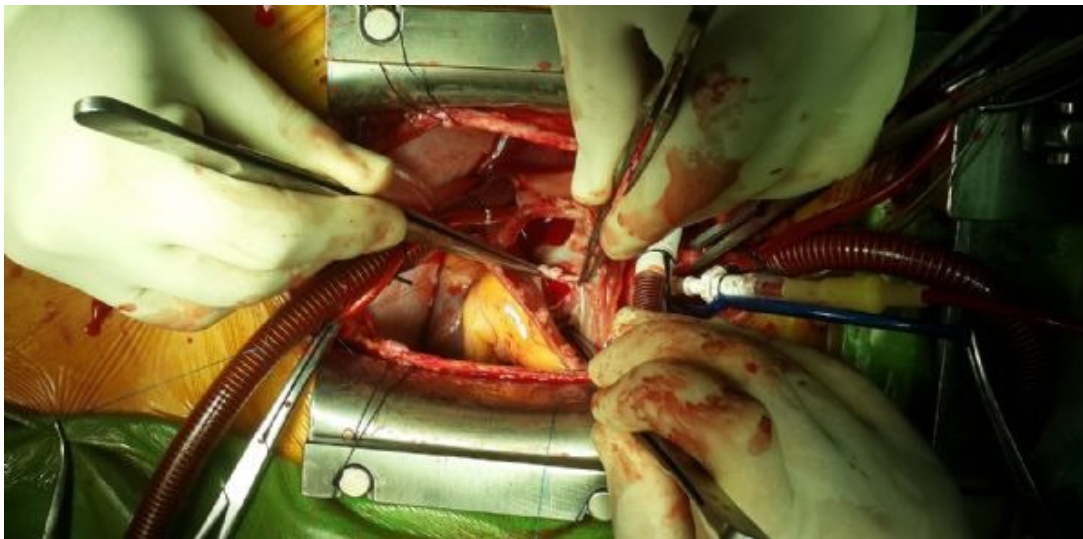

Figure 1. View of vegetation on lead with right atriotomy

ID: 536

Topic: Cardiovascular Surgery » Thoracic and Thoracoabdominal Aortic Dissections and AneurismsPresentation Type: **Poster****EMERGENT SURGERY FOR RUPTURED ANEURYSM OF SINUS VALSALVA IN A PREGNANT WOMAN****Özerdem Özçalışkan¹, Çağtay Maden², Dilek Yamak², Yavuz Yakut², Birol Yamak³**¹*Medical Park Tarsus Hospital, Mersin, Turkey*²*Hasan Kalyoncu University, Gaziantep, Turkey*³*Medical Park Gaziantep Hospital, Gaziantep, Turkey***Corresponding Author (ozerdemo@yahoo.com)**ozerdemo@yahoo.com, cagtay.maden@hku.edu.tr, dilek.yamak@hku.edu.tr, yyakut@yahoo.com, birolyamak@gmail.com***Abstract Text**

A 29 years old previously healthy woman in week 25 of pregnancy admitted to hospital due to newly developed palpitation and orthopnea. Continuous murmur was heard throughout the precordium. Transthoracic echocardiography showed a thin-wall aneurysmal dilatation of the non-coronary cusp of sinus Valsalva. Colored doppler images revealed a connection between aneurysmatic non-coronary cusp and right atrium. Due to she still was of orthopnea and limited exercise capacity despite intensive medical treatment, emergent surgery was planned. Fistula tract was observed just over the tricuspid annulus. Ascending aorta was opened and a 1,5 cm diameter fistula on aneurysmatic non-coronary cusp ruptured to right atrium was observed. A Dacron patch was used to close defect. Aortotomy was closed and cardioplegia was given from ascending aorta with a needle. There was no flow from aorta to the right atrium. Right atrium was closed and CPB was terminated properly. Control echocardiography revealed no shunt. Our obstetrician followed up daily with USG. Pregnancy was terminated in 35th week by cesarean section. Both mother and baby are healthy in their follow up. She had routine physiotherapy program at the hospital twice a day and her home three times a week with her physiotherapists. Her physiotherapy program was based on respiratory exercises and mobilization. All ROM exercises was performed with the assistance of physiotherapist.



CONCLUSION: The rupture of the sinus Valsalva aneurysm into the cardiac chambers is rare situation and presents a complex management. The surgical treatment of ruptured aneurysm remains the gold standard.

ID: 220

Topic: Cardiovascular Surgery » Thoracic and Thoracoabdominal Aortic Dissections and AneurysmsPresentation Type: **Poster****ABERRANT RIGHT SUBCLAVIAN ARTERY IN A PATIENT WITH ASCENDING AORTA ANEURYSM**Ufuk Çiloğlu, **Burcu Gönül**, Hakan Kutlu*SBÜ İstanbul Dr Siyami Ersek Göğüs Kalp ve Damar Cerrahisi Eğitim ve Araştırma Hastanesi, İstanbul, Turkey***Corresponding Author (ufukmd@yahoo.com)**ufukmd@yahoo.com, drburcugnl@gmail.com, drhakankutlu@yahoo.com***Abstract Text**

Aberrant Right Subclavian Artery in a Patient with Ascending Aorta Aneurysm

Ufuk Çiloğlu, Burcu Gönül, Levent Ceylan, Hakan Kutlu

ABSTRACT**OBJECTIVE:**

In this study, we present an aberrant right subclavian artery in an adult patient which is diagnosed by further examination for an early-elective Bentall procedure.

CASE REPORT:

A 54-year-old female patient was referred with unproductive cough and exertional dyspnea for 2 months. Her history included hypertension. She had no pulmonary disease diagnosed earlier. Respiratory functional tests were normal. Peripheral pulses were palpable. She had no peripheral edema. Pulmonary auscultation was normal. Normal sinus rhythm was seen in ECG. Echocardiogram showed dilated ascending aorta (7,2 cm) (Figure 1c) and sinuses of valsalvae (5,2 cm). Severe aortic valve insufficiency was present. Both internal carotid arteries were normal in color doppler ultrasound. Contrast-enhanced computed tomography found aberrant right subclavian artery (RSA) (Figure 1a, 1b) It was originated just distally from left subclavian artery root, taking its anatomic position after coursing posteriorly from the trachea and oesophagus. 3D-reconstructed bronchoscopy showed no signs of compression to trachea. Both common carotid arteries were originated from a joint trunk. Coronary angiography was normal. The patient then underwent Bentall procedure and replacement of hemiarch with 25# Medtronic open pivot aortic valved graft. For cardiopulmonary by-pass, we used double arterial cannula, one for right common femoral artery, other one for brachiocephalic trunk from which both common carotid arteries were originated. We used the latter for continuous antegrade cerebral perfusion during circulatory arrest to complete hemiarch anastomosis. The ostium of aberrant RSA was inspected normal during the procedure. No correctional procedure was performed. Surgery was ended uneventfully. The patient was followed in ICU for 24 hours, then discharged on the 8th postoperative day.

CONCLUSION:

Vascular rings are congenital anomalies of arcus aortae which are formed by an abnormal regression of aortic arches during embryological development. Only %1 of all congenital heart diseases are associated with vascular rings. In cases like we present, especially with a disease of another part of the aorta, such anomalies must be well evaluated preoperatively whether there is a need for additional correction surgery.

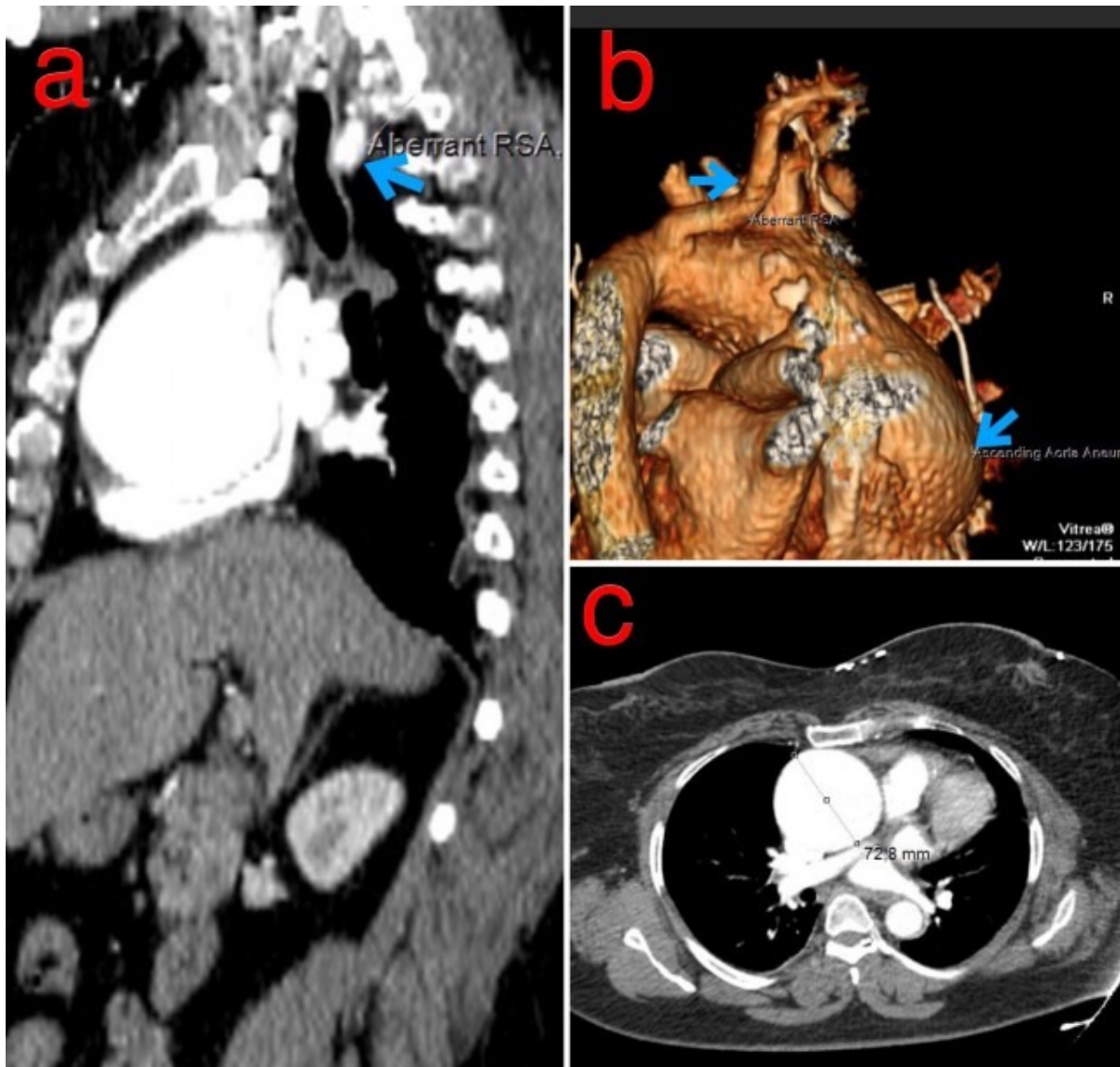


Figure 1; a: sagittal CT image, aberrant right subclavian artery is seen going posteriorly from trachea. b: 3D reconstructed image demonstrating the origin of aberrant right subclavian artery, and ascending aorta aneurysm. c: axial CT scan sequence, dilated ascending aorta (72,8 mm)

ID: 363

Topic: **Cardiovascular Surgery » Congenital Heart Disease**Presentation Type: **Poster****PRECAUTIONS AND MANAGEMENT OF VON WILLEBRAND FACTOR DISEASE IN CONGENITAL HEART SURGERY**

Nur Dikmen Yaman, Burcu Arıcı, Ata Niyazi Ecevit, Semih Ufuk Tezeren, Hatice Mine Çakmak, Elif Ince, Zeynep Eyileten, Adnan Uysalel

Ankara University School of Medicine, Ankara, Turkey

**Corresponding Author (nurdikmen@yahoo.com)*

nurdikmen@yahoo.com, burcuincekalan@hotmail.com, drataecevit@gmail.com, semihufuktezeren@hotmail.com, minecakmak@hotmail.com, eince@ankara.edu.tr, zeyileten@gmail.com, uysalel@gmail.com

Abstract Text

Introduction

Surgical procedures in von Willebrand disease (VWD) patients may require prophylactic treatment with exogenous von Willebrand factor (VWF) and coagulation factor VIII (FVIII) to prevent excessive bleeding.

VWD is a hemostatic defect associated with increased risk of bleeding in patients with cardiac lesions as a result of shear induced deficiency of high-molecular-weight multimers of vWF.

Case report

We report a case study of a four year old, 16 kg weighted child with ventricular septal defect who experienced significant bleeding during dental surgery and was subsequently suspicion of VWD.

To confirm the diagnosis we made some tests including peripheral smear, complete blood count, in vitro platelet functions, PFA-100, vWF, FVIII and bleeding time. Results of samples were in accordance with vWF disease as given in table. After exact diagnosis, we have tried some solutions to avoid peroperative and postoperative life threatening bleeding. We have applied blood products, fresh frozen plasma, platelets, cryoprecipitate, coagulation FVIIa (NovoSeven®), vWF/FVIII concentrates (Haemate®). After these approved precautions, the patient underwent surgery and taken to pediatric intensive care unit with non objectionable bleeding. Total drainage was 150 cc from mediasten tube and 70 cc from chest tube. We have continued to give a dose of NovoSeven® and Haemate® 1000 U/day for 7 days after surgery. Postoperative course was good without any problems and identical to other VSD patients.

Discussion

VWD is an uncommon cause of bleeding in the pediatric population but is an increasingly recognized cause of unexplained bleeding in patients with various congenital and acquired cardiac defects. Bleeding is unmasked or compounded in this patient population by exposure to antithrombotic therapy. Although multimer analysis is a very sensitive test, it is not widely available. Platelet Function Analyzer-100 (PFA-100), vWF antigen assay, vWF ristocetin cofactor (RCo) activity, and vWF collagen-binding activity are other investigations that may be helpful in supporting the diagnosis of VWD. Accuracy of PFA-100 testing requires normal hematocrit and nearly normal platelet count, and both can be difficult to achieve in a bleeding patient.

Management was individualized based on risk–benefit assessment. Initial measures to control bleeding consisted of standard blood product support, lowering the intensity or temporarily with holding anticoagulation (if possible) and surgical interventions to secure hemostasis if this was deemed appropriate. Prohemostatic therapies including vWF concentrate and desmopressin were generally reserved for persistent bleeding refractory to the above measures.

Treatment can be challenging

Table: Laboratory results

Hb: <u>10,3</u> g/dl (10,5-14)	<u>Gp IIIa/IIb</u> : normal
Htc: 31,5% (31-40)	<u>Gp Ib alfa/gp IX</u> : normal
Platelets: <u>153.000</u> g/l (150-450)	Fe: 43 <u>microgr/dl</u> (70-180)
MPV: 12,5 (9,2-12,1)	Total Fe binding: 443 <u>microgr/dl</u> (250-450)
CD 41: 100%	Transferrin saturation: 10% (13-45)
CD 42a: 100%	<u>Vit B12</u> : 517 <u>pg/mL</u> (126-505)
CD 42b: 100%	<u>Folate</u> : 7,94 <u>ng/mL</u> (5,9-24,8)
CD 61: 100%	<u>vWF (Ag)</u> : 219% (66-176)
F VIII: 82,6	<u>vWF (Ri:CoF)</u> : 158% (40-125)
Fibrinogen: <u>3,21</u> (2-3,93)	PFA-100 >291 (84-160)

Correction of the cardiac defect is the only definitive treatment but may not be possible in many patients. Blood product support and interruption and/or lowering the intensity of anticoagulation to allow hemostasis may be sufficient in some patients. However, patients with persistent severe bleeding may require specific prohemostatic therapies.

In conclusion, VWD is an uncommon but important cause of bleeding in pediatric patients with cardiac disease. A high index of clinical suspicion, characteristic clinical scenario, and low levels of vWF multimers are required to diagnose. Although the optimal management of VWD is unclear, vWF concentrates are available and appear to be efficacious for controlling life-threatening bleeding.

ID: 208

Topic: **Cardiovascular Surgery » Congenital Heart Disease**Presentation Type: **Poster****PULMONARY BICUSPID VALVE RECONSTRUCTION IN TETRALOGY OF FALLOT SURGERY**

Seymur Musayev, Emin Gurbanov, Farid Huseynov

*Central Hospital for Oilworkers, Baku, Azerbaijan***Corresponding Author (emin405@hotmail.com)**emin405@hotmail.com, emin405@hotmail.com, emin405@hotmail.com***Abstract Text****BACKGROUND:**

The purpose of the present study was to evaluate the surgical outcomes of our modification for reconstructing pulmonary valve using bicuspid valve technique in patients with tetralogy of Fallot (ToF).

METHODS:

Between October 2011 and July 2016, a total of 132 patients underwent total repair for ToF. The pulmonary valve reconstruction using bicuspid technique was used in 25 patients (group I), and a TAP only without valve reconstruction was used in 107 patients (group II). The 1st cusp of was formed from residual native pulmonary cusps and the 2nd cusp was made of autologous untreated pericardial patch.

RESULTS:

The median age of the patients was 12 years (range, 1–34 yr). Total perioperative mortality was 5.3%, one perioperative death occur in redo case and 6 due to low cardiac output. Patients in pulmonary valve reconstruction group although had longer bypass and operative times; however it was not statistically significant ($P > 0.01$). The early and midterm results demonstrated significantly more moderate or severe pulmonary insufficiency in the group II (68%) compared to group I (15%) ($P < 0.001$). Echocardiography of bicuspid valve function obtained at 8.5 +/- 10.8 months showed an average bicuspid valve gradient of 22.6 +/- 28.2 mm Hg.

CONCLUSIONS:

Pulmonary valve reconstruction using autologous pericardium to create bicuspid valve can be used in the majority of patients with ToF. Bicuspid valve performed as well as native valves and prevents early severe PI which preserves of RV function and improves short and midterm clinical outcomes.

ID: 199

Topic: Cardiovascular Surgery » Congenital Heart Disease

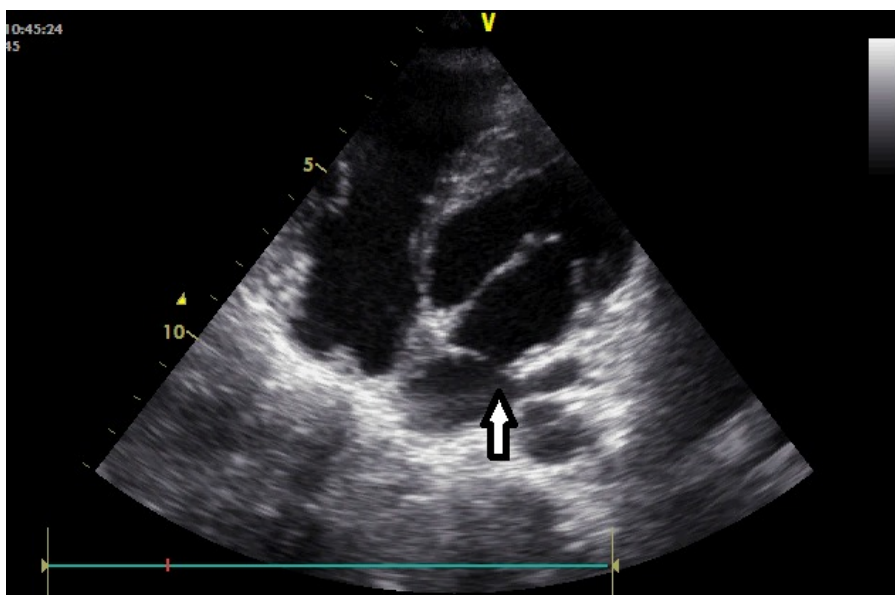
Presentation Type: Poster

COR TRIARIATUM SINISTRUM**Raif Kılıç, Bayram Arslan, Hasan Kaya, Tuncay Güzel, Faruk Ertaş, Halit Acet***Dicle University , Diyarbakır, Turkey***Corresponding Author (raifkkl@hotmail.com)**raifkkl@hotmail.com, drbarslan@windowslive.com, dr_hasankaya@yahoo.com, drtuncayguzel@gmail.com, farukertas@hotmail.com, halitacet@gmail.com***Abstract Text****CASE**

A 20-year-old male patient presented with dyspnea, effort intolerance and palpitations. Effort capacity was NYHA (New York Heart Association) class II. Physical examination revealed a diastolic murmur in the mitral focus and normal lung sounds. TA: 120/75 mmHg, ECG in sinus rhythm, heart rate: 120 / min, right axis deviation. Cardiothoracic rate was slightly increased in PALG(Posterior anterior lung graphy). Echocardiography showed a fibromuscular membrane that divides the atrium in the left atrium and was accompanied by pulmonary hypertension (PABs: 50 mmhg). In the transesophageal ECO, several defects were observed on the membrane allowing the flow between two membranes and the membrane separating the left atrium into two cavities. No additional cardiac anomaly was detected. The patient was diagnosed as Cor triatriatum sinistrum and underwent surgery for fibromuscular membrane resection.

DISCUSSION AND CONCLUSION

Cor triatriatum is a rare congenital cardiac anomaly, with a rate of 0.1% in all congenital heart diseases. A fibromuscular membrane that divides the left atrium into two separate chambers. Cor triatriatum may cause symptoms in the early period or symptoms may occur in the second decade or after. It mimics clinical mitral stenosis or ASD. Pulmonary hypertension, pulmonary edema may occur if there is obstruction in front of pulmonary venous return. The majority of cases (75-77%) are accompanied by an additional cardiac anomaly. The most common (50-60%) concomitant cardiac anomaly is ASD. In our case, there was no additional cardiac pathology, but because of the development of pulmonary hypertension and because the patient was symptomatic, the patient was referred to surgery. Its treatment is resection of fibromuscular membrane. Resection of the membrane can be performed by left atrial, transatrial, biatrial route. The surgical treatment of cor triatriatum is simple and early diagnosis plays an important role in reducing morbidity and mortality.



ID: 156

Topic: **Cardiovascular Surgery » Congenital Heart Disease**Presentation Type: **Poster****THREE CASES WITH COMPLEX INTRACARDIAC ANOMALIES
ACCOMPANYING ECTOPIA CORDIS****Kaan Yıldız, Mustafa Kır, Sevket Baran Ugurlu, Nurettin Unal, Onur Tasci, Zeynep Halise Genc***Dokuz Eylul University Faculty of Medicine, Izmir, Turkey***Corresponding Author (drkaanyildiz@gmail.com)**drkaanyildiz@gmail.com, mustafa.kir@deu.edu.tr, ugurlub@yahoo.com, nurettin.unal@deu.edu.tr,
onur.tasci@deu.edu.tr, zeynep.genc@deu.edu.tr***Abstract Text**

Introduction

Ectopia cordis is a rare congenital disorder where the heart is partially or completely located outside the chest cavity. The incidence of approximately one million live birth is of 5.5-7.9. The most common congenital heart disorders associated with ectopia cordis are ventricular septal defect, atrial septal defect, pulmonary stenosis, right ventricular diverticulum, double outlet right ventricle and Fallot tetralogy. In addition with ectopia cordis, non-cardiac disorders can be seen such as omphalocele, gastroschisis, scoliosis, cleft palate and central nervous system disorders. Because of the rare clinical condition, we present 3 cases with ectopia cordis who were followed up in our center.

Case 1

At the 35th gestational week of the first pregnancy of a 19-year-old mother, the baby born at a weight of 2,930 g with a caesarean section and the baby's heart was completely out of the chest cavity (Figure 1). On physical examination, there was ectopia cordis in the thoracic region, there was a slight opening in the abdominal wall, but omphalocele was not observed. In her echo, there were well-developed 2 separate ventricles and atrium, some of the atria were in the rib cage and deformed. A large primum ASD was observed, with normal aortic and pulmonary artery flow. The heart of the patient, who was operated by cardiovascular surgery on the 6th day after the birth, was placed in the abdomen and the defect on the heart was closed with porcine pericardial patch (Figure 2).

Case 2

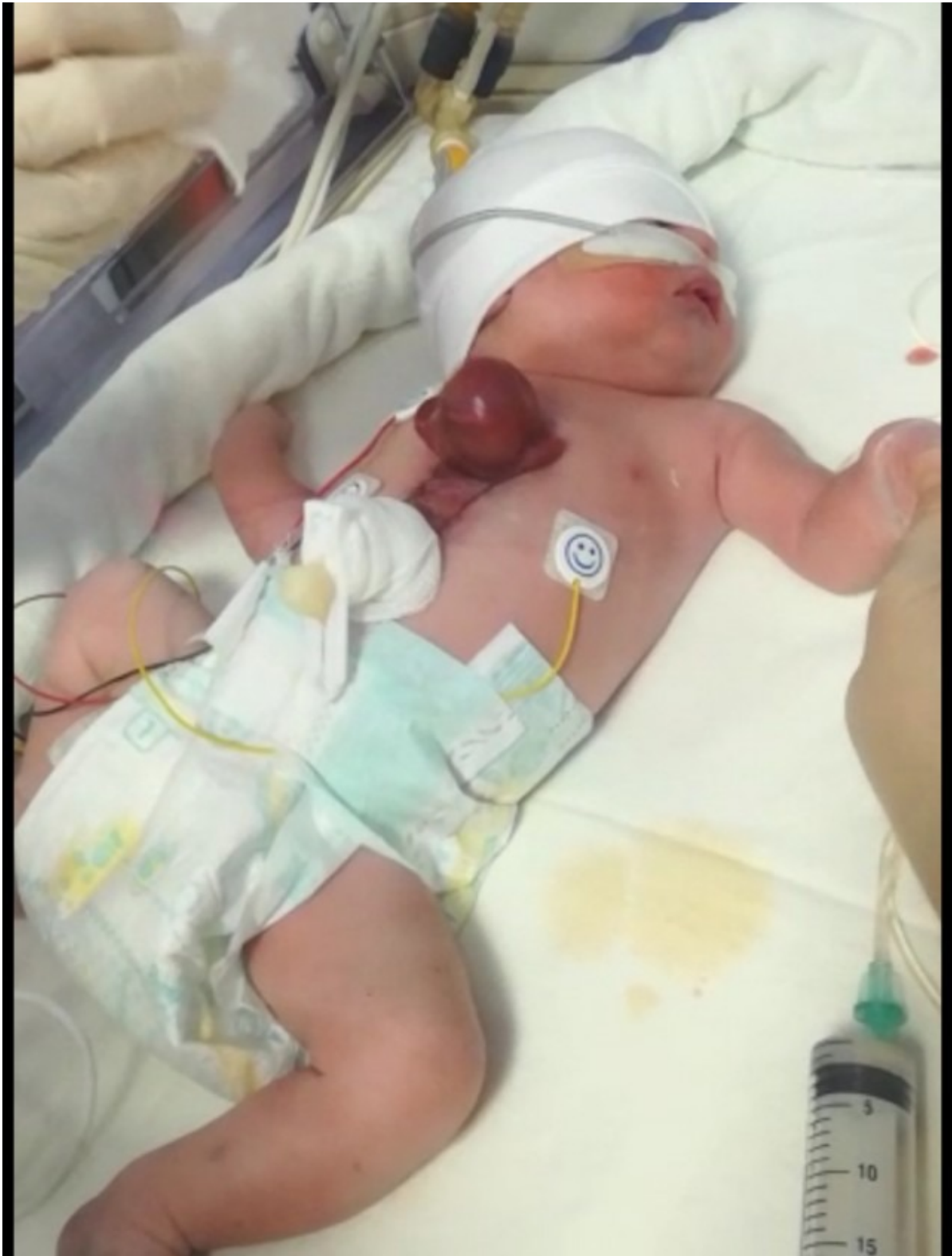At the physical examination of a baby boy, who born with a cesarean section at 39 weeks of gestation from a 24-year-old mothers first pregnancy, ectopia cordis, cleft palate, cleft lip and ventral supraumbilic defect was observed. In the echo of the patient who had a pentalogy of Cantrell, double outlet right ventricle (DORV), large VSD and pulmonary stenosis were detected. Cleft palate and lip repair were performed at 14 months of age, because of increased pulmonary stenosis in the patient's follow-up the left BT shunt operation was performed by cardiovascular surgery at 4 years of age. Our patient is 5 years old now, clinically stable and has been followed up in our department (Figure 3).

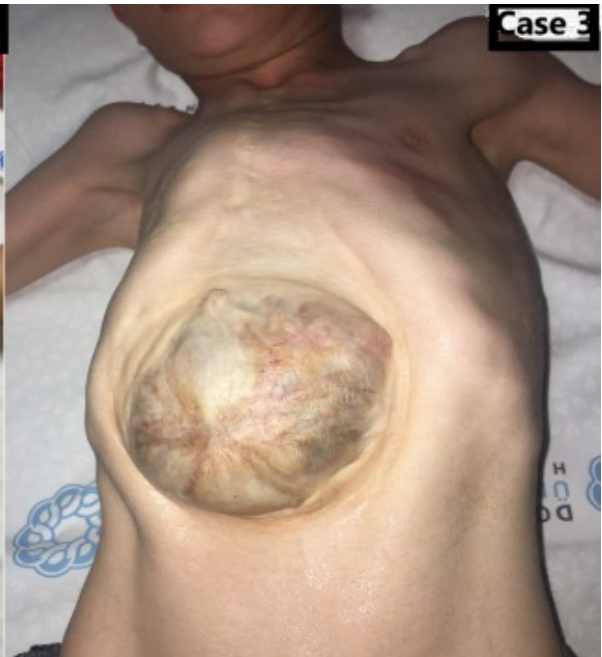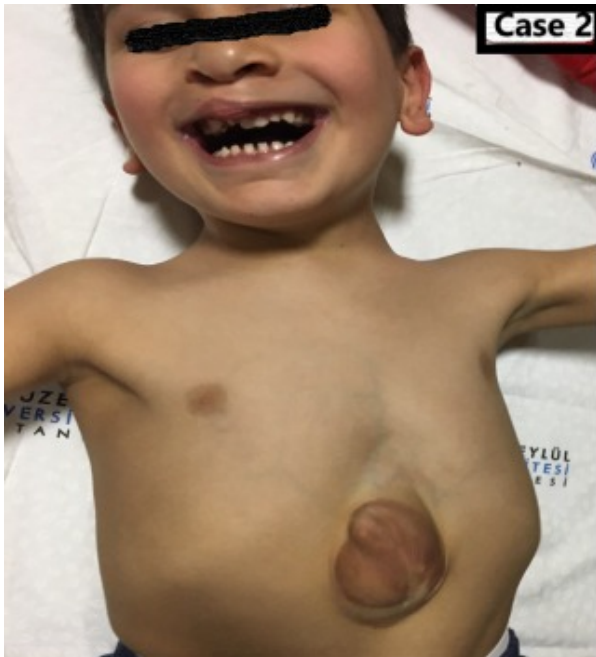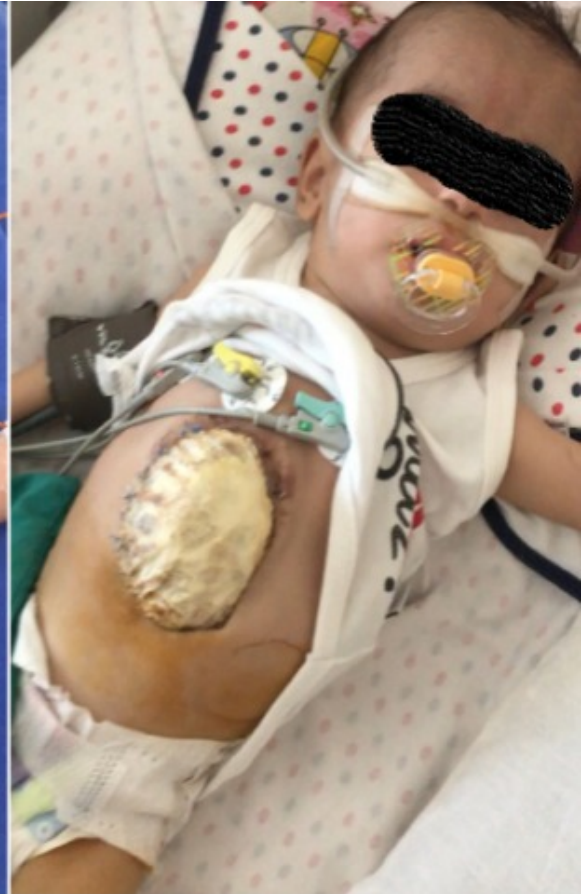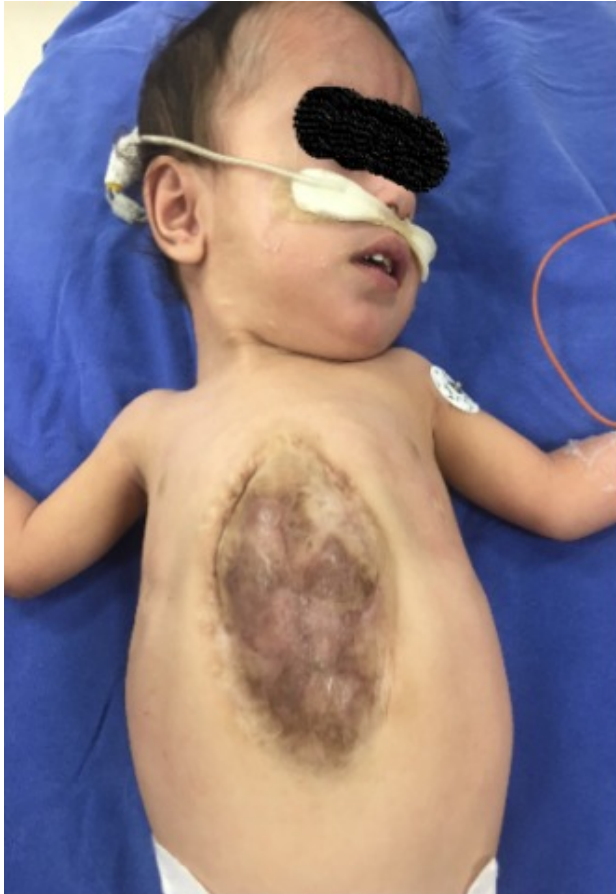Case 3

At the physical examination of a baby boy, who born with a cesarean section at 37 weeks of gestation from a 22-year-old mothers first pregnancy, ectopia cordis and omphalocele was observed. In echocardiography DORV, wide inlet VSD, arterial malposition, primum ASD, pulmonary stenosis, and PDA (thin) was observed. The patient underwent omphalocele repair at the age of two and a half months, and at the age of 6, left BT shunt surgery was performed by cardiovascular surgery because of increased pulmonary stenosis. Our patient is 10 years old now, clinically stable and has been followed up in our department (Figure 3).

Result

Coexistence of ectopia cordis with congenital heart diseases is common (80,2%). Ventricular septal defect, atrial septal defect, fallot tetralogy, left ventricular diverticulum and pulmonary stenosis are frequently seen. In our two cases had DORV, wide inlet VSD and pulmonary stenosis. In addition, one case had cleft palate-lip and the other case had omphalocele, which is the most common extracardiac anomaly. Because of their clinically quite rare, the cases of ectopia cordis were presented.





ID: 131

Topic: **Cardiovascular Surgery » Congenital Heart Disease**Presentation Type: **Poster****PDA DEVICE ENDOCARDITIS****Timuçin Sabuncu**, Uğur Karagöz, Ömer Faruk Gülaştı, Osman Nejat Sarıosmanoğlu*Dr. Behcet Uz Pediatric and Pediatric Surgery Research and Training Hospital, İzmir, Turkey***Corresponding Author (t_muchin@hotmail.com)**t_muchin@hotmail.com, drugurk@hotmail.com, drofg@hotmail.com, dronsar@yahoo.com***Abstract Text****PDA Device Endocarditis in a 10 Month Old Infant****Background:**

Postoperative complications are observed more frequently in parallel with the increase in the use of transcatheter methods, in treatment of patent ductus arteriosus (PDA).

Case:

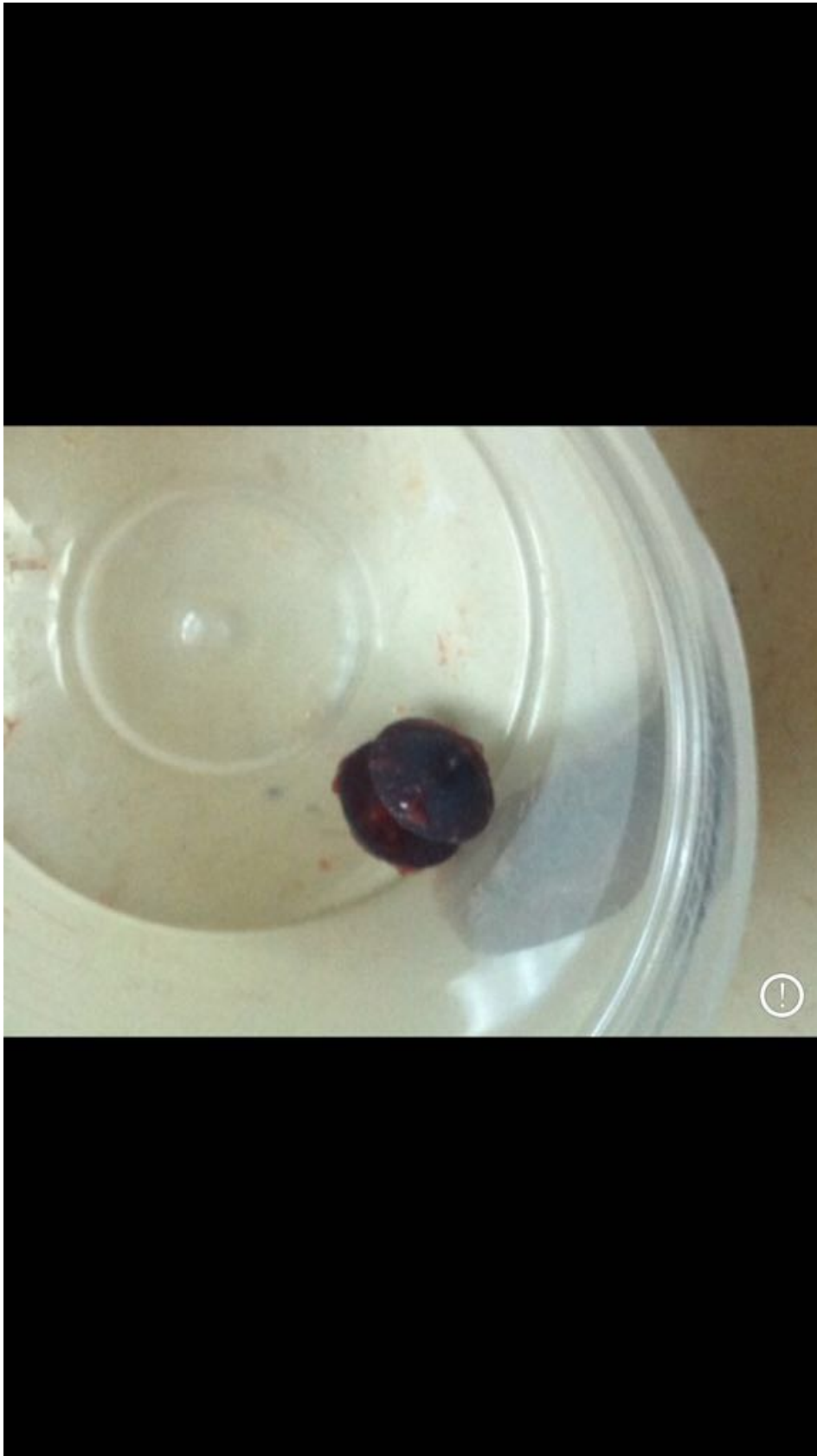The PDA of a 10-month-old girl was closed with the Amplatzer Duct Occluder II (ADO II) device. The patient was discharged after the procedure without any problems. One week later; the patient presented with complaints of nausea, lack of nutrition, deterioration in general condition, tachypnea and fever to our emergency ward. In physical exam, body temperature was 39,5°C, arterial blood pressure was 80/50 mmHg, pulse 140/min., respiratory rate was 50-70/min. 2/6 regurgitation detected at pulmonary site. Echocardiography showed an unusual hyperechogenicity on PDA, but was completely occluded with device, her ejection fraction was 68%. In laboratory tests; WBC: 25000 /L, 85% PMNL, CRP: 25mg / dL, sedimentation rate was 75mm / h. Blood cultures were taken and empirical Vancomycin (10mg / kg / day, 4 doses) - Ceftriaxone (50mg / kg / day, 2 doses) was administered. On the 4th day of the treatment, Vancomisin-sensitive Staphylococcus aureus was grown in the blood culture and an emergency operation was planned because of resistant fever despite she was under treatment with convenient antibiotherapy. Left posterolateral thoracotomy approach used to reach to the PDA. Pulmonary artery and aorta clamped proximally and distally of the PDA. After opening the PDA, all infected ductal tissue and the device itself resected and pulmonary arteriotomy sutured primarily with 6/0 polypropylene and the aortotomy site repaired with polytetrafluoroethylene (PTFE) graft.

Result:

Immediately after the operation, body temperature returned to normal values, and from the first day postoperatively there were no clinical and laboratory signs of infection. Patient's antibiotherapy completed to 14 days, and the blood cultures before discharge were negative too.

Conclusion:

Although infective endocarditis in patients with transcatheter PDA closure, is not a frequent and expected complication, but it is seen that is a serious complication which should not be ignored, to show the necessity of removal of the device, as in post-surgical infective endocarditis.



ID: 449

Topic: Cardiovascular Surgery » Adult Congenital Heart Disease

Presentation Type: Poster

MALIGN CORONARY ARTERY ANOMALIES THREE CASES REPORT**Münacettin Ceviz**, Abdurrahim Çolak, Uğur Kaya, Necip Becit, Abdulmecit Kantarcı, Hikmet Koçak*Atatürk University Medical Faculty, Erzurum, Turkey***Corresponding Author (munacettinceviz@hotmail.com)**munacettinceviz@hotmail.com, abdurrahimcolak@hotmail.com, dr.ugurum@hotmail.com, necipbecit@hotmail.com, akkanrad@hotmail.com, hkocak54@hotmail.com***Abstract Text**

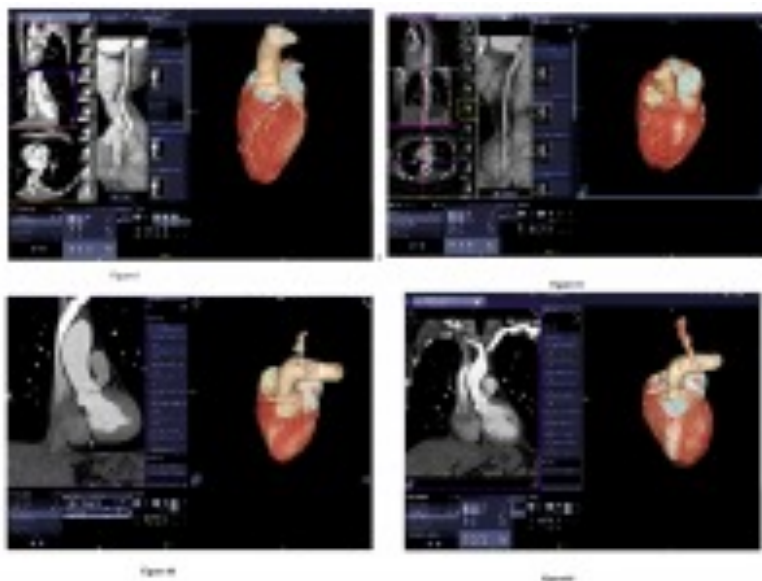
Malignant coronary artery anomalies are rare. Surgical treatment is necessary if there is a tightness coronary artery between the aorta and pulmonary artery. Three patients with malignant coronary artery anomalies underwent surgery. In 2 patients, the left main coronary artery was separated from the right sinus valsalva and transferred to the left sinus valsalva. In third patient; since coronary artery transfer operation was not possible, coronary bypass graft operation was performed. Control CT angiography was performed in 2 patients who underwent coronary transfer. Anastomosis and coronary flow were normal. We believe that the transfer of the coronary artery to the normal place in malignant coronary anomalies is the preferred method.

Figure I Preop CT angiogram

Figure II Postop CT angiogram

Figure III Preop CT angiogram

Figure IV Postop CT angiogram



ID: 234

Topic: **Cardiovascular Surgery » Adult Congenital Heart Disease**Presentation Type: **Poster****IMPACT OF PULMONARY VALVE REPLACEMENT: A MAGNETIC RESONANCE ASSESSMENT****Carolina Rodrigues, Manuela Silva, Rui Cerejo, José Fragata***Hospital de Santa Marta, Lisbon, Portugal***Corresponding Author (rodriguescarolina@gmail.com)**rodriguescarolina@gmail.com, manela_silva@hotmail.com, ruipscerejo@gmail.com, jigfragata@gmail.com***Abstract Text****Background**

An increasing number of patients with congenital heart disease survive until adulthood. Pulmonary valve replacement is the most frequent reoperation performed in adults with congenital heart disease. Without intervention, pulmonary regurgitation leads to right ventricular dilatation and, consequently, dysfunction and arrhythmias. Severe right ventricle dilatation also contributes to shape changes of the left ventricle, thereby causing biventricular dysfunction. The most accurate method to assess the degree of pulmonary regurgitation and right ventricle size is cardiac magnetic resonance. We aim to evaluate the results of pulmonary valve replacement at our institution.

Methods

We performed a descriptive analysis of 66 patients that undergone pulmonary valve replacement, between 2003 and 2016, and a subgroup analysis of patients that were evaluated by cardiac magnetic resonance, both pre and post-operatively.

Results

Of the 66 patients, 67% (n=44) are male. Predominant diagnosis (80%) is tetralogy of Fallot (n=53), while 8% (n=5) have congenital pulmonary valve stenosis, 5% (n=3) have pulmonary atresia with interventricular communication and 3% (n=2) have pulmonary atresia with intact interventricular septum. Surgical indication was severe pulmonary insufficiency in 88% (n=58), pulmonary stenosis in 6% (n=4) and mixed stenosis and insufficiency in 6%. In only one patient was implanted a mechanical valve. Mean age at surgery was 30,5 years. Mean follow-up time is five years. The last evaluation by transthoracic echocardiogram showed that 32%, 20% and 7% have mild, moderate and severe pulmonary regurgitation, respectively. There are no cases of endocarditis, prosthesis replacement or mortality. Twenty patients were evaluated by a cardiac magnetic resonance both pre-operatively (mean time 17 months before) and post-operatively (mean time 34 months after). Pre-operative end-diastolic and end-systolic right ventricle mean volumes are 310 and 168 ml, respectively. Post-operative end-diastolic and end-systolic right ventricle mean volumes are 187 and 114ml, respectively. The difference between mean volumes is statistically significant, both for end-diastolic and end-systolic volumes (p<0.05). There is a statistically significant reduction at right ventricle ejection fraction (p<0.05). However, there is a significant increase in left ventricle ejection fraction (p<0.05).

Conclusion

Despite a 40% reduction on right ventricle volumes, the incomplete resolution of RV dilation in our patient population probably indicates that PVR was undertaken too late. There is however, a significant improvement in left ventricle ejection fraction. A long-term follow-up and a standardized pre and post-operative evaluation with cardiac resonance are of major importance.

ID: 576

Topic: **Cardiology » Chronic stable angina pectoris**Presentation Type: **Poster****CHRONIC TOTAL OCCLUSION****Agil Allahverdiyev, Onur Yıldırım***Ankara University Faculty of Medicine, Ankara, Turkey***Corresponding Author (agil.allahverdiyev@mail.ru)**agil.allahverdiyev@mail.ru, hasanlicamal@gmail.com***Abstract Text**

GİRİŞ: Kronik total oklüzyon yapılmış olan KAG vakalarının yaklaşık %20'sini oluşturur. Son yıllarda PCI ekipmanlarının, rekanalizasyon tekniklerinin gelişmesi ve operatör tecrübesinin artması deneyimli merkezlerde başarı oranını %90'lara yükseltmiştir. Biz de sizlere sağ koroner arteri total tıkalı olan hastamıza uyguladığımız başarılı PCI vakamızı sunacağız.

OLGU: Hipertansiyon, DM, HL, ASKH, PAH(sol subklavien stent), KBH tanıları olan 76 yaşında kadın hasta son 5-6 aydır, hafif eforla olan göğüs ağrısı şikayeti son zamanlarda istirahatte de olmaya başlamış(CCS 4). Hasta acil servisten UAP-AKS tanısı ile hospitalize edildi. Üç yıl önce hastaya akut inferior MI tanısı ile primer PCI yapılmış ve RCA proximale 1 adet BMS, distale DES implante edilmiş. 1 ay sonra LAD ve CX lezyonları için 1'er adet DES implante edilmiş, RCA'daki stentler açık değerlendirilmiş. Son işlemden 1,5 sene sonra hasta NSTEMI-AKS nedeni ile hospitalize edilmiş ve RCA distaldeki stent içi lezyona PTCA+DES uygulanmış. Hospitalizasyon edildiğinde hastanın TA değeri 125/75 mmhg, FM'de apikal 1/6 sistolik üfürüm işitildi ve sol radial nabız alınmadı. Medikal tedavide ASA 100 mg, atorvastatin 20 mg, metoprolol 50 mg 1x1, ranolazin 500 mg 2x1,OAD ve insülin kullanmakta idi. Yapılan TTE'da sol kalp boşlukları hafif büyük, kapakların açılmaları iyi, inferior, posterior ve lateral duvarlar akinetik, diğer duvar hareketleri normal olup, EF yaklaşık %40 olarak değerlendirildi. Hasta kontrollü hidrasyon sonrası KAG laboratuvarına alındı. KAG'de LAD osteal %50 darlık, proksimale implante edilmiş stent içi %30-40 darlık, D1 ostiumunda %80 darlık (d.ç:1,5-2mm), CX'e implante edilmiş stent açık, OM2 ostiumda %90 darlık(d.ç:1 mm) izlendi.RCA proksimalde %50, RV dalı hizası total tıkalı izlendi.RCA distali grade 1-2 kollateraller ile sol sistemden görüntülendi olarak yorumlanıp, hastanın anti-anginal tedavisinin artırılması önerildi(video 1). Medikal tedaviye amlodipin 5 mg 1x1 ve isosorbid mononitrat 50 mg eklendi. 3 gün ranolazin 500 mg 2x1, metoprolol 50 mg 2x1, amlodipin 5 mg 1x1 ve isosorbid mononitrat altında hastanın semptomları takip edildi fakat bir iyileşme olmadı. Ardından LAD D1 ostiumunda %90 darlığa PCI planlandı. İşlem öncesi RCA'daki kronik total oklüzyona PCI planlanmamasına rağmen, PILOT 150 High-Torque (190 cm) tel ile lezyon geçilmeye çalışıldı. Tel proksimal cap'i geçti ve ilerletilmeye devam edildi fakat telin strut altı gittiği görüldü. Tel geri çekilip, tekrar gerçek lümen aranmaya çalışıldı ve sonunda tel distale ilerletildi(video 2). Ardından lezyona PTCA yapıldı, distale 1 adet 2,5x38 mm DES(XIENCE), stent proximalinde izlenen %80 rezidü darlığa 2,75x38 mm DES(XIENCE), RCA proximalde izlenen %90 darlığa 3,0x23 mm DES(XIENCE) implante edildi. Crux distalinde yer alan lezyona 2,5x15 mm DES(XIENCE) implante edildi. Suboptimal sonuç nedeni ile NC balon ile post-dilatasyon uygulandı. İşlem sonrası TIMI-3 akım izlendi, komplikasyon olmadan işleme son verildi(video 3). Hasta 3 gün boyunca serviste takip edildi, anginal semptomlarda belirgin düzelme izlendi(CCS 1-2). Hastanın medikal tedavisi düzenlenip 1 ay sonra kardiyojoloji poliklinik kontrol önerisi ile hasta taburcu edildi. Eğer anginal semptomlar artarsa 2. seansta LAD D1 lezyonuna girişim planlandı.

Presentation Type: **Oral****IMPACT OF LOW-DOSE DOPAMINE ON CLINICAL OUTCOMES IN HOSPITALIZED ACUTE DECOMPENSATED HEART FAILURE PATIENTS***Assist. Prof. Kurtulus Karauzum¹, MD.**¹Kocaeli University Medical Faculty, Department of Cardiology, Kocaeli, Turkey.**Kurtulus Karauzum, MD**Kocaeli University Medical Faculty, Department of Cardiology, Umuttepe Yerleskesi, 41380, Kocaeli, Turkey.**kurtuluskarauzum@yahoo.com*

Objective: The additional benefit of low-dose dopamine infusion on diuresis, renal function and clinical outcomes in patients with acute decompensated heart failure (ADHF) have not been suggested yet clearly in previous studies. In this study, we aimed to assess the effect of low-dose dopamine in hospitalized patients with ADHF.

Methods: We retrospectively evaluated 102 consecutive patients (68 males, 34 females) admitted with ADHF and divided the group as low-dose dopamine+intravenous furosemide (LDD+F, 49 patients) and continuous infusion furosemide (CF, 53 patients) groups. The effects on diuresis, renal function on 24th and 72nd hours, mortality and rehospitalization due to acute decompensated in 60th and 180th days were recorded.

Results: The mean age of study population was 65 ± 12 years. Systolic blood pressure (119 ± 12 mmHg), creatinine (1.39 ± 0.66 mg/dl) and NT-proBNP (11568 ± 9745 ng/dl) on admission and total furosemide dose (120 mg/day) during treatment were similar between the two groups. Rate of diuresis was higher (24th hour: 4201 ml vs. 2987 ml, $p=0.001$; 72nd hour: 10498 ml vs. 8413 ml, $p=0.007$) and length of hospital stay was statistically significant shorter (LDD+F: 8 ± 2 days vs. CF 10 ± 4 days, $p=0.009$) in LDD+F group. Creatinine at 24th (LDD+F 1.47 ± 0.56 mg/dl vs. CF 1.51 ± 0.82 mg/dl, $p=0.505$) and 72nd hours (LDD+F 1.43 ± 0.45 mg/dl vs. CF 1.64 ± 0.97 mg/dl, $p=0.828$) and electrolytes were not different. Rehospitalization rates at 60th days were statistically significant higher in LDD+F group than CF group (LDD+F 10 patients vs. CF 22 patients, $p=0.022$), but rehospitalization rates at 180th days and mortality rates at 30 and 180 days were not statistically different.

Conclusions: The low-dose dopamine combined with furosemide may improve diuresis volume, length of hospital stay and short-term rehospitalization in hospitalized patients with ADHF.

Table 1. Clinical and laboratory outcomes of study patients in LDD+F and CF groups.

End-points	Low-dose dopamine+furosemide group (n=49)	Furosemide group (n=53)	P-value
Diuresis at 24th hour (ml)	4201±2101	2987±1545	.001
Diuresis at 72nd hour (ml)	10498±3888	8413±3685	.007
Creatinine at 24th hour (mg/dl)	1.47±0.56	1.51±0.82	.505
Creatinine at 72nd hour (mg/dl)	1.43±0.45	1.64±0.97	.828
Length of hospital stay (day)	8±2	10±4	.009
Rehospitalization at 60th days (n)	10	22	.022
Rehospitalization at 180 days (n)	28	24	.231
Mortality at 60 days (n)	1	2	.605
Mortality at 180 days (n)	2	4	.473

ID:578

Presentation Type: Oral

CLaCS Treatment (Cryo Laser and Cryo Sclerotherapy)

Op Dr Emre Doğan

Trabzon Ahi Evren GKDC Hastanesi

Background: CLaCS (Cryo-Laser and Cryo-Sclerotherapy) is a way to treat leg vein lesions by combining transdermal laser effect and injection sclerotherapy, all under skin cooling (Cryo - cold air blown onto the skin at -20°C). It is a revolutionary treatment for spider veins and feeder veins of the leg.

The CLaCS technique was developed by some Vascular Surgeons of Sao Paulo, Brazil since 1999.

Their pioneering work has produced the most successful results of achieving eradication of the unsightly and embarrassing spider veins and feeder veins.

Methods

The laser causes a selective photothermolysis damaging to the vein wall. The vein's lumen gets smaller.

On a second procedure, sclerosing agent is injected where the vein is still open.

This combination allows to treat veins that could be treated by phlebectomy or sclerotherapy - more invasive options.

To improve results, CLaCS can be guided by Augmented Reality.

Results&Conclusion: Since CLaCS targets the feeder veins, the developers of CLaCS and us, we believe strongly that the improvements after CLaCS will endure over time. But new spider veins can always develop with venous risks.

There are 4 essential elements of CLaCS :

- Vigorous COOLING OF THE SKIN to reduce discomfort from laser and injections
- The use of AUGMENTED REALITY to visualize feeder veins so that they can be treated
- The application of a TRANSDERMAL LASER to the feeder veins and spider veins
- INJECTION OF THE FEEDER VEINS AND SPIDER VEINS with a chemical sclerosant (sclerotherapy)